Chronic Pancreatitis: The Inflammatory pancreatic head mass and the role of the Beger procedure.

Dr B.Jackson

Moderator: Prof Mieny

Introduction

- Chronic pancreatis is most frequently associated with alcoholism.
- Ductal pancreatic cancer can be found in 2% to 5% after 3 to 20 years of chronic pancreatitis
- Pain is usually the most common complaint.
- Origin of Pain**—perineural inflammation** and/or **ductal hypertension** (n=8-12cm H2O)
- 2 surgical principles chronic pancreatitis: **drainage** and/or **resection**.
- Chronic pancreatitis with an inflammatory mass in the head of the pancreas has been considered the classic indication for a resective procedure

Inflammatory mass in the head of the Pancreas in Chronic Pancreatitis

- Defined as a vertical pancreatic head diameter of 4cm or more on U/S, contrast CT or intraoperative findings
- Acts as a “pacemaker” of chronic pancreatitis due to complications (eg, common bile duct stenosis and duodenal stenosis).
- Higher pain score
- Resection of the inflammatory head results in favourable long-term results

Inflammatory enlargement (mass) of the pancreatic head

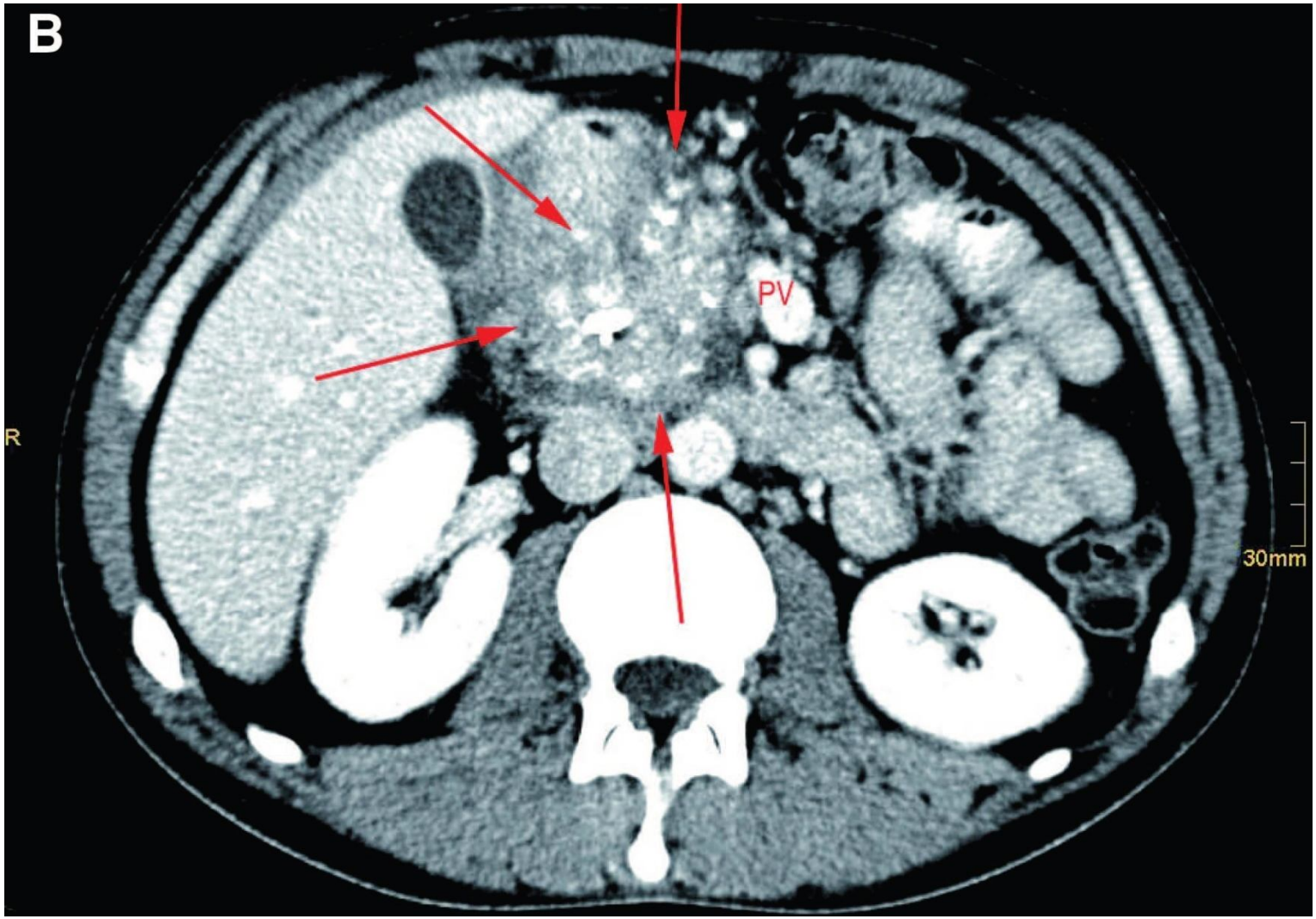

Pathomorphology of an inflammatory mass of pancreas head

- focal necrotic lesions
- small but rarely large pseudocystic cavities
- calcifications of the pancreatic parenchyma
- duct stones in the main duct
- loss of exocrine tissue, mainly the acinar cell component
- generation of extracellular matrix proteins, including laminin, fibronectin, and collagen

Factors influencing the inflammatory process in the pancreatic head

Overexpression of

- Epidermal growth factor receptor
- c-erb-B2 proto-oncogene
- transforming growth factor-α

Clinical features

- 70% to 90% are men, mostly under 40 years of age.
- Severe medically intractable pain
- 40% to 55% have a stenosis of the common bile duct
- 5% to 10% have severe duodenal stenosis
- 40% may have a single stenosis of the pancreatic main duct as demonstrated by ERCP or MRI
- 12% to 18% may have portal vein thrombosis also, splenic vein thrombosis associated with left sided portal hypertension with or without gastric varices;
- haemorrhage from pseudoaneurysms of the pancreatic and peripancreatic vasculature;
- Diabetes mellitus
- Ascites and fistulas

Pre-operative evaluation

- Nutritional status
- Degree of cholestasis
- Signs of portal hypertension and presence of ascites
- Endocrine function (i.e., fasting glucose level, oral glucose tolerance test) is mandatory.
- Faecal elastase for measurement of exocrine function
- Tumor markers CEA and CA 19-9 in addition to pancreatic and liver functions
- Upper gastro-intestinal endoscopy and ERCP
- MRI with reconstruction of the intrapancreatic ducts
- Pathomorphologic changes of the pancreas are delineated by CT scanning
- Suitability for operation (eg, addiction to alcohol).

The Beger Procedure—Duodenum-Preserving Pancreatic Head Resection (DPPHR)

- First experimented in dogs and introduced into clinical practice in 1972.
- The rationale: removal of the main inflammatory process while preserving the upper gastrointestinal tract.
- In contrast-enhanced CT scanning of the pancreas, 30% to 50% of all patients referred for surgical treatment demonstrate pancreatic head enlargement (3 to 4 cm).

Indications for DPPHR include the following

- Chronic pancreatitis with an inflammatory mass in the pancreatic head
- Chronic pancreatitis with an intrapancreatic common bile duct stenosis causing cholestasis or jaundice
- Pancreas divisum causing chronic pancreatitis
- Cystic neoplasia of the pancreatic head causing occlusion or compression of the pancreatic main duct and/or the common bile duct
- Adenomatous endocrine neoplasia of the pancreatic head complicating the duct systems
- Chronic pancreatitis causing portal/mesenteric vein compression
- Chronic pancreatitis causing stenosis of the duodenum

Surgical technique of Beger procedure

1. Surgical exposure of the pancreatic head and subtotal resection of the head between the portal vein and the intrapancreatic segment of the common bile duct.
2. Reconstruction with Roux-en-Y jejunal loop. Two pancreatic anastomoses must be done.

After tunneling of the portal vein behind the pancreas. Transection of the pancreatic neck along the duodenal border of the portal vein.

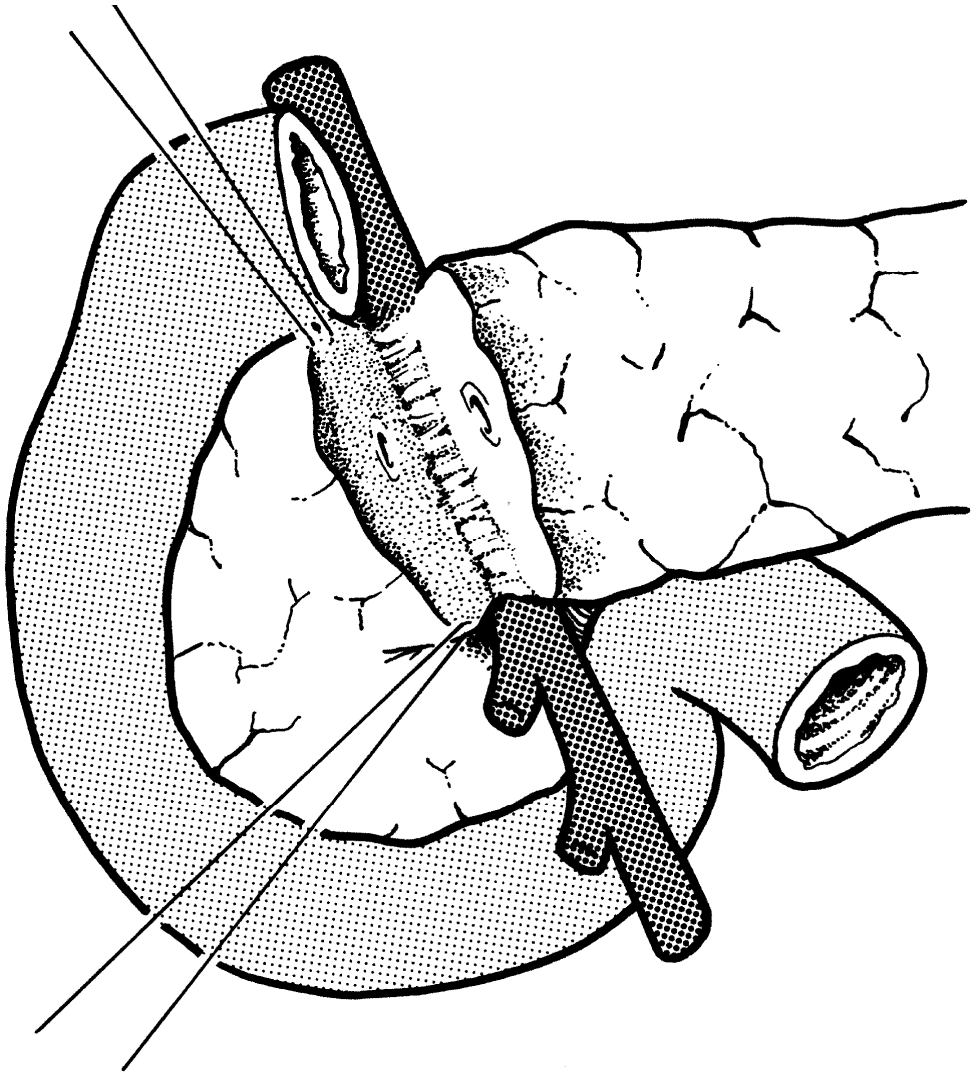

Subtotal resection of the pancreatic head between the portal vein and the intrapancreatic common bile duct after rotation of the pancreatic head by 90 degrees to the anteriorposterior position.

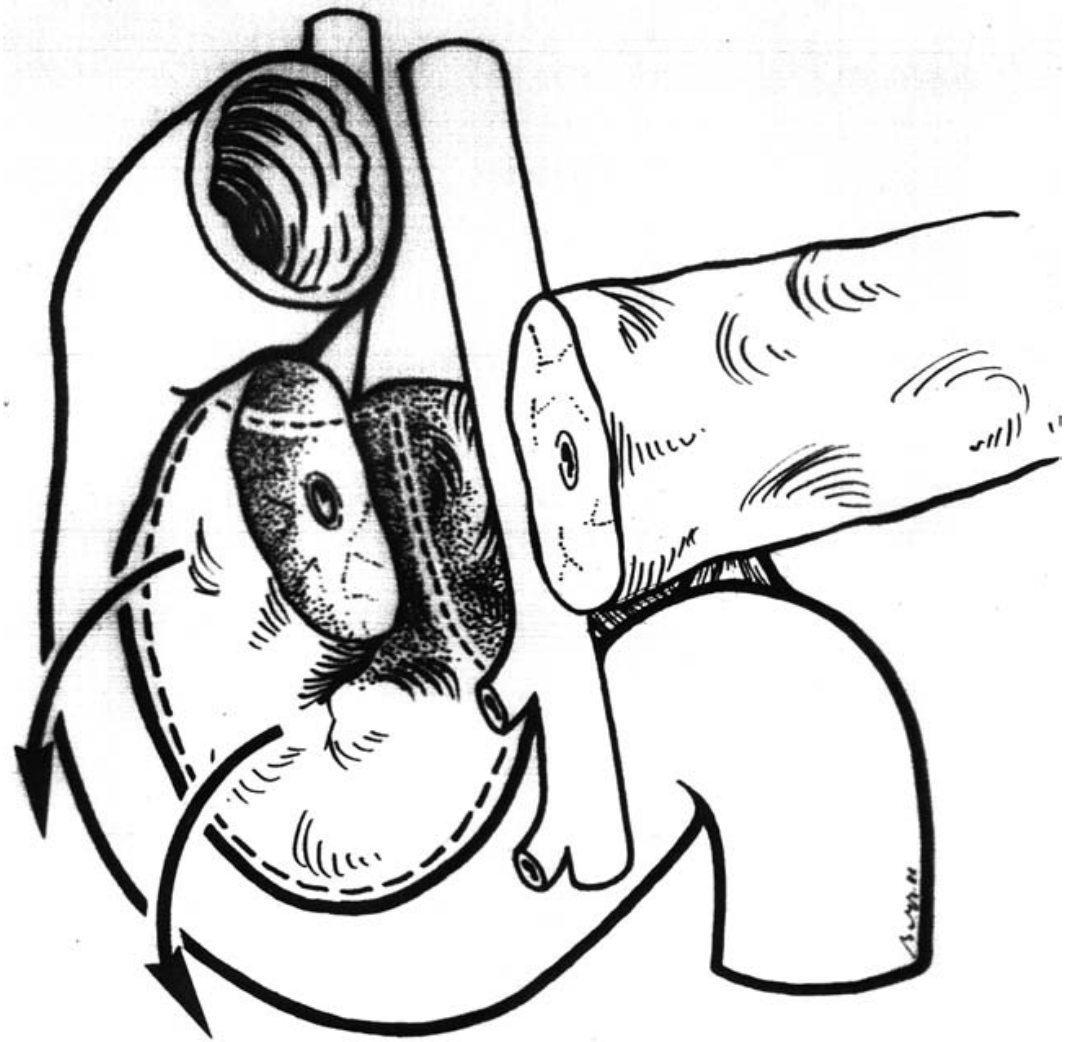

Subtotal resection results in decompression of the intrapancreatic common bile duct.

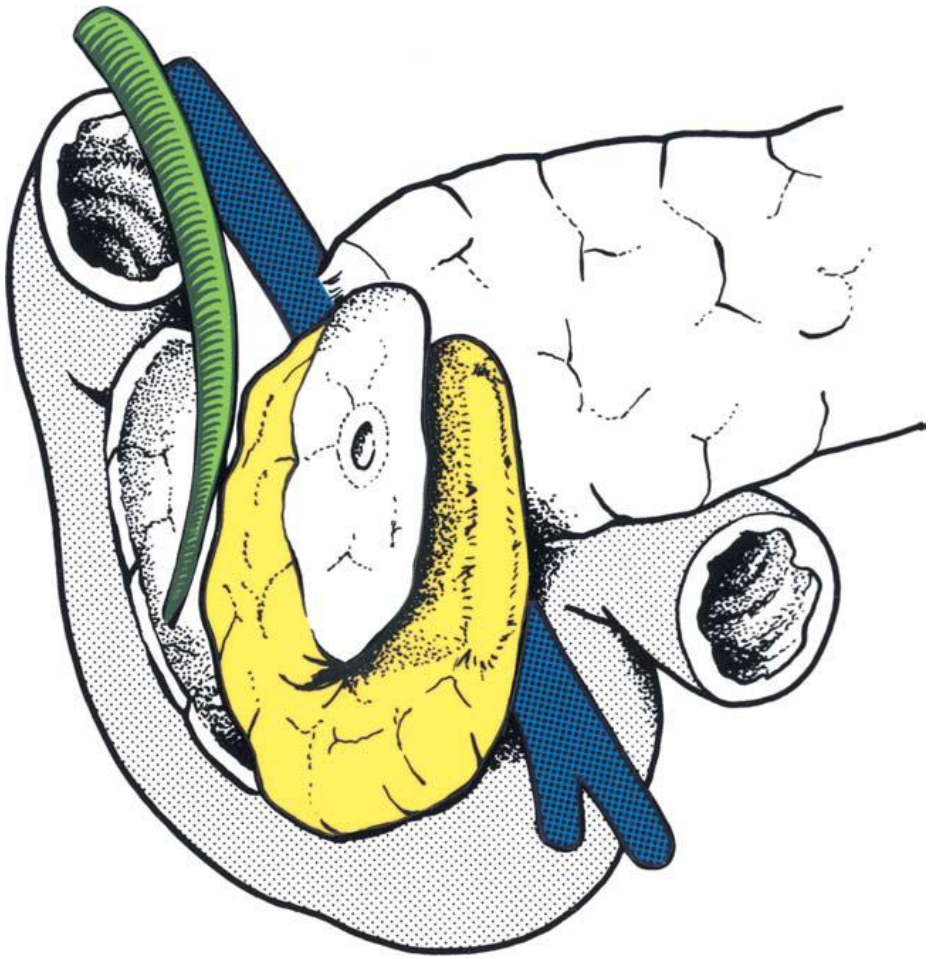

A shell-like structure is created in the remainder of the pancreatic head along the duodenum.

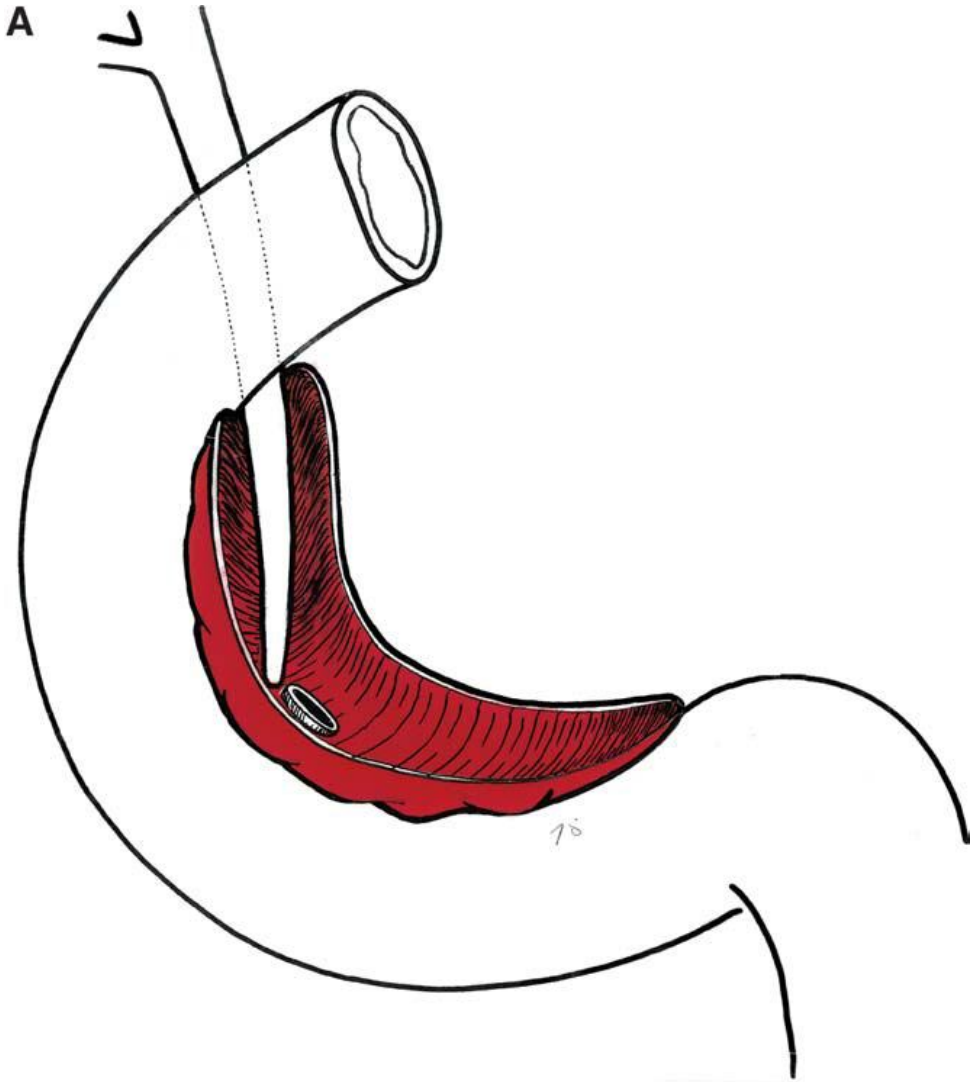

In severe common bile duct stenosis, an internal biliary anatomosis is performed between
the jejunal loop and the prepapillary common bile duct.

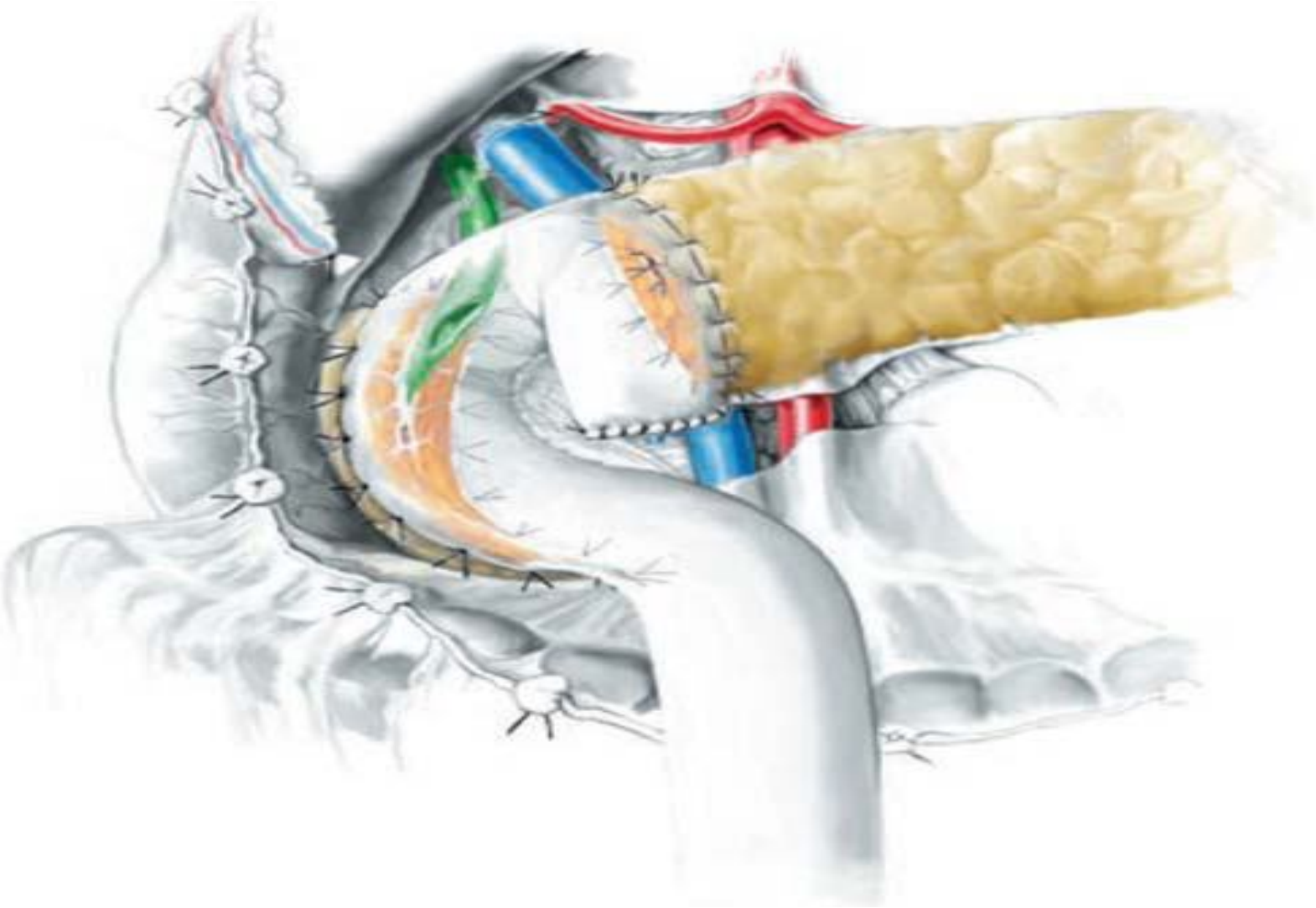

Duodenum-preserving pancreatic head resection: **Early** postoperative results in 603 patients

• Pancreatic fistula	3.3%
• Breakdown of pancreaticojejunostomy	1.5%
• Intra-abdominal abscess	2.8%
• Delayed gastric emptying	1.5%
• Hospitalization (postoperative)	14.5 days
• Relaparotomy	4.6%
• Hospital mortality	0.7%

*December 1972–October 2001: Department of Surgery, Free University Berlin (before May 1982); Department of General Surgery, University of Ulm (after May 1982).

Late outcome after duodenum-preserving pancreatic head resection in 388 patients

- Pain free 91.3%
- Continuing abdominal pain 8.7%
- Complaints, lower abdominal 12.0%
- Hospitalization due to pancreatitis 12.5%
- Return to work 69%
- Glucose metabolism normal 39%
- Insulin-dependent diabetes mellitus 44%

Different modifications of the duodenum-preserving pancreatic head resection

- **Frey** introduced a modification combining a longitudinal pancreaticojejunostomy with a local resection of the pancreatic head
- **Izbicki** performed a longitudinal V-shaped excision of the ventral pancreas to reach ductal side branches.
- **Berne** procedure combines the advantages of the Beger and Frey techniques. Avoids the delicate division of the pancreatic neck anterior to the portal vein and does not include a longitudinal opening and drainage of the pancreatic duct.
- **Warren procedure**, the pancreas is divided over the portal-superior mesenteric vein. The splenic artery and vein are ligated to denervate the body and tail of the pancreas

Beger procedure with the Berne modification

- Wide hollowing out of the pancreatic head without the inherent risks related to the dividing of the pancreas above the portal vein, which can be anastomosed end-to-side with a Roux-en-Y jejunal loop
- The Berne variation of DPPHR is equally effective compared with the original Beger technique regarding early and late postoperative outcomes.
- Both techniques seem to be equally effective regarding pain relief within two years after surgery.
- Taking into account the shorter operating time, this technique seems to be highly efficient in the treatment of patients with chronic pancreatitis and inflammatory pancreatic head tumors.
- Other studies will have to confirm results because the data are based on a **single** institution trial.

Surgery Volume 143, Issue 4, April 2008, Pages 490-498

Frey procedure

- Frey joined Gardner Child in 1964, who did 80%–95% **distal pancreatectomy** to control pain in patients with chronic pancreatitis.
- Associated with a high short- and long-term morbidity.
- **Longitudinal pancreaticojejunostomy** (LPJ) by Partington-Rochelle failed to address disease associated with the ducts of Wirsung, Santorini, or the uncinate
- Frey: Combining the head resection of the Child operation (80%–95% distal resection) with the LPJ decompression of the main duct in the neck, body, and tail of the gland

Local resection and Longitudinal Pancreatic duct opened

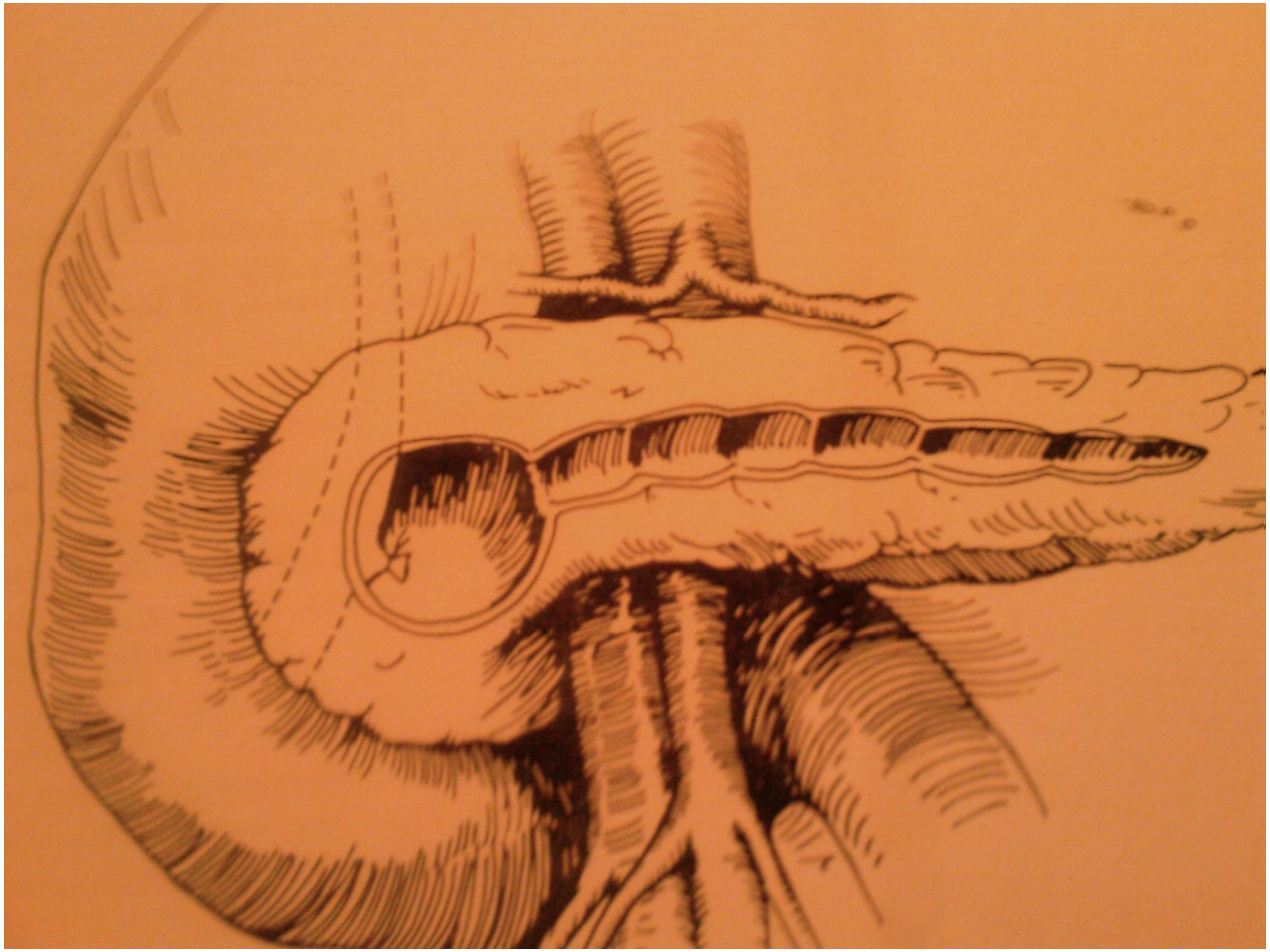

Longitudinal resection and Longitudinal Pancreaticojejunostomy

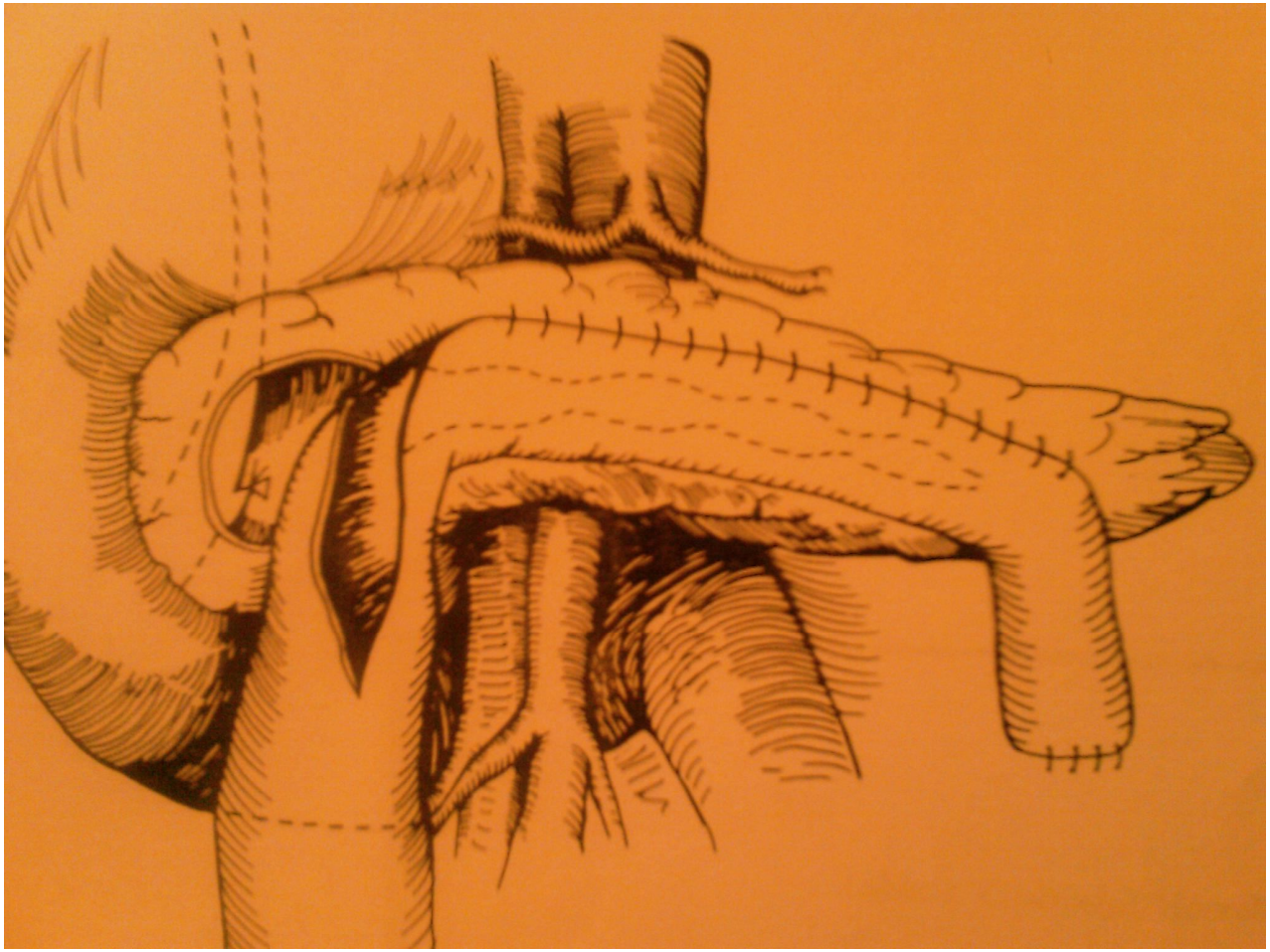

Frey procedure

- Combines the best features and eliminating the worst features of both the Child and the LPJ operations.
- In coring out (slicing pieces) the head of the pancreas, tissue posterior to the duct of Wirsung are not removed .
- A Roux-en-Y limb is used to drain the cored out head of the pancreas as well as the main pancreatic duct in the body and tail of the pancreas
- The jejunal limb is attached to the capsule of the pancreas, and an end-to-side jejunojejunostomy is placed approximately 40 cm below the pancreaticojejunostomy.

Advantages of the Frey Procedure

- Eliminates pain.
- The problems of the Child operation such as pancreatic fistulas and infected collections of pancreatic juice were reduced.
- Improvement of disease (obstructing calculi and strictures) in the main duct
- Less exocrine and endocrine insufficiency
- Simpler to perform than pancreaticoduodenectomy or duodenum-preserving pancreatic head resection.
- The LR-LPJ does not require division of the neck of the pancreas, which may be technically difficult if inflammation and portal hypertension cause adherence of the portal-superior mesenteric vein to the pancreas.
- With the LR-LPJ, the pancreatic head can be drained in continuity with the Roux en-Y limb draining the body and tail of the pancreas. This avoids the two separate anastomoses required in the DPHR procedure.

Differences between the Beger and Frey operations

- **Beger**: *Division* of the pancreas at its neck

  Frey: Roux-en-Y *drainage* of the neck, body, and tail of the pancreas.
- LR-LPJ does not require removal of a large amount of pancreas thereby reducing exocrine and endocrine insufficiency.
- Although (longitudinal pancreaticojejunostomy) involving the neck, body, and tail of the pancreas can also be accomplished in the duodenum-preserving head resection, Beger's group in Ulm has only used major duct decompression in 10% of their patients
- Izbicki and colleagues found **no difference** between the two procedures with regard to pain relief, quality of life, definitive control of complications affecting adjacent organs and exocrine and endocrine function in short term follow up
- There is also comparable quality of life and pain control after longterm (>8.5yrs) follow-up.
- Both operations are contraindicated in patients in whom the distinction between chronic pancreatitis and cancer of the pancreas cannot be made.

Pancreaticoduodenectomy indications

- Disease is in head of pancreas.
- Common bile duct or duodenal obstruction from small pseudocysts or cicatization in the head or uncinate process.
- A “small” major pancreatic duct
- Severe pain

Total Pancreatectomy

- After pancreaticoduodenectomy or distal subtotal resection fails to provide pain relief.
- Rarely the primary procedure as it creates exocrine and endocrine insufficiency.

Pancreatic drainage procedures

- Duval (pioneered duct drainage operations) described a procedure that involved splenectomy, resection of the pancreatic tail, and then creation of an end-to-end anastomosis between the transected end of the pancreas and a Roux-en-Y limb of jejunum.
- 1958, Puestow and Gillespy described an operation that involved longitudinally opening the entire duct and then invaginating the opened pancreas into a Roux-en-Y loop of jejunum.
- 1960, Partington-Rochelle modified the longitudinal pancreaticojejunostomy by creating a a side-to-side anastomosis between the opened duct and jejunum, thus eliminating the need for splenectomy.
- Longitudinal pancreaticojejunostomy: duct as small as 5mm (normal: 2-3mm) can be sewn to jejunum to capsule of pancreas. Usually >8mm can do duct-to-mucosa anastomosis

Anatomical Characteristics and Complications of Chronic Pancreatitis in the German (n 48) and American (n 45) Group

Variable	Germany	United States
AP diameter of the pancreatic head (cm) median (range)	4.5 cm	2.6 cm
Alkaline phosphatase	227 (0–260) U/L	110 (3–304) U/L
Bilirubin Median (range)	1.5 (0.1–24) mg/dL	0.46 (0.2–1.5) mg/dL
Chemical cholestasis	46%	4%
CBD stenosis	19 (40%)	11 (26%)
Duodenal stenosis	9 (19%)	1 (2%)
Pancreato-pleural fistula	3 (6%)	0%
Hemorrhage	7 (15%)	0%
Occlusion splenic vein	14 (29%)	0%
PV/SMV stenosis or thrombosis	8 (15%)	(1) 2%

Principal Indication for Surgical Treatment

Indication	Germany	United States
Chronic pain	15 (31%)	28 (62%)
Suspicion of malignancy	5 (10%)	11 (24%)
Gastric outlet obstruction	8 (17%)	1 (2%)
Haemorrhage	7 (15%)	0%
Biliary stenosis/jaundice	6 (13%)	3 (7%)
Multiple indications	7 (15%)	2 (4%)

Treatment Performed in 93 Patients

Operation	Germany (n 48) n (%)	United States (n 45) n (%)
Pancreaticoduodenectomy with antrectomy (whipple)	1 (2%)	37 (82%)
Pylorus-preserving pancreaticoduodenectomy (PPPD)	8 (17%)	3 (7%)
Duodenum-preserving pancreatic head resection (DPPHR)	25 (52%)	None
Distal pancreatectomy	5 (10%)	3 (7%)
Others*	9 (19%)	2 (4%)

*Six patients in the German group had no surgical or interventional treatment

DPPHR not always the preferred surgical option for CP, particularly in the USA.

- Complexity of the original Beger procedure.
- The Beger procedure is considered more difficult than the Whipple operation.
- In the Beger procedure subtotal pancreatic head resection that is too limited might result in recurrence of complications, particularly jaundice and pain.

British Journal of Surgery 2008; ***95: 350–356***

Differences in US vs Germany

- The US center typically used a classic pancreatoduodenectomy (with antrectomy), whereas the German group preferred pylorus-preserving technique
- More than half of the German patients had a **duodenum preserving pancreatic head resection** versus none in the US group.
- These observed differences might just reflect patterns of patient referral, bias, and experience, or may be the product of real differences in the nature of CP in different patient populations.
- If there are genuine differences in the morphology of CP in various geographic locales, these may reflect as yet undetermined differences in pathogenesis.

Determining which operation is more effective in patients with chronic pancreatitis

- No single operation that relieves pain and addresses all complications of chronic pancreatitis
- The ideal operation should have a low morbidity and mortality, be easy to perform, provide long-lasting pain relief, rectify the complications and not augment exocrine and endocrine insufficiency.
- Patient selection, eg. Alcohol use.
- In case of portal vein encasement, the Berne (or even Frey) technique which spares the division of the pancreas above the portal vein can be performed more easily.
- On the other hand, in some cases it may be technically difficult to resect all the inflamed tissue from the pancreatic head and neck without dividing the pancreas.
- Surgeon's ability to match the patient's problem with the most appropriate solution

References

- Frey CF and Amikura K. Local Resection of the Head of the Pancreas Combined with Longitudinal Pancreaticojejunostomy in the management of Patients with Chronic. Pancreatitis. Annals of surgery. J.B. Lippincott Company. 1994; Vol 220. No. 4,492-507.
- Beger HG, Gansauge F, Schwarz M and Poch B. Pancreatic head resection: the risk for local and systemic complications in 1315 patients-a monoinstitutional experience. The American Journal of Surgery 194 (Suppl to October 2007) S16-S19.
- Frey CF, Suzuki M, Isaji S and Zhu Y. Pancreatic Resection for Chronic Pancreatitis. The Pancreas. 499-528
- Beger HG, Buchler M, Ditschuneit H and Malfertheiner P. Chronic Pancreatitis-Research and Clinical Management. Springer-Verlag. 1990.
- J. R. Izbicki, et al. Extended Drainage Versus Resection in Surgery for Chronic Pancreatitis- A Prospective Randomized Trial Comparing the Longitudinal Pancreaticojejunostomy Combined With Local Pancreatic Head Excision With the Pylorus-Preserving Pancreatoduodenectomy. Annals of Surgery. Lippincott Williams & Wiidns. 1998; Vol. 228, No. 6, 771-779.
- Strate T, et al. Long-term Follow-up of a Randomized Trial Comparing the Beger and Frey Procedures for Patients Suffering From Chronic Pancreatitis. Annals of Surg. 2005;241: 591–598.
- Köninger J, et al. Duodenum-preserving pancreatic head resection—A randomized controlled trial comparing the original Beger procedure with the Berne modification. Surgery. Mosby. April 2008. Volume 143, Issue 4, Pages 490-498

References...continued

- Muller MW, et al. Long-term follow-up of a randomized clinical trial comparing Beger with pylorus-preserving Whipple procedure for chronic pancreatitis. (Online) 2007 in Wiley InterScience. Available on www.bjs.co.uk.
- Keck T, et al. The Inflammatory Pancreatic Head Mass Significant Differences in the Anatomic Pathology of German and American Patients With Chronic Pancreatitis Determine Very Different Surgical Strategies. Annals of Surgery. 2009;249: 105–110.
- Frey CF and Mayer KL. Comparison of Local Resection of the Head of the Pancreas Combined with Longitudinal Pancreaticojejunostomy (Frey Procedure) and Duodenum-Preserving Resection of the Pancreatic Head (Beger Procedure). World Journal of Surgury. 2003 27, 1217–1230.
- Beger HG, Kunz R and Poch B. The Beger Procedure—Duodenum-Preserving Pancreatic Head Resection *"How I Do It".* The Society for Surgery of the Alimentary Tract. 2004. Vol. 8, No. 8, 1090-1097.
- Izbicki JR, et al. Duodenum-Preserving Resection of the Head of the Pancreas in Chronic Pancreatitis A Prospective, Randomized Trial. Annals of Surgery. J. B. Lippincott Company . 1995, Vol. 221, No. 4, 350-358