



University of Pittsburgh

# Interventional MRI (iMRI) guided Deep Brain Stimulation for Parkinson's Disease

Anesthetic considerations | A case study

Lydia Cendana

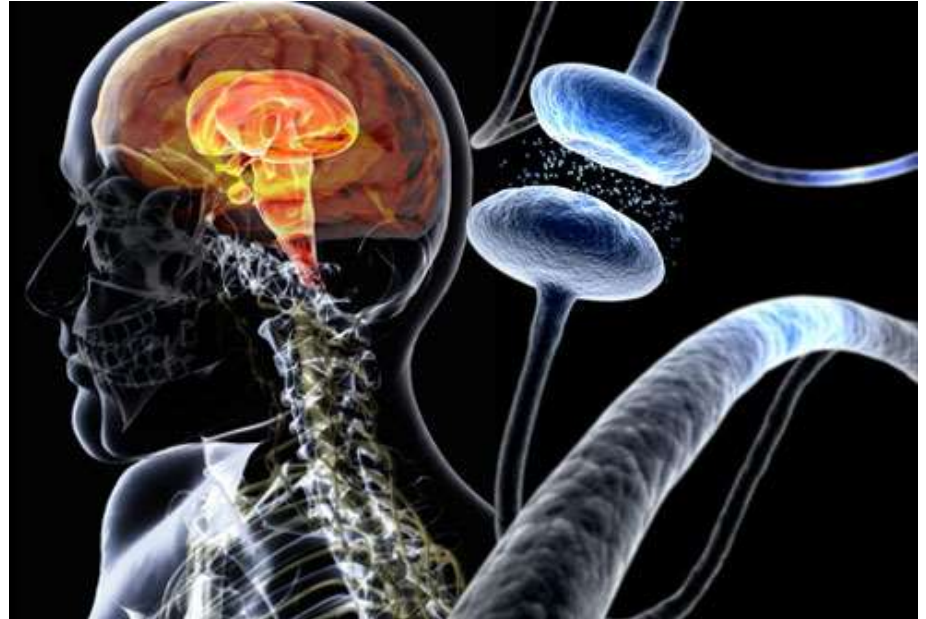University of Pittsburgh

School of Nurse Anesthesia





Parkinson's disease is diagnosed in more than 50,000 Americans each year



The motor symptoms associated with PD can be debilitating, affecting the ability to perform everyday functions.




- “DBS surgery offers important symptomatic relief in patients with moderate disability from Parkinson's disease who still retain some benefit from antiparkinsonian medications and who are cognitively intact.”



UPMC Presbyterian Hospital was one of the first of 10 programs *worldwide* that offers iMRI guided DBS

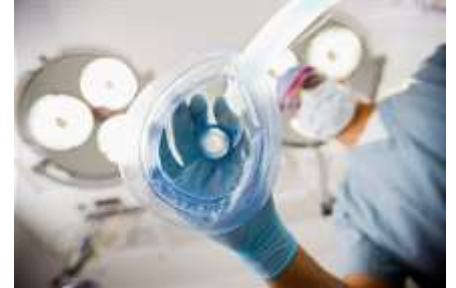What is the advantage?

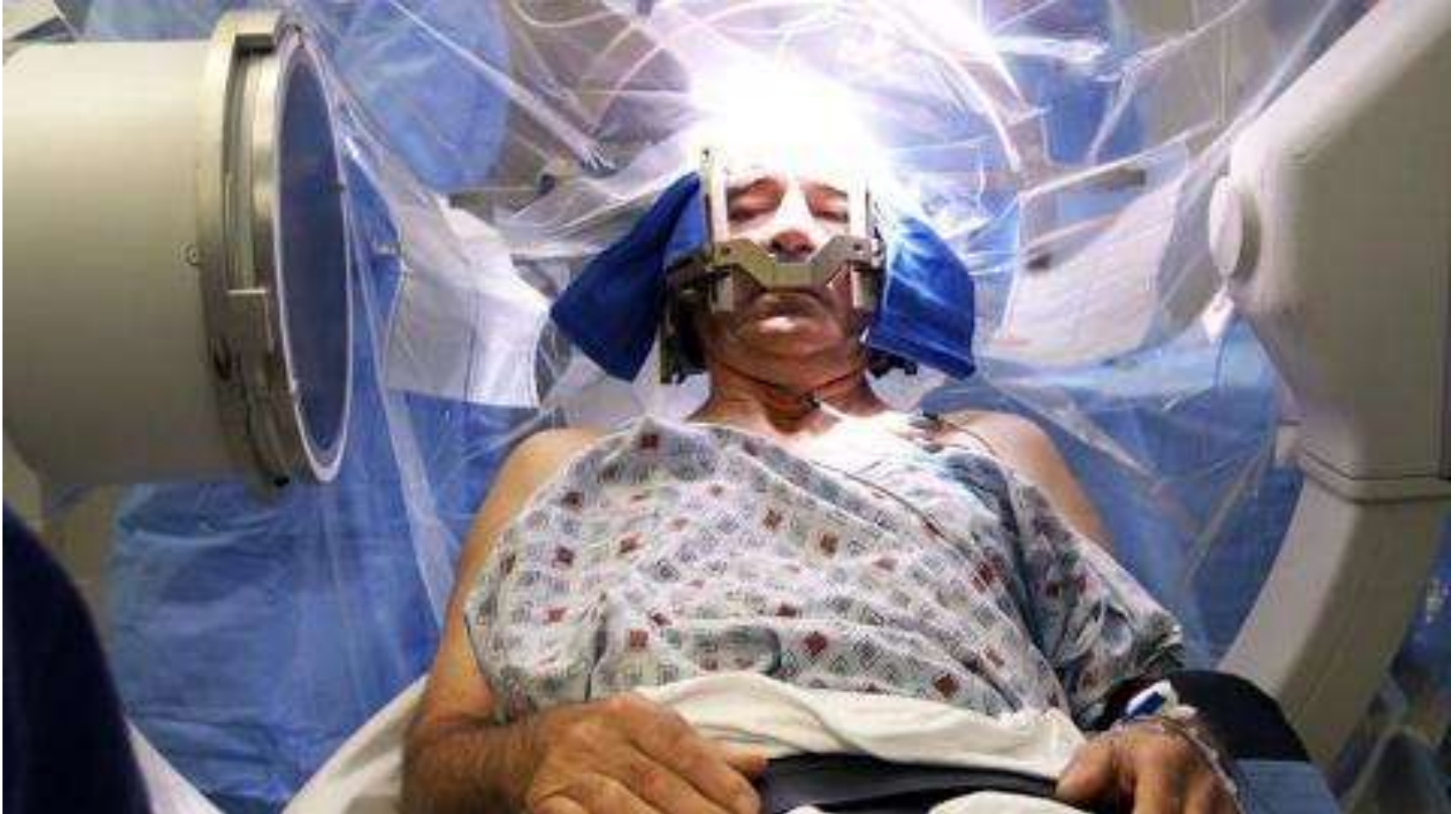


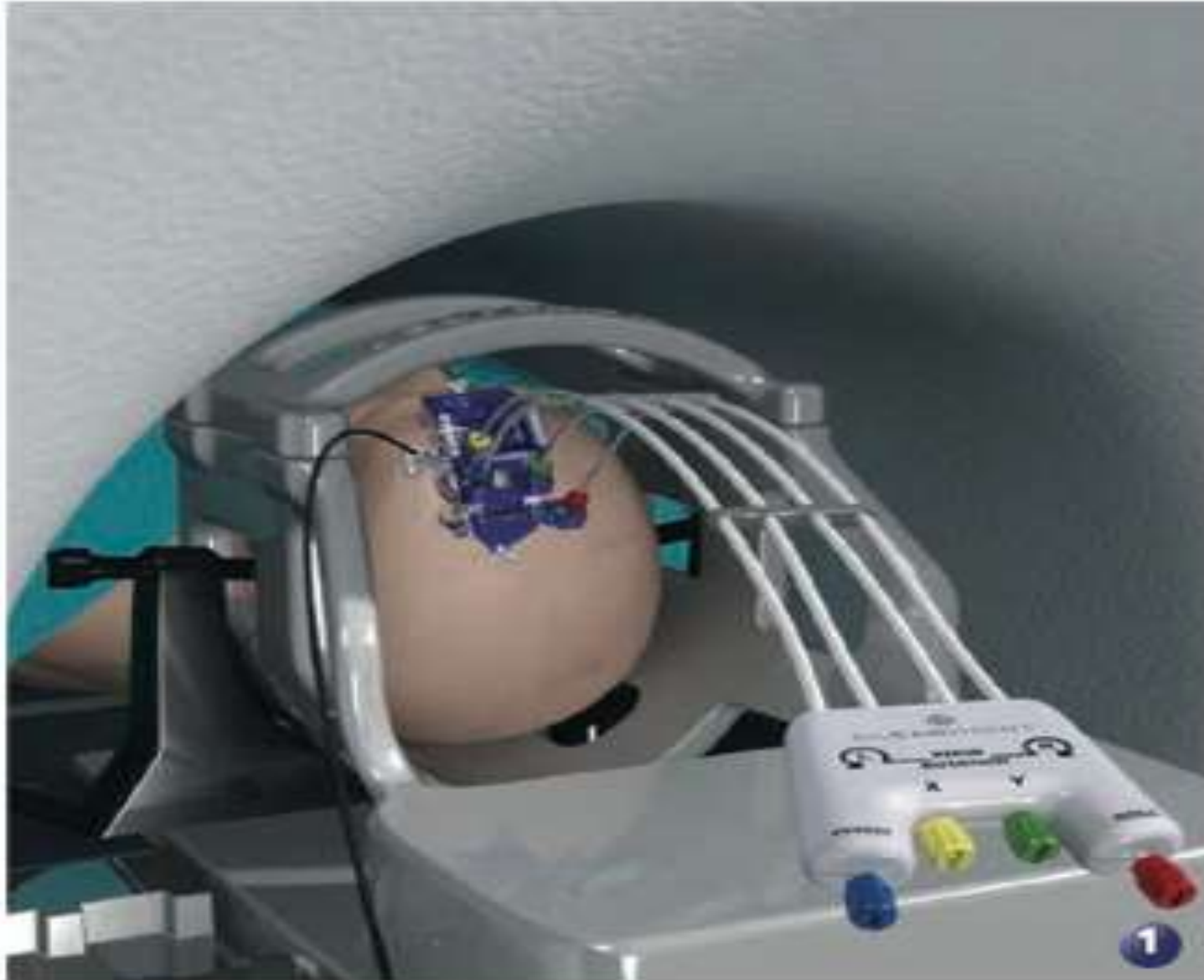
## iMRI-guided vs. standard DBS

- iMRI guided DBS offers a great alternative to standard DBS for the patient.
- Standard DBS involves an awake patient in an uncomfortable head frame



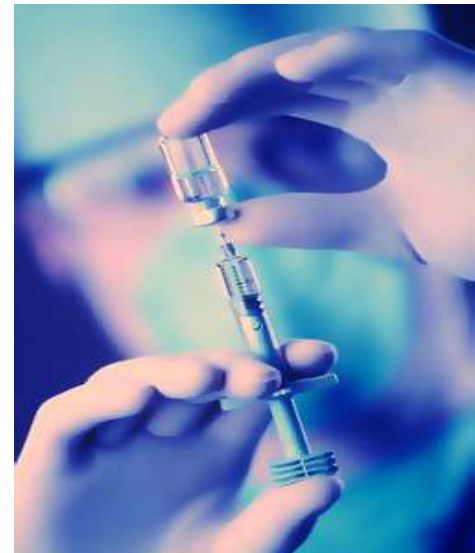





# Anesthetic concerns and considerations:

- MRI safety including airway protection
- Parkinson's disease-specific issues
- Risk for intracranial hemorrhage

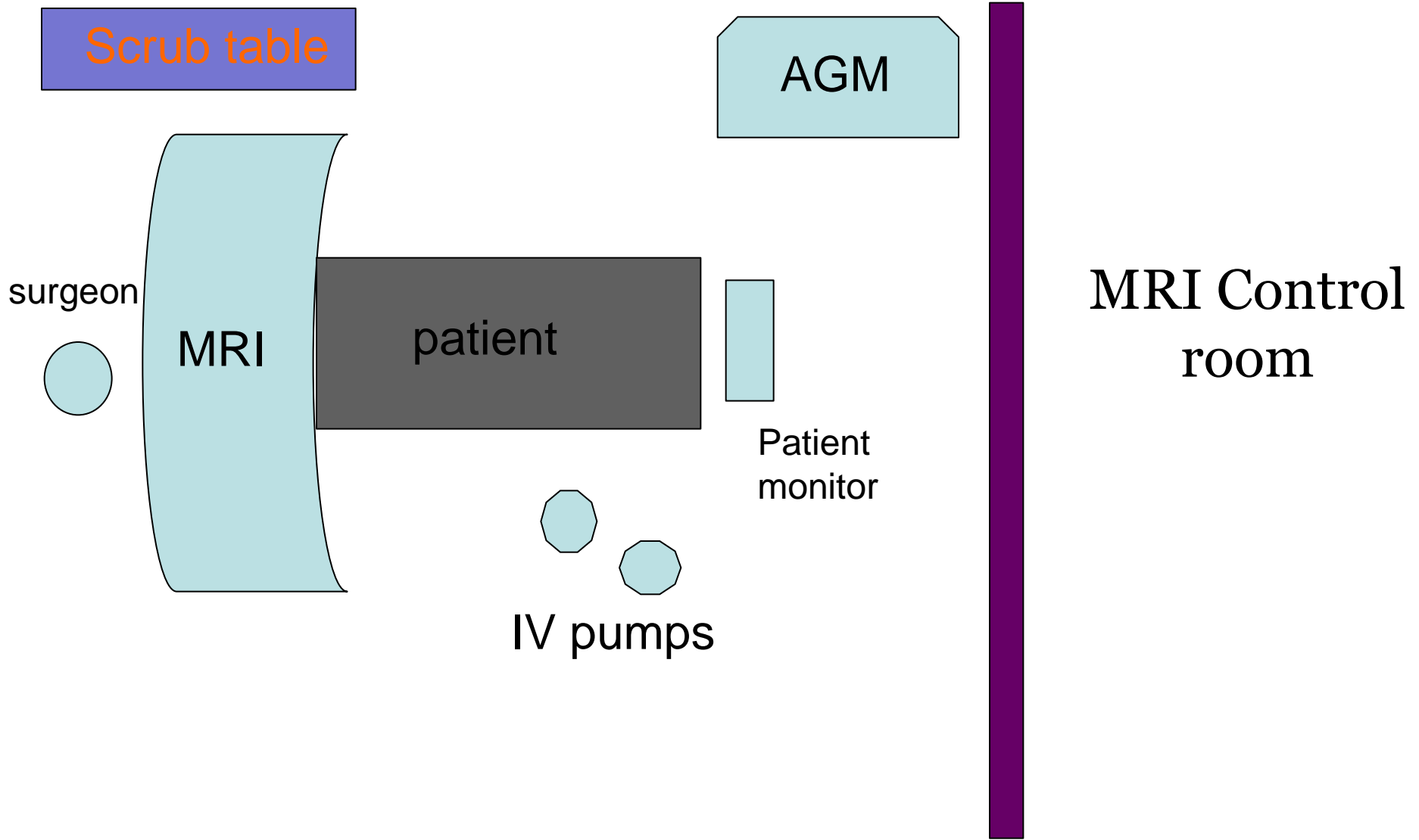






## **MRI safe anesthesia:**

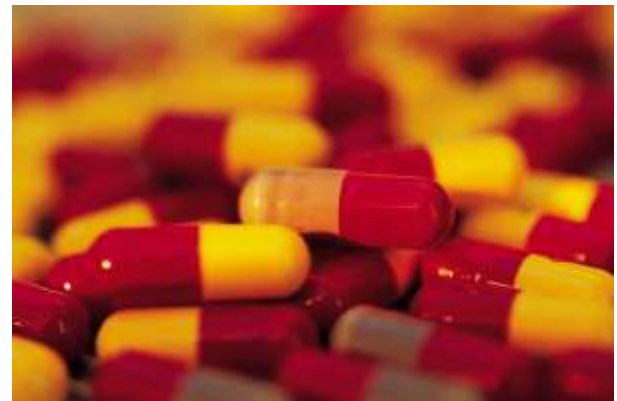- All anesthesia equipment needs to be MRI safe
- Field avoidance is a major airway safety issue
- The anesthesia provider may be unable to reach the the head or torso so careful attention to positioning and equipment placement is necessary





# Parkinson's disease considerations:

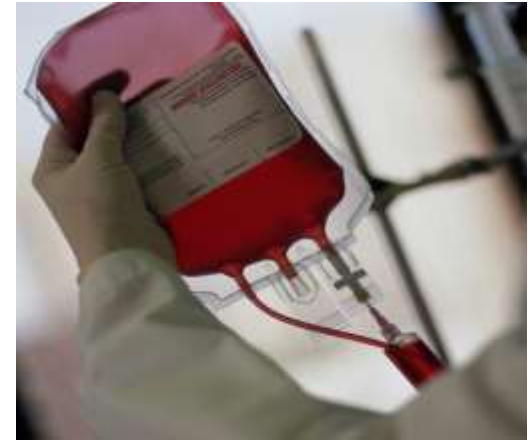- Patients undergoing DBS surgery are often on high doses of Parkinson's disease medications
  - An OG should be placed after induction to allow for administration of the patient's carbidopa-levodopa
- Drugs that precipitate or exacerbate Parkinson's symptoms should be avoided: phenothiazines, butyrophenones, and metoclopramide.
- Patients are often hyperdynamic → may have to address blood pressure control





# Intracranial Hemorrhagic

**Bleeding is considered to be one of the greatest surgical risks for iMRI guided DBS surgery.**



- The anesthetist plays an important role in hemorrhage prevention through blood pressure control
- Two peripheral IVs should be placed with access to a large bore infusion line as well as access for vasoactive drips
- **Must be prepared for a trip to the operating room in the event of a surgical emergency**



## Case presentation:

- 44 year old male with PMH significant for early onset Parkinson's disease
- Carbidopa-levodopa medication regimen included *10-12 doses per day*
- Procedure: bilateral DBS lead extender placement in MRI
- Peripheral IV placed in pre-op: 2mg midazolam given



## Induction:

- Standard IV Propofol/SCh induction in the MRI holding room.
- Left radial arterial line and second IV placed after induction.
- Patient placed on remifentanyl, propofol and precedex gtt in MRI safe infusion pumps.
- MRI-safe leads applied and patient transported into MRI



## Maintenance:

- Sevoflurane maintained at 0.8-0.9% ET
- Dexemedotomidine (0.5mcg/kg/hr) and remifentanil (0.2mcg/kg/min) infusions used in adjunct
- 50mg rocuronium given after induction and then 20mg rocuronium given q1hr per protocol as MRI-safe twitch monitor not available
- Clevidipine (CCB) available in line for BP control if needed



## Emergency:

- 1 gram acetaminophen given at end of case for post-op pain management
- Sevoflurane turned off when patient to be moved out of scanner.
- Patient transported to MRI holding room where TOF evaluated with a twitch monitor, pt. given reversal, suctioned and extubated once extubation criteria met.
- Patient transported to PACU





## Post-operative considerations:

- Patient will return to the OR in a few days for placement of the stimulator (usually in pectoral area, subcutaneously, similar to a pacemaker)



[DBS at presby](#)



## References:

“Deep Brain Stimulation for Movement Disorders” University of Pittsburgh  
Epilepsy and Movement Disorders Program

<http://www.neurosurgery.pitt.edu/centers-excellence/epilepsy-and-movement-disorders-program/deep-brain-stimulation-movement-disorders>

Nicholson G, Pereira AC, Hall GM. Parkinson's disease and anaesthesia. *Br J Anaesth*. Dec 2002;89(6):904-916.

R. Mark Richardson, MD, PhD; Douglas Kondziolka, MD “New interventional MRI deep brain stimulator surgery program offered” University of Pittsburgh  
Neurosurgery News (2012) 13:3.

[http://www.neurosurgery.pitt.edu/sites/default/files/Pdf\\_Files/Newsletter/2012summer.pdf](http://www.neurosurgery.pitt.edu/sites/default/files/Pdf_Files/Newsletter/2012summer.pdf)