

Enteral Nutrition
via
Nasogastric Tube
&
PEG Tube



Enteral Nutrition

Enteral Nutrition (EN): Feeding through a tube.

- Important to decide on site and size of the tube.
- Site: nasal or percutaneous (e.g. stomach, duodenum, jejunum).
- Site depends on concurrent injuries, disease, impaired gastric motility, risk of aspiration & duration of nutritional support. (Williams 2009)
- Fine bore (5-12 Fr), large bore (>14Fr)
Size: Depends on need for medications, feeding, gastric suctioning, decompression, measurement of pH or residual volumes. (Williams, 2009)
- EN can be cyclic, bolus and intermittent.



- The preferred method of delivering EN is with a medical infusion pump.
- At pre-determined intervals, oftentimes at night while the person is sleeping, a specially balanced feeding solution is dripped into the tube either by gravity or by pump.
- In the morning the feeding is disconnected and allows the person to mobilise unhindered.



Indications

- Patients with a functioning GI tract but inadequate oral intake due to:
 - Neurological indications (e.g. stroke, coma)
 - Increased energy requirements (hypermetabolic states) – e.g. burns, injury/trauma, illness
 - Gastrointestinal disease – e.g. IBD
 - Upper GI tract obstruction
 - Eating disorders



Contraindications

- Gastrointestinal obstruction
- Prolonged ileus
- Enterocutaneous fistula
- Severe vomiting/diarrhoea



Advantages

- Improved nutritional status (Zalar et al, 2004)
 - Low incidence of complications
 - Cost effective - especially NG feeding
 - Satisfactory use by home carers (Zalar et al, 2004)
 - Convenience
 - Decreased infectious complications
 - Enhanced host immune function
 - Maintains GI mucosal structure & function
 - Provides convenient access to GI tract (often used for meds that are unable to be swallowed)
- (Williams, 2009)



Complications

1. Mechanical: e.g. blockage, malposition
2. Gastrointestinal:
 - Diarrhoea/constipation
 - Nausea
 - Reflux/regurgitation
 - Abdominal distension/bloating
3. Metabolic:
 - Hyperglycaemia
 - Hyperkalaemia
 - Low phosphate/magnesium/zinc
 - Vitamin/mineral/trace elements/essential fatty acid deficiencies
4. Miscellaneous:
 - Abnormal liver function tests
 - Pulmonary aspiration

(Pearce & Duncan, 2002)

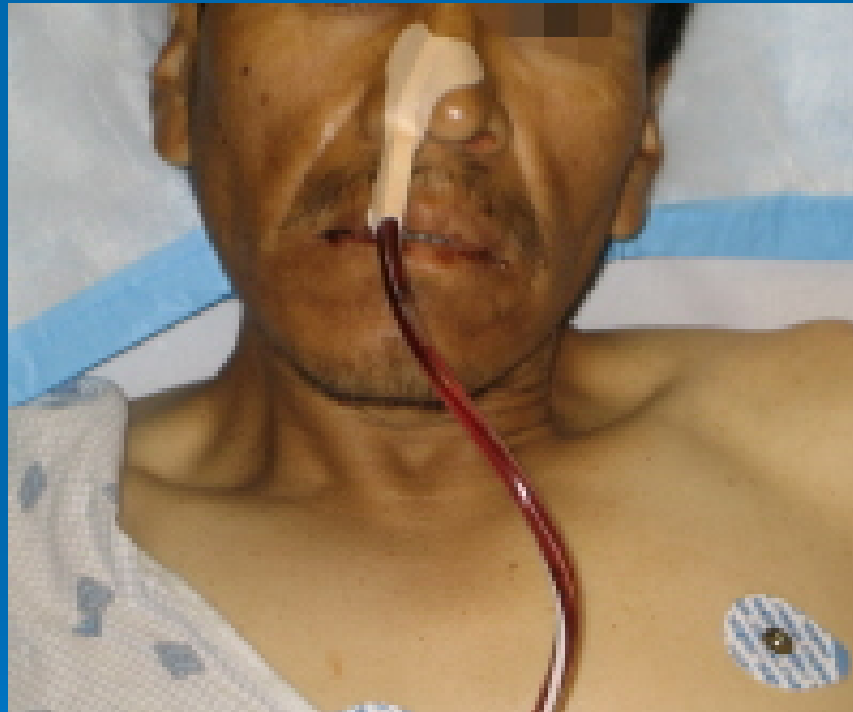

The nutrient solution consists of:

- water
- electrolytes
- glucose
- amino acids
- lipids
- essential vitamins, minerals and trace elements are added or given separately.



Nasogastric (NG) Tube



(image from: <http://emedicine.medscape.com/article/80925-media>)



INDICATIONS

➤ Diagnostic

- Evaluation of upper gastrointestinal (GI) bleed (presence of blood, volume)
- Aspiration of gastric contents
- Identification of the oesophagus and stomach on a chest radiograph
- Administration of radiographic contrast to the GI tract



INDICATIONS contd.

➤ Therapeutic

- Feeding – Inability to take orally, e.g.
 - Loss of swallowing reflex, e.g. a stroke (fine-bore tubes),
 - Facial fractures (fine-bore tubes),
 - Inflammation of the mouth/oesophagus (fine-bore tubes)
- Gastric decompression, including maintenance of a decompressed state after endotracheal intubation
- Relief of symptoms and bowel rest in the setting of small-bowel obstruction
- Aspiration of gastric content from recent ingestion of toxic material
- Administration of medication/oral agents



Contraindications

Absolute:

- Maxillofacial trauma/basilar skull fracture
- Recent nasal/oesophageal/gastric surgery

Relative:

- Oesophageal abnormalities/strictures
- Oesophageal burns or alkali/acid ingestion
- Oesophageal varices or recent banding/cautery of varices
- Coagulation abnormalities

(SJH policy 2005, Todd et al 2008, Dehn & Asprey 2007, Absukis et al 2000)



COMPLICATIONS

- Patient discomfort/sore throat
- Blockage of the tube
- Traumatic complications:
 - Trauma to nasopharynx
 - Epistaxis – lubricate tip, gentle insertion to prevent
 - Oesophageal perforation
 - Intracranial placement – very rare
- Aspiration
- Respiratory tree intubation
- Pneumothorax



Nursing staff may contact team if there are concerns regarding continued use of an NG tube if:

- the patient has vomited or coughed violently
- the marking of the tube has slipped
- the patient can feel the tube in their throat
- malposition of the tube is suspected



Percutaneous Endoscopic Gastrostomy (PEG) Tube Feeding

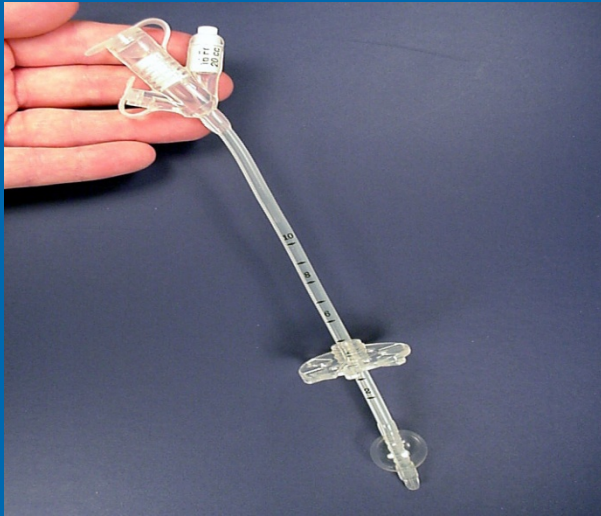


Image from:
<http://emedicine.medscape.com/article/421427-overview>

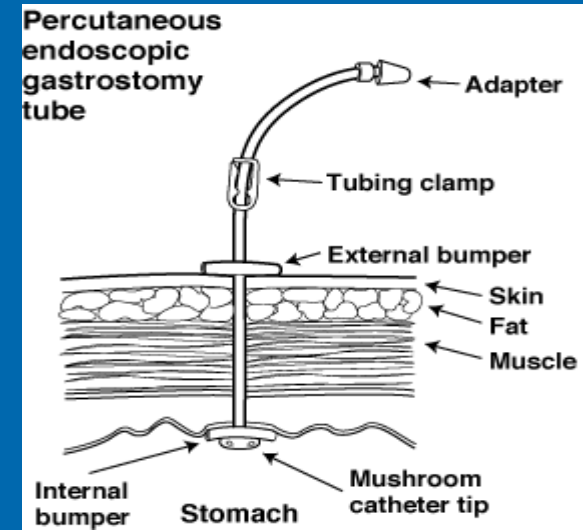


Image from:
http://my.clevelandclinic.org/services/Percutaneous_Endoscopic_Gastrostomy_PEG/hic_Percutaneous_Endoscopic_Gastrostomy_PEG.aspx

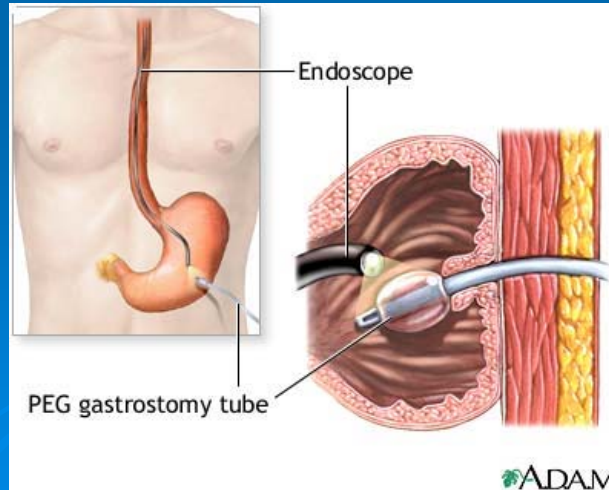
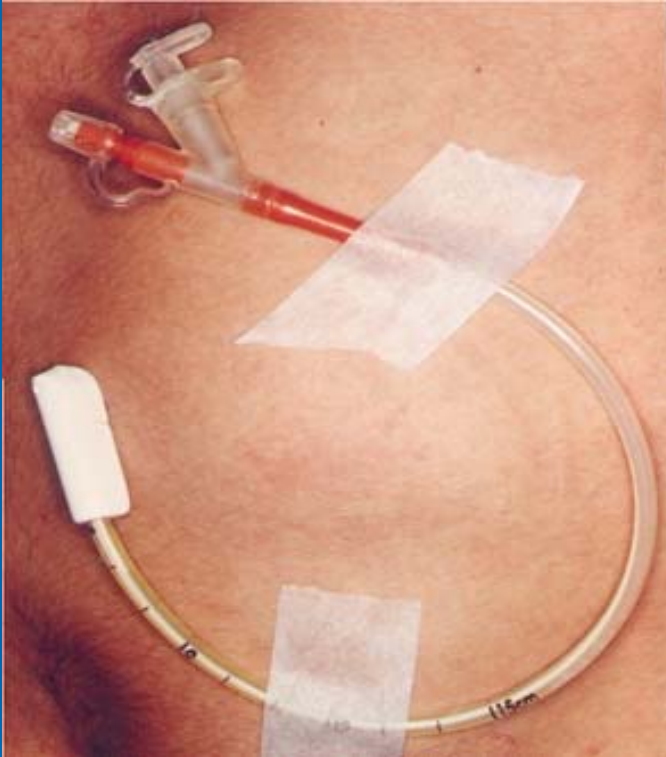


Image from:
http://www.nlm.nih.gov/medlineplus/ency/presentations/100125_5.htm





PEG in-situ

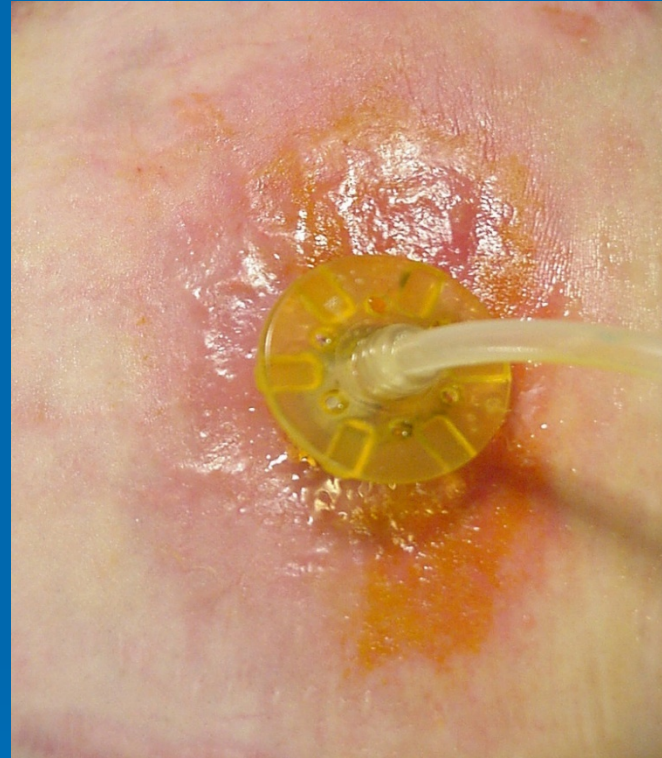


Image from: <http://emedicine.medscape.com/article/421427-overview>

Infected site



Indications

- Requirement for prolonged nutritional support where oral or nasogastric feeding is difficult or contraindicated:
 - Neurological – e.g. due to impaired swallowing from neurological disease: stroke, MS, advanced dementia, Parkinson's disease
 - Malignant bowel obstruction, including oesophageal cancer
 - Head and neck cancers

- Uses: nutrition, hydration and administration of medications
- Benefits:
 - Better tolerated compared to NG tube
 - Reduction in aspiration pneumonia associated with swallowing disorders (Zaler et al, 2004) – but there is still risk of aspiration
- A simple gastrostomy requires approx. 1-2 weeks to form a tract. A gastrostomy tract can narrow or close within hours of tube removal.



Contraindications

- Bleeding disorders
- Inability to perform OGD
- Anatomical abnormalities (e.g. gastrectomy)
- Gastric cancer
- Active gastritis or peptic ulcer disease
- Intestinal obstruction (unless used for drainage)
- Peritonitis
- Ascites
- PEG replacement should not be performed if there is any evidence of infection around the site.



Complications

- Blockage/dislodgement/inadvertent removal
- Leakage
- Aspiration
- Dehiscence
- Infection
- Granulation tissue formation
- Gastric perforation
- Misplacement in the peritoneal cavity- peritonitis
- Tube degradation (Zaler et al, 2004)

The PEG tube lasts approximately 6 months after which time the tubing begins to wear and may cause leaking if it pulls away from the stomach

(Lim et al 2007)



References

- Abuksis G, Mor.M, Segal. N, Shemesh. I, Plout. S, Sulkes. J, Fraser. G.M, Niv. Y, Percutaneous endoscopic gastrostomy: high mortality rates in hospitalized patients. American J Gastroenterol. 2000 Jan;95(1):128-32.
- AMNCH Hospital Policy
- Dehn, R.W. and Asprey, D.P (2007) Essential Clinical Procedures. 2nd ed. Saunders Elsevier, Philadelphia
- Lim, E., Loke, Y.K., & Thompson, A., (2007) Medicine & Surgery an Integrated Textbook. London: Churchill Livingstone
- Pearce, C.B. and Duncan, H.D., Enteral feeding. Nasogastric, nasojejunal, percutaneous endoscopic gastrostomy, or jejunostomy: its indications and limitations. Postgrad Med J. 2002;78(918):198-204.
- St James Hospital 2005, Nursing Procedure for the Insertion and Placement of Nasogastric Tubes – Wide Bore and Fine Bore.
- Todd, W.T, Shaffer, R.W. & Setnik, G.S (2006) Nasogastric intubation; Videos in Clinical Medicine. The New England Journal of Medicine 345;17 e16 www.nejm.org (2nd Dec 2008)
- Williams. N.T, 2009, Medication Administration Through Enteral Feeding Tubes. American Journal of Health-System Pharmacists 65 (24):2347-2357
- Zalar. A.E., Guedon, C. & Piskorz. E.L. Percutaneous endoscopic gastrostomy in patients with neurological diseases. Results of a prospective multicenter and international study. 2004;34(3):127-32

