Chapter 25

Motor System II
Corticofugal Systems and the
Control of Movement

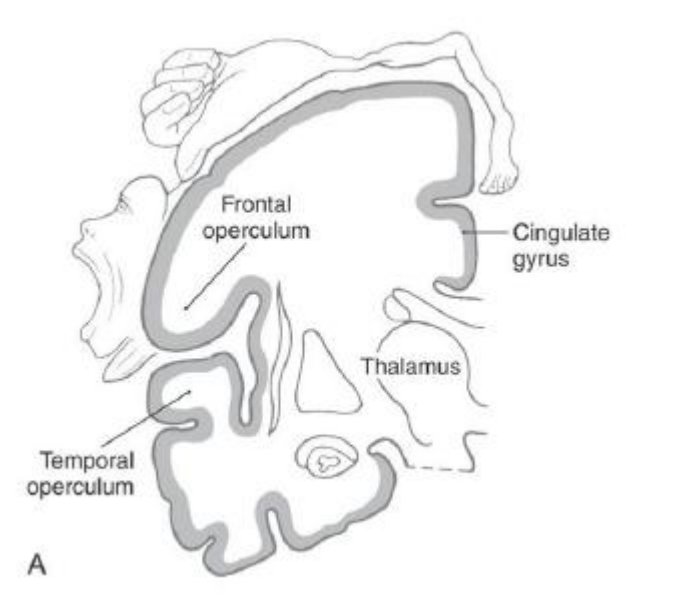

Corticospinal Fibers:

-Somatotopy,
-Laterality,
-Trajectory

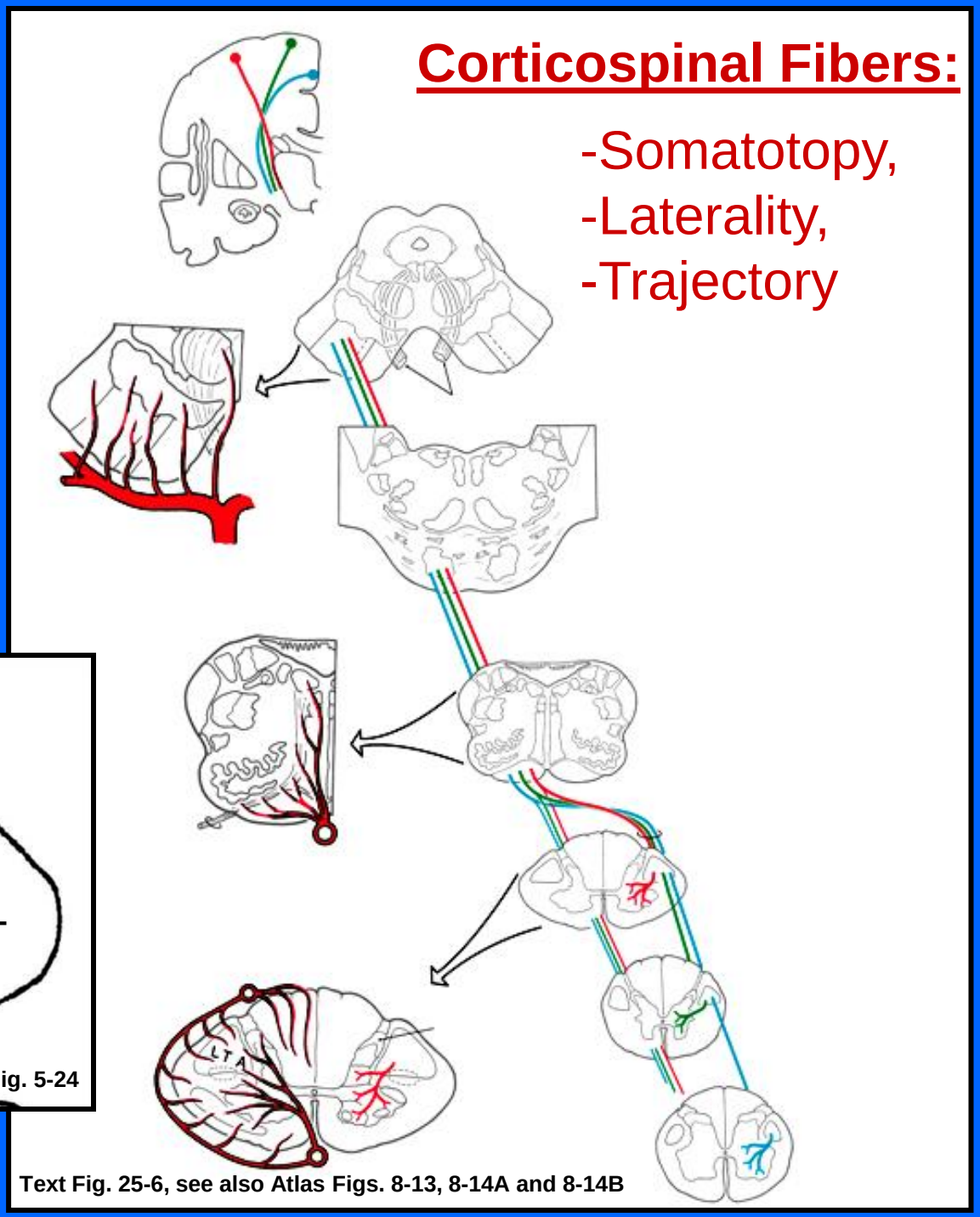

Text Fig. 25-6, see also Atlas Figs. 8-13, 8-14A and 8-14B

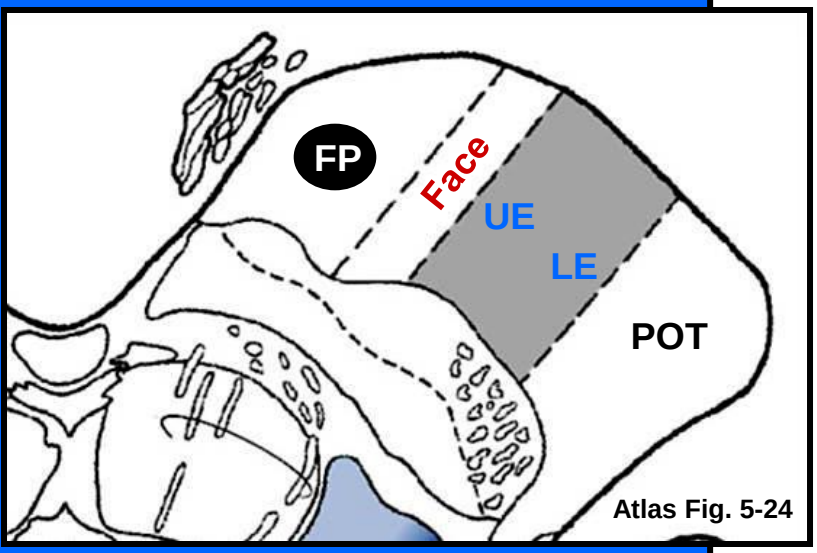

Atlas Fig. 5-24

Expanding Extramedullary Lesion

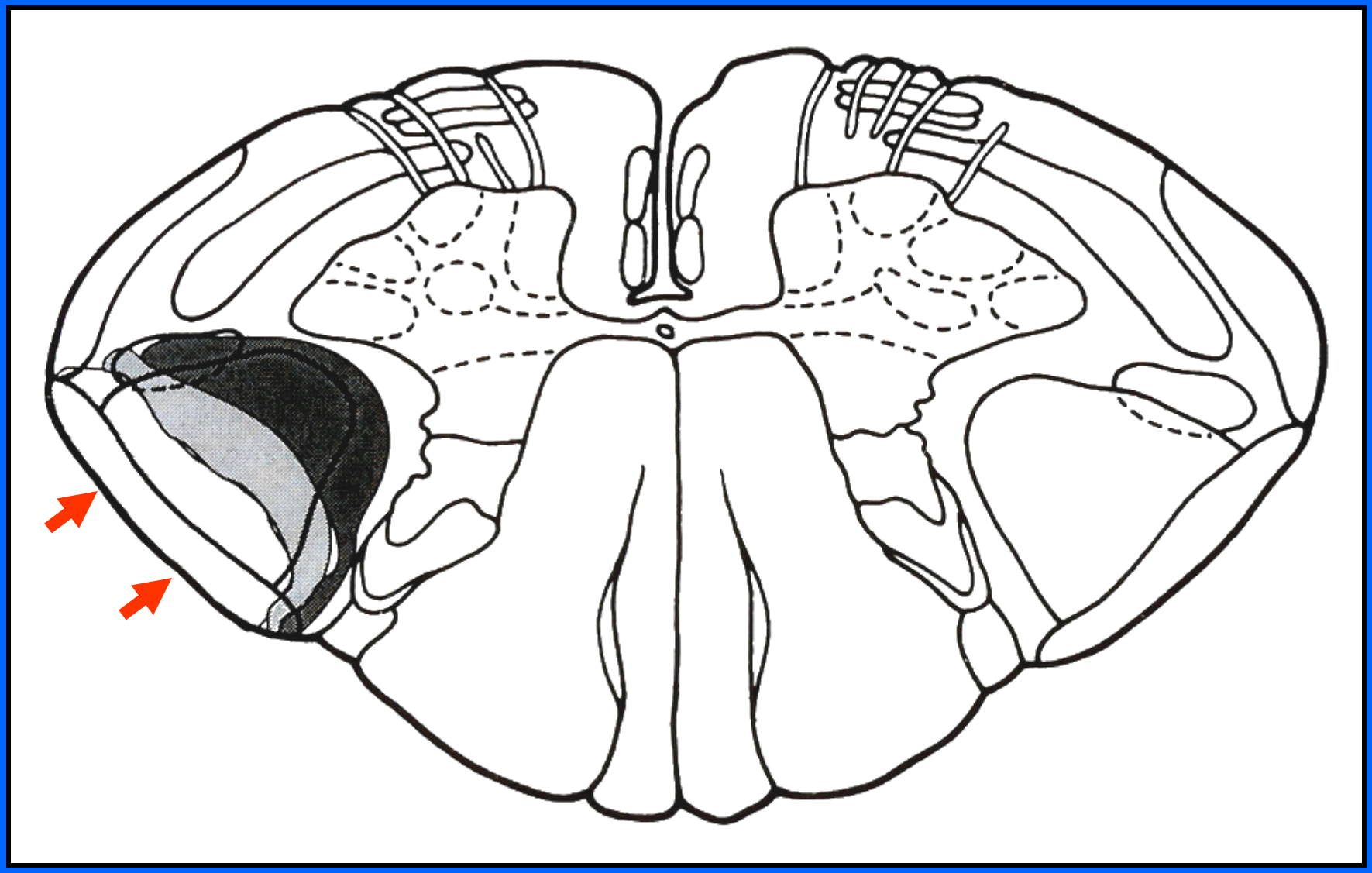

The Brown-Sequard Syndrome

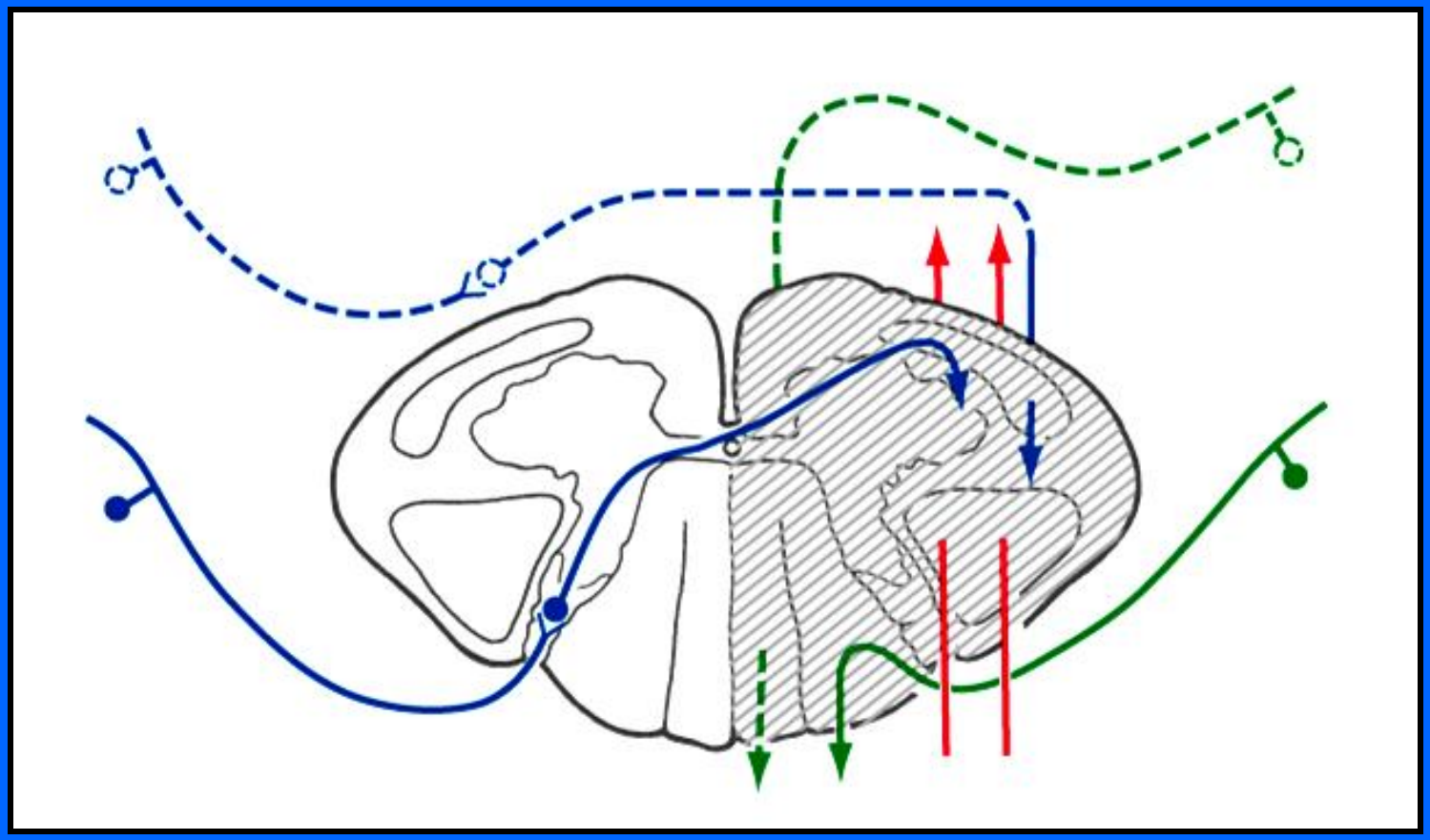

Decorticate and Decerebrate Rigidity

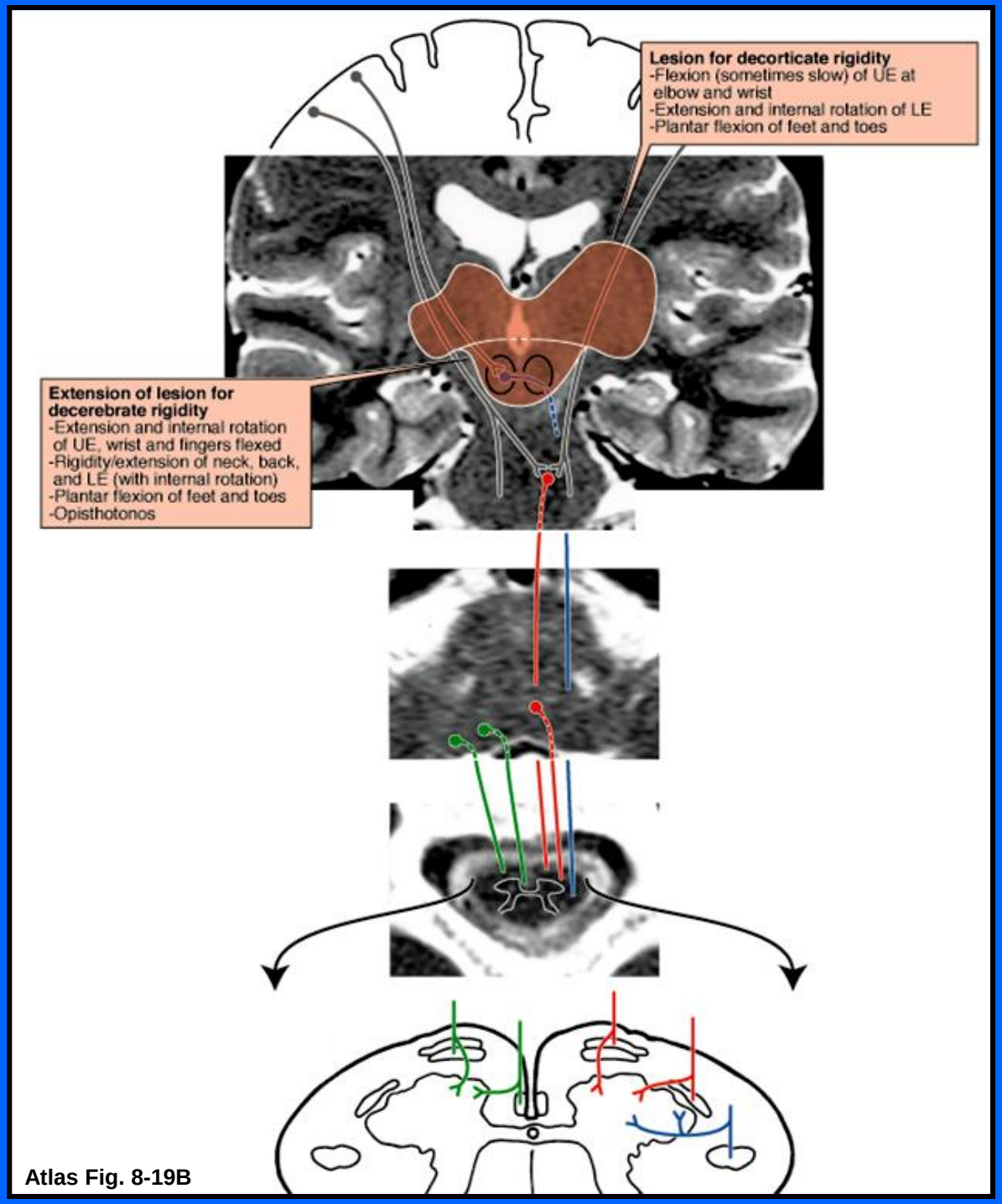

Atlas Fig. 8-19B

Decorticate

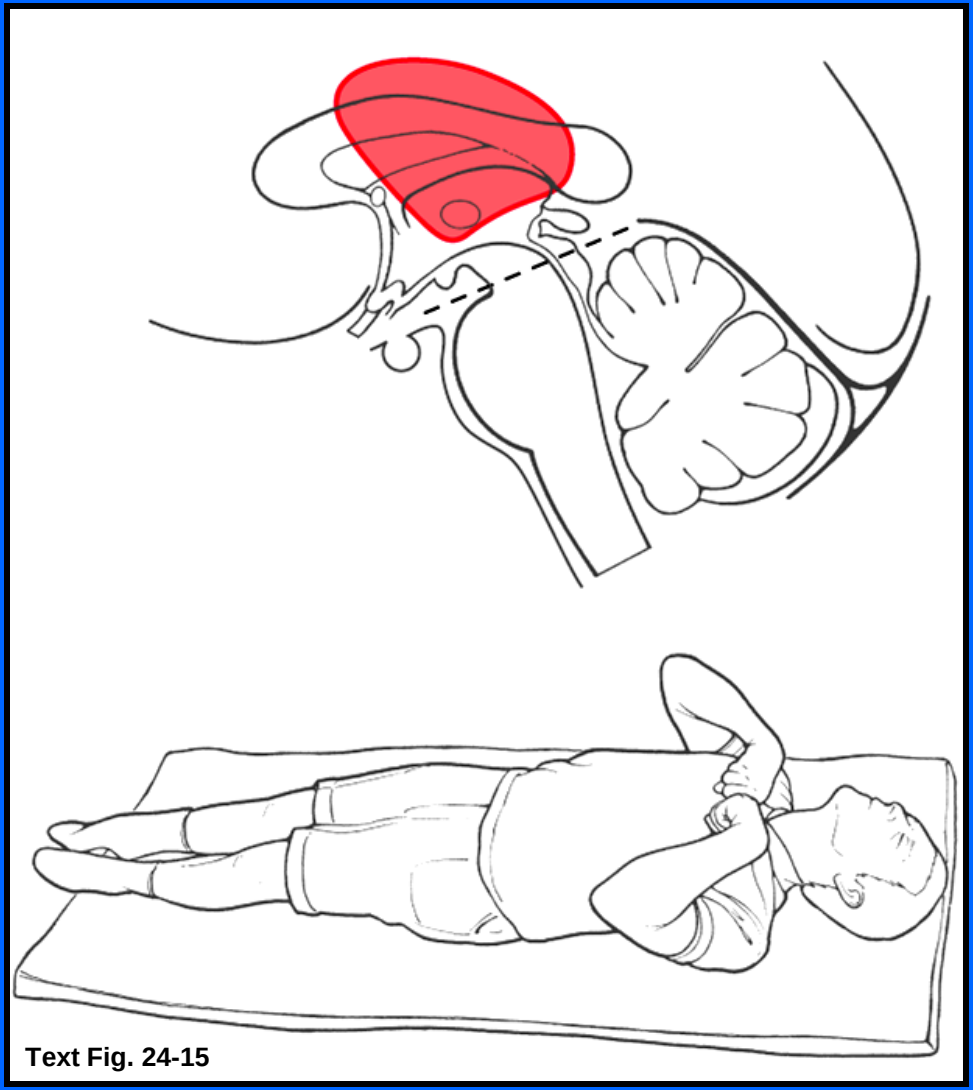

Decerebrate

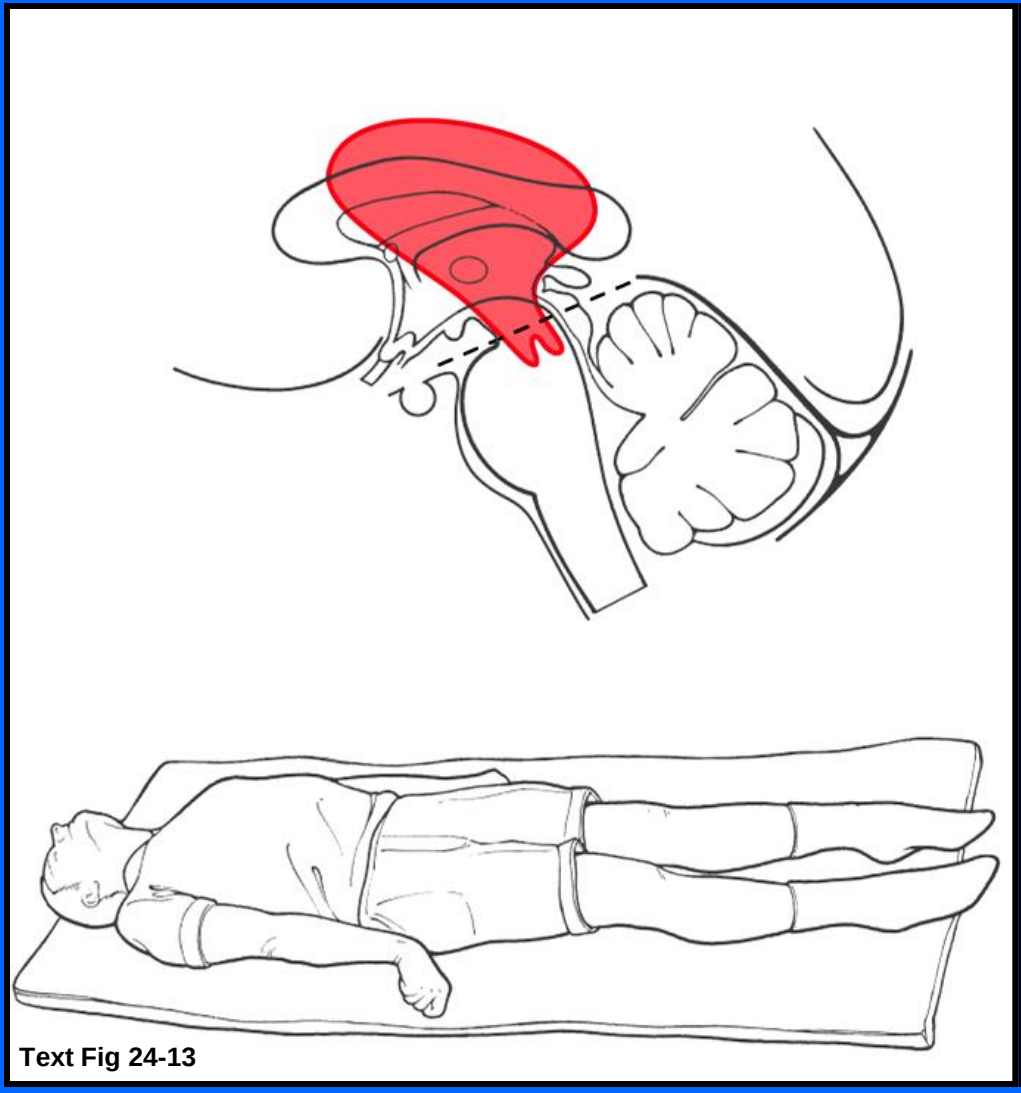

The Motor Cortex

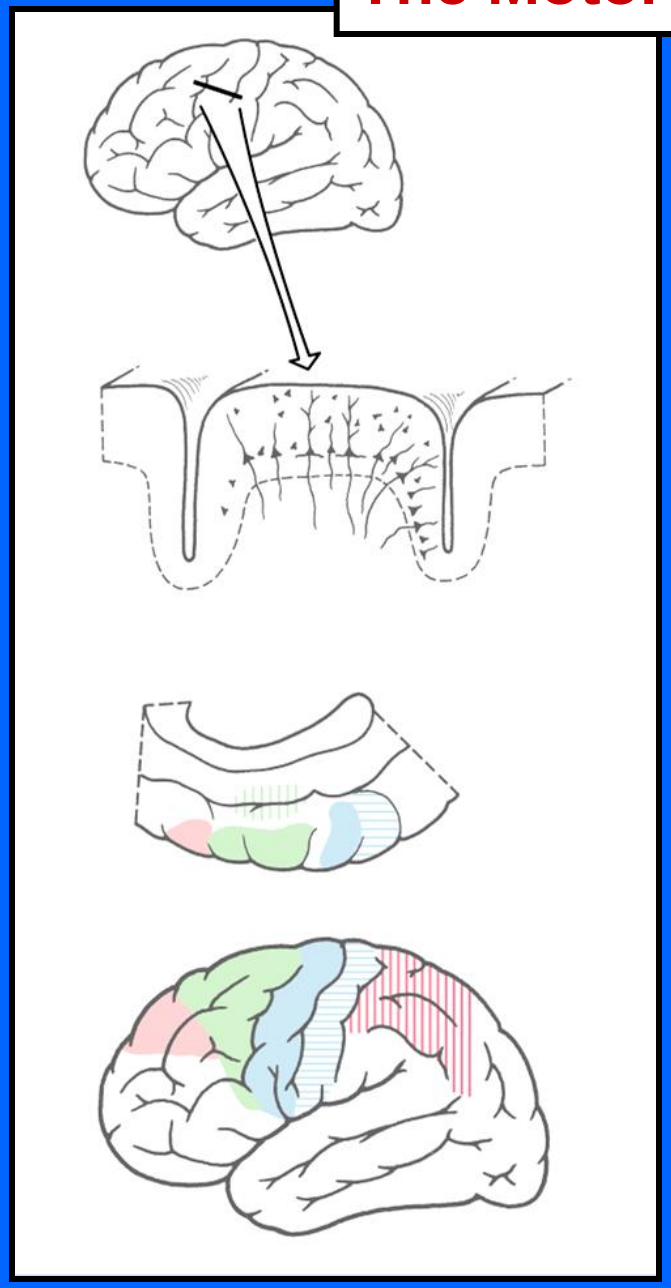

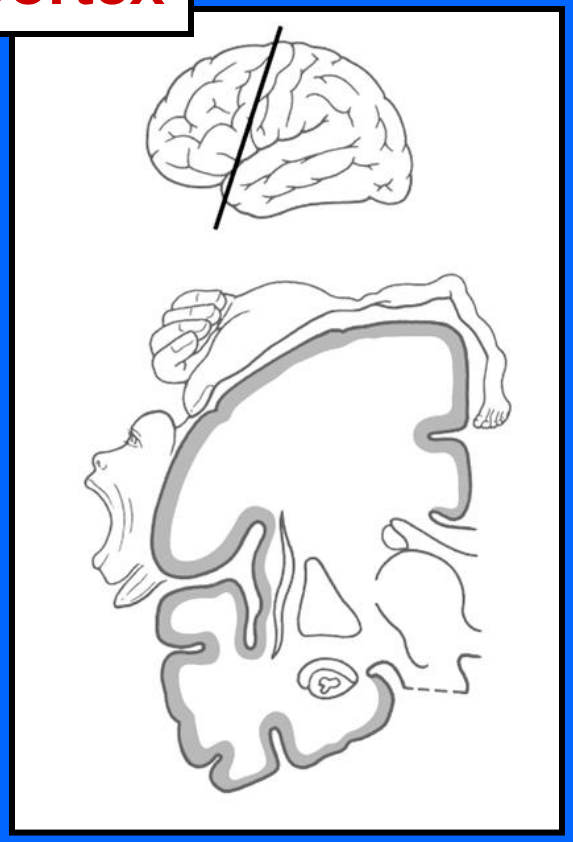

The Primary Somatomotor Cortex

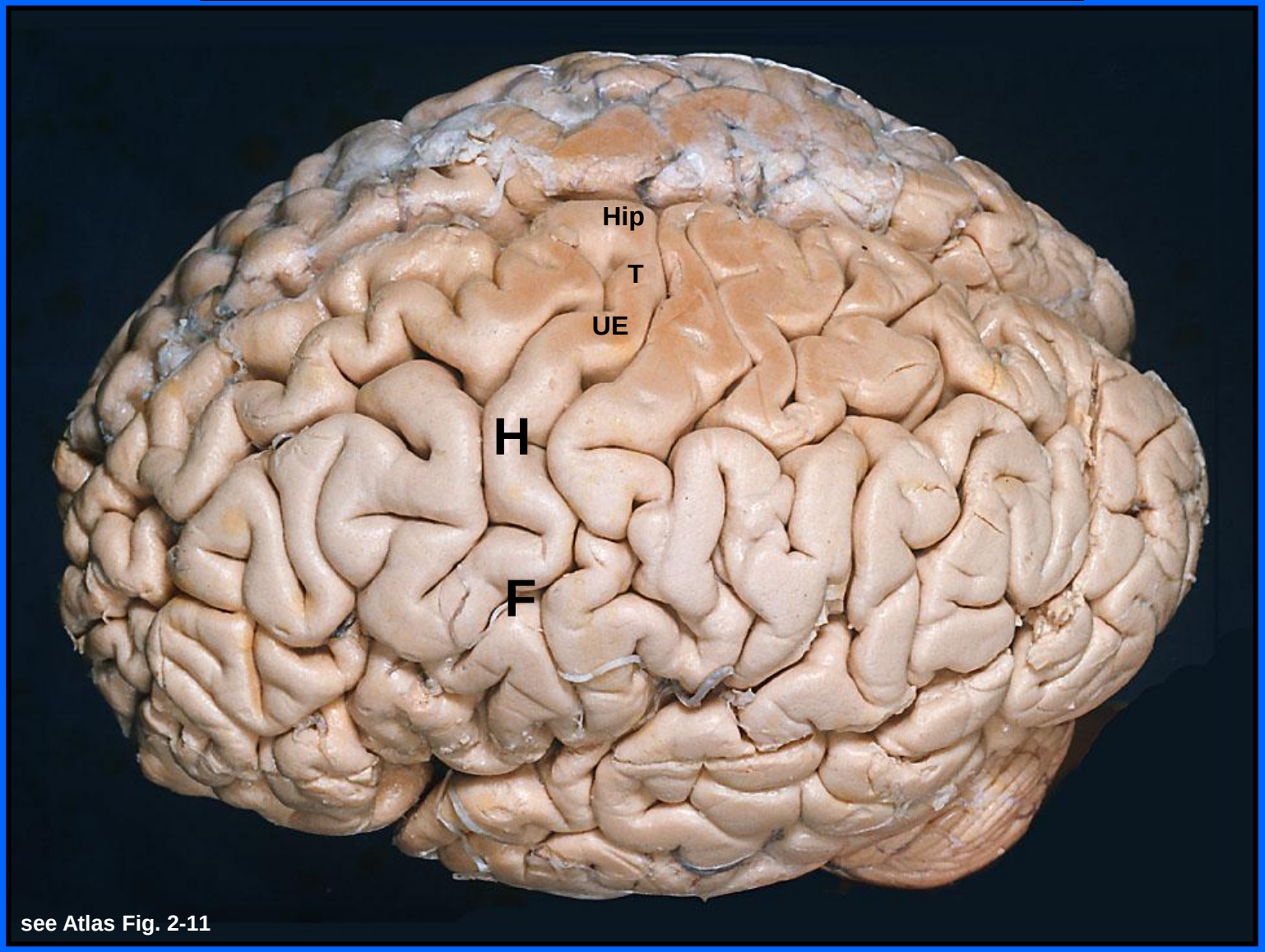

see Atlas Fig. 2-11

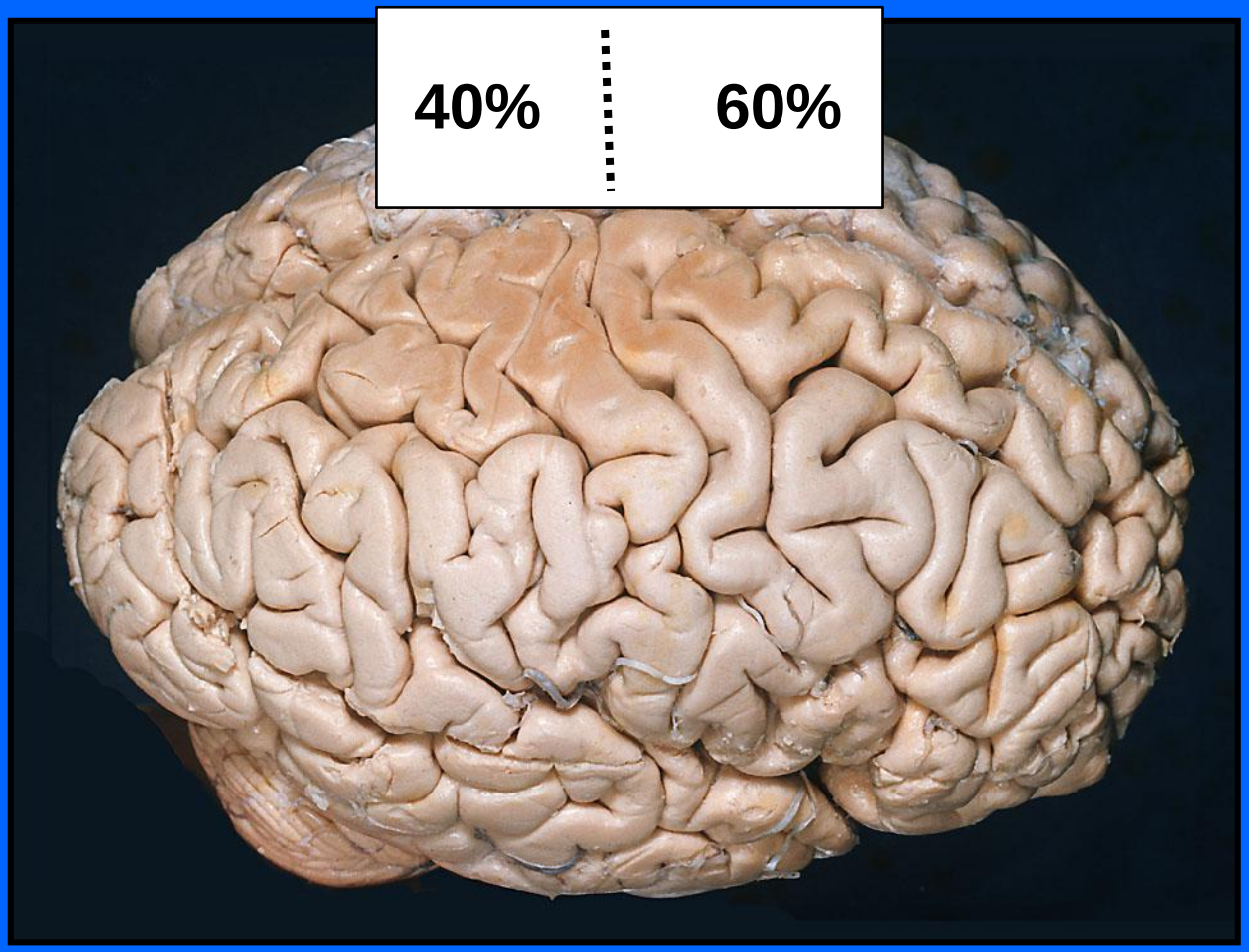
40%
60%

Motor areas in the cerebral cortex

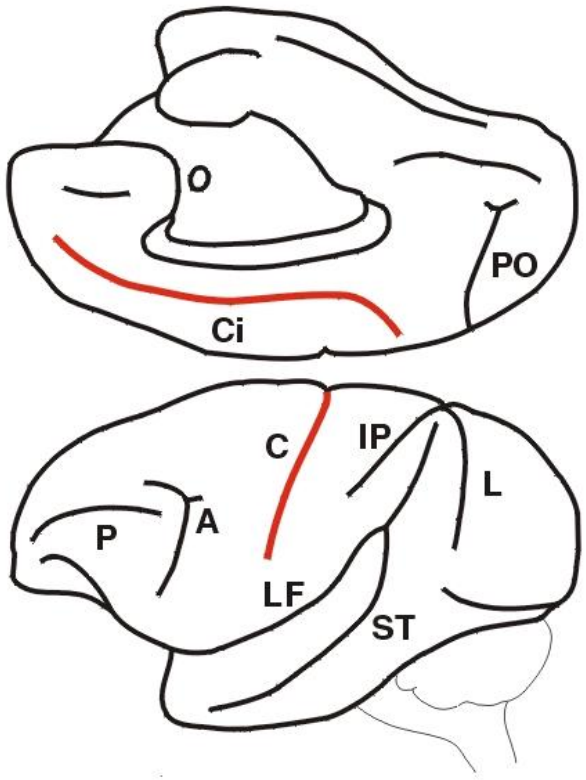

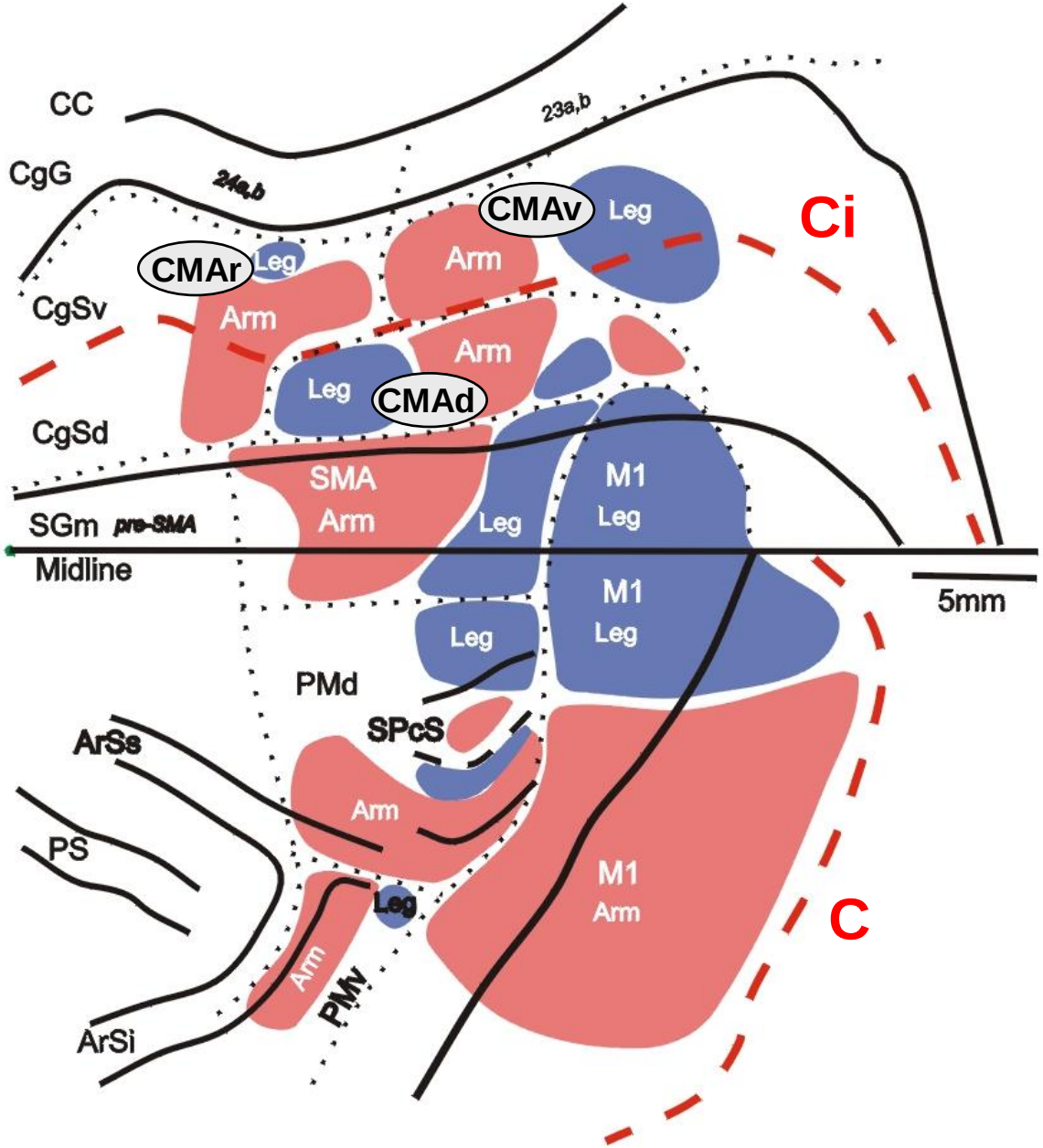

adapted from Strick, PL and Dum, RP, *The Corticospinal System*, in Handbook of Physiology, Oxford, 1996.

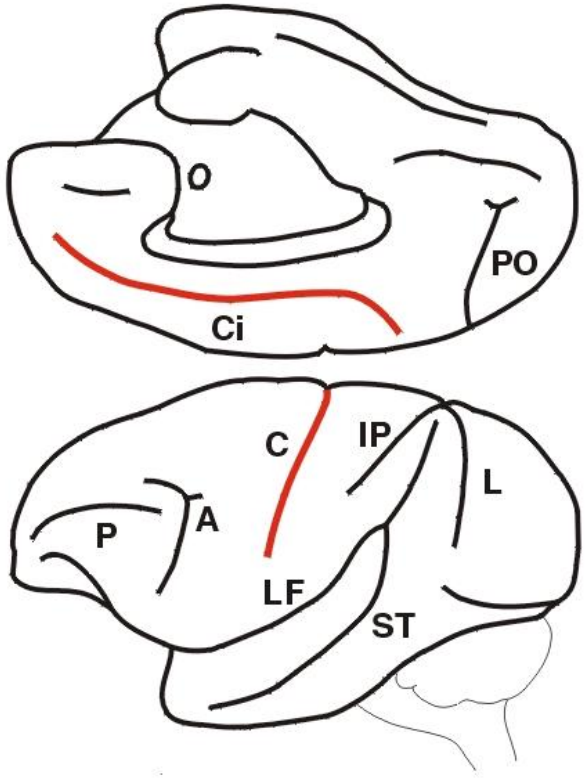

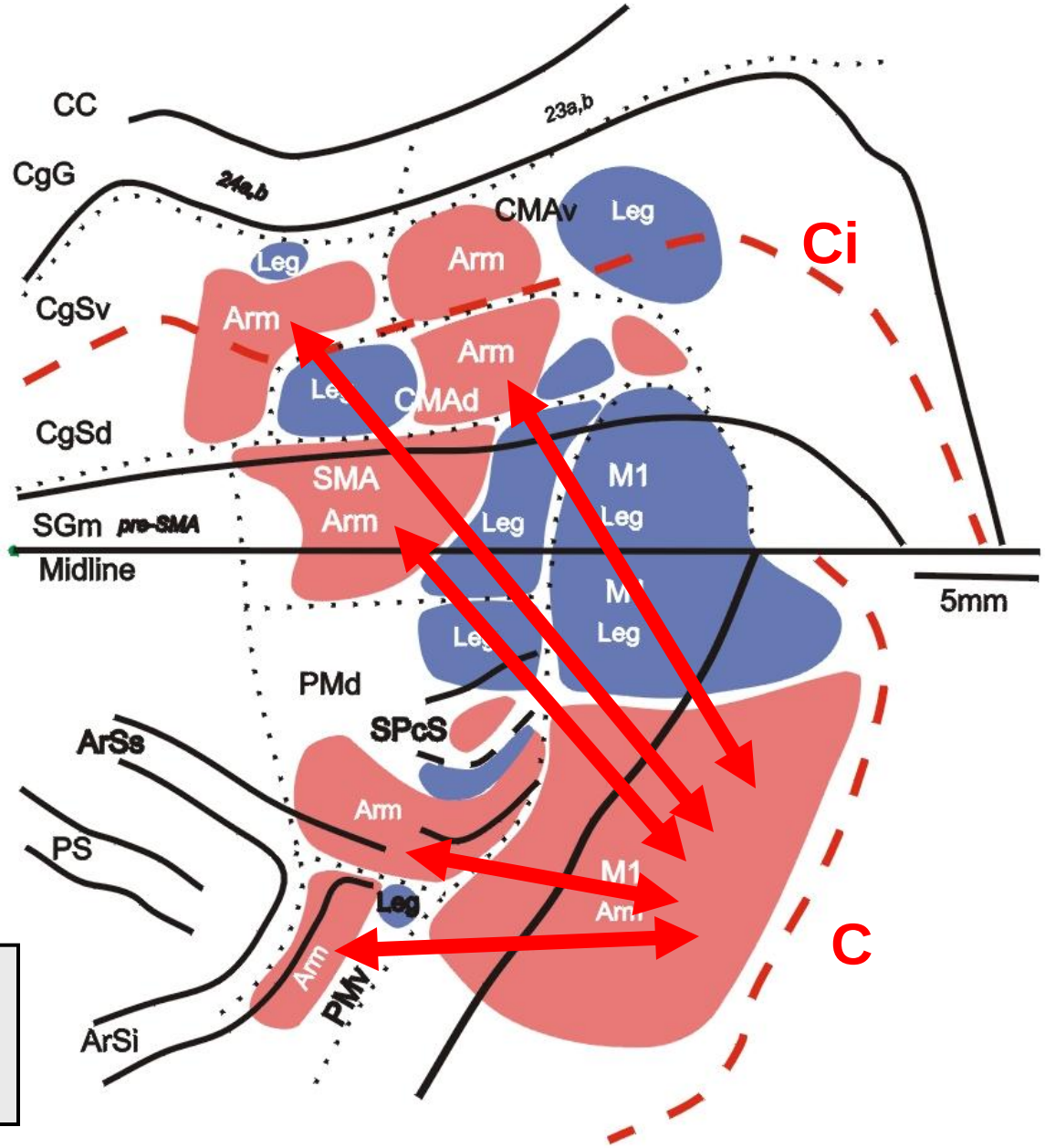

The several cortical motor areas are connected with each other.

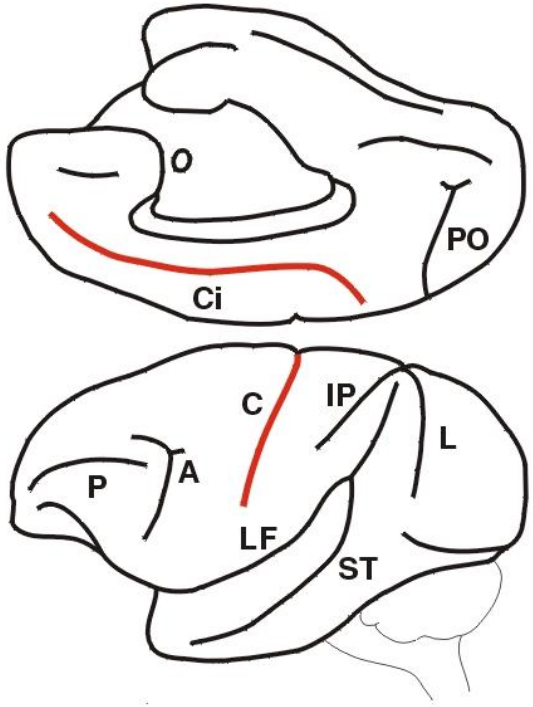

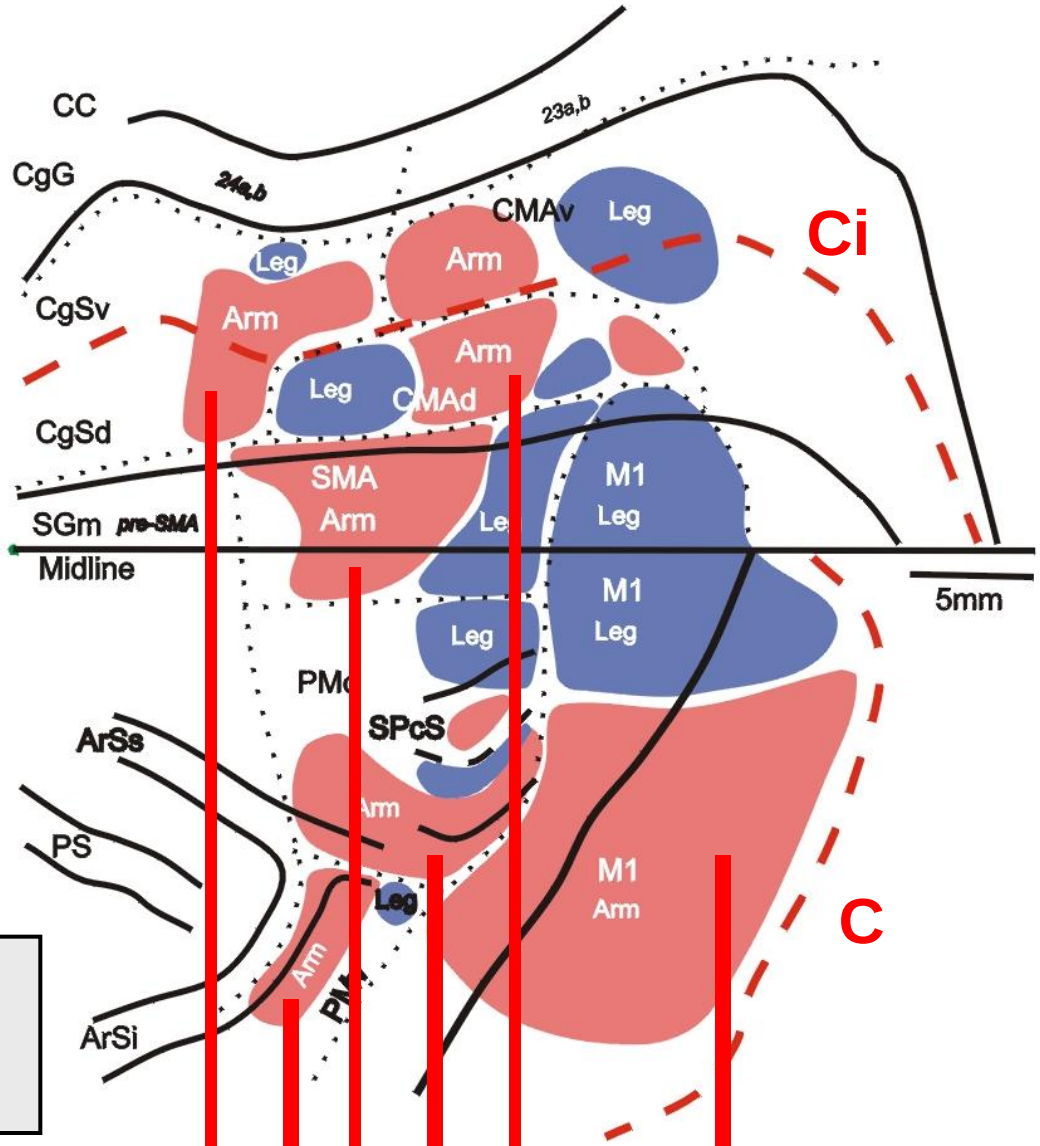

Each cortical motor area projects to spinal cord (anterior horn or interneurons)

to cervical spinal cord

Supplementary Motor Area

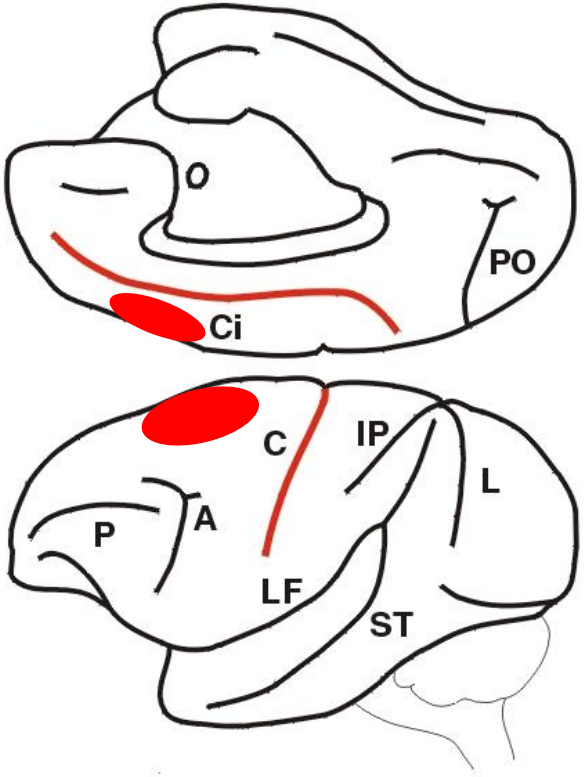

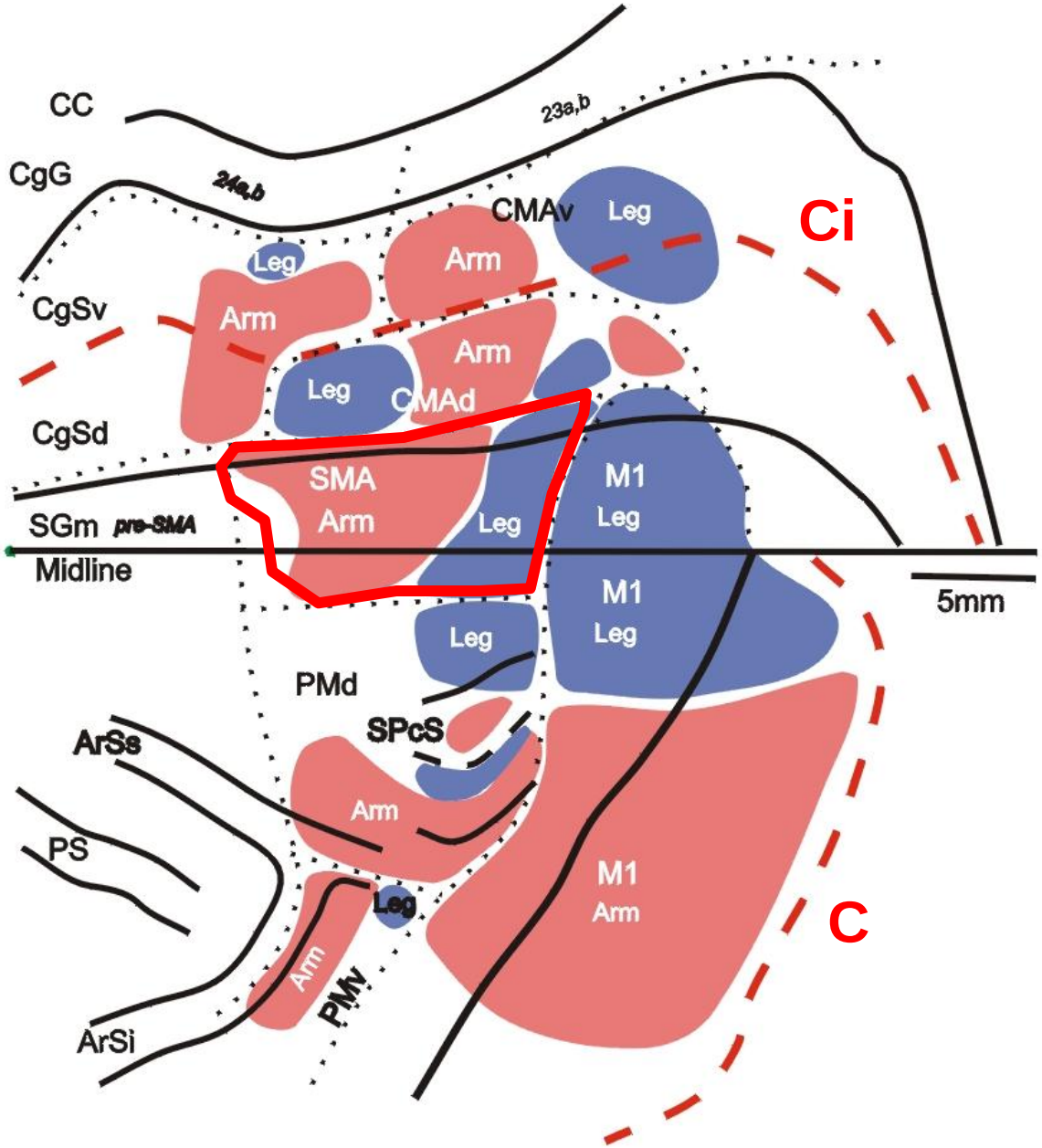

"Preparation for movement, Coordination of two hands"

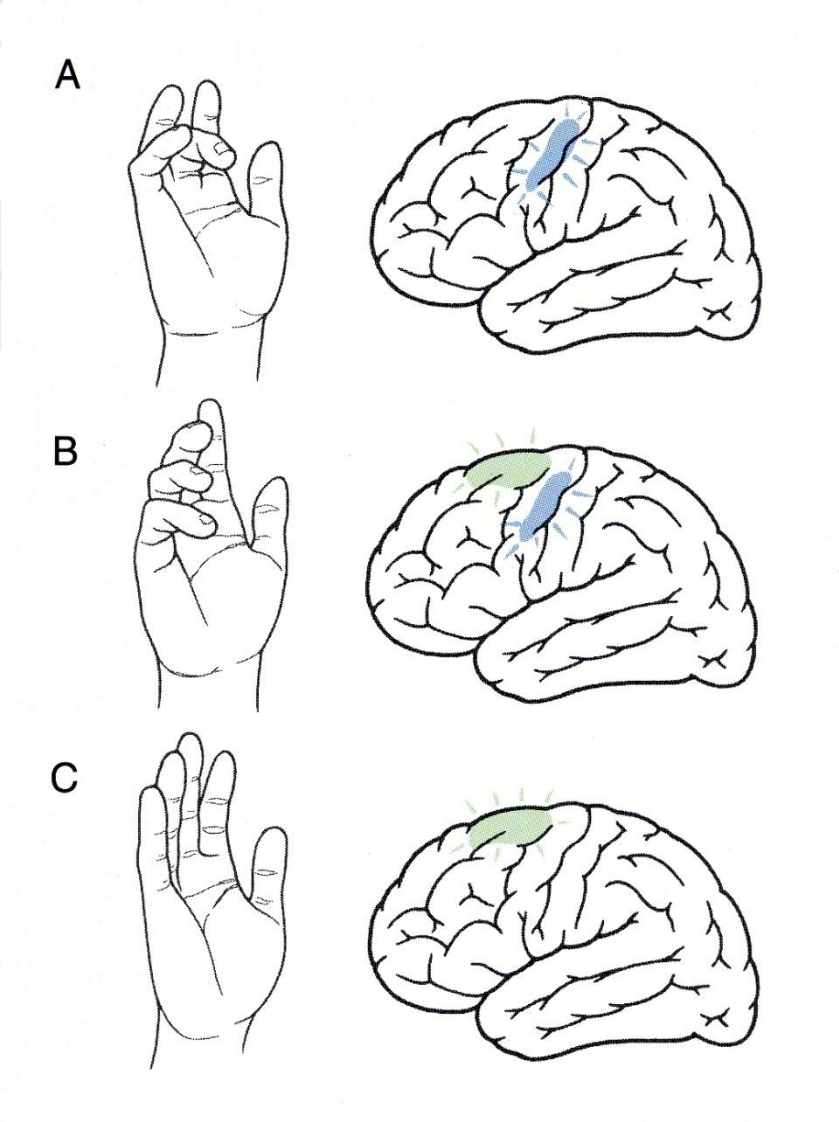

Move one finger repetitively

Execute complex learned pattern of finger movements

Imagine **complex learned pattern of finger movements**

SUPPLEMENTARY MOTOR AREA

Haines Figure 25-15

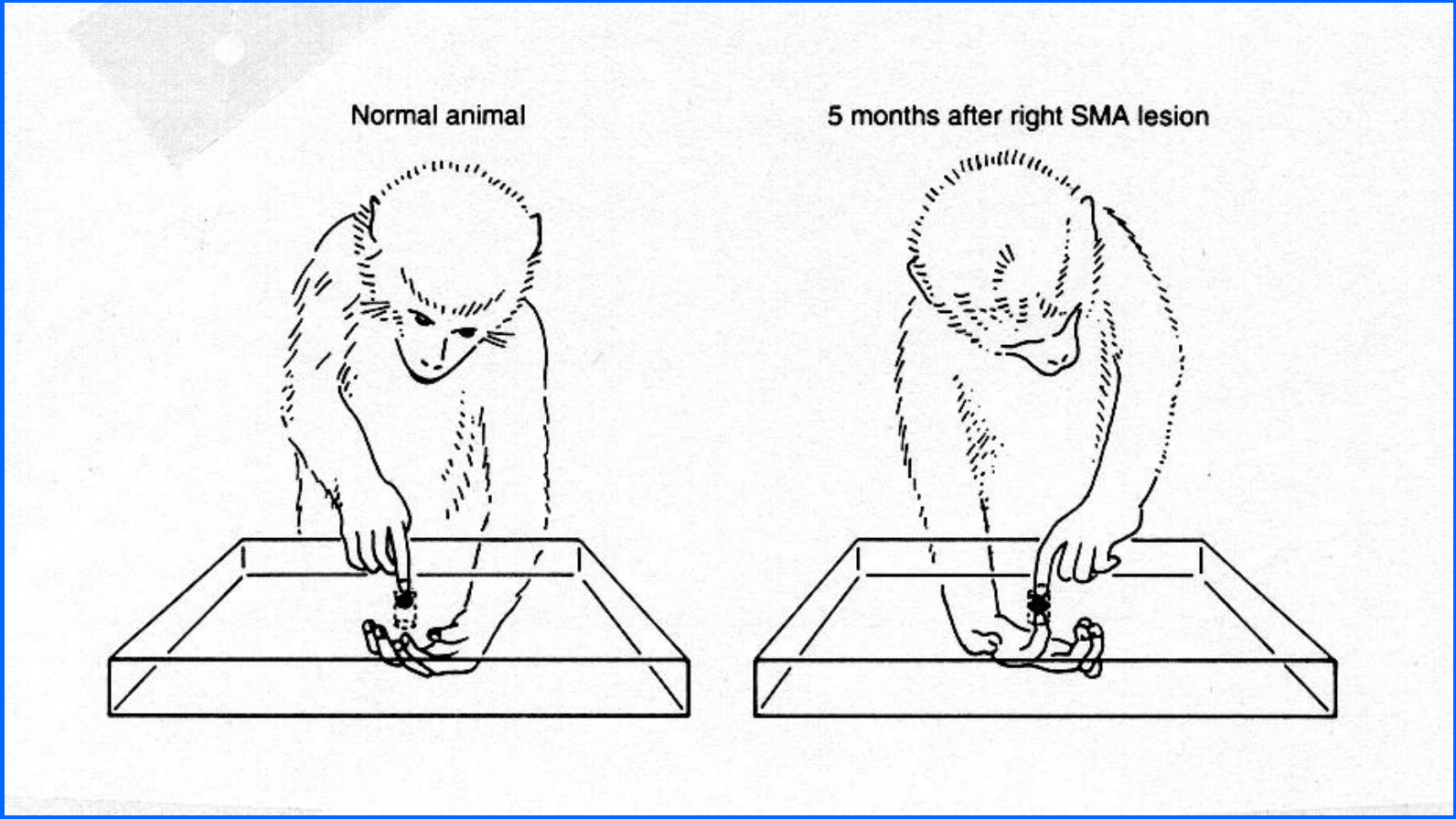

Effect of damage in the *Supplementary Motor Area*: difficulty in using two hands together

Dorsal Premotor Cortex

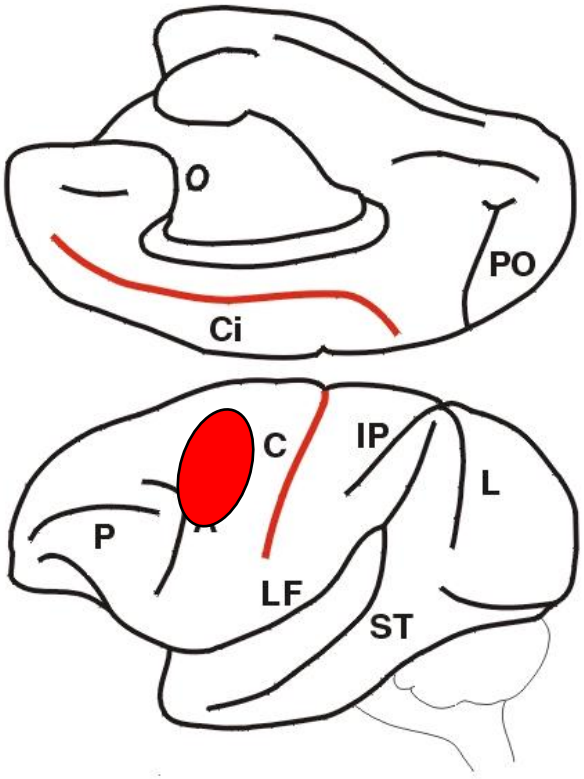

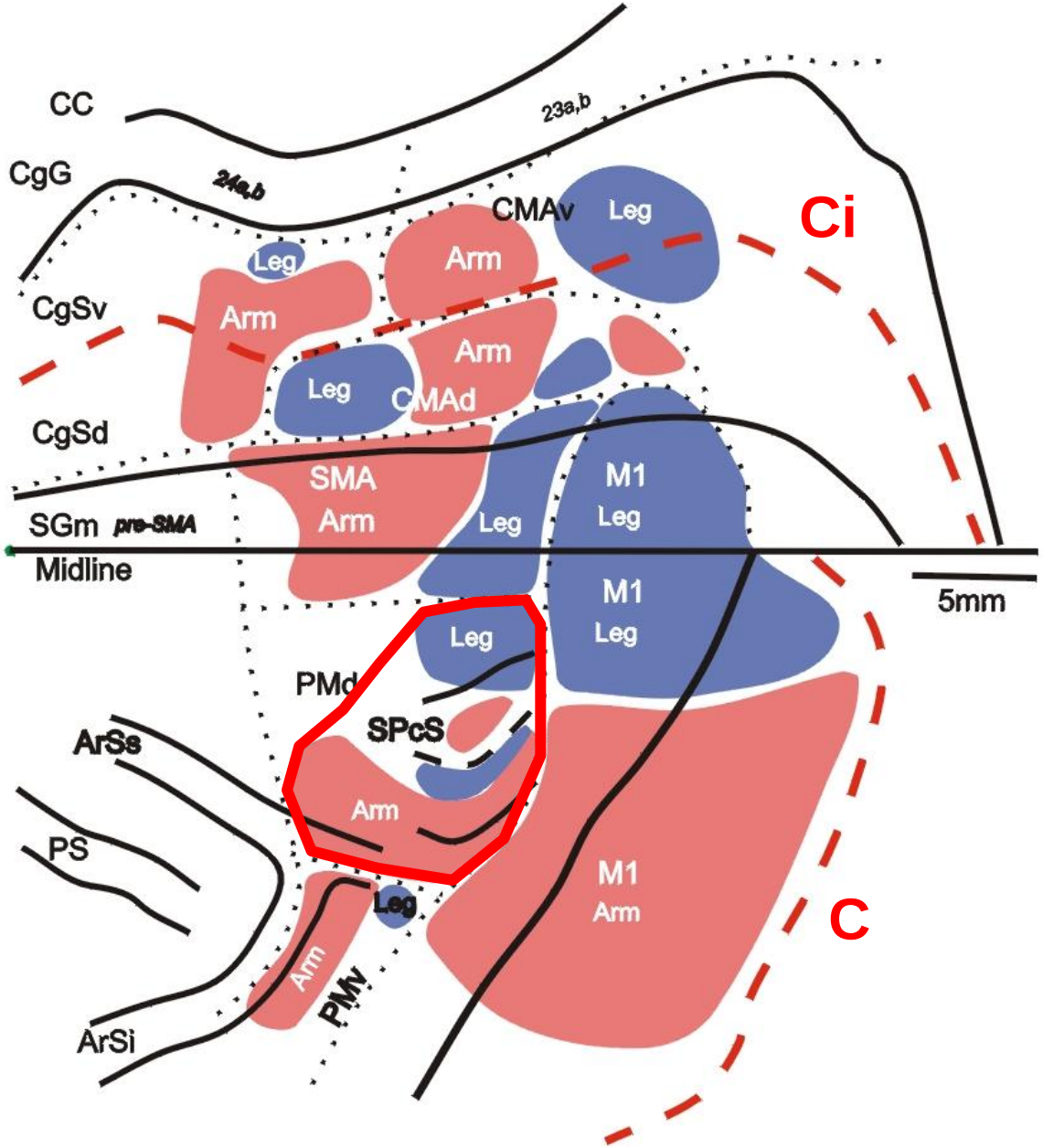

**"Complex movements,
Preparation for movement"**

Ventral Premotor Cortex

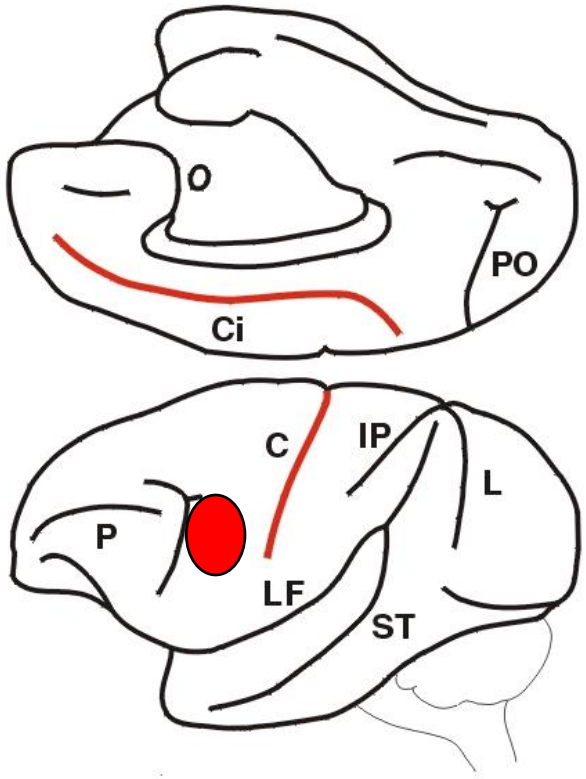

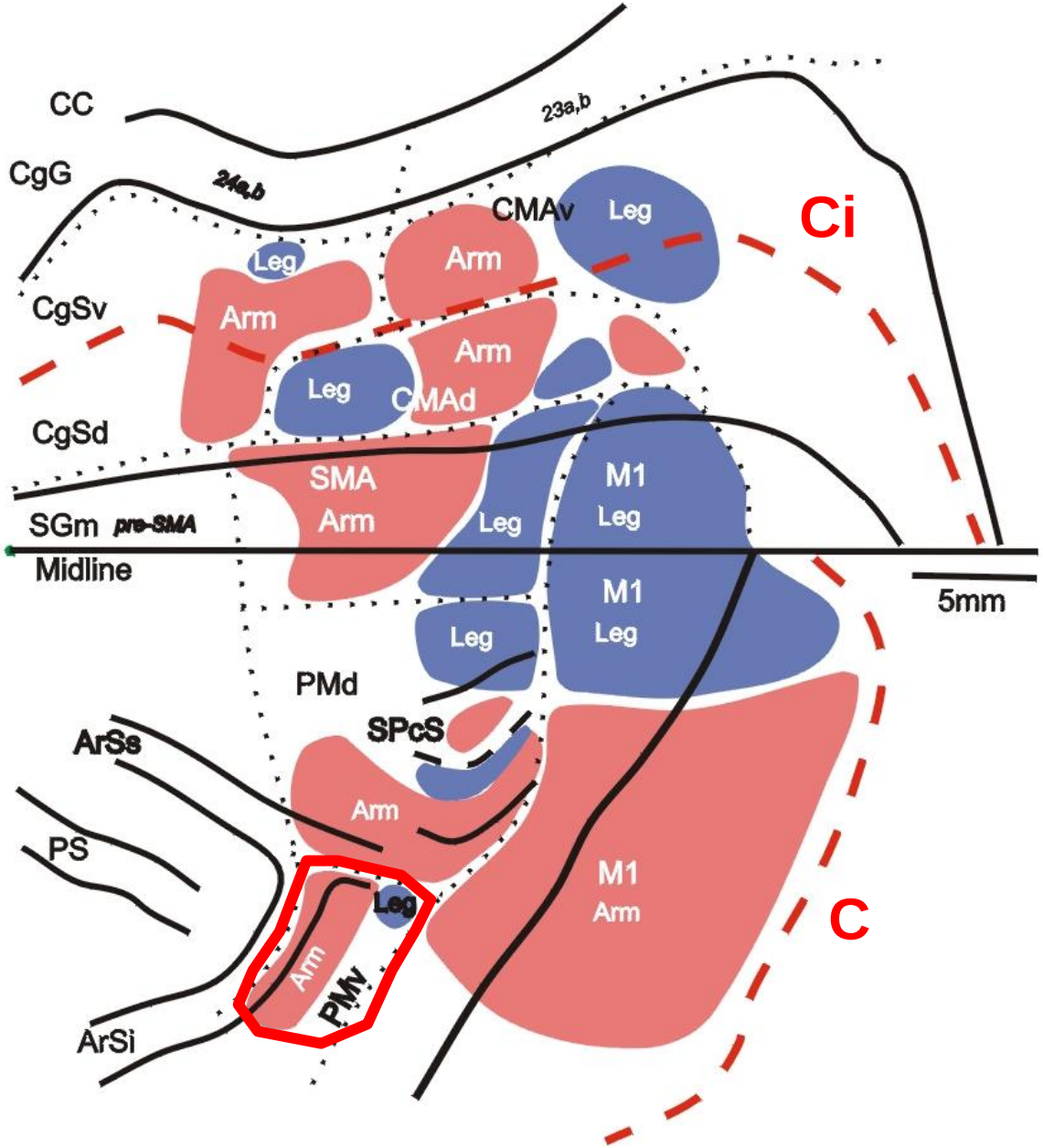

"Hand-eye coordination"

Ventral Premotor Cortex

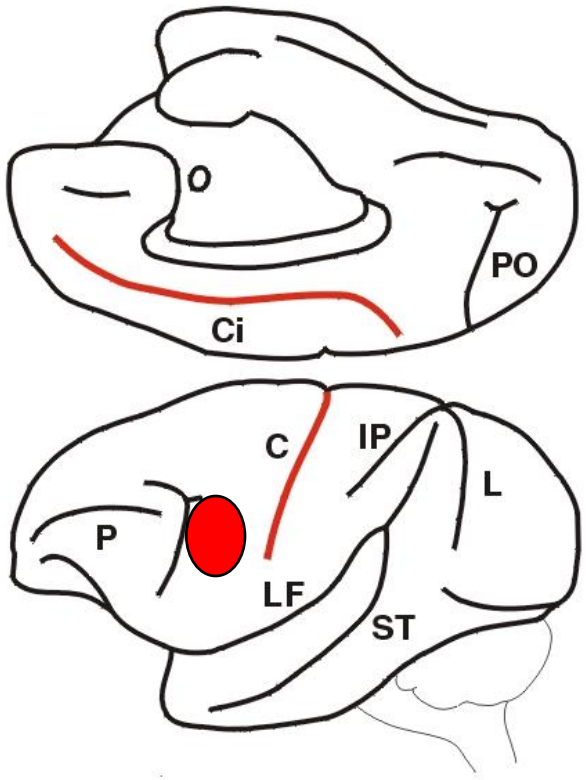

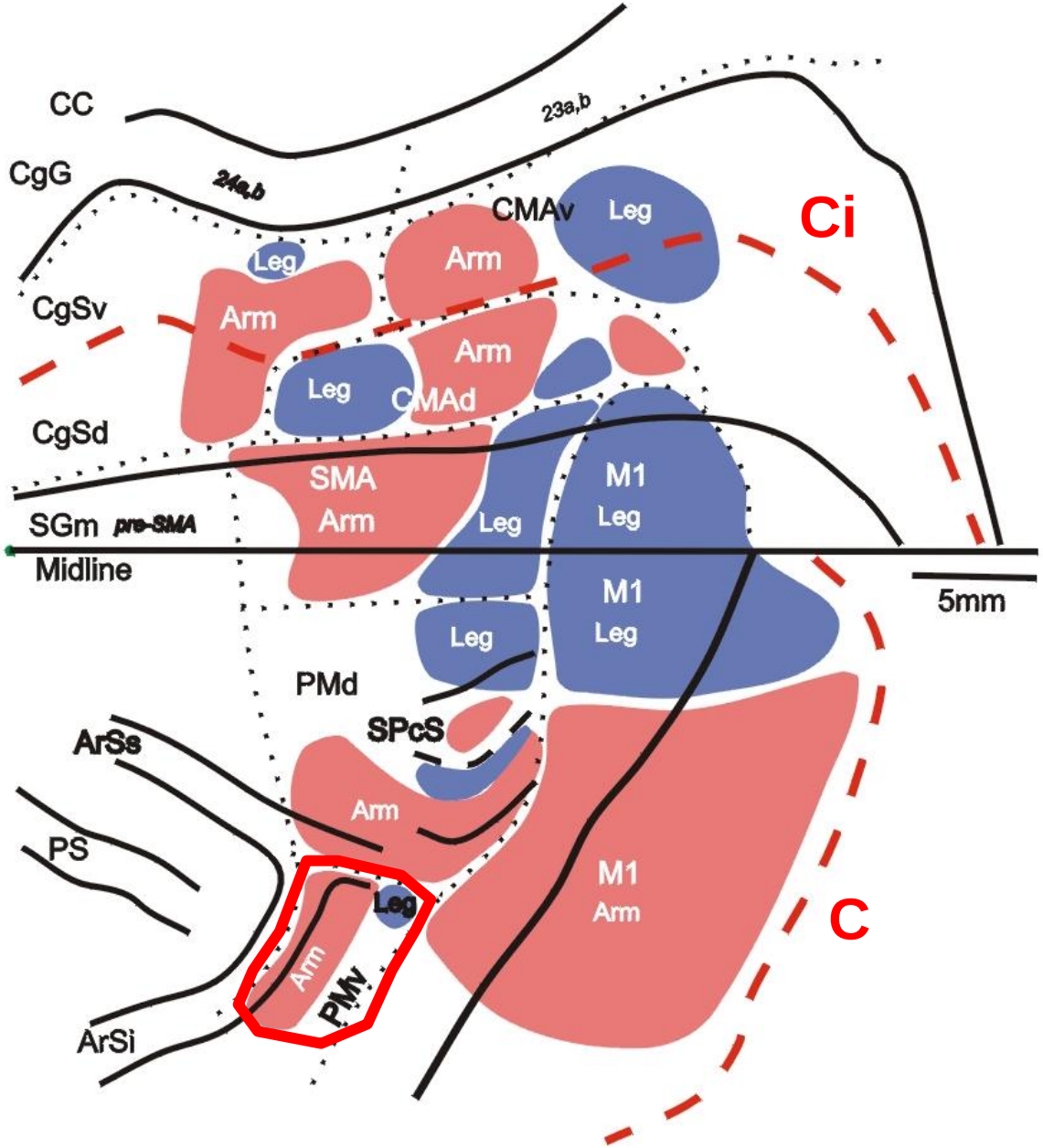

"Hand-eye coordination"

+

mirror motor neurons

WHOLE-BODY EXOSKELETON



Design: Gordon Cheng (Technical University of Munich)


MIGUEL
NICOLELIS
Inspira.SP


BRAIN-MACHINE
INTERFACES
TO
RESTORE MOBILITY
Miguel Nicolelis
Center for Neuroengineering, Duke University
Edmond and Lily Safra International Institut
of Neuroscience of Natal, Brazil

Posterior Parietal Cortex (5+7)
&
Cingulate Motor Cortex

Posterior Parietal Cortex (5+7)
&
Cingulate Motor Cortex

Vs

Limbic
Prefrontal (9 + 46)
&
Posterior Parietal Cortex (5+7)

3. pathways from the cerebral cortex
to the spinal cord

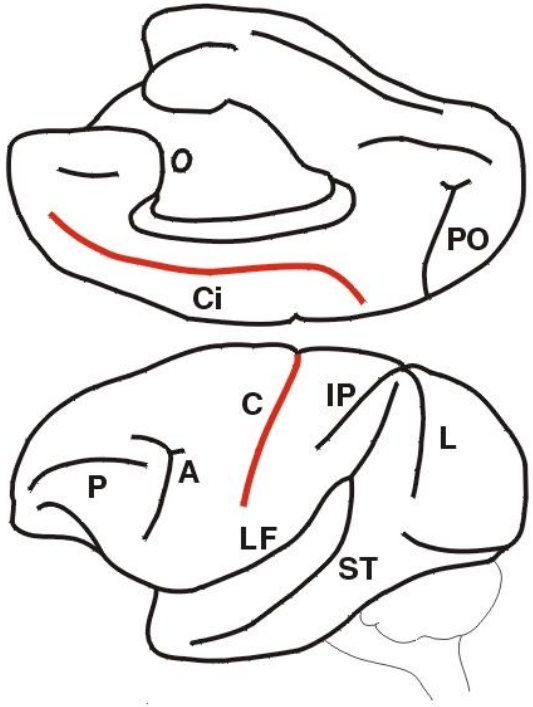

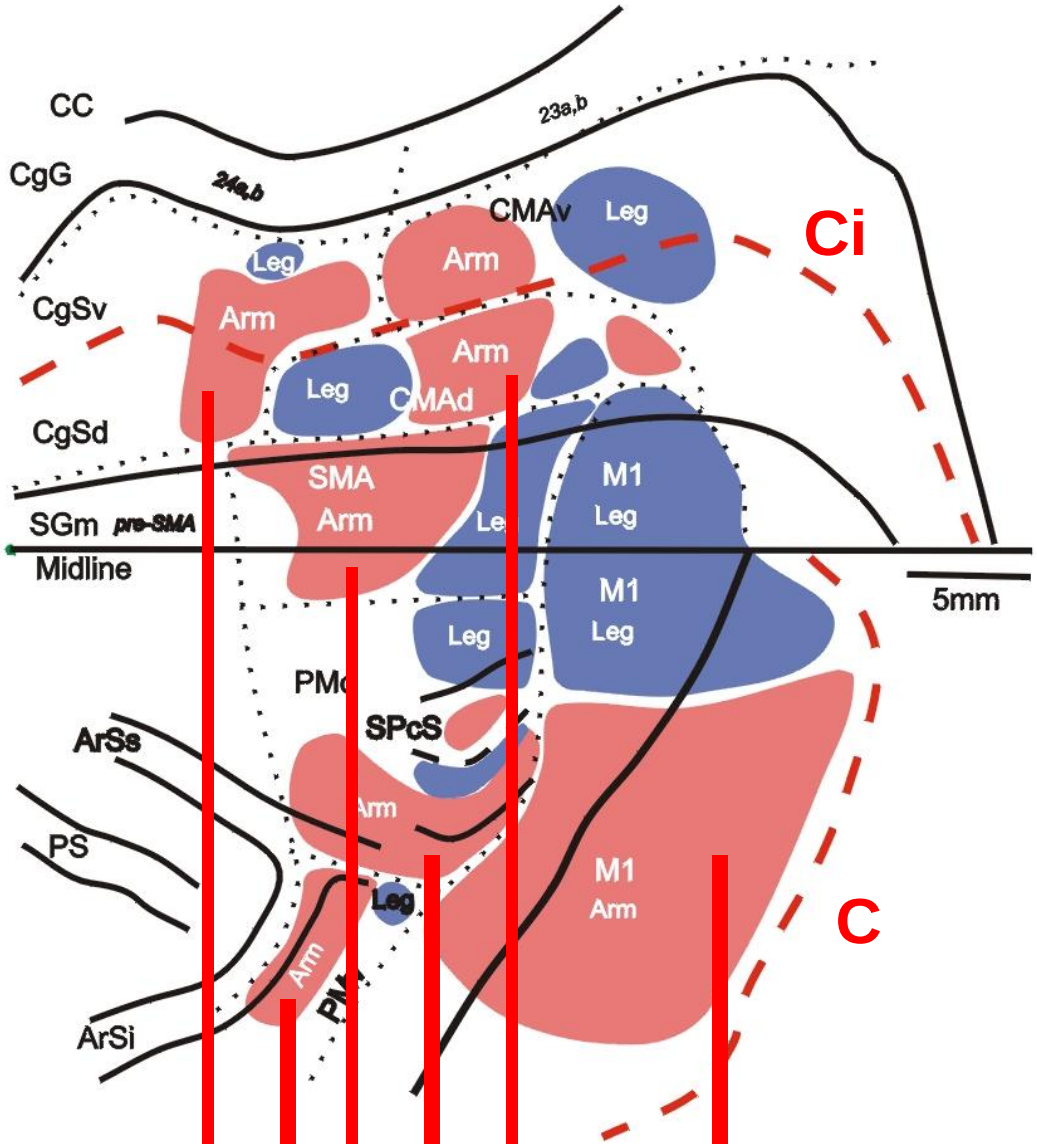

to cervical
spinal cord

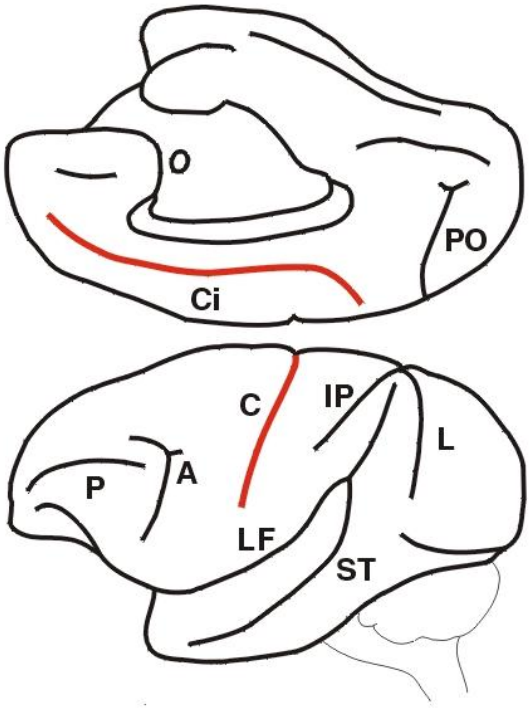

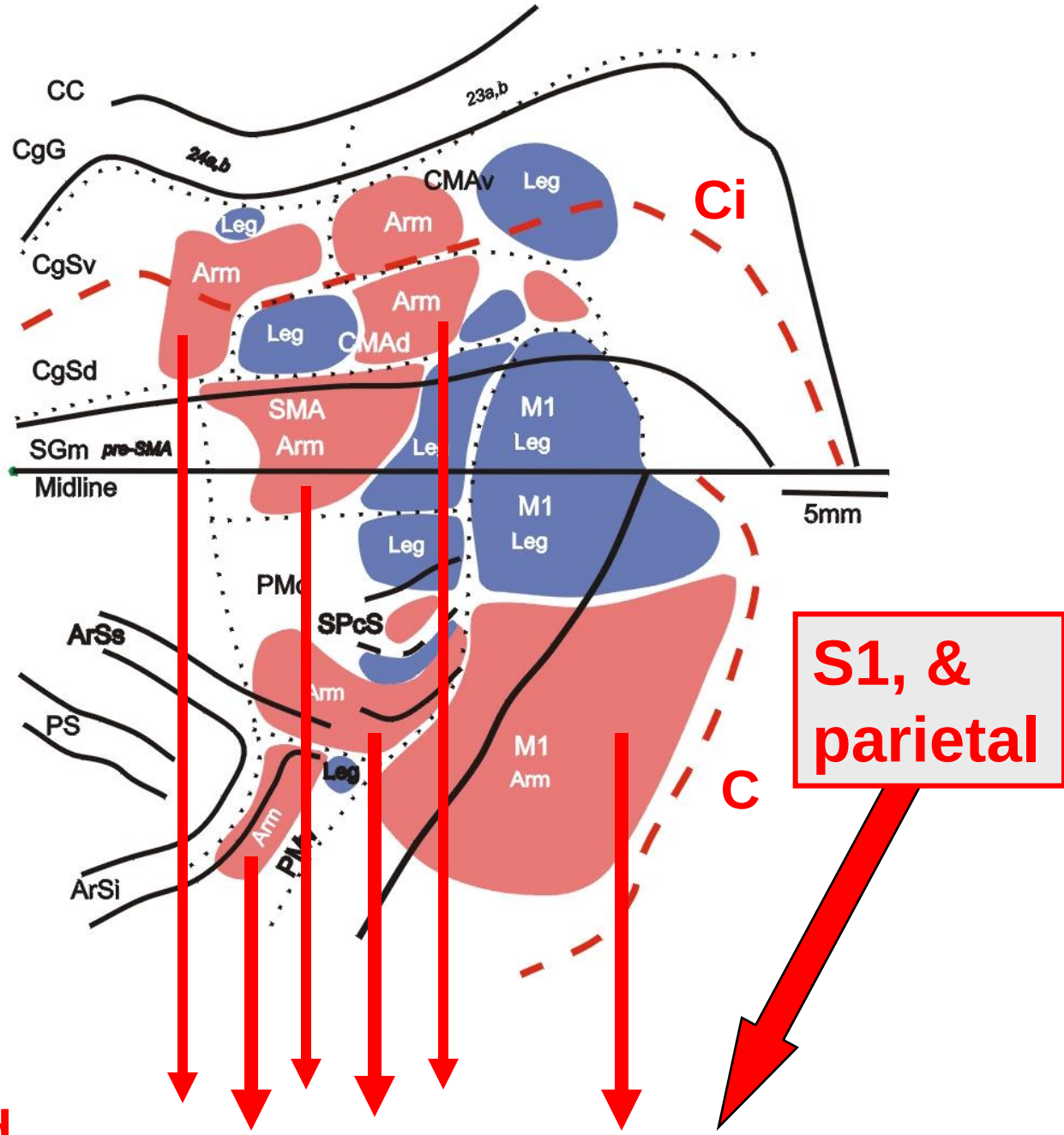

S1, & parietal

to cervical spinal cord

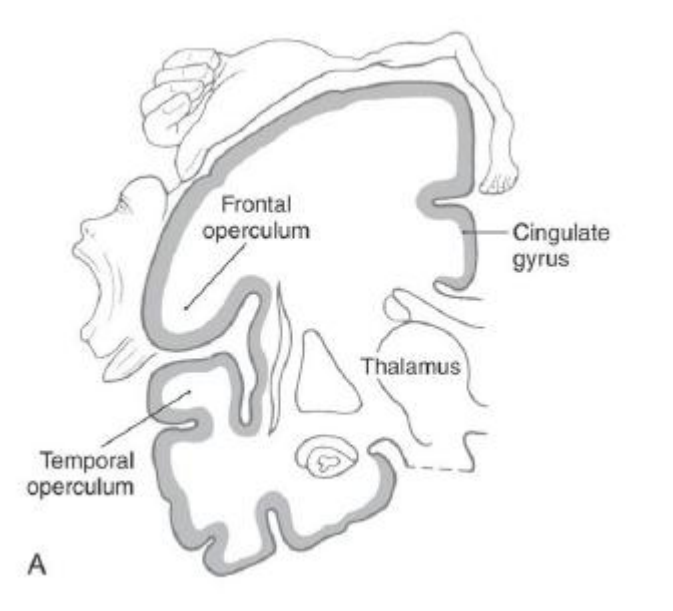

Corticospinal Fibers:

-Somatotopy,
-Laterality,
-Trajectory

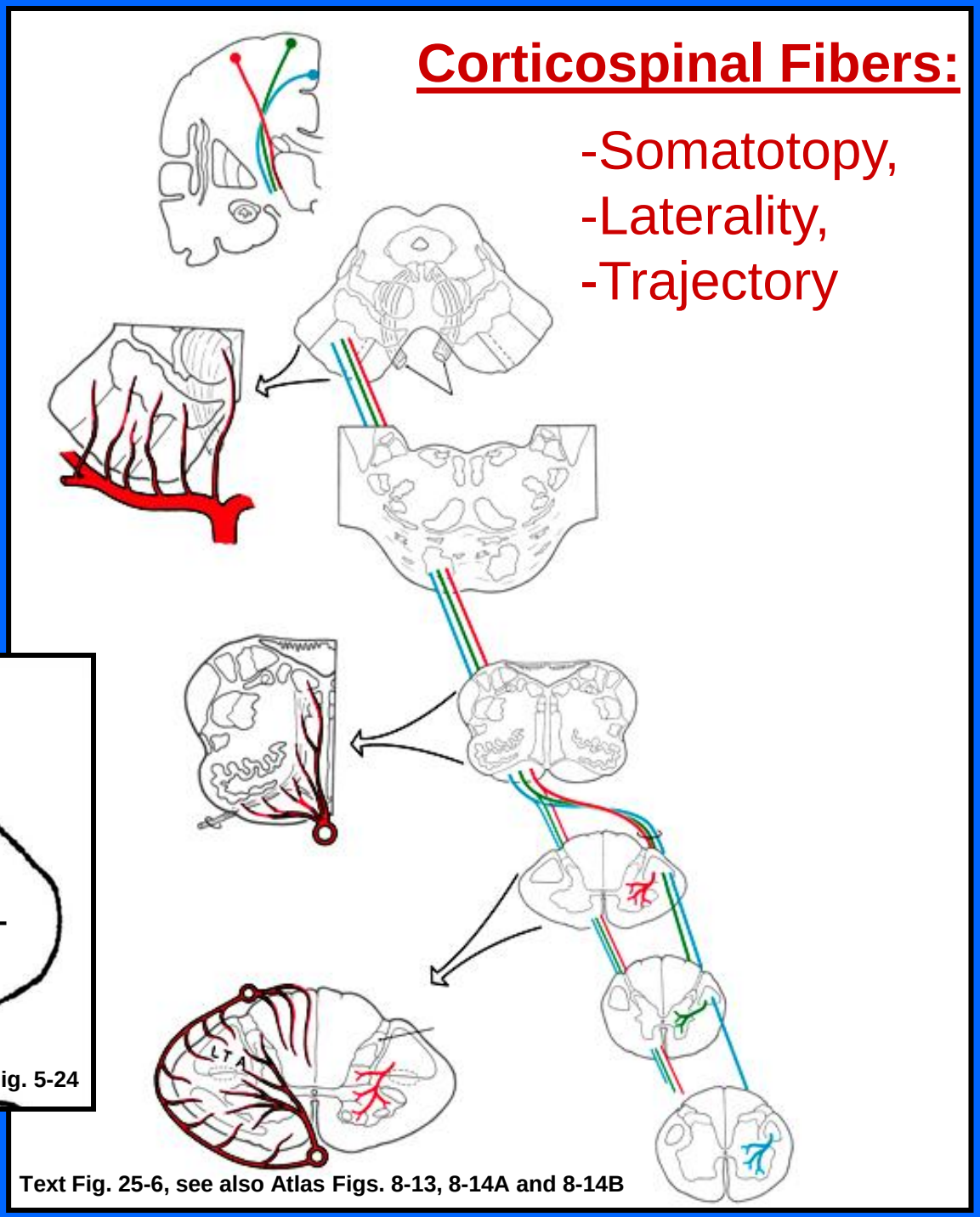

Text Fig. 25-6, see also Atlas Figs. 8-13, 8-14A and 8-14B

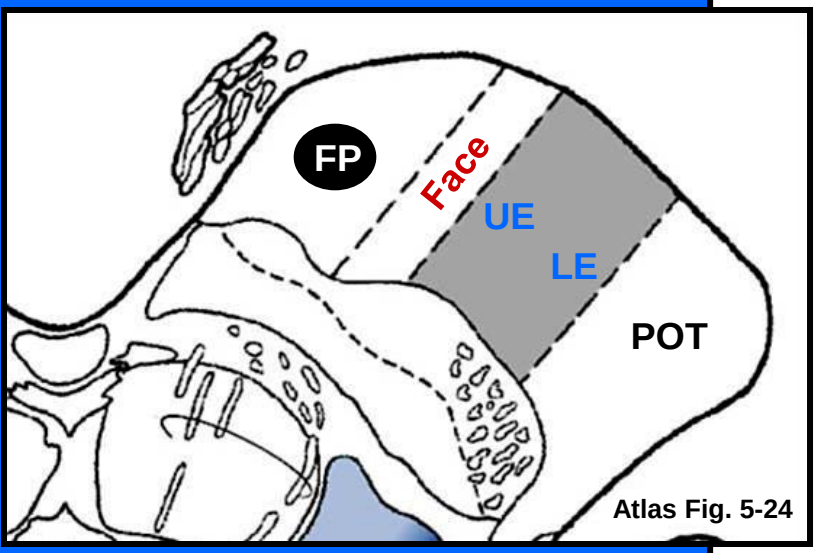

Atlas Fig. 5-24

Pyramidotomy


1
2
8
7
5
6
4 DAYS AFTER
BILAT. PYRAMIDOTOMY

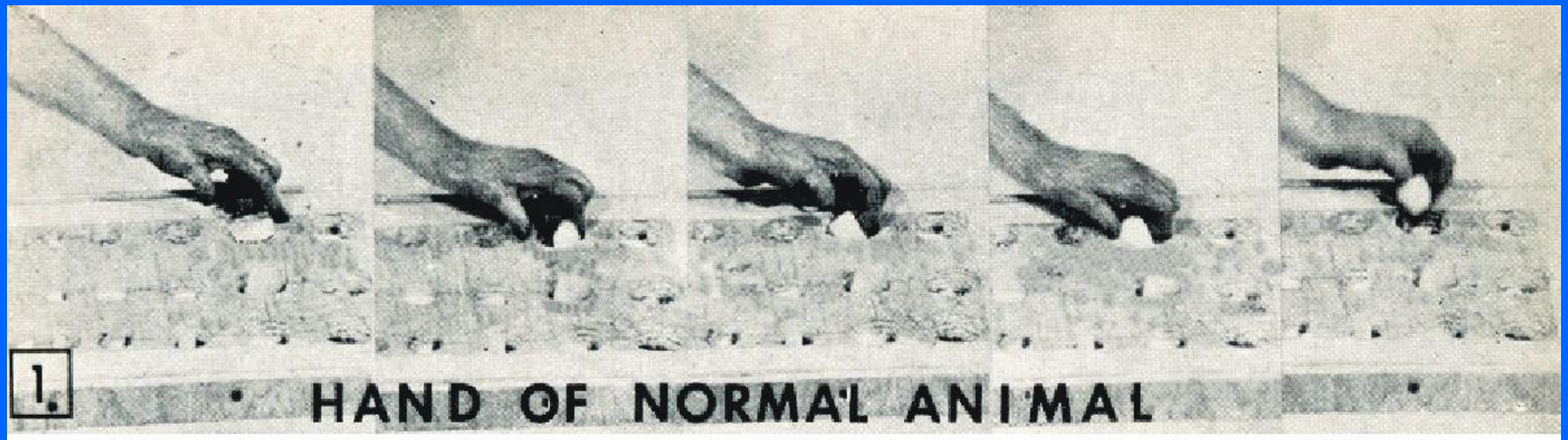

5 months after pyramidal tract lesion:



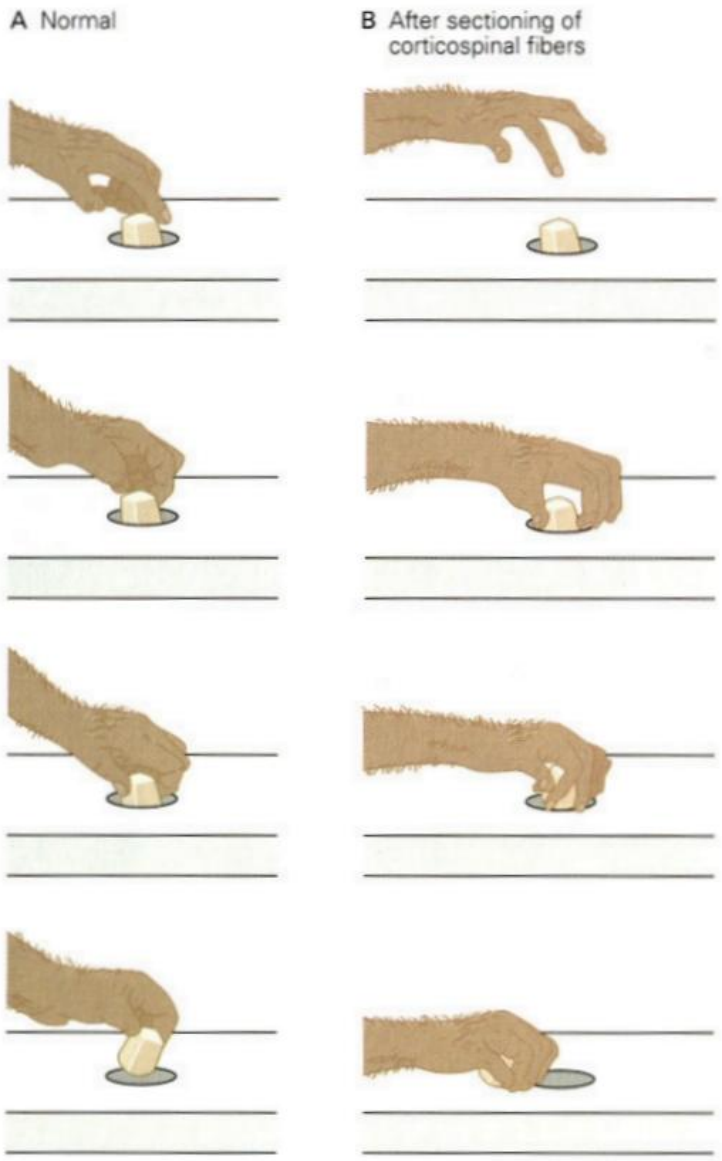
A Normal
B After sectioning of corticospinal fibers

Hemiparesis versus Hemiplegia

Corticobulbar

~~Corticobulbar~~ = Corticonuclear

International Anatomical Terminology

FCAT
Federative Committee on Anatomical Terminology

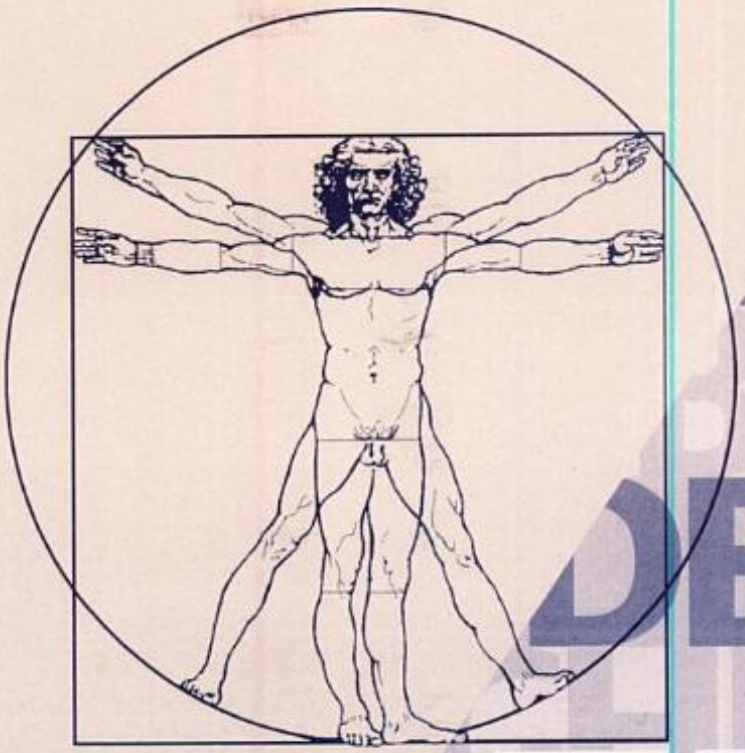

Thieme

Terminologia Anatomica

International Anatomical Terminology

FCAT
Federative Committee on Anatomical Terminology

1998
Thieme Stuttgart · New York