World Symposium on Endometriosis

Endometriosis, Cancer and Reproduction

Fertility Sparing Technology from Molecules to Robotics

A New Surgical-Ultrasound Scoring System Helps in Mapping Pelvic Deep Infiltrating Endometriosis and Predicts Surgical Difficulties

Errico Zupi

Department of Molecular and Development Medicine
University of Siena

Endometriosis
Do you know it when you see it?

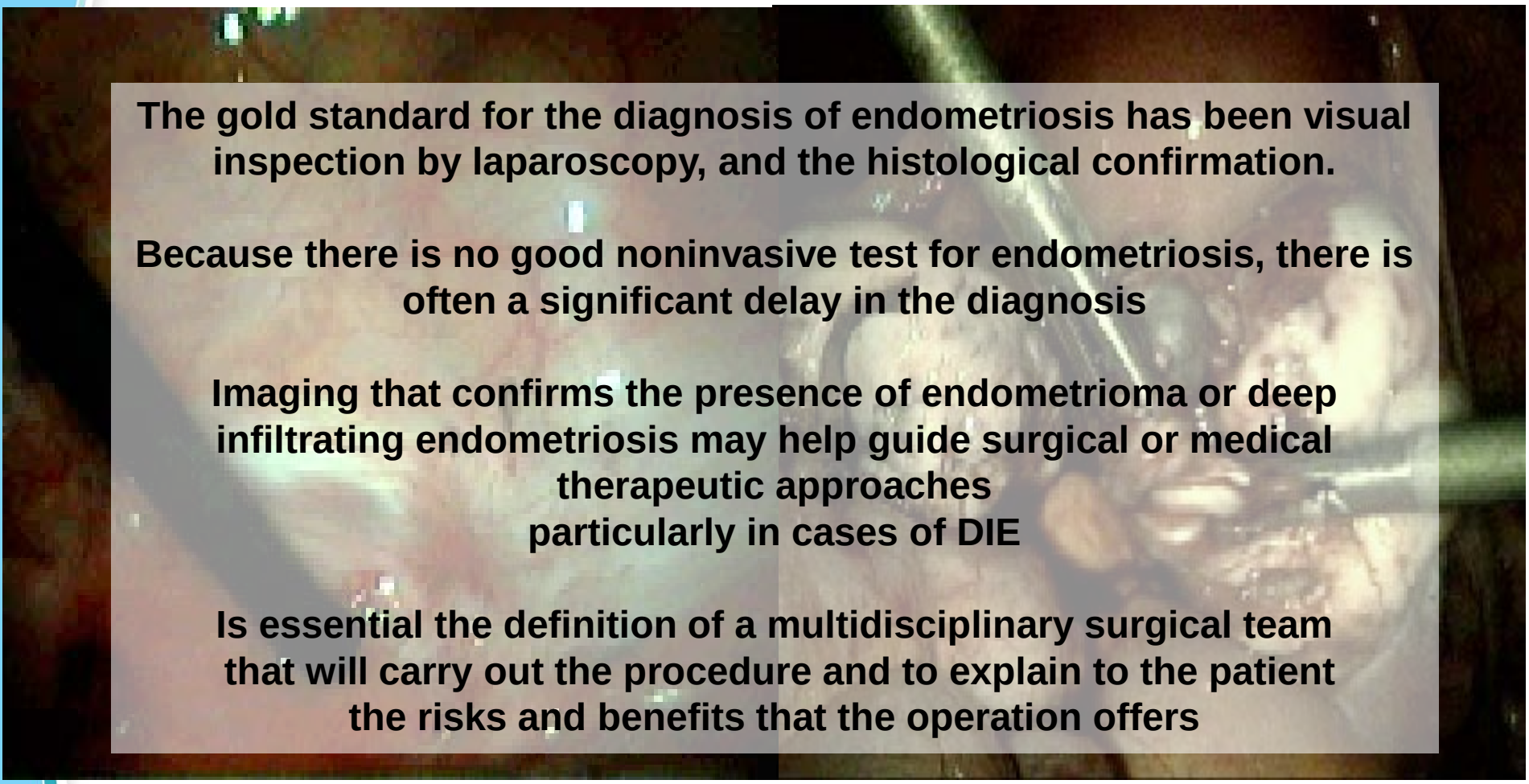

The gold standard for the diagnosis of endometriosis has been visual inspection by laparoscopy, and the histological confirmation.

Because there is no good noninvasive test for endometriosis, there is often a significant delay in the diagnosis

Imaging that confirms the presence of endometrioma or deep infiltrating endometriosis may help guide surgical or medical therapeutic approaches particularly in cases of DIE

Is essential the definition of a multidisciplinary surgical team that will carry out the procedure and to explain to the patient the risks and benefits that the operation offers

From diagnosis….. to treatment

Clinical history

Pelvic examination

Visual inspection
Vaginal touch

Imaging

Imaging is needed to evaluate the extension of the disease and to map the DIE lesions

counselling

adequate surgical or medical management

assisted reproduction

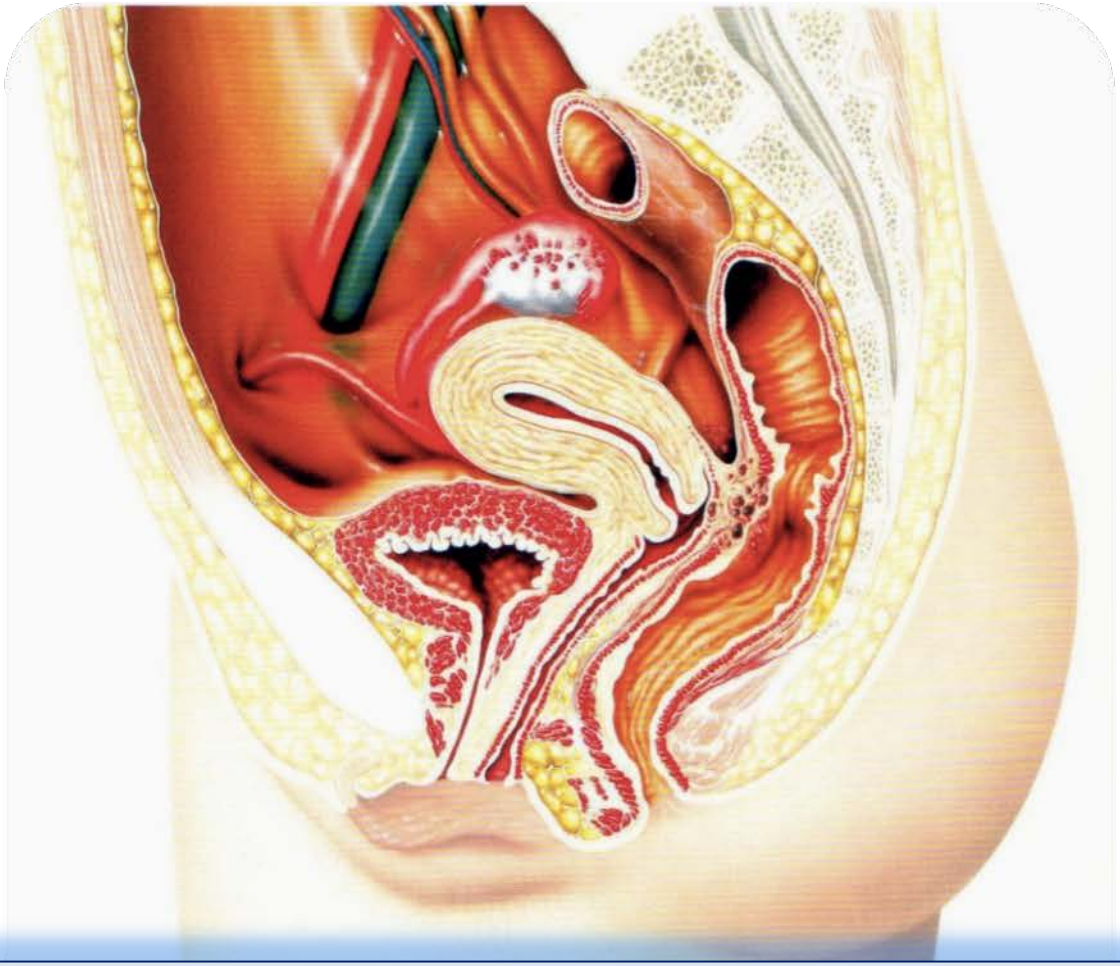

A new ultrasonographic/surgery driven system in mapping the extent of deep endometriosis may be useful for preoperative planning and intraoperative management of symptomatic patient

A New Surgical-Ultrasound Scoring System Helps in Mapping Pelvic Deep Infiltrating Endometriosis and Predicts Surgical Difficulties

The aim of this study was to assess the accuracy of TVS in localizing pelvic DIE by comparing the TVS results with laparoscopic/histological findings utilizing a new standardized ultrasound/surgically driven scoring system

"Endometriosis Surgical-Ultrasonographic Score System" (ESUSS)

extention of the disease

adequate management

counselling

common definitions for a common language

A New Surgical-Ultrasound Scoring System Helps in Mapping Pelvic Deep Infiltrating Endometriosis and Predicts Surgical Difficulties

prospective multicenter study 214 patients with confirmed hystological diagnosis of DIE

University of RomeTor Vergata
University of Siena
Malzoni Advanced Endoscopic Surgery Center, Avellino

Inclusion criteria

TVS diagnosis of DIE with subsequent laparoscopic/histological confirmation

Main outcome Measures

Surgical confirmation of the ultrasonographic data in evaluating presence and localization of DIE

LOCATION	LESION				SCORE
POSTERO-LATERAL DIE					
UTEROSACRAL LIGAMENTS (USL) and TORUS	NODULE				
	No 0	Yes <1 cm 2	Yes 1-3 cm 4	Yes > 3cm 6	
	RIGHT USL				
	No = 0		Yes = 4		
	LEFT USL				
	No = 0		Yes =4		
	TORUS				
	No = 0		Yes =4		
PARAMETRIA and URETERS	RIGHT PARAMETRIUM				
	No = 0		Yes =6		
	LEFT PARAMETRIUM				
	No = 0		Yes =6		
	RIGHT URETER				
	No=0	Compression=8		Dilatation=10	
RECTO-VAGINAL SEPTUM and VAGINA	LEFT URETER				
	No=0	Compression=8		Dilatation=10	
	RVS				
	No = 0		Yes =4		
	VAGINA				
	No = 0		Yes = 6		
CRANIAL and CAUDAL RECTUM	CRANIAL RECTUM				
	No = 0		Yes = 6		
	Wall infiltration grade				
	Superficial = 8		Full thickness = 10		
	CAUDAL RECTUM				
	No = 0		Yes = 10		
	Wall infiltration grade				
	Superficial =8		Full thickness =10		
POSTERO-LATERAL COMPARTMENT (PL) TOTAL SCORE					
DOUGLAS (D)					
DOUGLAS POUCH OBLITERATION	No = 0	Yes partial = 6	Yes complete= 10		
ANTERIOR DIE					
BLADDER	NODULE				
	No =0		Yes = 6 ..... mm site :		
	Distance from right ureter: ..... mm				
	Distance from left ureter: ..... mm				
	ADHESIONS				
	No =0		Yes = 2		
ANTERIOR COMPARTMENT (A) TOTAL SCORE					
ADNEXAL ENDOMETRIOSIS					
ADNEXA	ENDOMETRIOMA (right ovary)				
	No =0		Yes = 2 ..... mm		
	ADHESIONS (right ovary)				
	No =0		Yes = 2 site:		
	RIGHT TUBE				
	No =0		Yes = 2 ..... mm		
	ENDOMETRIOMA (left ovary)				
	No = 0		Yes = 2 ..... mm		
	ADHESIONS (left ovary)				
	No = 0		Yes = 2 site:		
	LEFT TUBE				
	No = 0		Yes = 2 ..... mm		
ADNEXAL COMPARTMENT (AD) TOTAL SCORE					
OTHER SITES	Description				

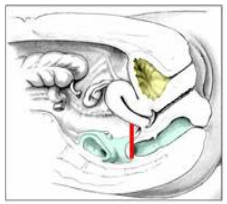

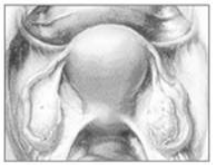

COMPARTMENTS:	Score	Range
PL (Postero-lateral DIE)		**(0-112)**
D (Douglas)		**(0-10)**
A (Anterior DIE)		**(0-8)**
AD (Adnexa)		**(0-12)**
TOTAL SCORE		**(0-142)**

This mapping system is based on the anatomical site where DIE could be found and was elaborated by surgeons and sonographer together in order to define exactly each site

After surgery the operative report, the surgical ESUS and the mean operating time of each surgical procedure were recorded

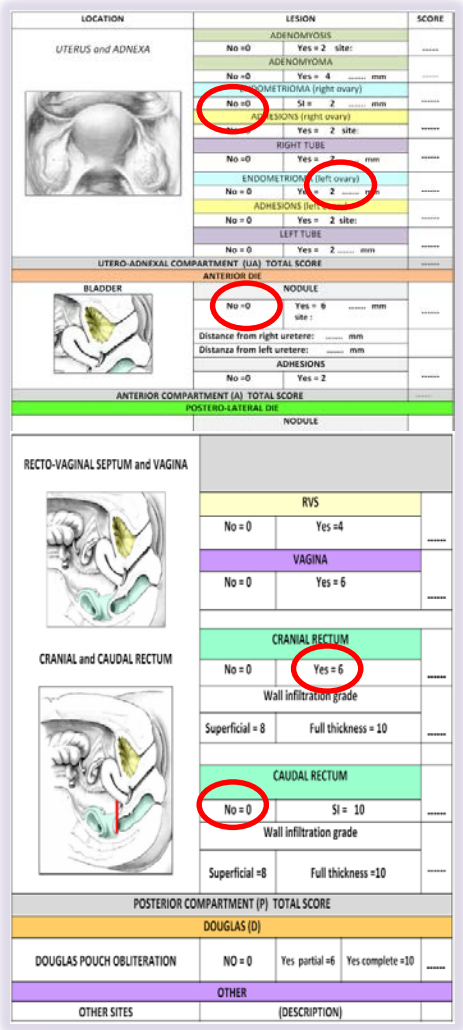

LOCATION	LESION		SCORE
UTERUS and ADNEXA	ADENOMYOSIS		
	No =0	Yes = 2 site:	.....
	ADENOMYOMA		
	No =0	Yes = 4 ..... mm	.....
	ENDOMETRIOMA (right ovary)		
	No =0	SI = 2 ..... mm	.....
	ADHESIONS (right ovary)		
		Yes = 2 site:	.....
	RIGHT TUBE		
	No =0	Yes = 2 ..... mm	.....
	ENDOMETRIOMA (left ovary)		
	No = 0	Yes = 2 ..... mm	.....
	ADHESIONS (left ovary)		
	No = 0	Yes = 2 site:	.....
	LEFT TUBE		
	No = 0	Yes = 2 ..... mm	.....
UTERO-ADNEXAL COMPARTMENT (UA) TOTAL SCORE			.....
ANTERIOR DIE			
BLADDER	NODULE		
	No =0	Yes = 6 ..... mm site :	.....
	Distance from right uretere: ..... mm		
	Distanza from left uretere: ..... mm		
	ADHESIONS		
	No =0	Yes = 2	.....
ANTERIOR COMPARTMENT (A) TOTAL SCORE			.....
POSTERO-LATERAL DIE			
	NODULE		
RECTO-VAGINAL SEPTUM and VAGINA			
	RVS		
	No = 0	Yes =4	.....
	VAGINA		
	No = 0	Yes = 6	.....
CRANIAL and CAUDAL RECTUM	CRANIAL RECTUM		
	No = 0	Yes = 6	.....
	Wall infiltration grade		
	Superficial = 8	Full thickness = 10	.....
	CAUDAL RECTUM		
	No = 0	SI = 10	.....
	Wall infiltration grade		
	Superficial =8	Full thickness =10	.....
POSTERIOR COMPARTMENT (P) TOTAL SCORE			
DOUGLAS (D)			
DOUGLAS POUCH OBLITERATION	NO = 0	Yes partial =6 / Yes complete =10	.....
OTHER			
OTHER SITES	(DESCRIPTION)		

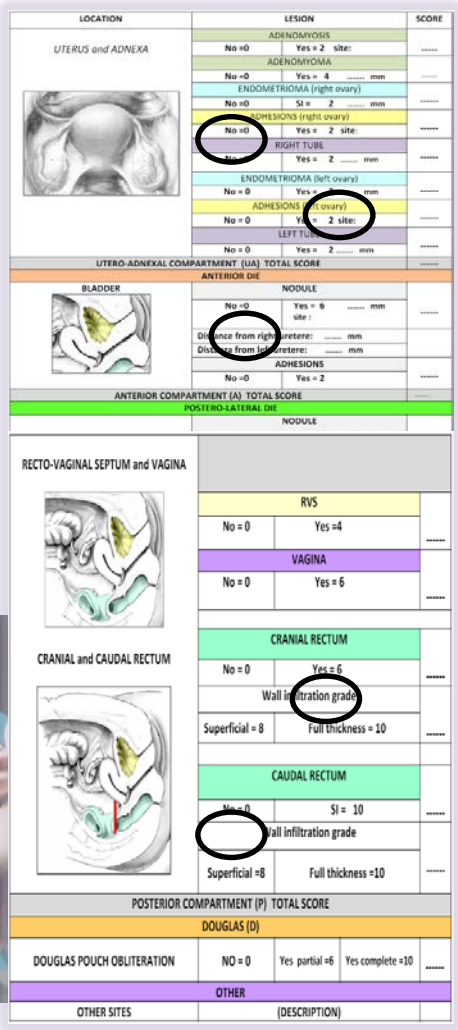

LOCATION	LESION		SCORE
UTERUS and ADNEXA	ADENOMYOSIS		
	No =0	Yes = 2 site:	.....
	ADENOMYOMA		
	No =0	Yes = 4 ..... mm	.....
	ENDOMETRIOMA (right ovary)		
	No =0	SI = 2 ..... mm	.....
	ADHESIONS (right ovary)		
	No =0	Yes = 2 site:	.....
	RIGHT TUBE		
	No =0	Yes = 2 ..... mm	.....
	ENDOMETRIOMA (left ovary)		
	No = 0	Yes = 2 ..... mm	.....
	ADHESIONS (left ovary)		
	No = 0	Yes = 2 site:	.....
	LEFT TUBE		
	No = 0	Yes = 2 ..... mm	.....
UTERO-ADNEXAL COMPARTMENT (UA) TOTAL SCORE			.....
ANTERIOR DIE			
BLADDER	NODULE		
	No =0	Yes = 6 ..... mm site :	.....
	Distance from right uretere: ..... mm		
	Distanza from left uretere: ..... mm		
	ADHESIONS		
	No =0	Yes = 2	.....
ANTERIOR COMPARTMENT (A) TOTAL SCORE			.....
POSTERO-LATERAL DIE			
	NODULE		
RECTO-VAGINAL SEPTUM and VAGINA			
	RVS		
	No = 0	Yes =4	.....
	VAGINA		
	No = 0	Yes = 6	.....
CRANIAL and CAUDAL RECTUM	CRANIAL RECTUM		
	No = 0	Yes = 6	.....
	Wall infiltration grade		
	Superficial = 8	Full thickness = 10	.....
	CAUDAL RECTUM		
	No = 0	SI = 10	.....
	Wall infiltration grade		
	Superficial =8	Full thickness =10	.....
POSTERIOR COMPARTMENT (P) TOTAL SCORE			
DOUGLAS (D)			
DOUGLAS POUCH OBLITERATION	NO = 0	Yes partial =6 / Yes complete =10	.....
OTHER			
OTHER SITES	(DESCRIPTION)		

common definitions for a common language

Sonographic DIE mapping

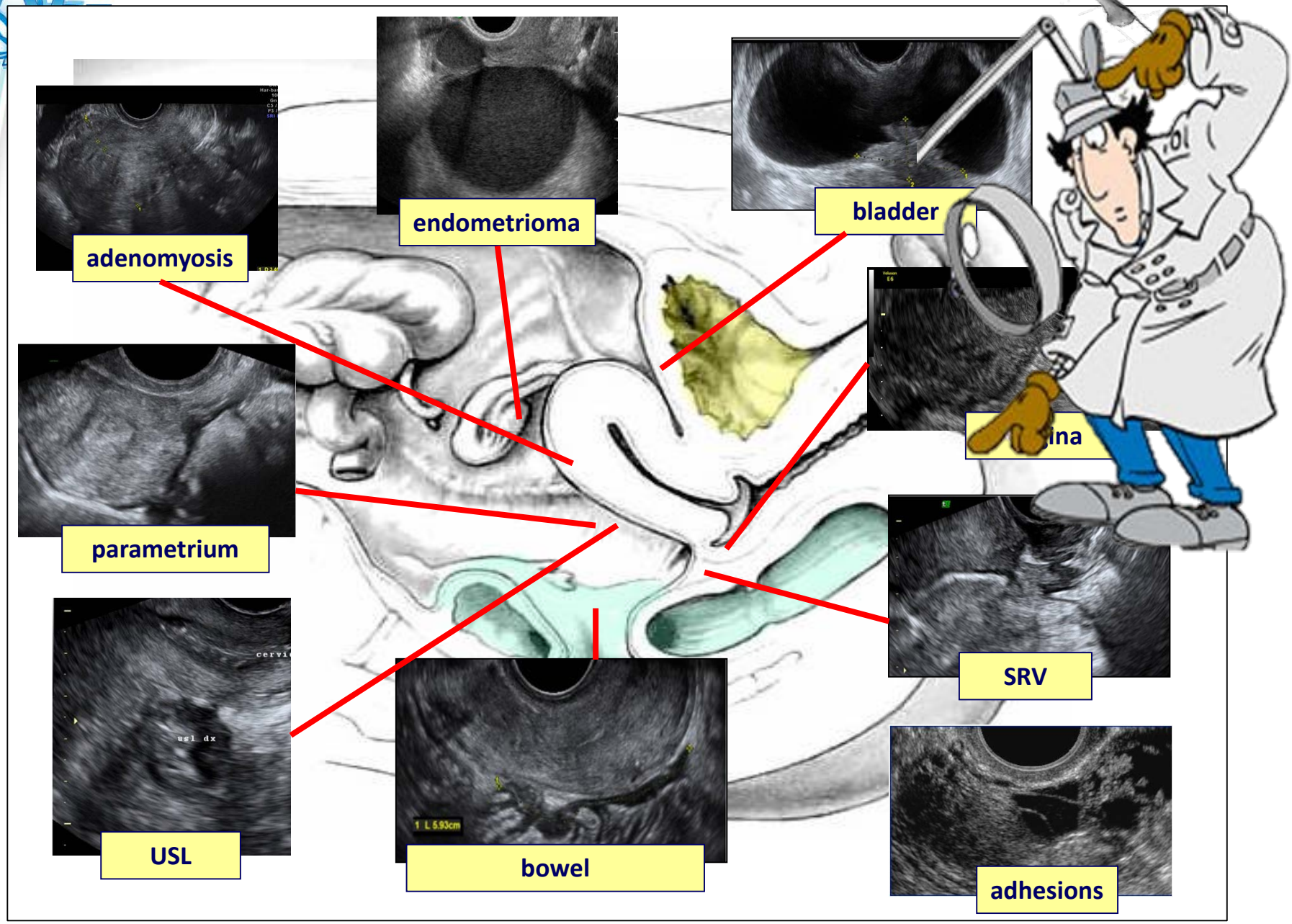

A New Surgical-Ultrasound Scoring System Helps in Mapping Pelvic Deep Infiltrating Endometriosis and Predicts Surgical Difficulties

- ***Posterior compartment***

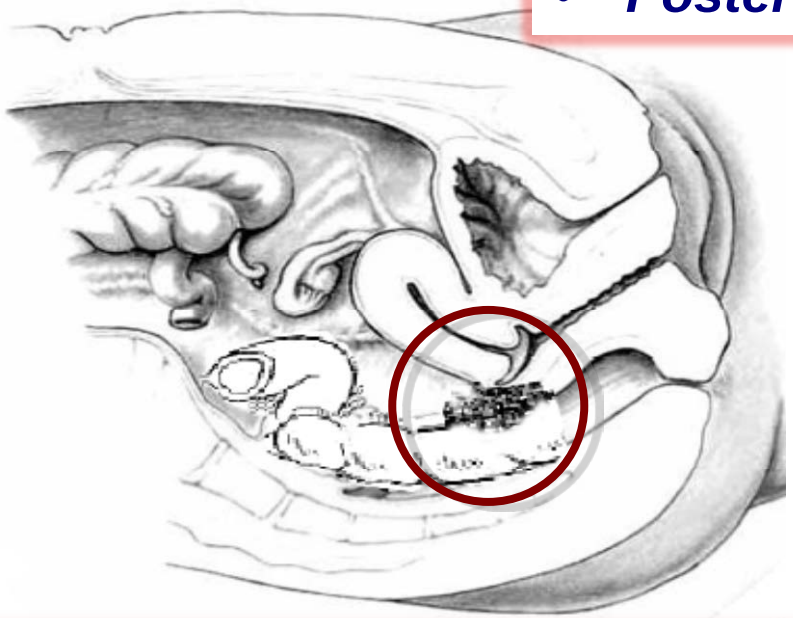

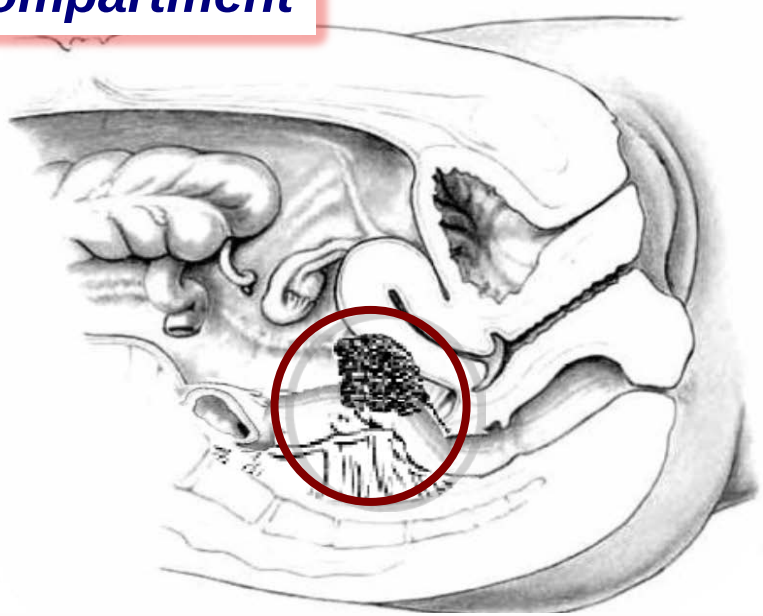

Utilizing TVS and TRS (if needed):

- **an accurate assessment of the vagina, particularly the areas of the posterior and lateral vaginal fornix**
- **the retrocervical area with torus and USL**
- **the parametria laterally**
- **the rectovaginal septum (RVS)**

Posterior compartment

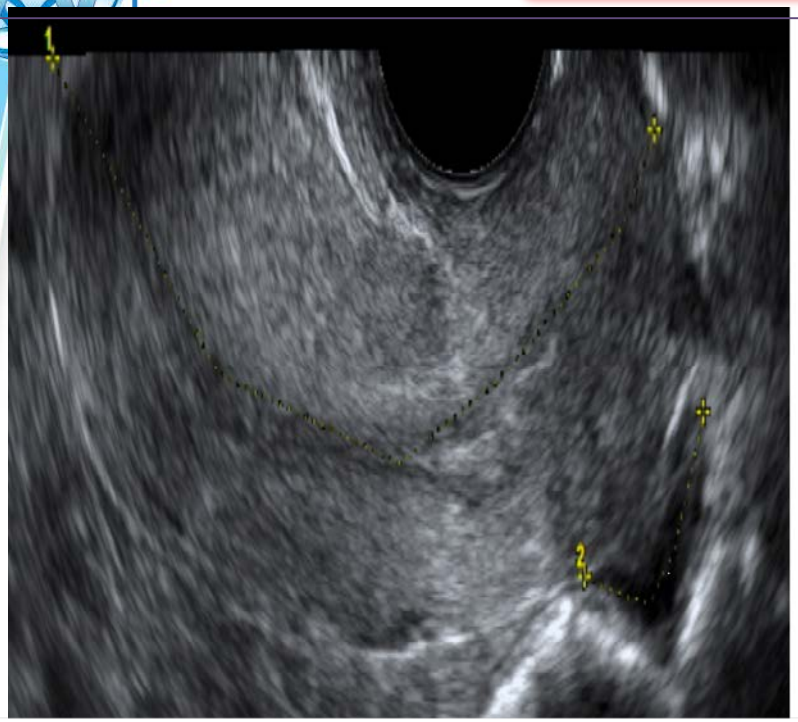

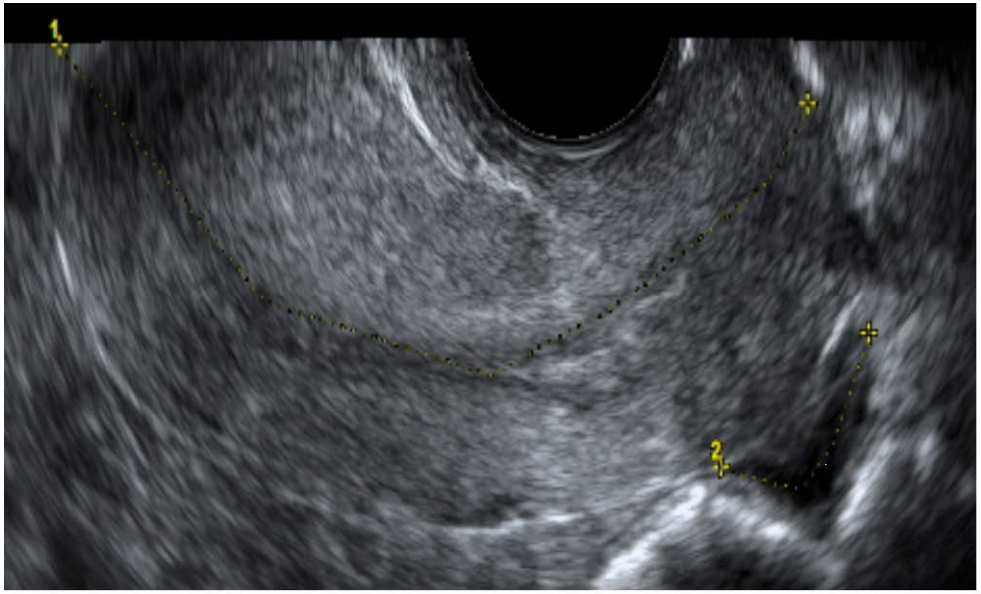

Rectal sigmoid nodules
were visualized as an irregular hypoechoic mass penetrating into the intestinal wall replacing its normal structure (hypoechoic and thin muscularis propria and hyperechoic submucosa/mucosa).
With respect to the posterior uterine wall, intestinal nodules located below the level of the insertion of uterosacral ligaments on the cervix were considered low rectal lesions

Posterior compartment

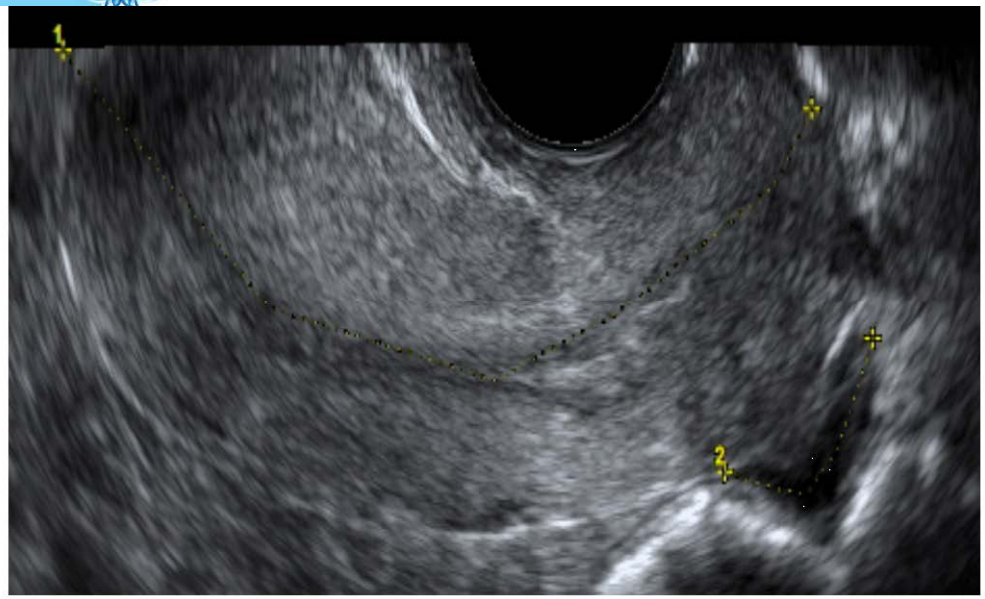

b

In case of posterior nodules (torus and uterosacral ligaments, parametria, SRV, vaginal posterior wall) bilateral pararectal dissection was performed down to the inferior limit of the nodule, and then the rectum was separated from the posterior uterine and/or vaginal wall correlating the extent of excision with the degree of disease

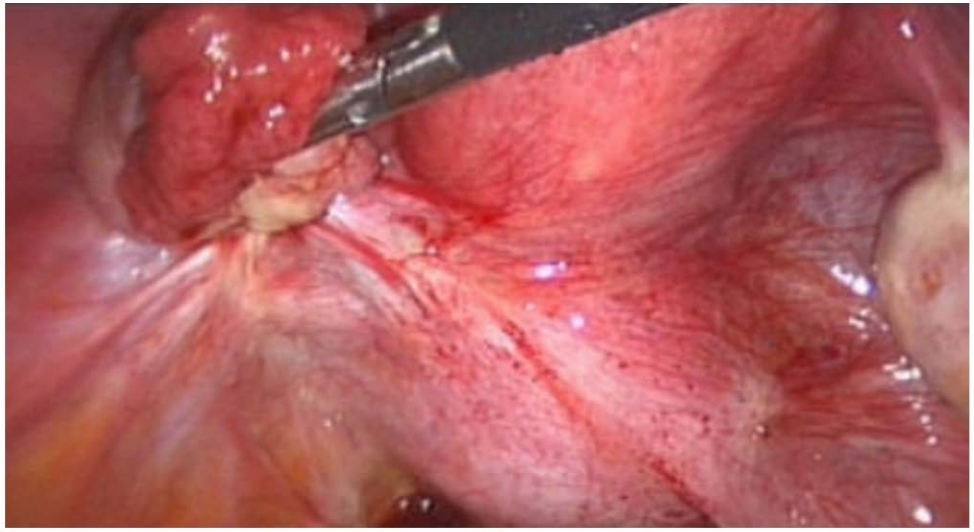

c

In cases of nodules infiltrating vaginal wall, a full-thickness excision was done suturing the defect laparoscopically or vaginally

Posterior compartment

Upper rectal or the recto-sigmoid junction, possible to visualize by TVS till 3-4 cm above the uterine fundus

The ultrasound scan has low accuracy in detecting the infiltration to the mucosal layer, therefore TVS does not help surgeons in deciding whether to perform segmental or disc resection of the lesion

More likely this decision depends on the diameters of infiltrating tissue and lumen stenosis

Posterior compartment

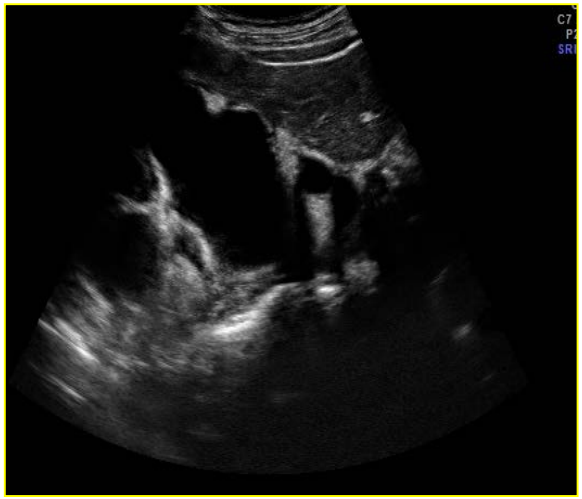

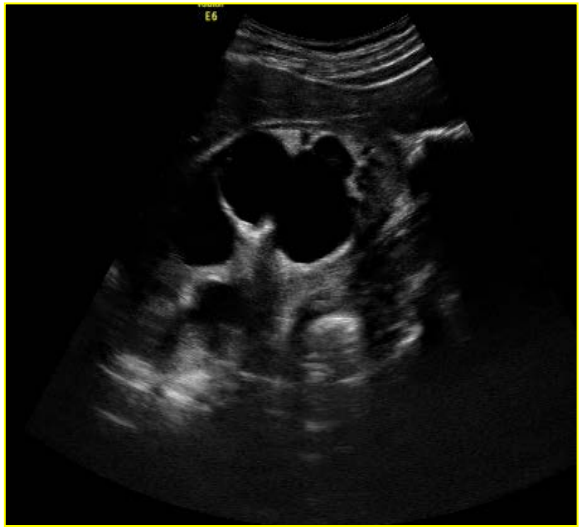

In case of endometriotic lesions involving the uterosacral ligaments, special attention was paid to pelvic ureteral evaluation particularly in the paracervical area and by transabdominal ultrasound we evaluated always the renal pelvis. An ureteral involvement was recorded in case of lesions > 3 cm if located in the omolateral parametrium.

Posterior compartment

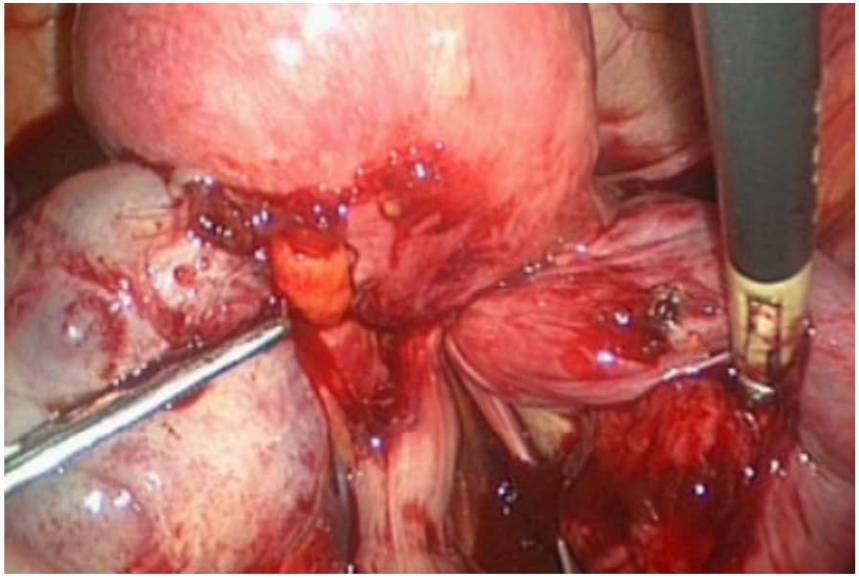

Lesions of the recto-sigmoid were removed by shaving or resection depending on the size and depth of infiltration of the bowel wall

With segmental bowel resection, after an effective mobilization of the descending part of the sigmoid colon, a circular stapler was inserted and fixed in the bowel lumen to obtain the end-to-end or side-to-end anastomosis

In few cases of a lower tract involvement a stoma was provided to avoid complications

Anterior compartment

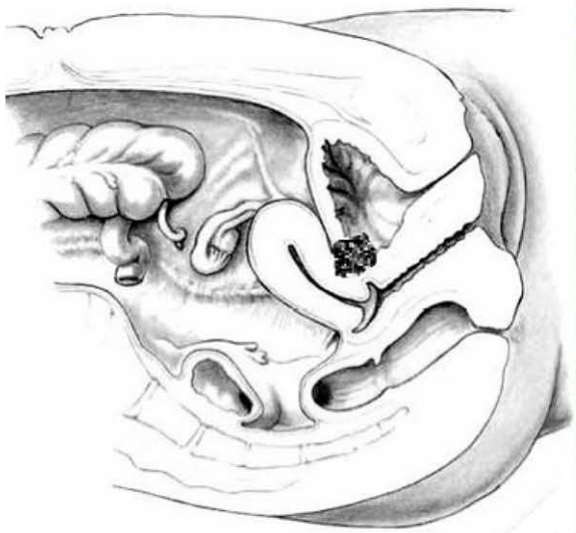

Anterior compartment (bladder):

The bladder was filled to better evaluate the structure of its wall and the presence of endometriotic nodules or adhesions.

Nodules appeared as round shaped lesions with or without cystic areas and regular/irregular margins of the bladder wall, bulging towards the lumen.

Anterior compartment

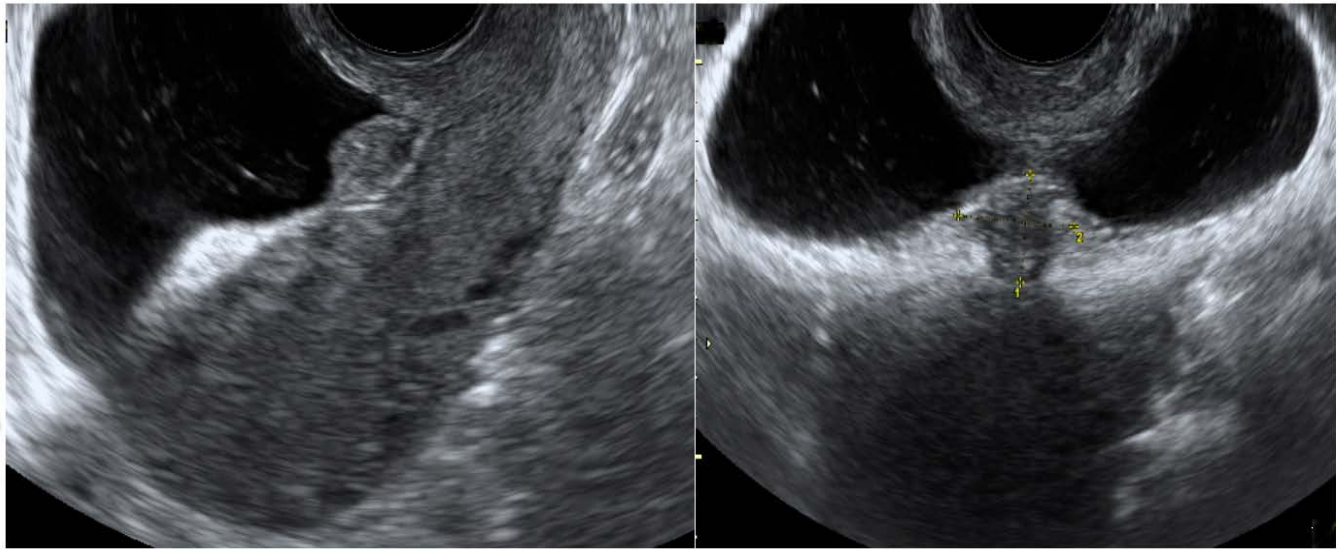

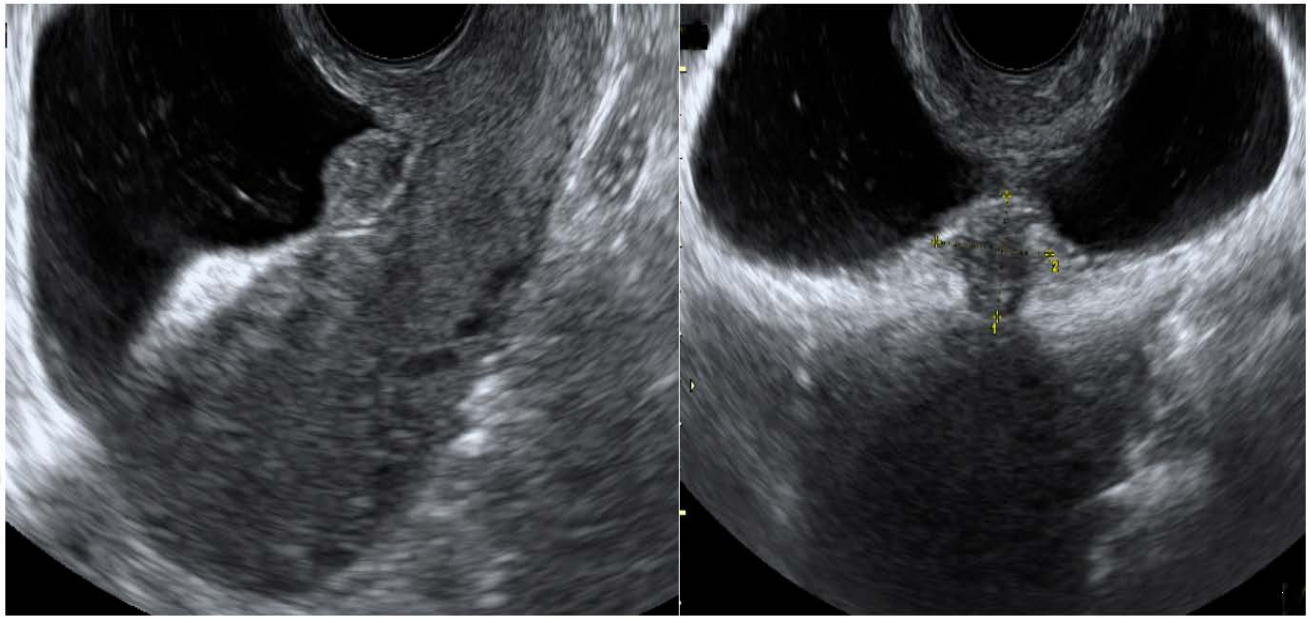

Ureteral resection was done only in few cases of complete infiltration of its layers. In the majority of cases an accurate ureterolysis was performed with a successful dilatation of its distal part. When the ureter was involved close to the bladder wall the segment was resected and ureteral bladder implantation was done.

Anterior compartment

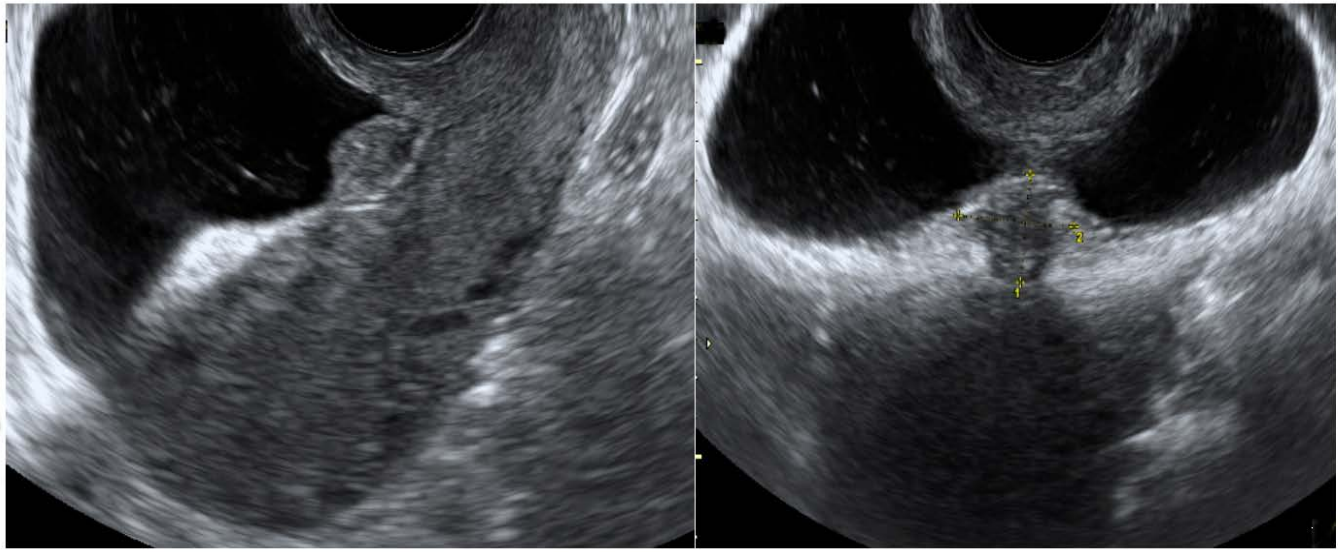

Bladder resection was performed with monopolar electrode cutting around the lesion and including a visible edge of normal tissue

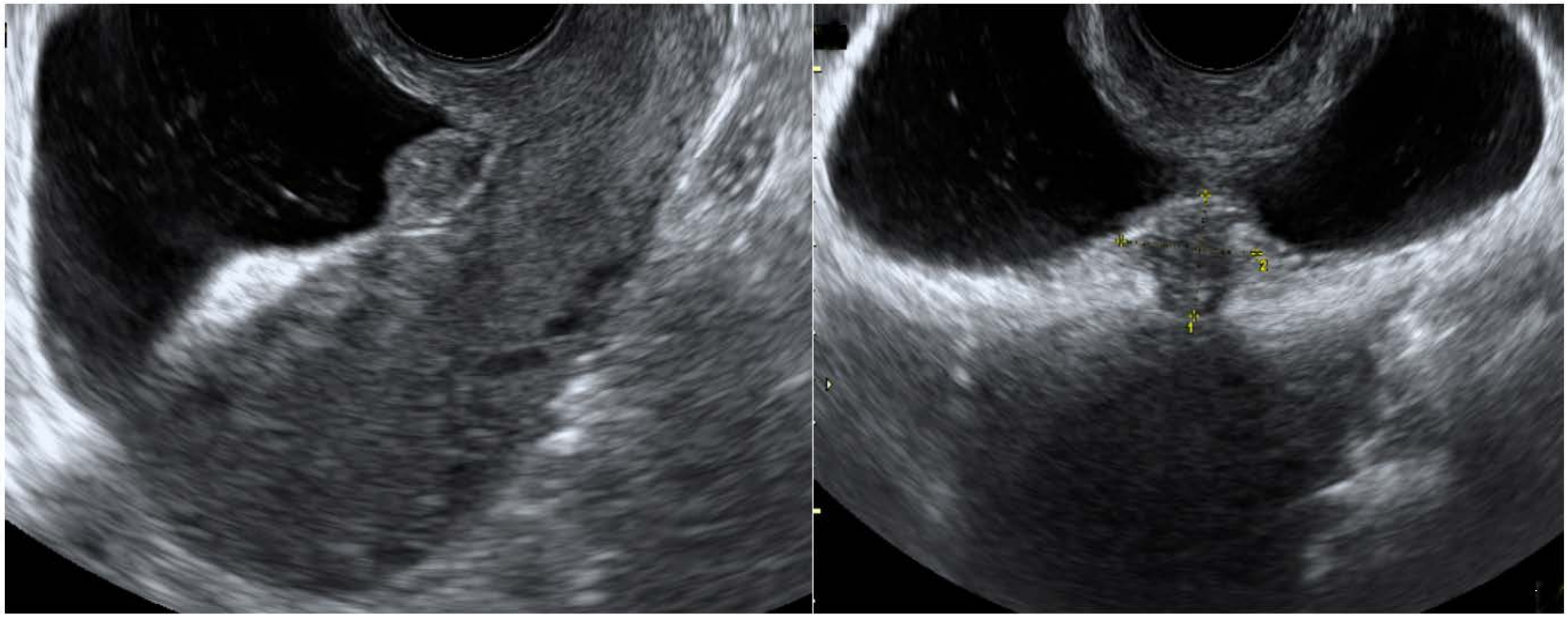

Endometriosis localizations

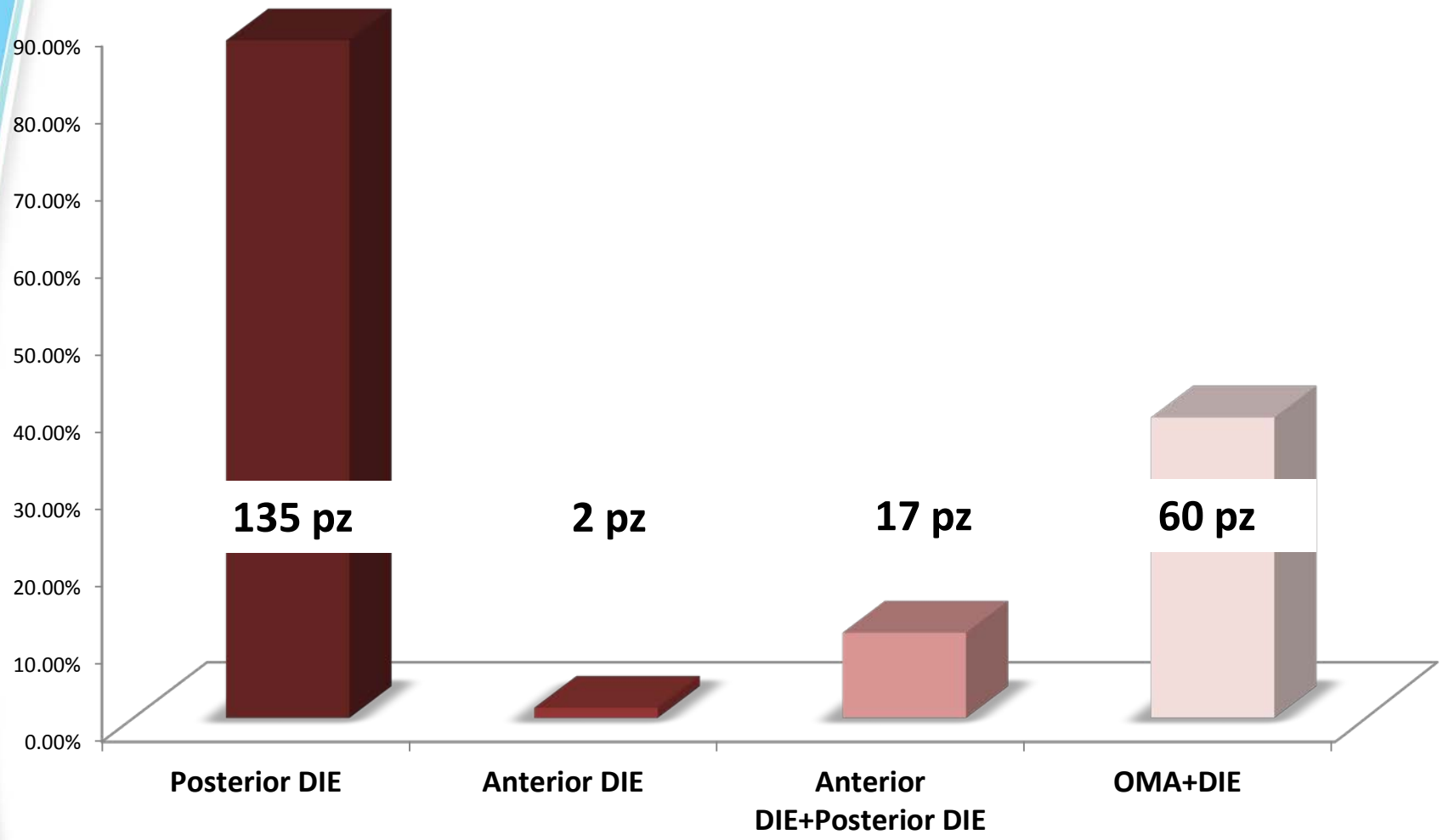

Endometriosis Surgical-Ultrasound Score System

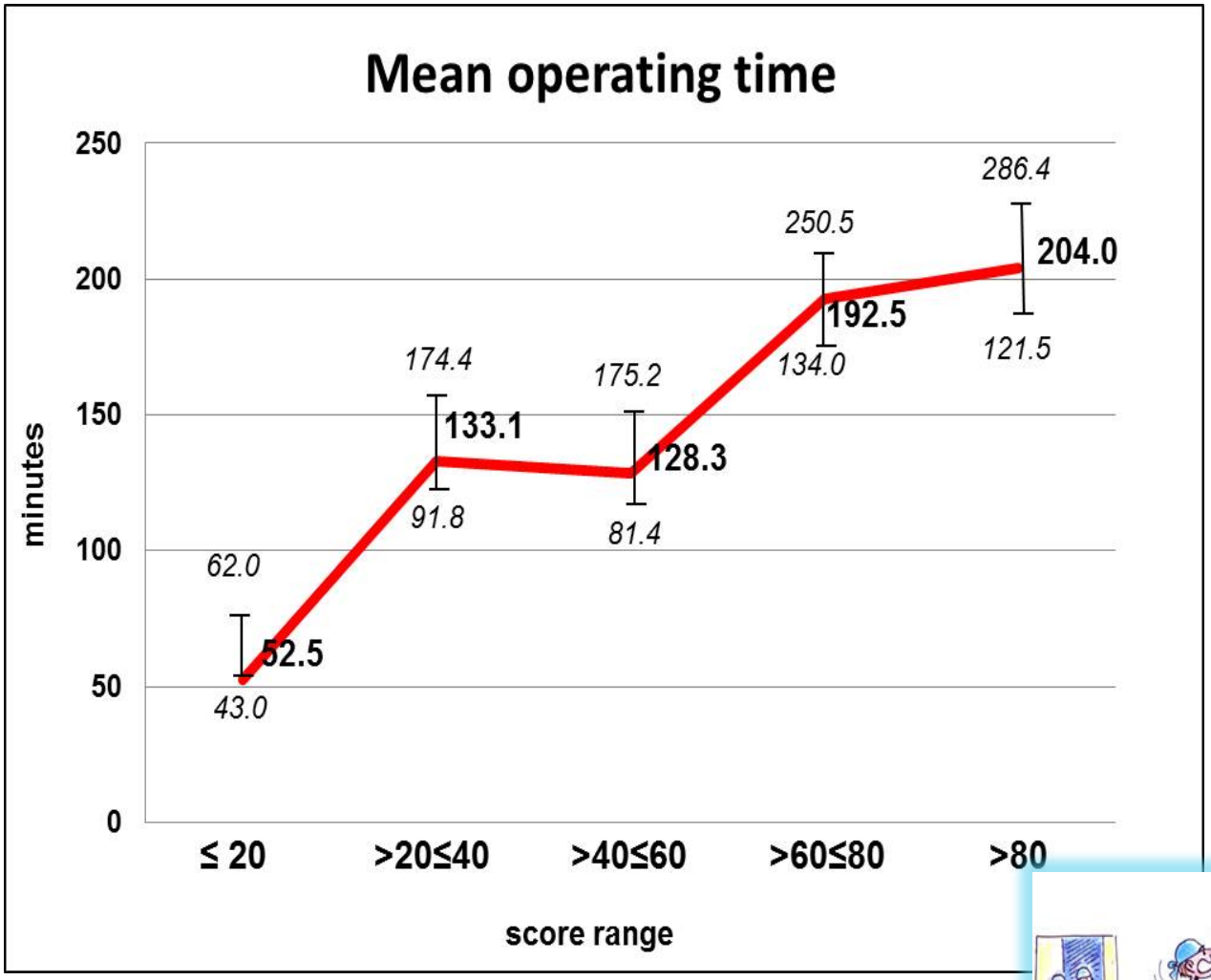

the score reflect the surgical difficulty

A New Surgical-Ultrasound Scoring System Helps in Mapping Pelvic Deep Infiltrating Endometriosis and Predicts Surgical Difficulties

- ✓ to adopt a common language between different expert operators
- ✓ can give an accurate assessment of the extent of DIE with a high diagnostic accuracy

best surgical approach and the potential need to involve other surgical specialists

to establish a correct medical management

properly inform patients of the extent of their disease and therapeutic options

- ✓ possibility to compare and share results between different centers