Institute for Molecular Medicine Finland
Nordic EMBL Partnership for Molecular Medicine

Exploring the Spatial Dimension of Estrogen and Progesterone Signaling: Detection of Nuclear Labeling in Lobular Epithelial Cells in Mammary Glands Adjacent to Breast Cancer

Anne Grote[1], Mahmoud Abbas[2] , Nina Linder[1] , Hans. H. Kreipe[2] , Johan Lundin[1] Friedrich Feuerhake[2]

[1] Institute for Molecular Medicine Finland (FIMM), Tukholmankatu 8, 00290, Helsinki, Finland

[2] Hannover Medical School (MHH), Institute for Pathology, Neuropathology, Carl-Neuberg-Str. 1, 30625 Hannover, Germany

19.06.2014

© FIMM - Institiute for Molecular Medicine Finland

Overview

- Introduction
  - Evaluation of lobules in relation to tumor in breast cancer: A proof of concept for automated region of interest (ROI) detection for analysis at cell level
- Image analysis
  - Strategy of detecting lobules and tumor with Definiens Developer software
- Results
  - Combination of distance metrics with ROI-based object detection reveals trends in average ER/PR nuclear positivity in relation to tumor border
- Outlook
  - Potential applications of the principle, current limitations, and approaches to improve detection and evaluation
- Summary

Goal: evaluate lobules in relation to tumor

- Background: Growing demand to evaluate nuclear markers, e.g. in context of ER/PR signaling, in tumor cells and adjacent tissue in cancer models
- Human lobules as proof-of-concept for analyzing ER/PR related markers in their spatial context (Material: Paraffin-embedded archival breast cancer tissue)

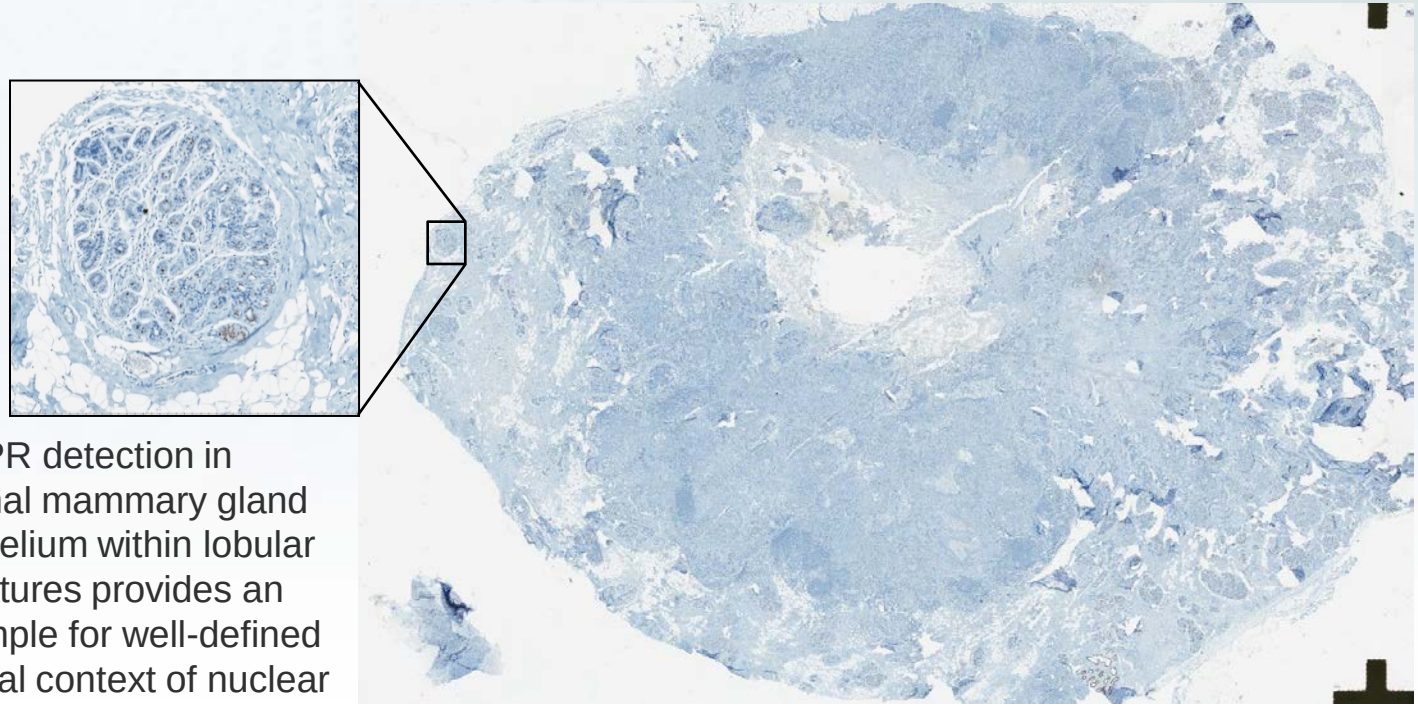

ER/PR detection in normal mammary gland epithelium within lobular structures provides an example for well-defined spatial context of nuclear pathway-related markers

Image analysis - workflow

Preprocessing
- downsampling
- tissue – background separation
- creation of texture channel

⇩

Segmentation
- five levels of granularity

⇩

Classification
- lobule detection
- tumor detection

⇩

Lobule evaluation
- nuclei detection (pos./neg.)
- positivity & distance to tumor

Preprocessing

- 1. create low resolution image (10% of original resolution) for analysis of whole slide
  - → faster processing time
  - → fewer details better for analysis of larger regions
- 2. tissue / background segmentation based on intensity
- 3. create image layer with textural feature: standard deviation to neighbour pixels

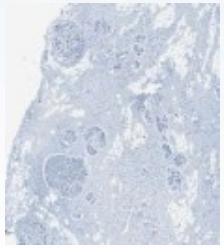

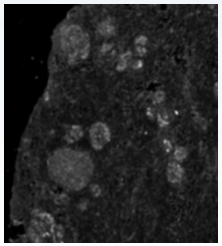

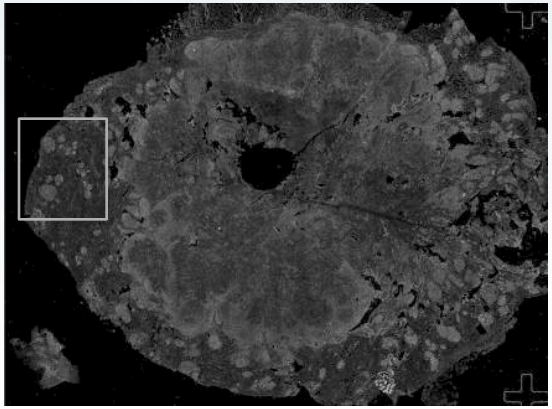

Segmentation

- multiresolution segmentation
  - image information: RGB channels and standard deviation to neighbour pixels
- five levels of granularity: from coarse to fine



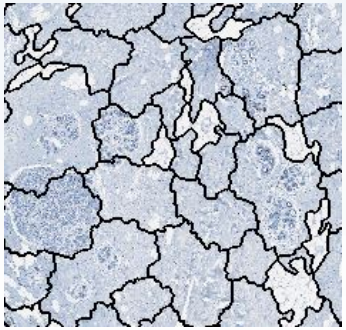

level 1



level 2



level 3



level 4



level 5

Detection of lobules

› 1. Classification of lobule candidates

- in each level (except for the finest): detection of initial lobule candidates

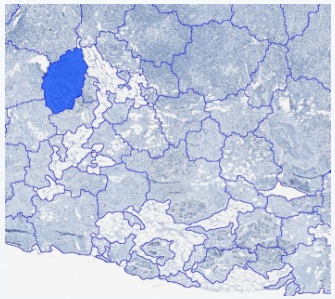

level 1

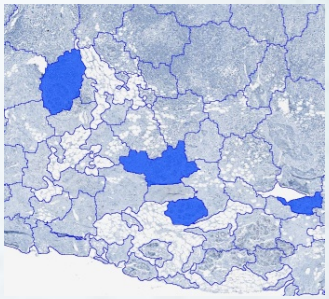

level 2

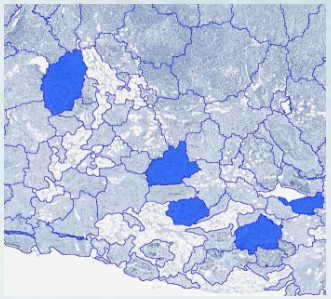

level 3

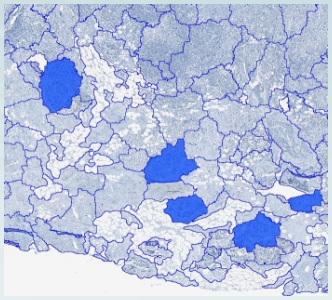

level 4

- features of lobule class:

textural:
- mean standard deviation to neighbour pixels (min and max)



geometric:
- min and max area
- min roundness

relational (textural feature):
- min mean difference to neighbour segments
- min border contrast to neighbour segments

Detection of lobules

- 2. Refining classification by combination of segmentation levels
  - consolidating levels: going through levels and analysing subsegments of candidates
    - Example: if several subsegments: check classification of ”small” lobule class: without restrictions on size and neighbour difference

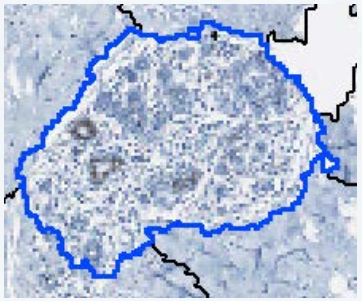

Classification in level 3

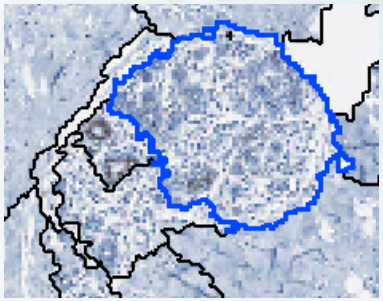

Classification in level 4

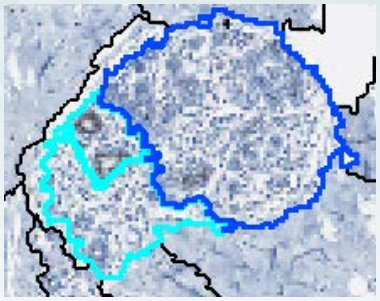

Classified subsegments

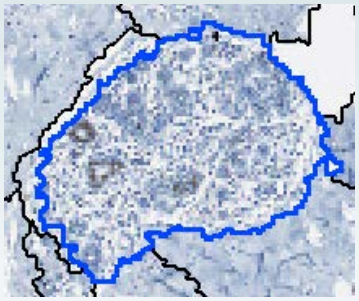

Merging detected segments

  - result: one segmentation level with all classified lobules

Classification of tumor

- Seed-based classification for tumors with coherent tumor mass
- Seed segments: segments whose mean standard deviation to neighbour pixels is very close to median value

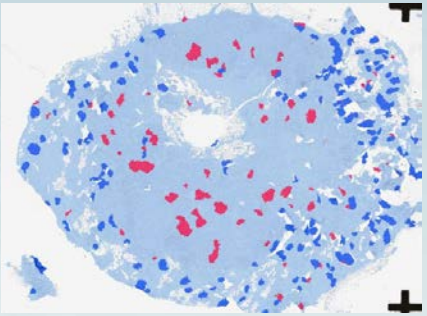

red: tumor
dark blue: lobules

Classification of tumor

- Seed-based classification for tumors with coherent tumor mass
- Seed segments: segments whose mean standard deviation to neighbour pixels is very close to median value
- neighbour segments added iteratively

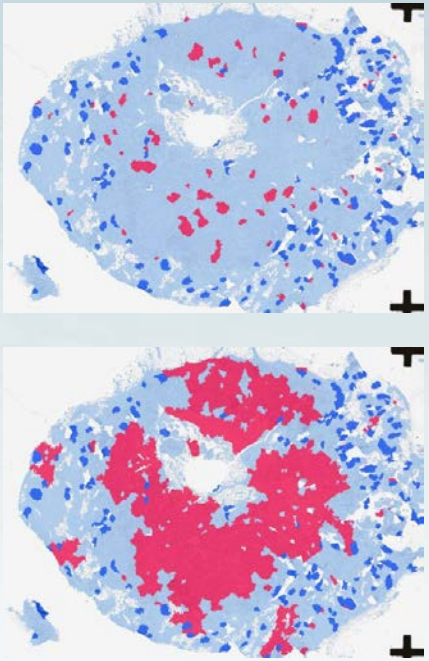

red: tumor
blue: lobules

Classification of tumor

- Seed-based classification for tumors with coherent tumor mass
- Seed segments: segments whose mean standard deviation to neighbour pixels is very close to median value

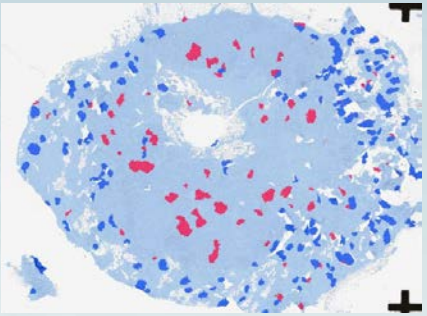

- neighbour segments added iteratively

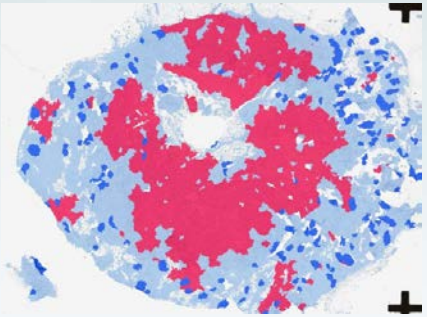

- post-processing: filling holes, deleting small regions

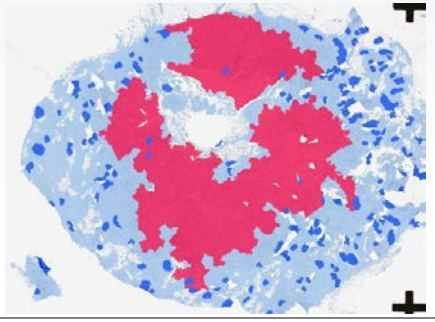

red: tumor
blue: lobules

Detailed lobule analysis

› Nuclei detection and classification in high resolution

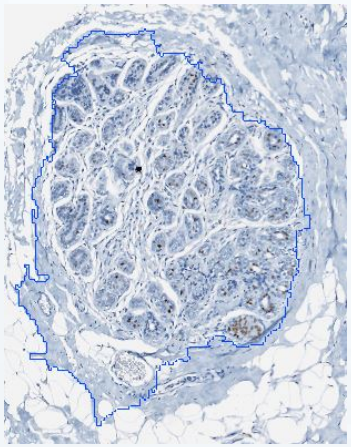

High resolution lobule

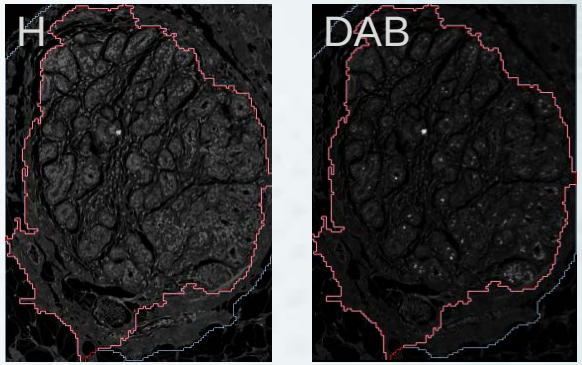

Stain separation

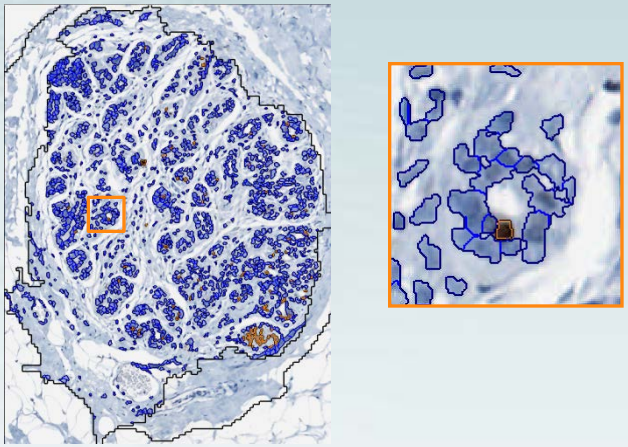

Nuclei detection: threshold + watershed algorithm separately on H and DAB channels
orange: ER positive nuclei
blue: negative nuclei

› nuclear positivity for each lobule:

$$ratio = \frac{number\ DAB\ nuclei}{number\ DAB\ nuclei + number\ H\ nuclei}$$

Detailed lobule analysis

- Dividing lobules into three categories based on distance to tumor

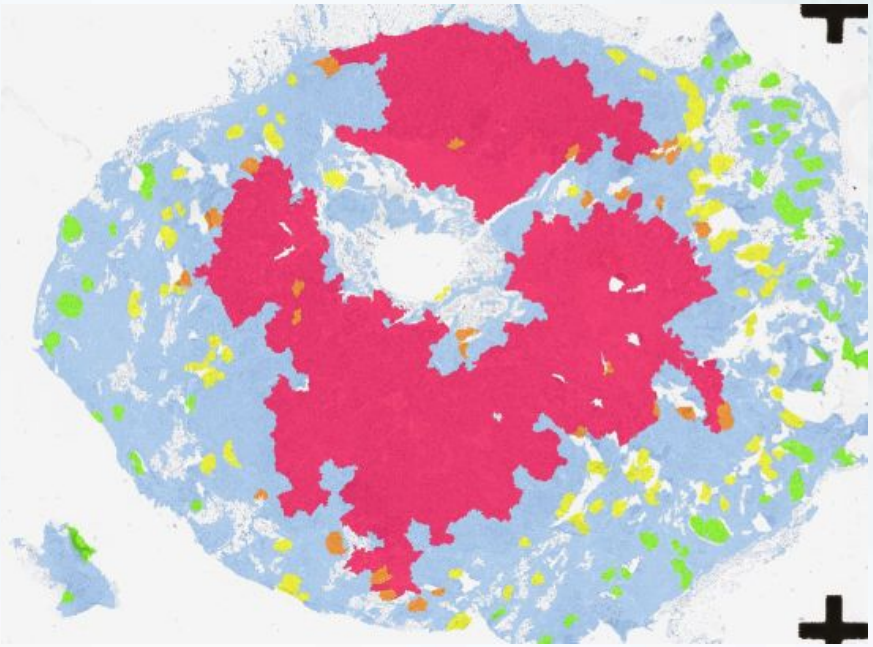

red: tumor
orange: adjacent lobules, distance < 0.5 mm
yellow: intermediate lobules, distance 0.5-2 mm
green: distant lobules, distance > 2 mm

- Lobule positivity in relation to tumor distance

Results

- quality of lobule detection
  - of 12 test cases 4 had acceptable detection quality
    - ER: correctness 81-89%; completeness 62-90%
    - PR: correctness 46-66%; completeness 30-75%
  - lower quality in images with massive inflammation in lobules – not consistent with model (round structure, tubular substructures)

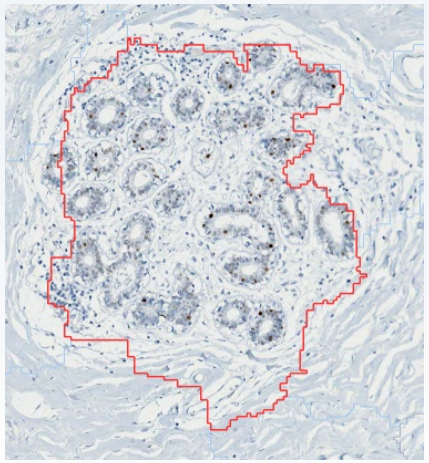
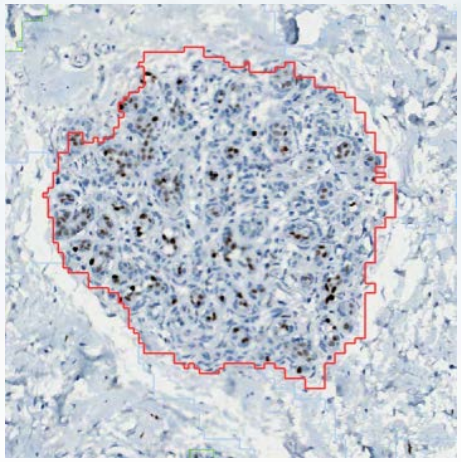

correctly detected

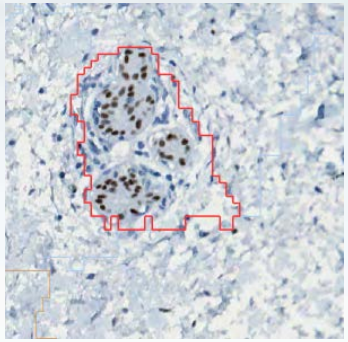

missed (too small)

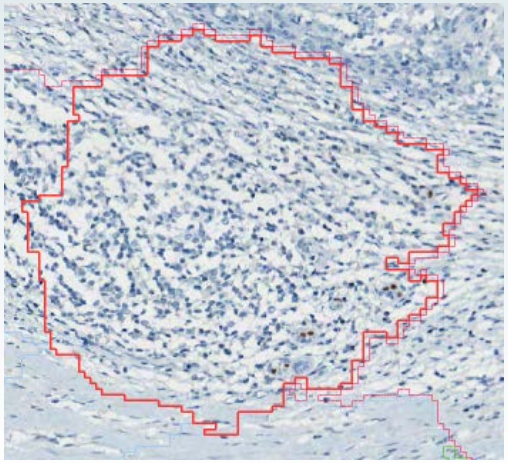

falsely detected
(similar structural properties)

Results

› lobule positivity distribution: average positivity by distance

ER	Case 1	Case 2	Case 3	Case 4	Case 5	Case 6
adjacent lobules	7%	11%	-	10%	3%	5%
intermediate lobules	14%	17%	26%	13%	5%	7%
distant lobules	20%	14%	28%	15%	7%	17%

PR	Case 1	Case 2	Case 3	Case 4	Case 5	Case 6
adjacent lobules	6%	3%	12%	0%	4%	5%
intermediate lobules	11%	11%	9%	0%	8%	7%
distant lobules	11%	7%	10%	1%	11%	7%



Results

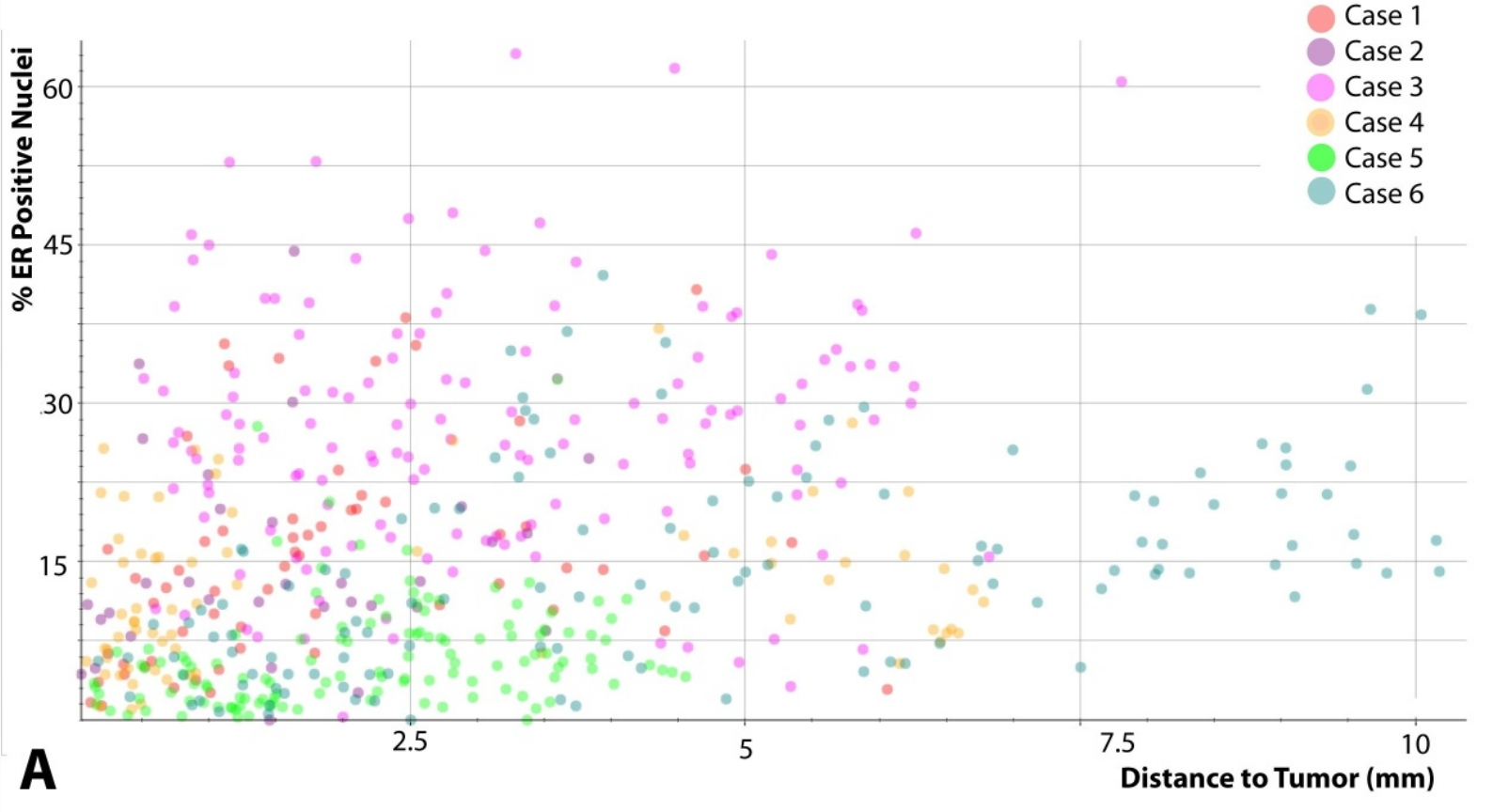
Case 1
Case 2
Case 3
Case 4
Case 5
Case 6
% ER Positive Nuclei
60
45
30
15
2.5
5
7.5
10
Distance to Tumor (mm)
A

Outlook

- Improve tumor classification
  - Cover a broader range of variable tumor morphology
  - Include modular analysis tools for ER positive tumors
  - Increase robustness of tumor features, particular focus on tumor margins
- Expand analysis of lobules
  - Cover a broader range of lobule shapes and sectioning levels
  - Capture variable epithelial morphology, e.g. due to menstrual cycle phase, menopause, previous anti-hormonal treatment
  - Increase robustness of lobule detection in the presence of inflammatory infiltration
- Further reduce need for manual interaction
  - Develop a standardized approach for quality control (e.g., QC images)
  - Define a corridor of statistically robust detection quality to optimize rule set

Summary

- Feasibility: In whole slide images of breast cancer, stained for nuclear markers (e.g., ER/PR)
  - Lobules can be detected at low resolution with a multilevel segmentation strategy
  - Nuclear positivity can be evaluated in automatically outlined ROIs determination of within each lobule in high resolution
  - Distance metrics can be applied to each object, e.g. positively stained nuclei, or average positivity per lobule in relation with distance to tumor
- Current Limitations: Tumor variability and inflammation
  - Method works well in tumors with coherent tumor masses and moderate inflammatory tumor microenvironment
  - Inflammatory changes and broader tumor variability requires adjustments

Acknowledgements

- Group Lundin at Fimm
- Institute for Pathology at MHH
- Angelika Fuchs, Roche Pharma Research and Early Development Information Technologies (pREDi), Penzberg, Germany
- Adam Nopora, Discovery Oncology, pRED Penzberg, Germany
- Hans-Joachim Müller, Discovery Oncology, pRED Penzberg, Germany
- Juliane Krüger, Definiens AG, München, Germany
- Funded by the Roche Postdoc Fellowship (RPF) program.