


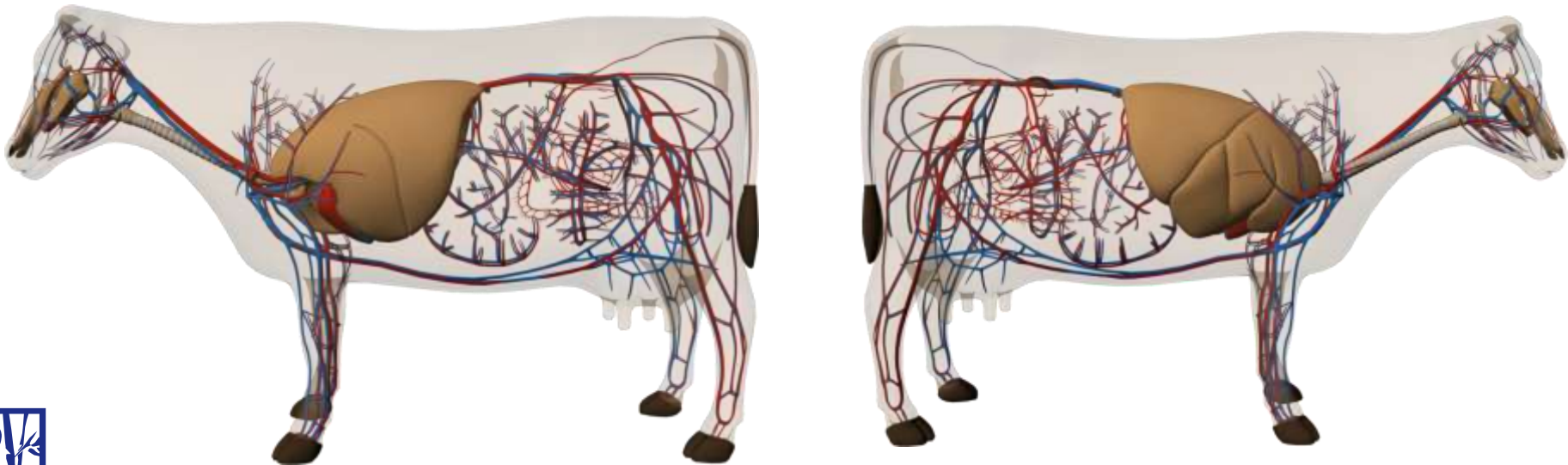
Auscultation: Lungs, Heart, GI Tract


October 2011





Auscultation of the Respiratory System






Bovine Lung Field

- **The bovine lung field is relatively small**
- **Breath sounds can heard in a triangle formed by:**
 - the triceps cranially,
 - the attachment of the ribs to the vertebral column dorsally
 - an imaginary line joining the point of the elbow with the eleventh intercostal space
- **Lung sounds are loudest in mid thorax**






Auscultation of the Respiratory System

- **Auscultation of the respiratory system includes listening to the trachea and lungs**
- **Normal respiratory rates ruminants are very similar**
 - **Cattle: 18 – 35**
 - **Calf: 20 – 40**
 - **Goat: 15 - 30**
 - **Kid: 20 - 40**
 - **Sheep: 12 - 20**
 - **Kid: 20 – 40**
- **Abnormal sounds**
 - **Crackles, wheezes, bronchial sounds**

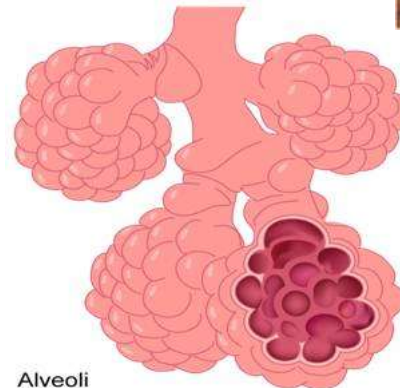
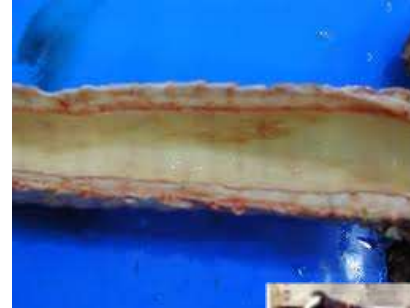





Auscultation of the Respiratory System

- **Normal sounds**

- Trachea
 - Large airway sounds are normally sound
 - Sound like air moving through a large tube
 - Less turbulence
- Lungs
 - Lung sounds are soft
 - Abnormal sounds are characterized as:
 - Crackles
 - Wheezes
 - Bronchial sounds

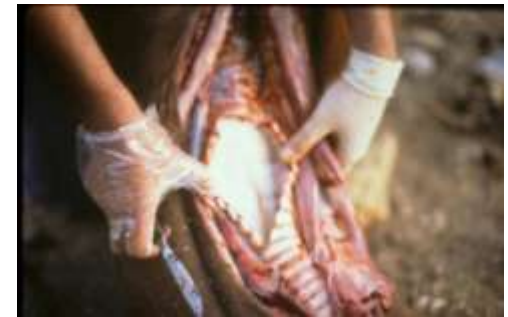


Alveoli



Abnormal Sounds: Trachea

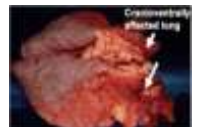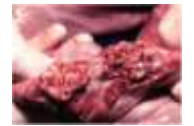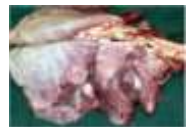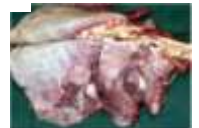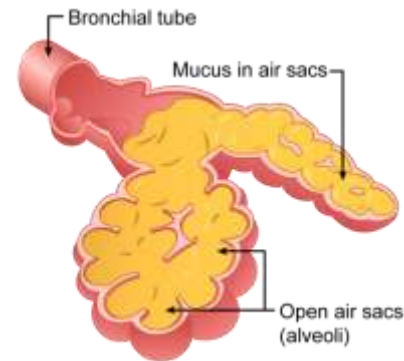
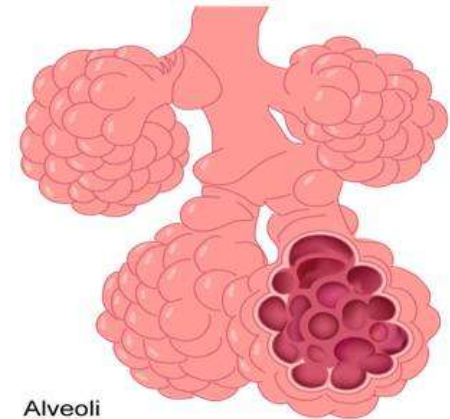
- **Abnormal tracheal sounds are often associated with narrowing of the upper airway and/or fluid accumulation in the trachea**
- **Disease that can result in tracheal pathology include:**
 - Necrotic laryngitis
 - Infectious bovine rhinotracheitis (IBR)
 - Parainfluenza 3
 - Pulmonary edema
 - Bronchopneumonia
 - Parasitic pneumonia
 - Aspiration pneumonia






Abnormal Breath Sounds: Bronchial Tones

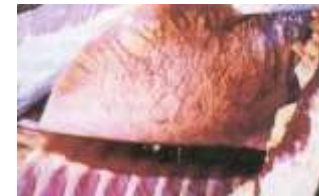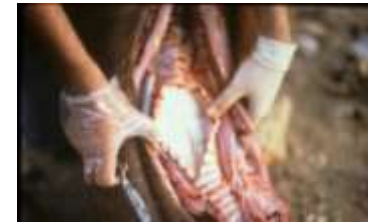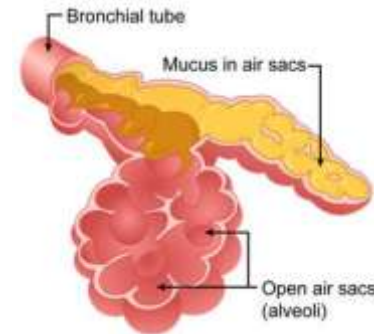

- **Bronchial tones are associated with:**
 - Consolidated lung
 - **Bronchopneumonia – cranial ventral consolidation**
 - Atelectasis
 - **Collapsed lung – prematurity, severe consolidation, pleural effusion**
- **Bronchial tones sound like tracheal sounds only not as loud**
- **Mostly heard in the cranial ventral area of the lung – best on the right side**
 - Bronchopneumonia pathogenesis






Abnormal Breath Sounds: Crackles

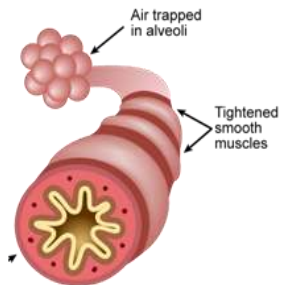
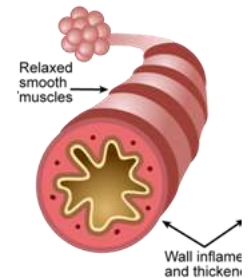
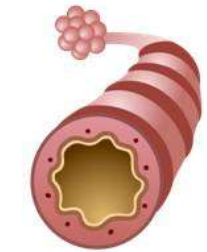
- **Crackles occur when fluid is present in the lower airways**
 - The fluid can be purulent or serous
 - Often heard with broncho- and viral pneumonias
- **Crackles are discontinuous sounds because their intensity fluctuates**
 - Fine crackles fluctuate rapidly in intensity - may be produced by airways snapping open
 - **Sometimes associated with emphysema**
 - Coarse crackles fluctuate more slowly and have a lower frequency
 - **Coarse crackles are produced by fluid movements within the larger airways.**






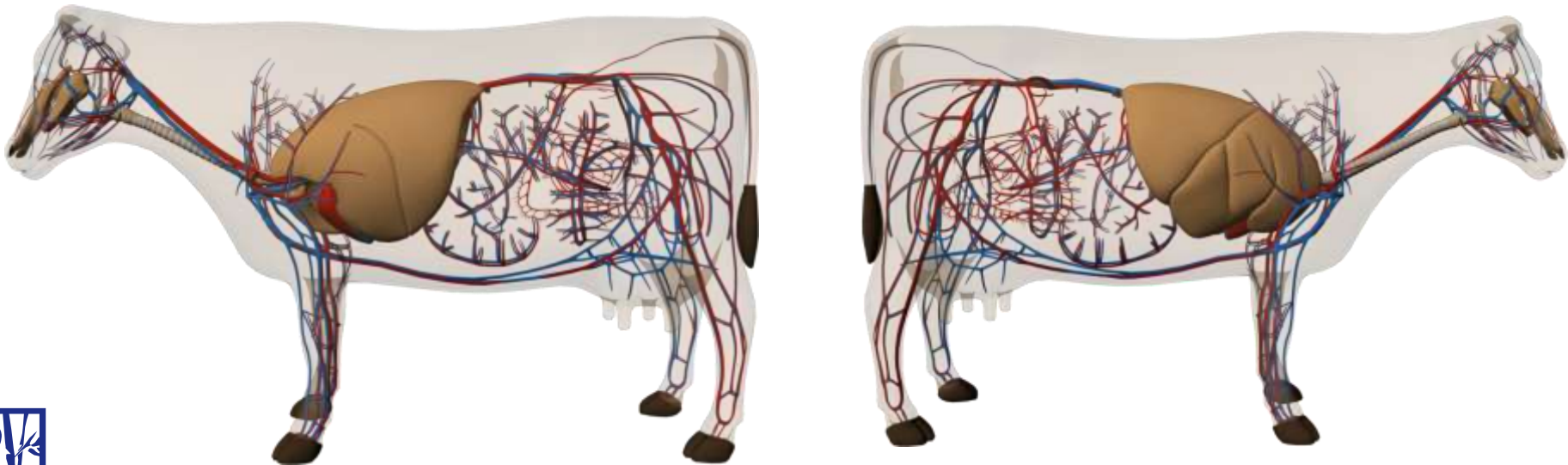
Abnormal Breath Sounds: Wheezes


- **Wheezes are created by narrowing of the airways**
 - Airways are narrowed by:
 - **Smooth muscle constriction**
 - **Mucous**
 - Wheezes can be heard in animals with allergic airway disease (asthma), viral pneumonia, bacterial pneumonia, and parasitic pneumonia
- **Wheezes can be described as continuous sounds because the intensity gradually decreases during their length**
- **Squeaks are sometimes regarded as a sub type of wheezing sounds.**





Auscultation of the Heart






Cardiac Auscultation

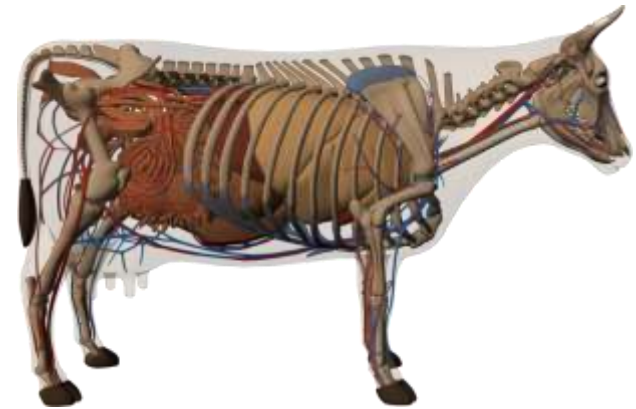
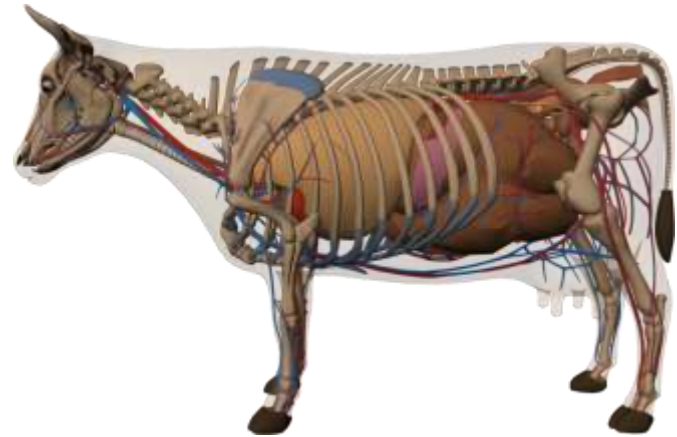
- **Heart sounds are best heard under the triceps/elbow between the 3rd and 5th intercostal spaces on the left side but can be heard on the right side**
 - The heart sounds are difficult to hear but if the stethoscope is pushed far cranially, under the elbow, the heart sounds are audible
 - Usually heart sounds are loudest on the left side when the stethoscope head is completely hidden by the triceps mass
- **The normal heart rate is 50 to 80 beats/minute**






Auscultation of the Heart: Normal Heart Sounds

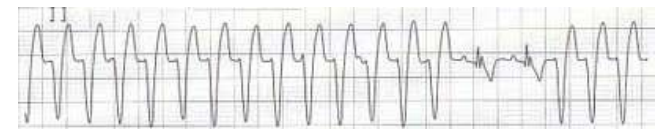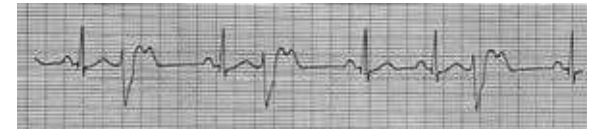
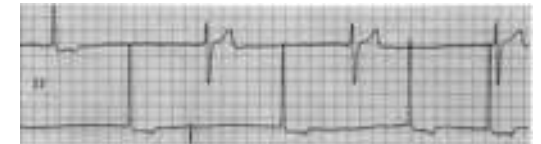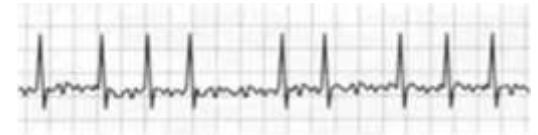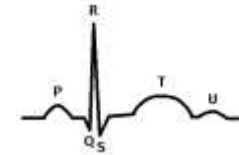
- **Only the first two sounds heart sounds are heard**
 - S1 the first heart sound is the loudest and is associated with the closure of the atrioventricular valves
 - **It is loudest at the 4th intercostal space**
 - S2 is heard shortly after S1 and is associated with the closure of the aortic and pulmonic valves
 - **It is loudest at the 3rd intercostal space**






Auscultation of the Heart: Arrhythmias

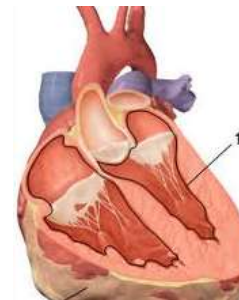
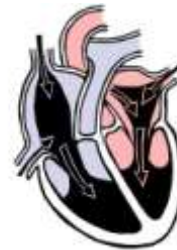- **Arrhythmias are disturbances in the normal heart rhythm**
 - Regularly irregular
 - **Bradycardia**
 - **Tachycardia**
 - **Premature ventricular contractions located in a single foci**
 - **Sinus bradycardia**
 - Irregularly irregular
 - **Atrial fibrillation**
 - **Paroxysmal supraventricular tachycardia**
 - **Ventricular tachycardia**
 - **Premature ventricular contractions**
 - In cattle arrhythmias are often associated with electrolyte imbalances
 - ***Hypokalemia***






Auscultation of the Heart: Murmurs

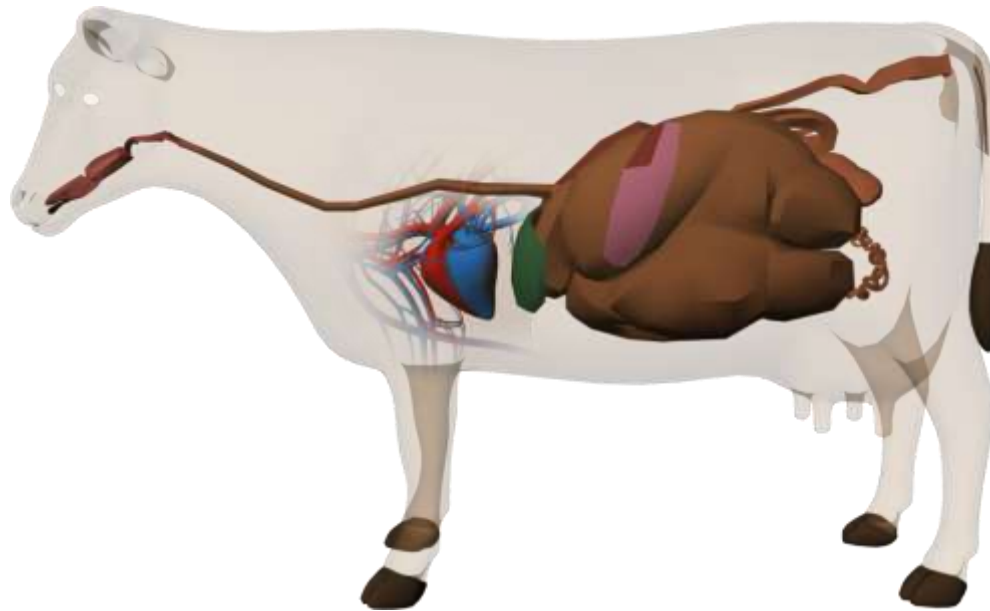
- **Murmurs are created by turbulent blood flow in the heart**
- **The most common causes of heart murmurs in cattle is endocarditis**
 - The intensity of the murmur will depend on location – AV valves, aortic, or pulmonic
- **Calves with foot and mouth disease may have cardiomyopathy, which may create a murmur**
- **Murmurs may also be heard with anemia, cardiomyopathy, and congenital anomalies such as ventricular septal and atrial septal defects**






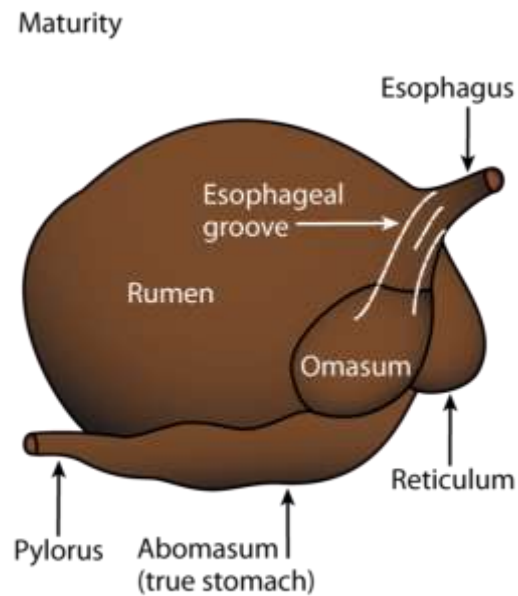
Auscultation of the Heart: Pericarditis


- **Traumatic reticulopericarditis (hardware disease) can create abnormal lung sounds**
 - Sloshing sound generated by an air – fluid interface
 - Only occurs if gas producing bacteria are present
 - **Most rumen flora are gas producing organisms**





Auscultation of the Gastrointestinal Tract






Gastrointestinal Auscultation

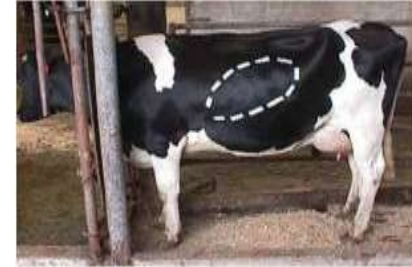- **Auscultation of the gastrointestinal (GI) tract should include the rumen, large and small intestines**
 - The rumen is the only distinct sound that can be heard
 - It will be heard best in the paralumbar fossa
 - A normal contraction will cause the rumen to bulge in the paralumbar fossa
 - Small and large bowel will sound similar and can be somewhat discerned by anatomy
 - Both can be heard on the right side
 - The spiral colon and cecum are best heard in the right paralumbar fossa






Gastrointestinal Auscultation: Abnormal Sounds

- **Tympanic sounds are heard when percussion and auscultation are done simultaneously**
 - **Caused by a gas filled viscous**
- **What are the most common causes of tympany on the left side?**





Gastrointestinal Auscultation: Abnormal Sounds

- What are the most common causes of tympany on the right side?

