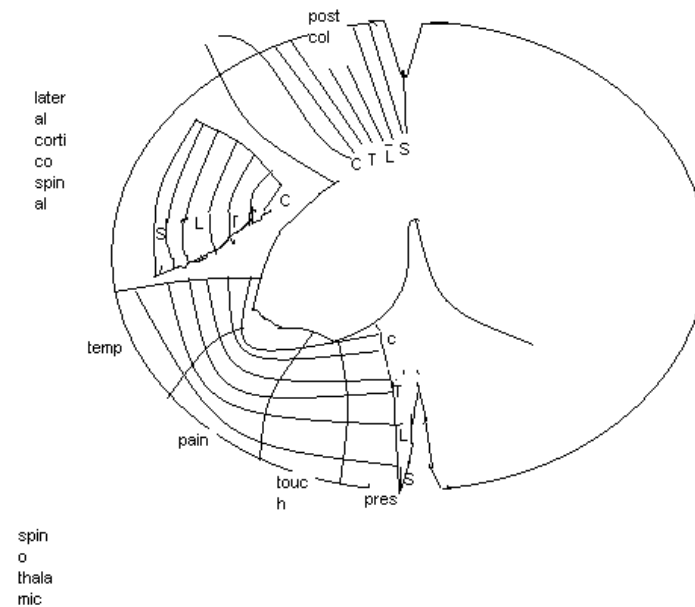


# Lesions of the spinal cord

---

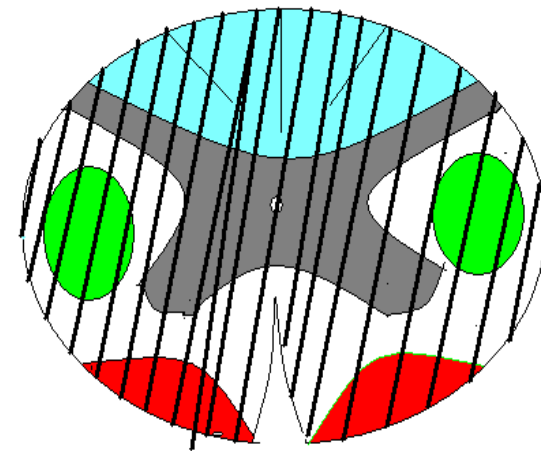
# Spinal cord lamination

---



# Complete spinal cord transection (Transverse myelopathy)

- All ascending tracts from below the level of the lesion and all descending tract from above the level of lesion interrupted.
- Motor , sensory, autonomic functions below the level of lesion disturbed
- Causes : traumatic spine injuries
  - tumour
  - multiple sclerosis
  - vascular disorders
  - spinal epidural hematoma/abscess
  - auto immune disease
  - herniated intervertebral disc
  - parainfectious/post vaccinal syndrome






---

□ Sensory disturbances:

- soft touch, pain, temperature, position, vibration impaired below the level of lesion
- band like radicular pain/segmental paraesthesia at the level of lesion
- localised vertebral spine pain- destructive lesions

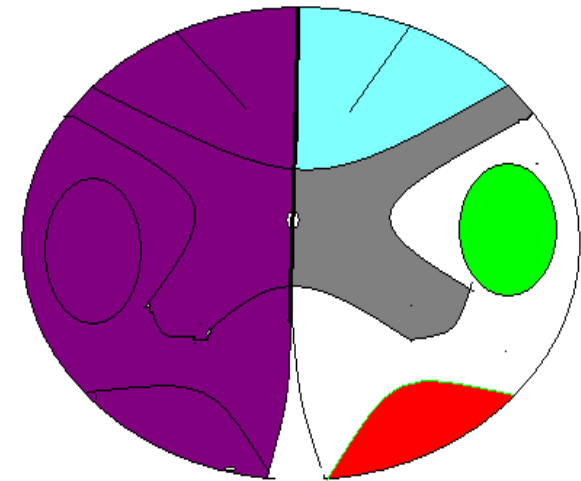
• Motor disturbances:

- paraplegia/quadriplegia
- acute- flaccid/areflexic-spinal shock
- latter- hypertonic/hyper reflexic, loss of superficial reflexes, babinski +, flexor/extensor spasm
- extension of hip , knee occurs in high spinal & incomplete lesion
- flexion of hip , knee occur in low spinal & complete lesion

- 
- 
- at the level of lesion – paresis, atrophy, fasciculations, and areflexia (LMN signs) in a segmental distribution because of damage to the anterior horn cells and ventral roots
  - Autonomic disturbances:
    - initially atonic, later spastic bladder, rectal sphincter disturbances
    - orthostatic hypotension
    - trophic skin changes
    - anhidrosis
    - impaired temperature control
    - vasomotor instability
    - sexual disturbances
    - I/L horner syndrome

# Hemisection of the spinal cord (Brown sequard syndrome)

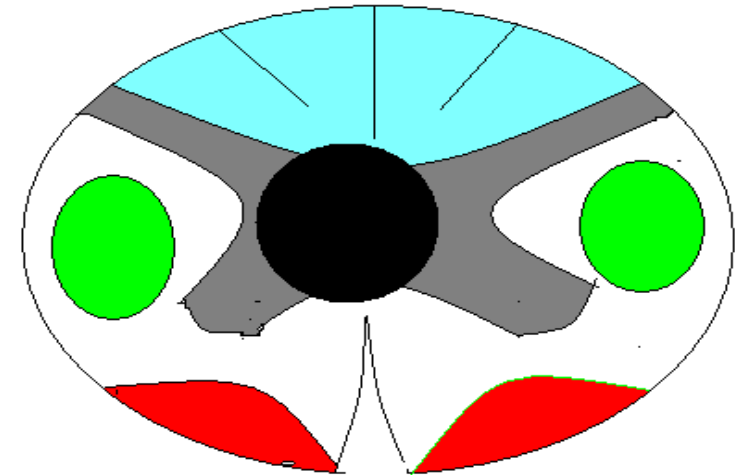
- ❑ Loss of pain, temp C/L to the hemisection- interruption of crossed spino thalamic tract
- ❑ I/L loss of proprioception – interruption of ascending fibers of posterior column
- ❑ I/L spastic weakness due to interruption of descending cortico spinal tract
- ❑ Segmental LMN signs and sensory changes at the level of lesion due to damage of the roots and anterior horn cells at the level of lesion



# Central spinal cord lesion

---

- ❑ Spinal cord damage starts centrally and spreads centrifugally
- ❑ Decussating fibers of spinothalamic tract involved initially
- ❑ Thermo anaesthesia, analgesia a "vest like" or "suspended" bilateral distribution with preservation soft touch sensation and proprioception--- dissociation of sensory loss



- 
- Forward extension of disease  
anterior horn cells inv- segmental neurogenic atrophy, paresis, areflexia
  - Lateral extension  
I/L horner syndrome  
kypho scoliosis  
spastic paralysis
  - Dorsal extension  
I/L position sense, vibratory loss
  - Extreme venterolateral extension  
thermo anaesthesia, analgesia with sacral sparing
  - Neuropathic arthropathy
  - Pain



# Acute cervical central spinal cord syndrome

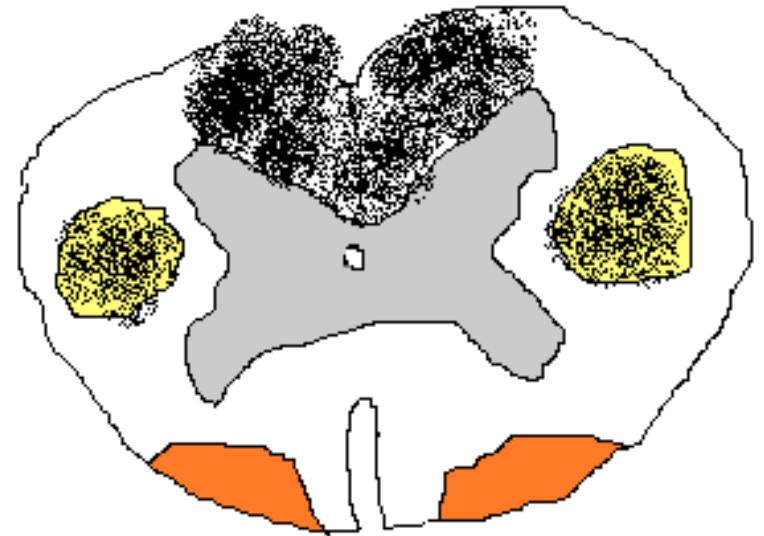
---

- ❑ Severe hyper extension injuries of neck
- ❑ Pt becomes quadriplegic after trauma, and regains strength in hours even in mnts
- ❑ Urinary retention
- ❑ Patchy sensory loss below the lesion
- ❑ Weakness more in arms, more distal than proximal
- ❑ “man in a barrel syndrome”
- ❑ Considerable recovery
- ❑ Due to damage of central grey matter, lateral cortico spinal tract at cervical enlargement

# Postero lateral column disease

---

- ❑ SACD- B12 def
- ❑ Vacuolar myelopathy-  
AIDS-HTLV 1, tropical  
spastic paraparesis
- ❑ Cervical spondylosis  
-paraesthesia, difficulty with  
gait , balance, loss of  
vibration and  
proprioception, sensory  
ataxia, rombergs +, bladder  
atony, reflexes lost or hypo  
active – super imposed  
peripheral neuropathy



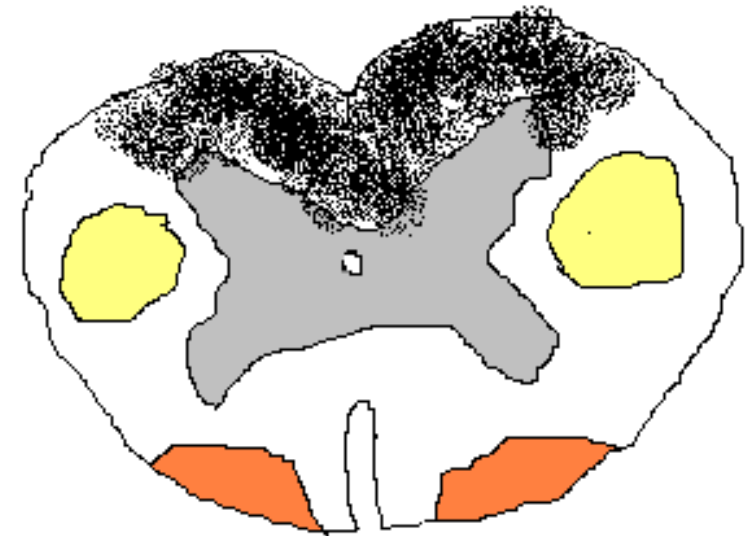# Posterior column disease

---

- ❑ Tabes dorsalis- tabetic neuro syphilis, progressive locomotor ataxia
  - ❑ Impaired vibration and position sense, and decreased tactile localisation
  - ❑ Lability of mechanical sensation threshold, tactile & postural hallucinations, persistence of mechano receptor sensation, disturbances in the knowledge of extremity movement and positions( temporal & spatial disturbances)
  - ❑ Sensory ataxia in dark, romberg +
  - ❑ Ataxic / stomping/ double tapping gait
  - ❑ Positive sink sign
  - ❑ In tabes dorsalis- lancinating pain, urinary incontinence, -ve patellar and ankle DTR, hypotonic limb, hyper extensible joints
- abdominal , laryngeal crises
- Abadie's sign , impaired light touch perception in hitzig zone
- Argyll robertson pupil, optic atrophy, ptosis, ophthalmoplegia

Lhermitte sign or barber chair syndrome due to increased mechano sensitivity

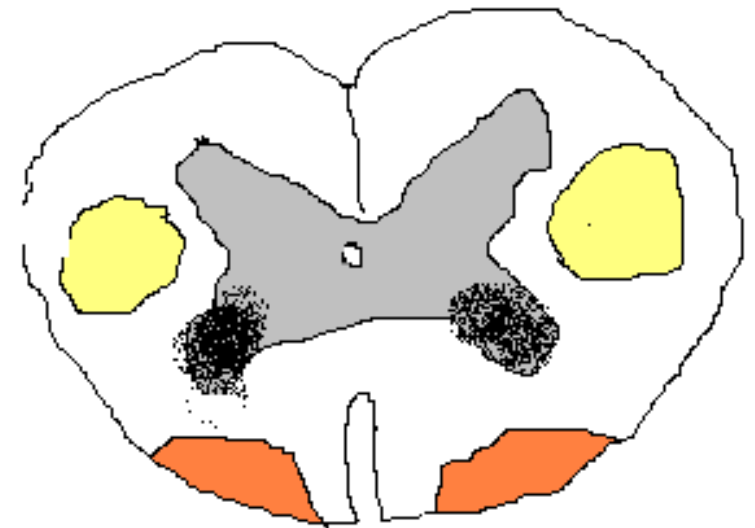
Truncal and gait ataxia : also seen in mets causing cord compression  
impaired conduction in dorsal spino cerebellar tract  
may be a primary manifestation of epidural spinal cord compression- lower extremity dysmetria and gait ataxia, pt usually have thoracic spine compression due to selective vulnerability of spinocerebellar tract in thoracic spine to compressive ischemia



# Anterior horn cell syndrome

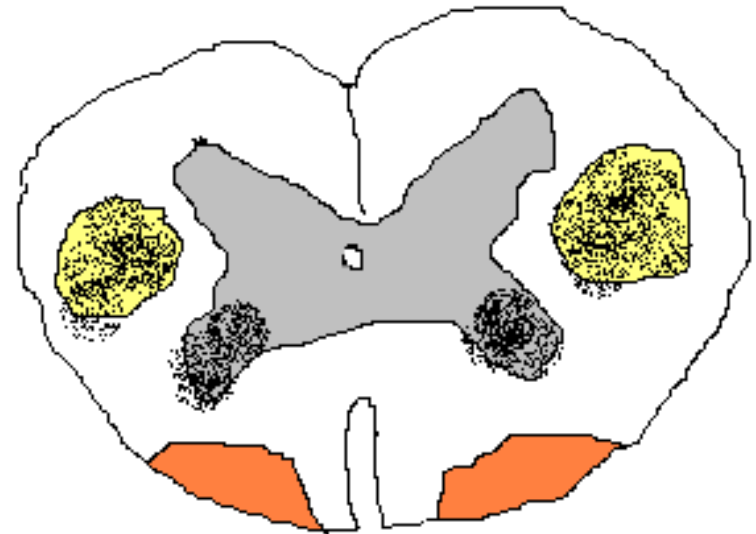
---

- Anterior horn cell, cranial motor nuclei involved
- Autosomal recessive spinomuscular atrophy
- Diffuse weakness and atrophy, fasciculations of trunk and extremities
- Muscle tone & DTR ↓
- Sensation intact



# Combined anterior horn cell and pyramidal tract disease

- ❑ Progressive diffuse LMN signs with UMN dysfunction
- ❑ Striated muscles except pelvic floor muscles affected
- ❑ U/L, muscles of hands and foot are involved
- ❑ Sparing rectal and urethra sphincter
- ❑ Bulbar and pseudobulbar inv super imposed





# Vascular syndromes of spinal cord

---

□ Anterior spinal artery syndrome:

Territory – anterior funiculi, anterior horn, base of the dorsal horn, periependymal area, antero medial aspect of lateral funiculi

Lower thoracic segment and conus- vulnerable

Abrupt onset of radicular pain, girdle pain

Flaccid quadriplegia, paraplegia

Bowel bladder dysfunction

Thermo anaesthesia analgesia

Position vibration light touch preserved

Painful burning dysaesthesia

Watershed boundary zone T1-T4, L1, central white matter of anterior funiculi



---

□ Venous spinal cord infarction:

Impaired venous drainage, insitu thrombosis

Retrograde emboli

Chronic venous hypertension- irreversible spinal injury

Slowly progressive myelopathy, varying degrees of pain and sensory disturbances in the extremities, bladder bowel disturbances





---

□ Posterior spinal artery syndrome:

Uncommon

Loss of position , proprioception, vibration

Loss of segmental reflexes

Pain , temperature – preserved

Motor function- preserved

Rarely – U/L posterior horn, lateral spinal cord inv

□ Lacunar infarct:

Isolated focal motor/sensory deficits in extremities

□ Hypoxic myelopathy:

Slowly progressive paraparesis/quadriparesis

□ Hemodynamic TIA:

spinal cord claudication

# Localisation of spinal cord lesion at different levels

---

## □ Foramen magnum syndrome & lesions of upper cervical cord:

Sub occipital pain in C2 distribution, neck stiffness, electric shock like sensation


sub occipital paraesthesia, syringo myelic type of sensory dissociation, finger tip numbness and tingling

Spastic tetraparesis, long tract sensory findings, lower cranial nerve palsy

“around the clock presentation of UMN type of weakness

foramen magnum lesion- down beat nystagmus, papilloedema ,cerebelar ataxia

causes: tumour, cx spondylosis, basilar invagination in pagets disease , syrx, C1C2 subluxation, chiari, MS



---

Pyramidal tract decussates at cervicomedullary junction  
lesion at this place causes HEMIPLEGIA  
CRUCIATA, onion skin pattern of facial sensory  
loss, respiratory insufficiency, bladder dysfunction

Compressive lesion of C1-C5 cord segment may  
compromise the cranial nerve 11

C3-C5 lesion produces diaphragmatic paralysis

High cervical cord lesion- respiratory arrest



---

□ Lesions of C5-C6:

LMN signs at corresponding segment level. UMN sign below the lesion,  
LMN paresis of arm associated with spastic para paresis of lower  
extremities.

C5 level:

Diaphragmatic function compromised

BJ&BRJ -ve

TJ & FFR ++++

Inversion of brachio radialis reflex

Sensory loss entire body below neck and anterior shoulder

C6 level:

BJ, BRJ, TJ -ve & FFR ++++

Sensory loss same as that of C5 lesion sparing the lateral part of arm



---

□ Lesion at C7:

Diaphragm fn normal

Paresis of flexors and extensors of wrist and fingers

BJ, BRJ-Normal, FFR++++

Paradoxical triceps jerk

Sensory loss at /below 3<sup>rd</sup> 4<sup>th</sup> finger

□ Lesion at C8 T1:

Weakness of small muscles of hands with spastic paraparesis

C8 inv- TJ & FFR-ve

T1 inv-TJ –Normal, FFR-ve

U/L or B/l horner syndrome

Sensory loss starts from fifth digit



---

□ Lesion of thoracic segment level:

Root pain , paraesthesia mimicking intercostal neuralgia

Segmental LMN paralysis

Paraplegia and sensory loss below a thoracic level

Bladder, bowel sexual dysfunction

Lesion above T5- orthostatic hypotension, episodic autonomic dysreflexia

Lesion at T10- +ve Beevors sign

Lesion at T6- abdominal reflex –ve

Lesion at T10 – upper, middle part +ve

Lesion at T12- abdominal reflex intact

---

□ Lesion at L1:

All muscles of lower extremities – weak

Lower abd musc- Internal oblique, tr abd weak

Sensory loss – both lower limbs up to groin, to a level above buttocks

Chronic lesion- patellar++++, ankle++++

□ Lesion at L2:

Spastic paraparesis

Cremasteric reflex↓↓, patellar reflex ↓↓

Ankle jerk +++++

Sensation in upper anterior aspect preserved



---

□ Lesion at L3:

Some preservation of hip flexion, adduction

KJ ↓↓, ankle++++

Sensation upper anterior aspect of thigh normal

□ Lesion at L4:

Better hip flexion, adduction

Able to stand stabilising knee

KJ↓↓, ankle++++

Sensation normal in anterior aspect of thigh, superomedial aspect of knee

□ Lesion at L5:

Normal hip flexion, adduction

KJ- normal, ankle++++ pt extends knee against resistance

Sensation normal in antr aspect of thigh, medial aspect of legs ankle and sole





---

□ Lesion at S1:

Weakness of triceps surae, flexors of foot, and small muscles of foot

Ankle reflex↓↓, KJ-normal

Sensory loss- sole, heel, outer aspect of foot and ankle, medial aspect of calf, posterior thigh, outer aspect of saddle area also anaesthetic

□ S2 lesion:

Triceps surae spared, flexors of toes, small muscles of foot weakness

Ankle jerk ↓↓

Sensory loss- upper part of dorsal aspect of calf, dorsolateral aspect of thigh and saddle area



# Conus medullaris lesion

---

Pelvic floor weakness, early sphincter dysfunction

Autonomous neurogenic bladder

Constipation, impaired ejaculation and erection

Symmetric saddle anaesthesia

Pain

Tethered spinal cord:

- numbness feet

- asymmetric muscle atrophy of calf and thigh, UMN signs, bowel bladder dysfunction, foot deformities, cutaneous manifestations of spinal dysraphism



# Cauda equina lesion

---

- ❑ Compression lumbar sacral roots below L3 vertebra
- ❑ U/L early radicular pain, worse at night
- ❑ Flaccid hypotonic areflexic paralysis producing peripheral paraplegia
- ❑ Asymmetrical sensory loss in saddle area
- ❑ KJ variable, ankle ↓↓
- ❑ Sphincter dysfunction similar to conus lesion but late

	Conus lesion	Cauda lesion
Spont pain	-ve, B/L	+ve, severe,
		Radicular, U/L
sensory	Saddle, B/L	saddle., U/L
deficit	dissociation	All forms affected
Motor loss	Symmetric,	Asymmetric , atro
	fasciculations	Phy, no fasciculn
DTR	Ankle -ve	KJ, ankle -ve
Bowel,bld	early	late
trophic	+ve	-ve
Sex fn	impaired	Less impaired
onset	Sudden. b/l	Gradual, u/l

signs	intramedullary	extramedullary
Radicular pain	unusual	common
Vertebral pain	unusual	common
Funicular pain	common	Less common
Umn Sign	+, late	+, early
Lmn sign	+++ , diffuse	Unusual, segmental
Paraesthesiae	descending	ascending
sphincter	early	late
Trophic	common	unusual