Imaging of scarring

Marco Romanelli, MD PhD

Wound Healing Research Unit

Department of Dermatology

University of Pisa

Introduction - 1

- Hypertrophic scars are the major long term problem for the post burn-injured patient

- Methods used to treat scars are based mainly around the use of custom made pressure garments and more recently, the use of adhesive and non-adhesive contact media

Introduction - 2

- Progress in the rational development of therapy methods will be dependent upon the use of more objective assessment

- Objective quantification of skin physical parameters through non-invasive techniques is an essential way to monitor hypertrophic scarring and the efficacy of related treatments

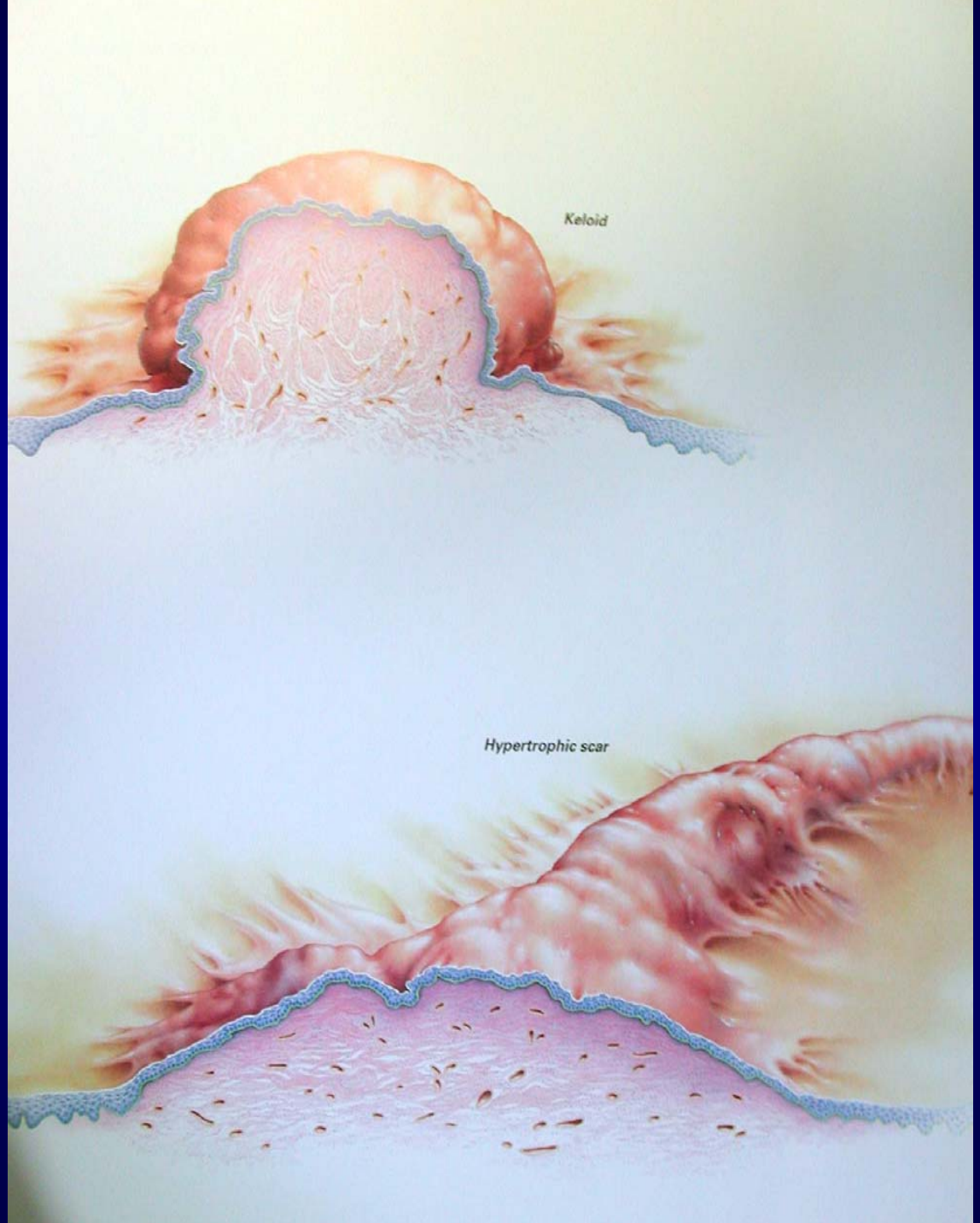
Keloid
Hypertrophic scar

“neither a disease nor a physiological process can be defined until it can be measured”

T. K. Hunt

Scars: morphological characterisitcs

- Thickness
- Width
- Colour
- Elasticity
- Temperature
- Hardness

Measurements on scars

- Simple
- Accessible
- Non - invasive
- Reliable
- Valid
- Easy to use in the clinical setting
- Reproducible
- Cost effective

Methods to assess scarring

- Ultrasound HF
- Cutometer
- Tonometer
- Laser Doppler
- $TcpO_2$
- Colorimetry
- Skin temperature

Frequency of assessment

- Too frequent assessment may lead to inappropriate changes in treatment plans
- Infrequent assessment may miss significant deterioration
- Most authors support formal assessment for scars every 4 weeks

?

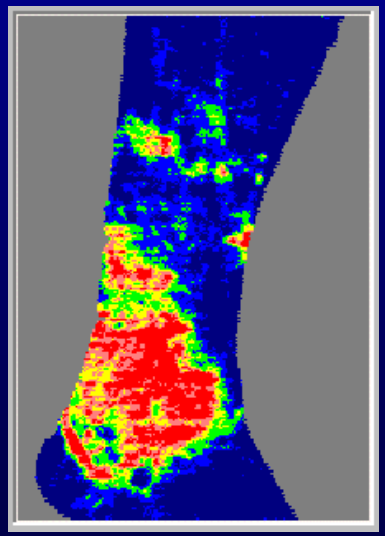


DermaTemp

Wound healing and TIME: new concepts and scientific applications

Schultz G., Mozingo D., Romanelli M., Claxton K

Wound Rep Reg 2005; 13(4 Suppl): S1-S11

TIME wound assessment tool®

Clinical observations	Proposed pathophysiology	Wound bed preparation non invasive measurement	Effect of wound bed preparation on measurements	Clinical outcome
Tissue	Defective matrix and cell debris impair healing	Debridement assessment: -colour assessment -tissue perfusion - TCP02, colour Doppler, angiography	-promotion of granulation tissue -improved wound bed vascularity	Viable wound tissue
Infection	High bacterial counts or prolonged inflammation: ↑ Inflammatory cytokines ↑ Protease activity ↓ Growth factor activity	Wound bed and surrounding skin: -temperature -odour -colour -pH	-controlled temperature -reduced odour -vital colour -acidic pH	Bacterial balance and reduced inflammation
Moisture	Excessive fluid causes maceration of wound margin. Desiccation slows epithelial cell migration.	Leg volume Colour of surrounding skin Surrounding skin trans epidermal water loss (TEWL)	-reduced leg volume -natural skin tones regained -reduced TEWL	Moisture balance
Edge	Non-migrating keratinocytes. Non-responsive wound cells and abnormalities in extracellular matrix or abnormal protease activity.	2D evaluation: -acetate tracing -digital photography -digital tools and PC software 3D evaluation -probes, moulds -scanning systems	Ability to determine healing progression Wound area is reduced. Wound depth is reduced.	Advancing epidermal margin. Wound stage decreased.

Imaging of scarring

- Laser Doppler imaging
- High frequency ultrasound
- Confocal microscopy
- Derma scanner

Laser Doppler Imaging

Principle: Doppler effect continuosly scanned to assess blood movement

Advantages: non contact measurement, large area

Measurement depth: dermis

Applications:

burn depth

blood flow in chronic wounds

scarring

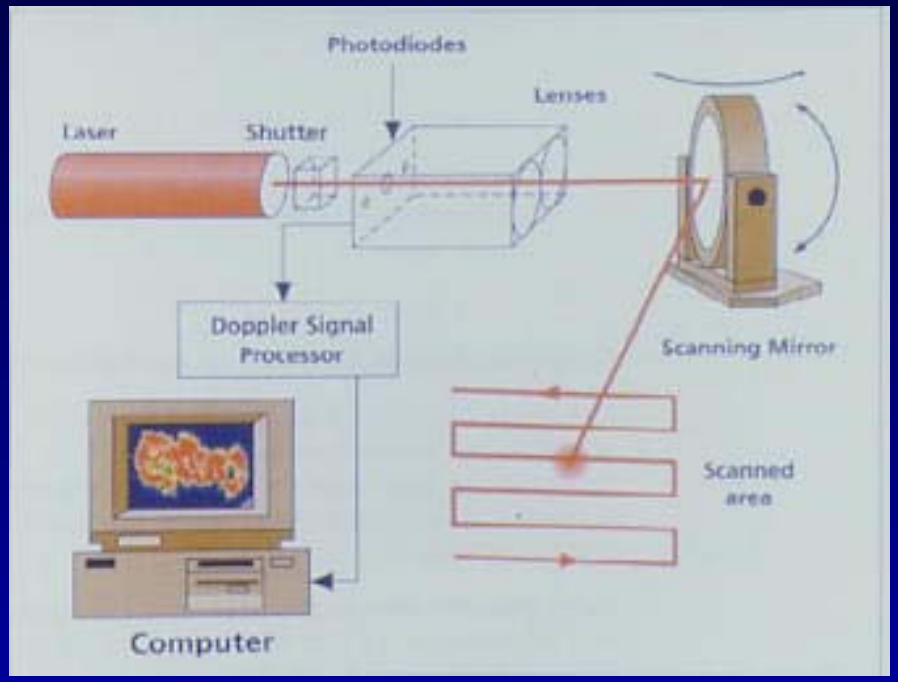

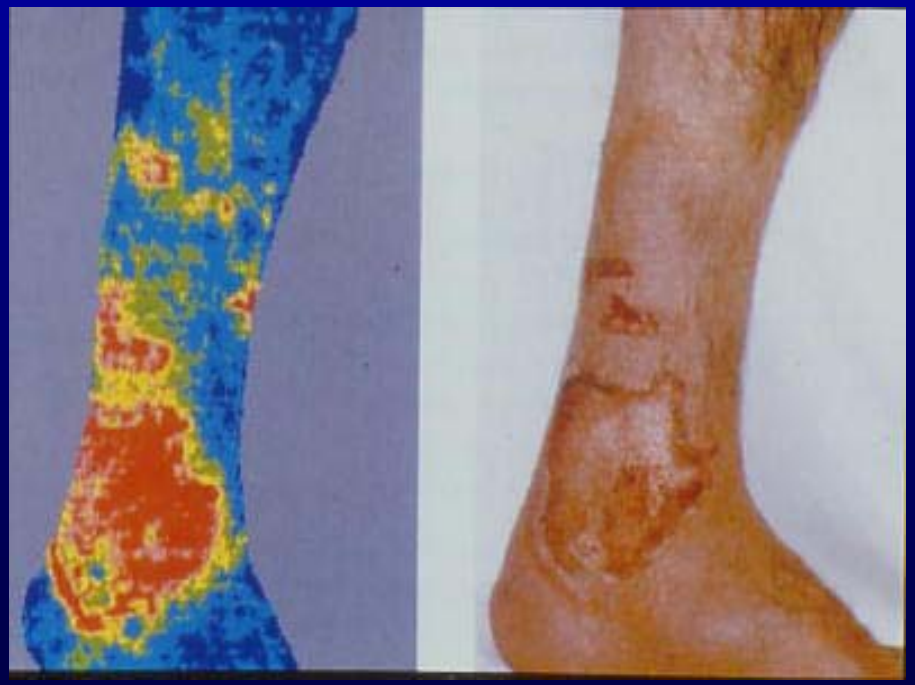

Laser Doppler imaging

Laser Doppler imaging of burn scars: a comparison of wavelength and scanning methods

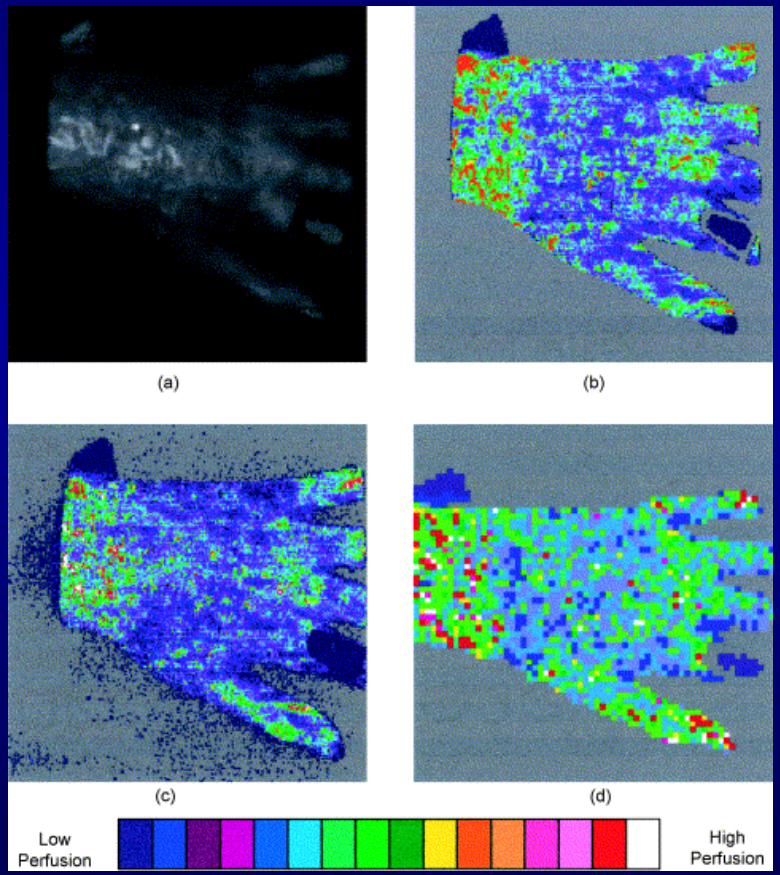

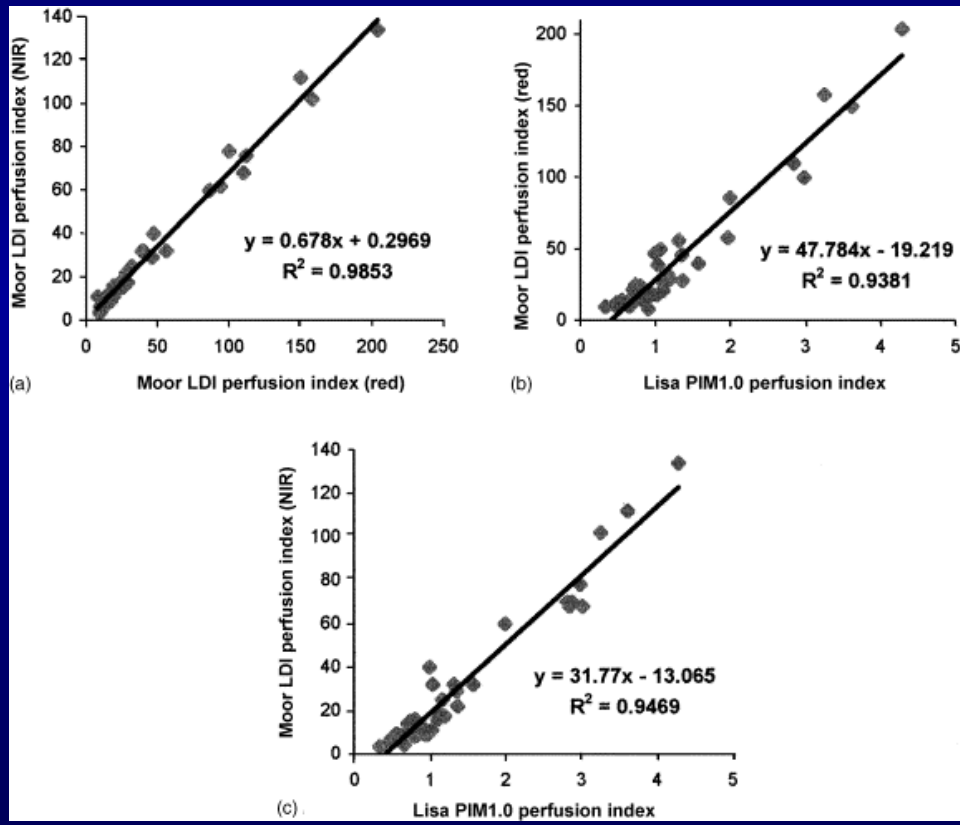

R. Bray et al. BURNS 2003; 29: 199-206

Imaging of scars before and after treatment

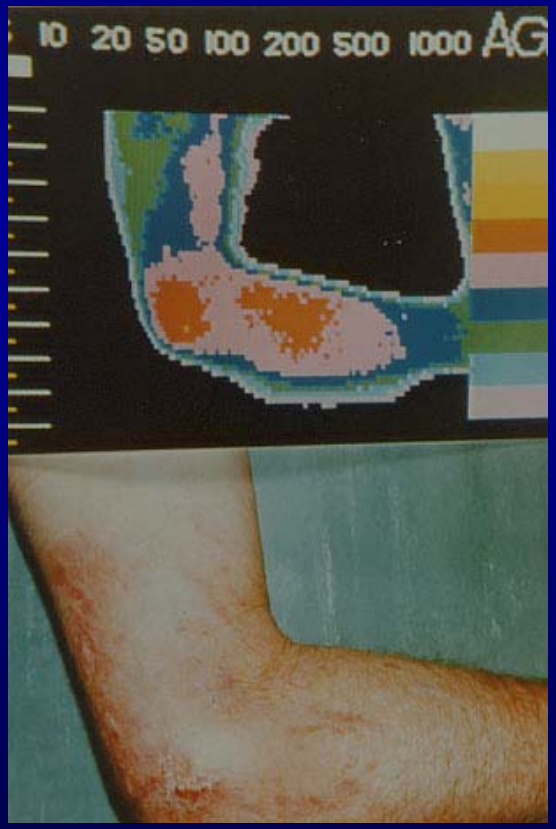

Imaging on Burns

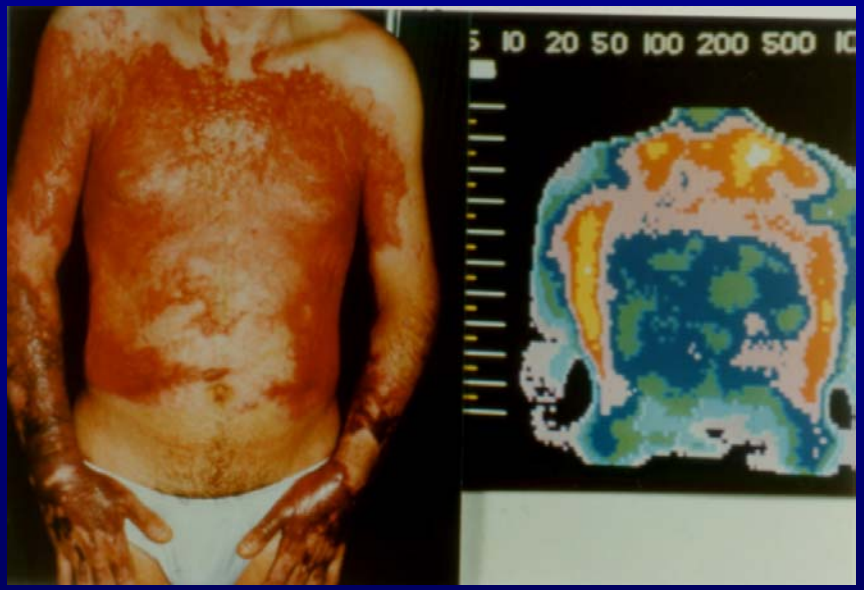

High frequency ultrasound

- A mode - B mode – 3D scanning
- 7.5 - 100 mHz
- rapid, non invasive, epidermis and dermis
- 3D wound bed evaluation
- oedema in venous leg ulcers
- scarring
- preoperative assessment of melanoma

High frequency ultrasound

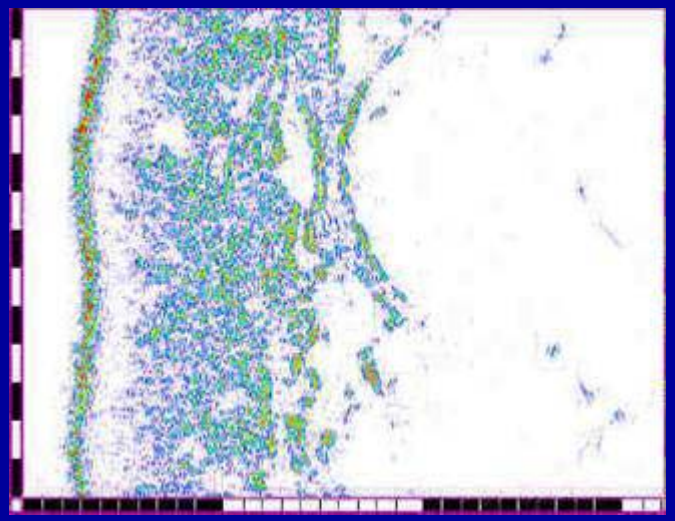



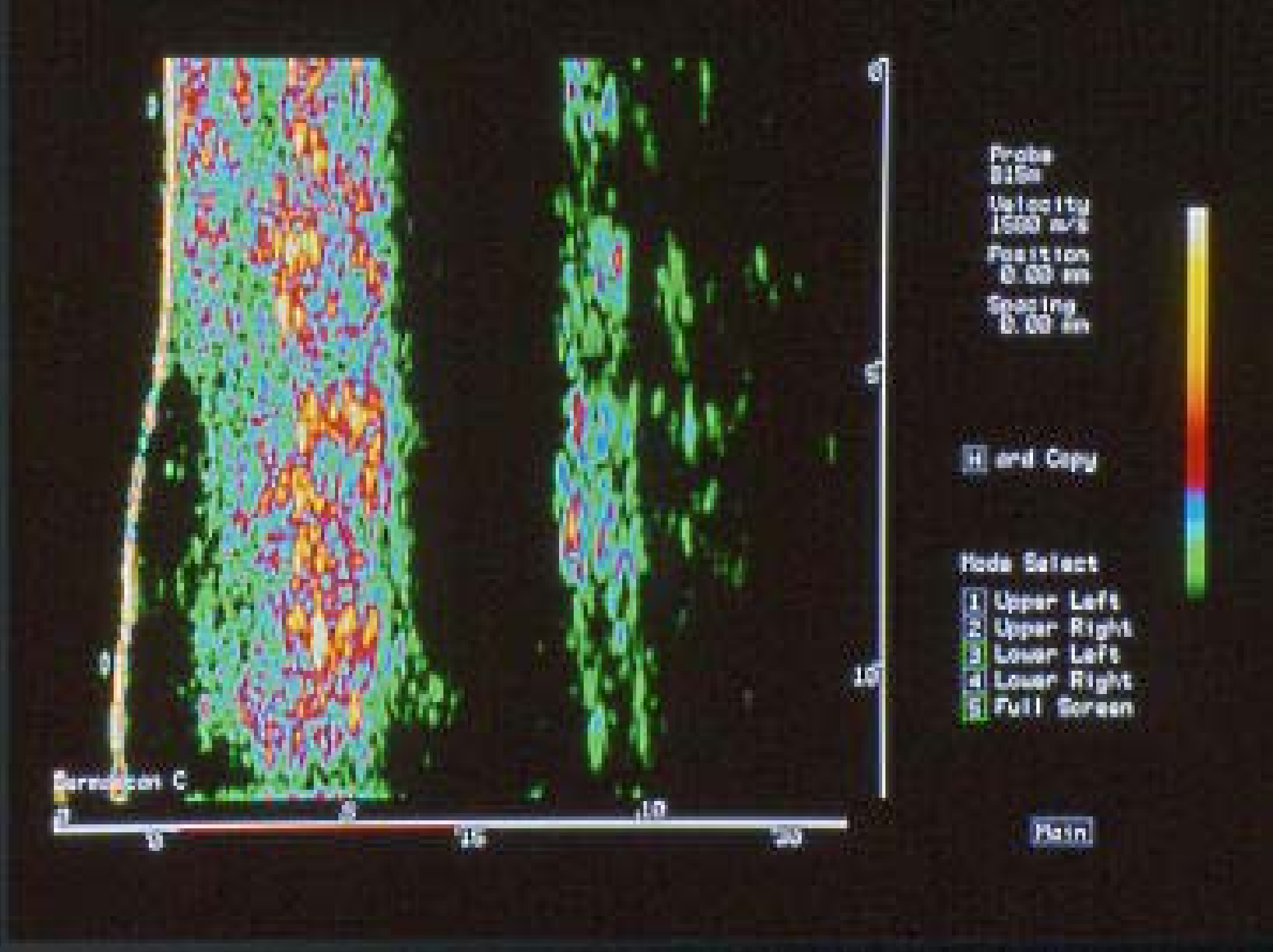
Probe
Velocity
1500 m/s
Position
0.00 mm
Spacing
0.00 mm
H ard Copy
Mode Select
1 Upper Left
2 Upper Right
3 Lower Left
4 Lower Right
5 Full Screen
Plain

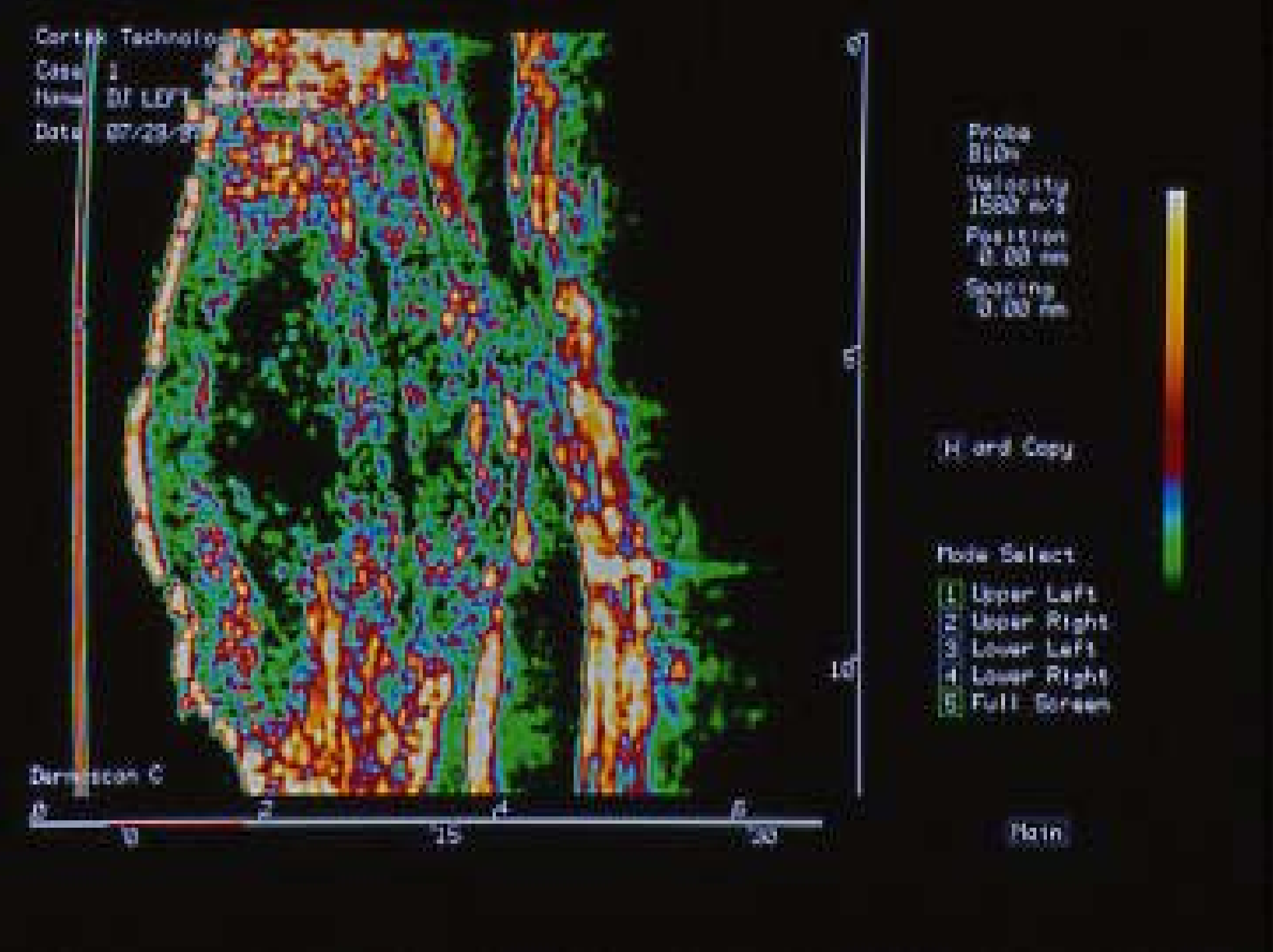
Case 1
Probe
810m
Velocity
1580 m/s
Position
0.00 mm
Spacing
0.00 mm
Hard Copy
Mode Select
1 Upper Left
2 Upper Right
3 Lower Left
4 Lower Right
5 Full Screen
Main
0
5
10
0
2
4
6
0
15
30

Ultrasound Densitometry

Patient	Age	Scar	Control
1	60	16.13	25.46
2	33	4.97	28.38
3	70	2.60	39.87
4	24	6.71	24.89
5	65	5.70	49.96

Bessonart MN. et al. Skin Research and Technology 2005; 11: 185-188

Scar Tissue

and

confocal microscopy

Principles of Confocal Microscopy

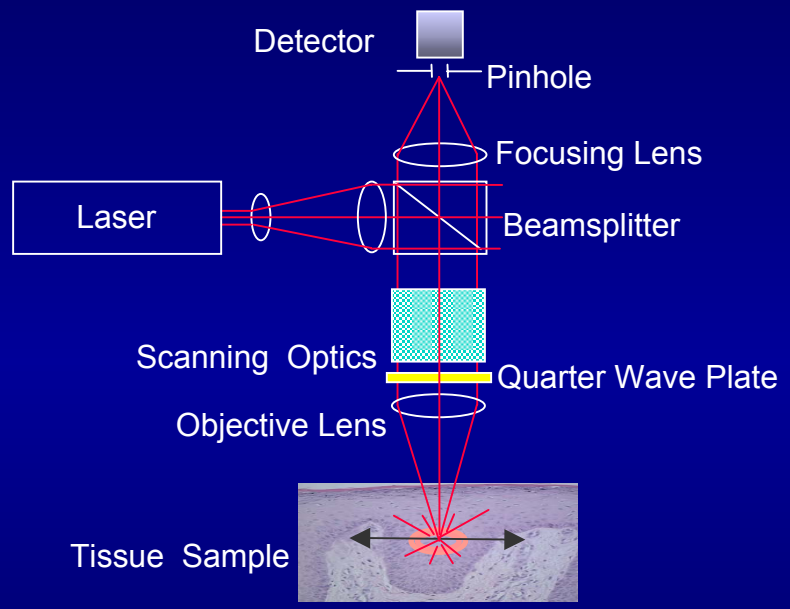

Confocal microscopy is an optical imaging technique that non-invasively images thin sections of tissue. Cellular and architectural detail, including nuclei, microvasculature and blood flow, are imaged in thin, *en face* sections without having to excise and process the tissue as in standard histology. The tissue morphology may be imaged either in vivo or freshly excised (ex vivo).

VivaScope® 3000 Confocal Microscope

The VivaScope® 3000 is a hand-held laser confocal microscope capable of video-rate imaging of living tissue at the cellular level. This device potentially can be used as an in vivo or intra-operative device to examine the morphological features and dynamic processes of tissue in real time. The non-invasive “optical biopsy” generated by the VivaScope provides medical practitioners with information that can be used as an adjunct to histology.

- Provides real time, video rate sample assessment
- Images cells in vivo for diagnostic and therapeutic research
- Allows for observation of a site over time to study progression of disease
- Assists in pre-operative and intra-operative margin evaluation

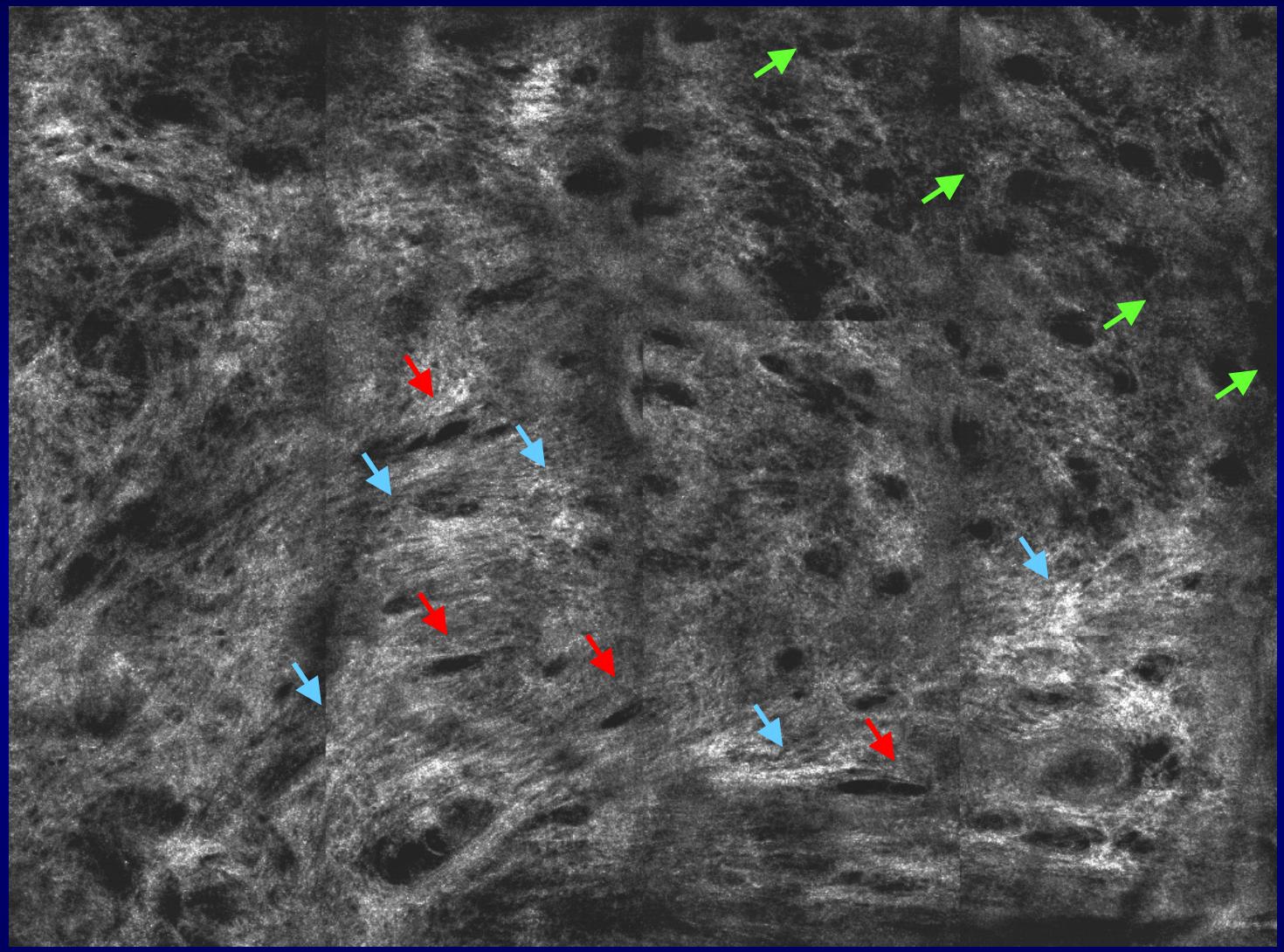

Composite map or VivaBlock measuring 2 x 1.5 mm taken at the top of the reticular dermis shows dense scar tissue (blue arrows) and elongated capillaries (red arrows) adjacent to a normal papillary dermis (green arrows).

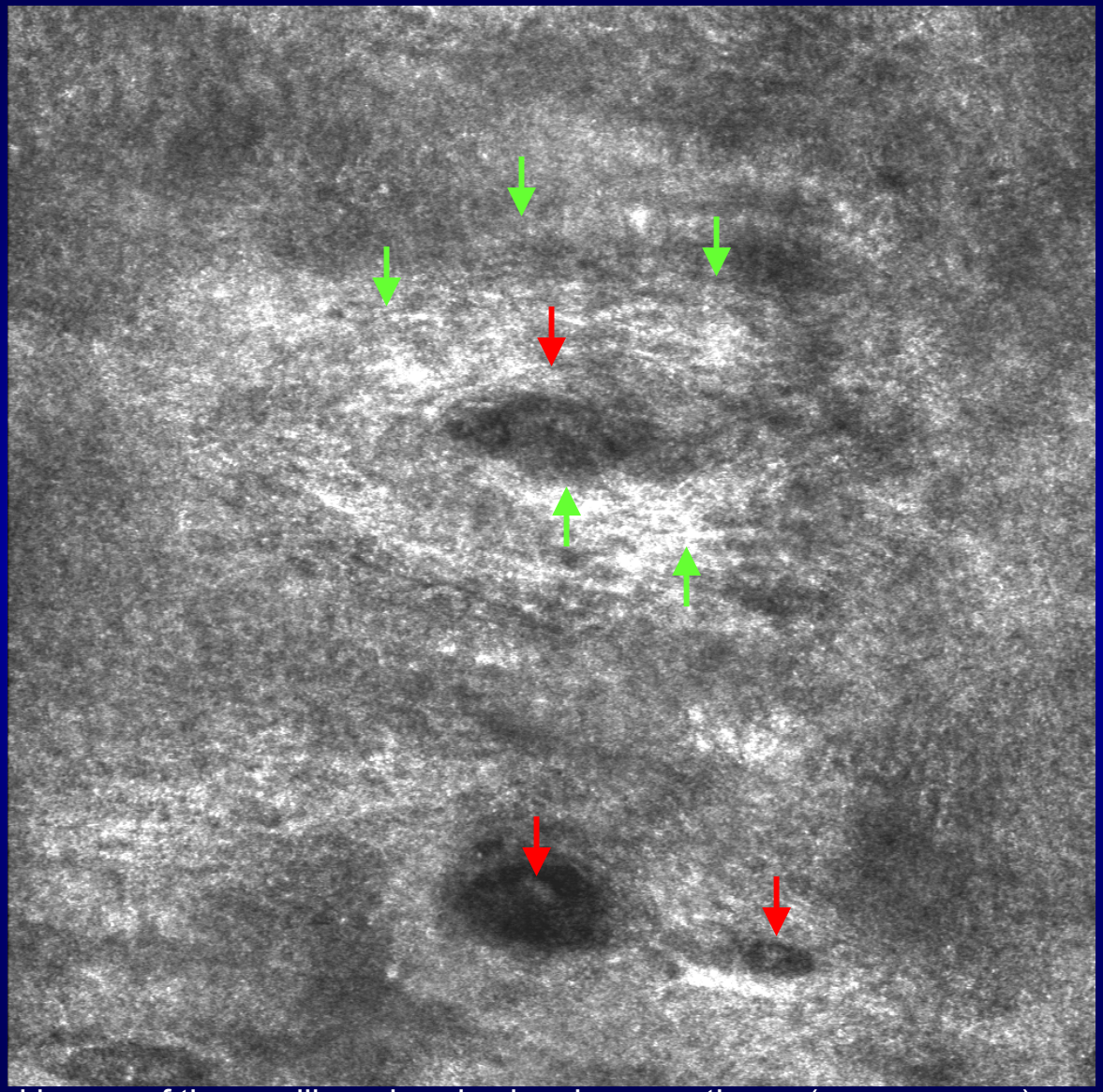

Confocal image of the papillary dermis showing scar tissue (green arrows) around the dermal papillae and blood cells (red arrows) flowing through the capillaries.

Field of view is 500 x 500 microns, 1000 x 1000 pixel resolution.

Normal vs. Scar

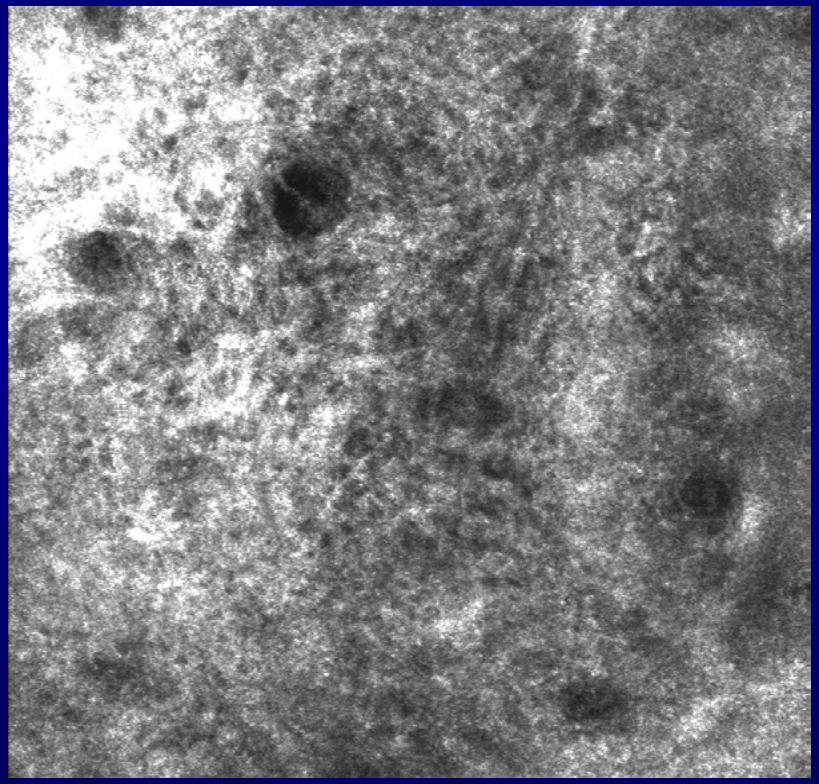



Confocal images of normal papillary dermis compared to scarred papillary dermis. Field of view is 500 x 500 microns, 1000 x 1000 pixel resolution.

3D scar analysis

3D scar analysis

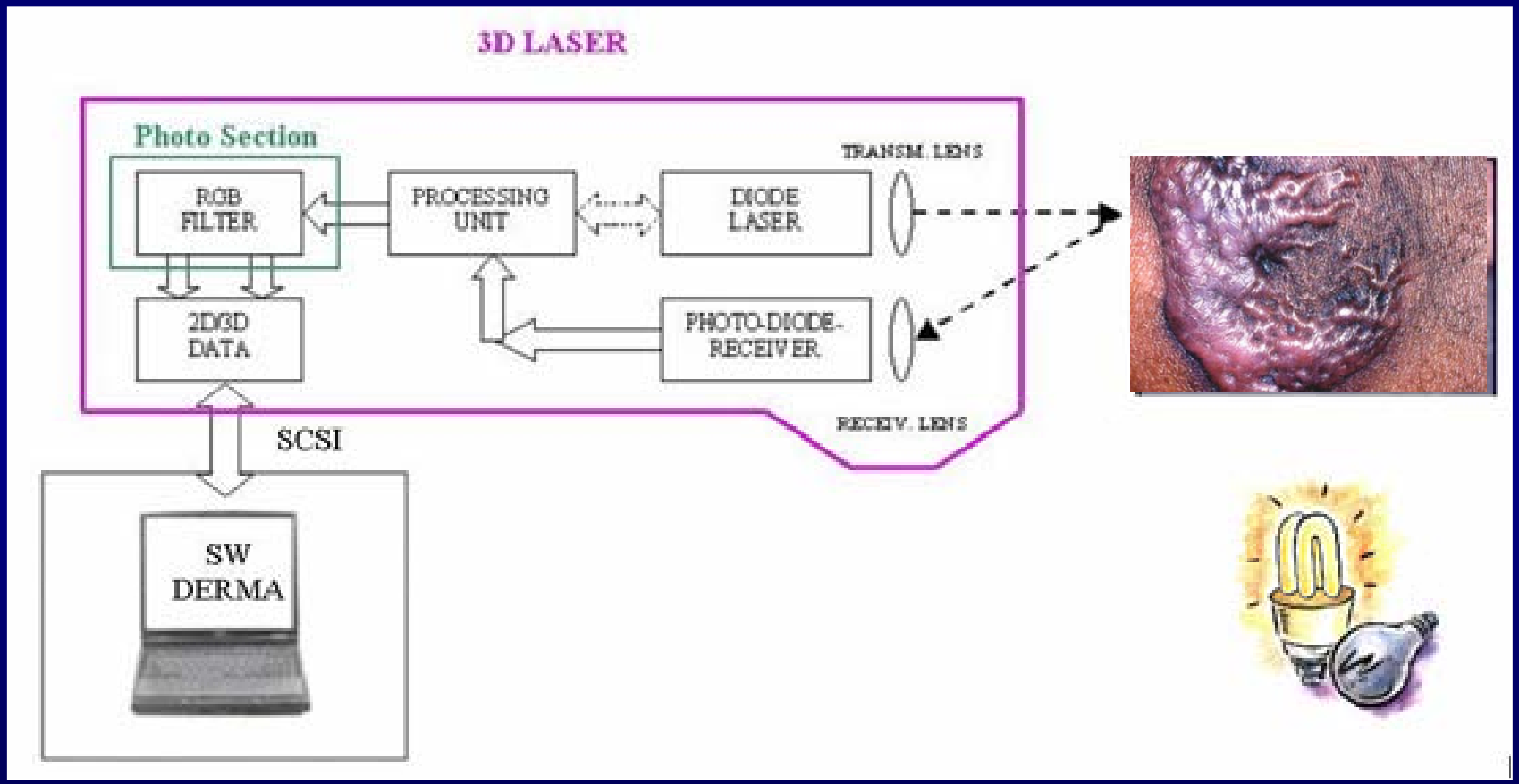

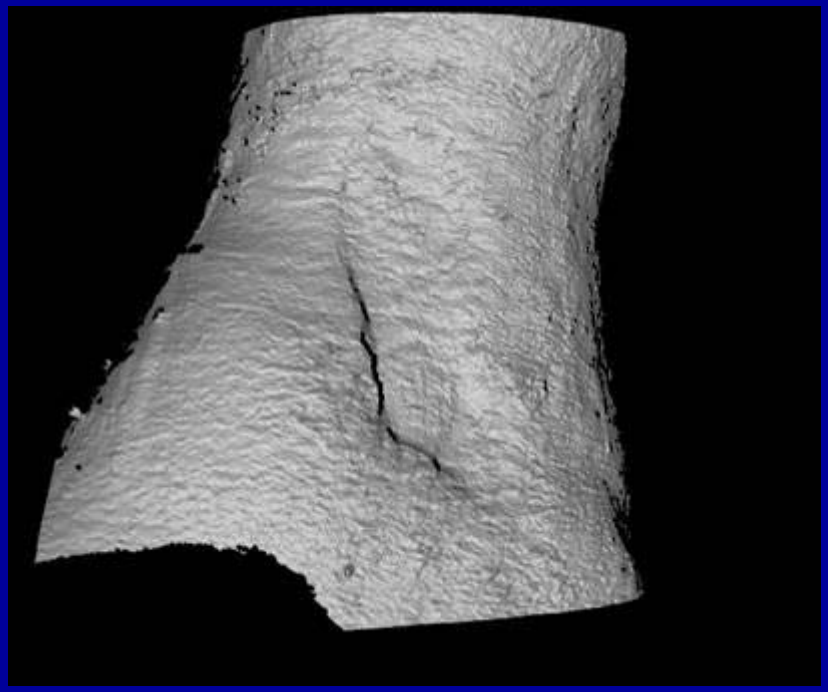

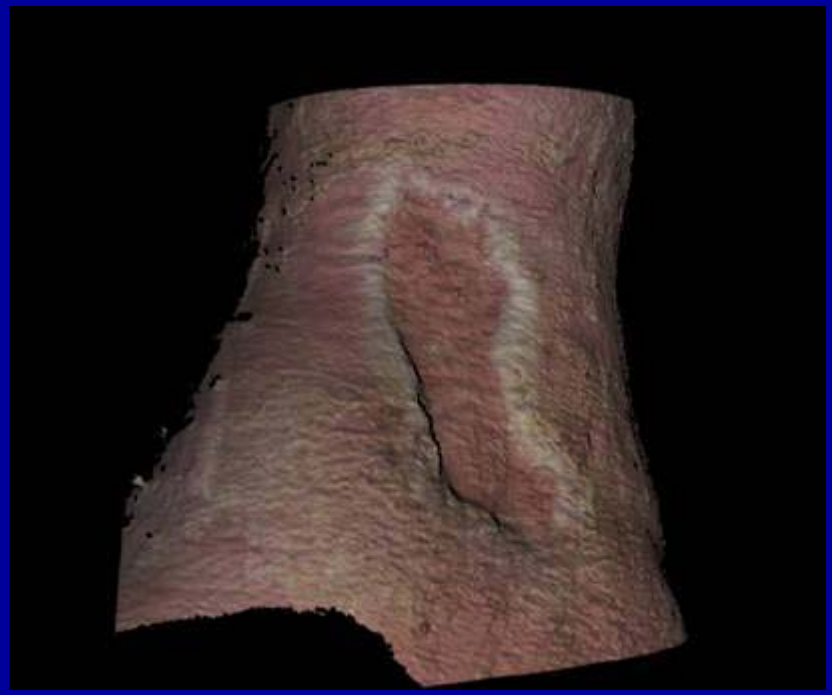


Patient: -- Scan: 15/10/2002 16:1 -- Derma
File Edit Show ?
Patient Scan Measure Segment Compare
Clear All
Undo
Save Segmentation
Show
Seeds
Data
Borders
Region 1
regione 1
Manual Seed
Auto Seed
Tolerance
Region 2
regione 2
Region 3
regione 3
Region 4
regione 4
Region 5
regione 5
Ready
Patient:
Scan: 15/10/2002 16:1

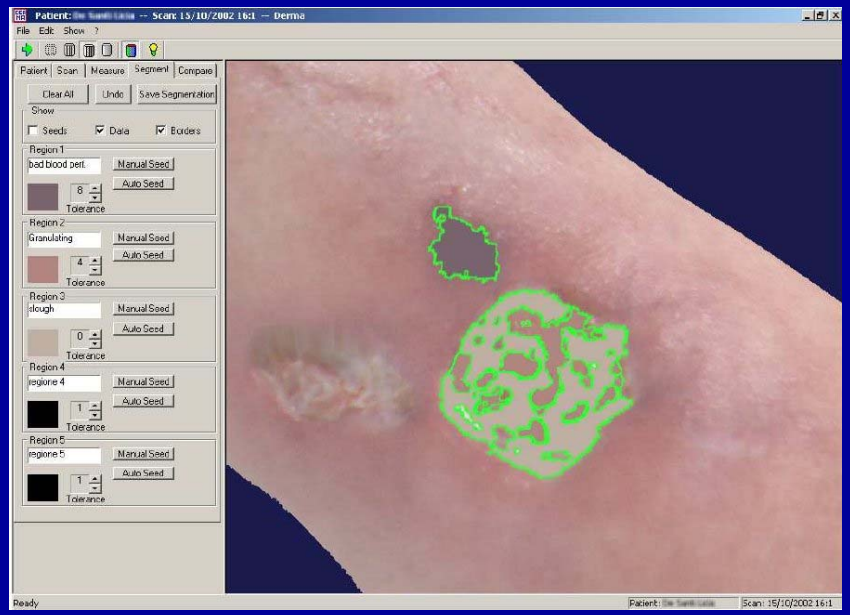
Patient: -- Scan: 15/10/2002 16:1 -- Derma
File Edit Show ?
Patient Scan Measure Segment Compare
Clear All
Undo
Save Segmentation
Show
Seeds
Data
Borders
Region 1
bad blood perf.
Manual Seed
Auto Seed
Tolerance
Region 2
Granulating
Region 3
slough
Region 4
regione 4
Region 5
regione 5
Ready
Patient:
Scan: 15/10/2002 16:1

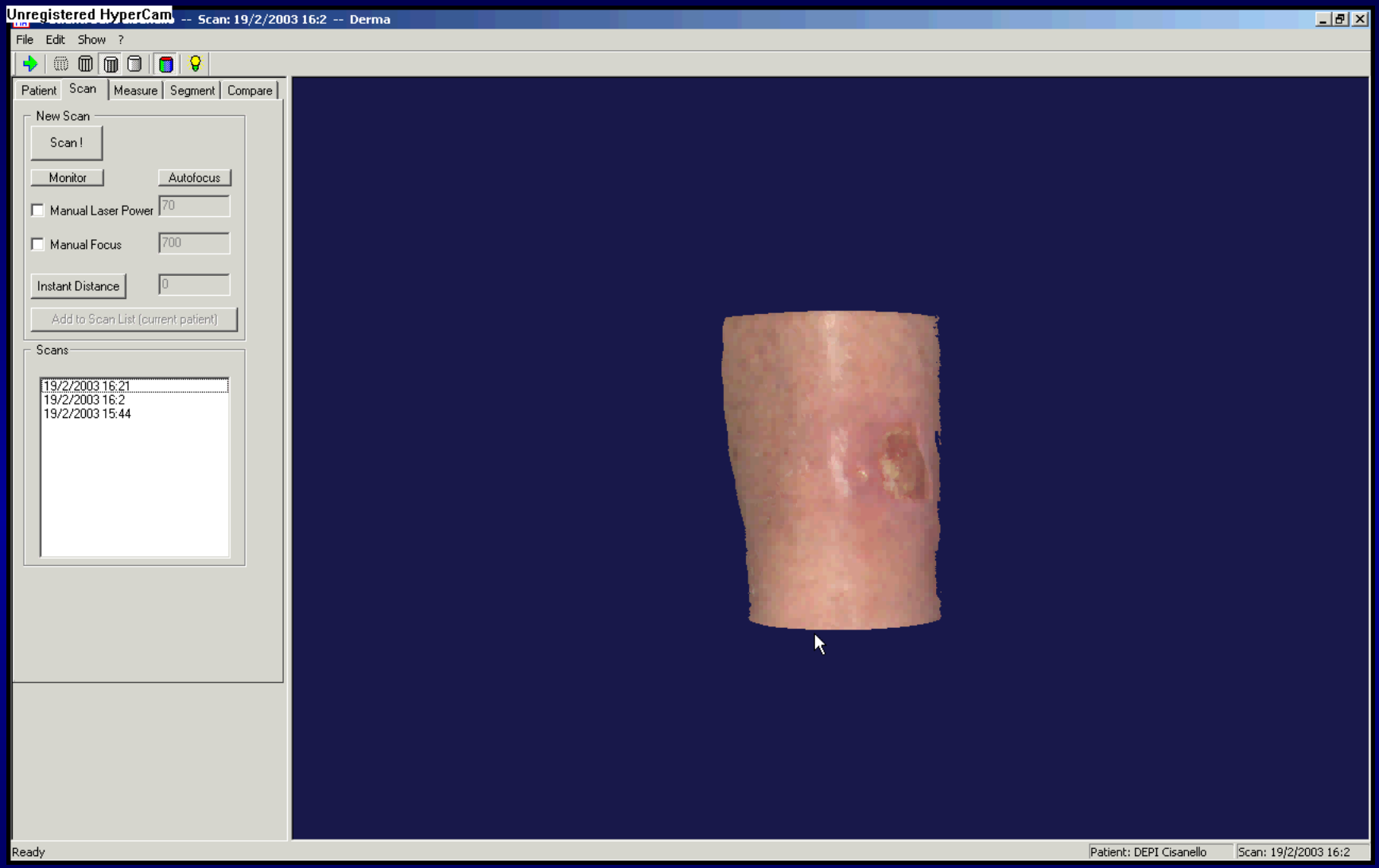
Unregistered HyperCam
-- Scan: 19/2/2003 16:2 -- Derma
File Edit Show ?
Patient
Scan
Measure
Segment
Compare
New Scan
Scan !
Monitor
Autofocus
Manual Laser Power
70
Manual Focus
700
Instant Distance
0
Add to Scan List (current patient)
Scans
19/2/2003 16:21
19/2/2003 16:2
19/2/2003 15:44
Ready
Patient: DEPI Cisanello
Scan: 19/2/2003 16:2

Conclusions

- Scar measurement is complex and is a skill which requires appropriate instruction, supervision and practice
- Physical measurements are essential in wound healing
- The noninvasive nature of available techniques allows repeated assessment

Acknowledgement

Valentina Dini, MD

Sabrina Barbanera, MD

MariaStefania Bertone, NT

Cinzia Brilli, RN

Alfredina Orsetti, RN

Susanna Zingoni, RN

Graziana Battaglia, BA

European Tissue Repair Society
16th Annual Meeting

13 – 16 September 2006

Pisa – Italy

www.ETRS2006PISA.com

info@etrs2006pisa.com