Cervical Myelopathy: Anterior Surgery is Best

Rick C. Sasso MD

Professor
Chief of Spine Surgery
Clinical Orthopaedic Surgery
Indiana University School of Medicine

Disclosure: Research support-Medtronic, Stryker, AO, Cerapedics, Smith & Nephew, Lilly
Royalties-Medtronic, Saunders Elsevier

Indiana Spine Group

Myelopathy: Surgical Options

- Anterior decompression & fusion:
  - Discectomies & interbody grafts
  - Corpectomies & strut grafts
  - Mixed Corpectomy/discectomy
- Posterior Surgery:
  - Laminectomy
  - Laminoplasty
  - Laminectomy & fusion
- Combined Ant./Post.

Indiana Spine Group

Anterior decompression and stabilization-Gold Standard

- Direct decompression of ventral cord
- Direct and indirect foraminal decompression
- Restoration of cervical lordosis

Iyer *Clin Spine Surg* 2016

Multi-level Corpectomy Reconstruction Failure Rate

	2 level	3 level
Vaccaro	9%	50%
Sasso	6%	71%

Indiana Spine Group

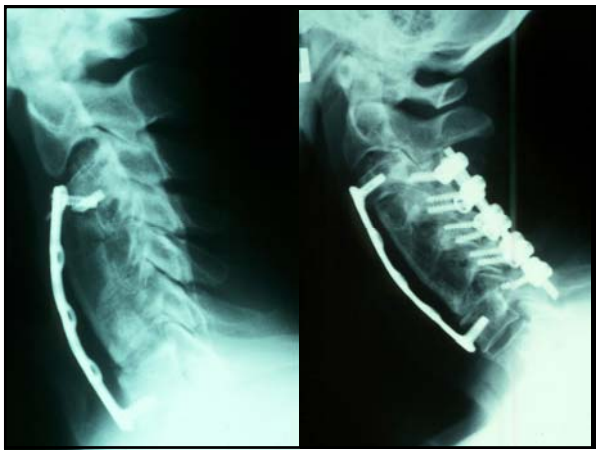

Posterior Approaches

Laminectomy

Laminoplasty

Laminectomy + Fusion

Indiana Spine Group

Post-laminectomy Cervical Kyphosis

Indiana Spine Group

Laminoplasty: Pre-op alignment

- No Decompressive effect when cervical lordosis less than 10 degrees
- Cord bowstrings against anterior osteophytes

Yamazaki Spine 1999

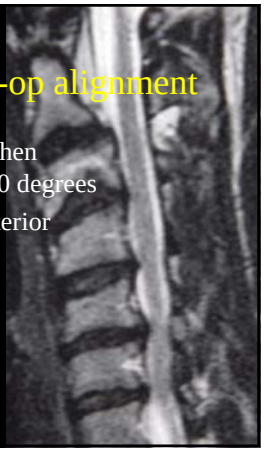

Laminoplasty Long-term F/U

- Delayed neurologic deterioration
  - Progressive Kyphosis
  - Progression of OPLL

Iwasaki Spine 2007

Laminoplasty Long-term F/U

- 5-yrs postop
- Progressive Kyphosis
- 30% patients

Saruhashi JOSDT 1999

An Evidence-Based Stepwise Surgical Approach to Cervical Spondylotic Myelopathy: A Narrative Review of the Current Literature

"In patients with straightened spine" (loss of lordosis):

- limited involved levels (1 or 2), ACDF with a plate is recommended
- **multiple involved levels should undergo posterior decompression and fusion**

Farrokhi et al: *World Neurosurg* **2016**

Indiana Spine Group

Are There Differences in The Progression of Ossification of the Posterior Longitudinal Ligament Following Laminoplasty Versus Fusion? A Meta-Analysis

OPLL progression

- **62.5%** for the **Laminoplasty** group
- **7.6%** for the **fusion** group
- **Laminoplasty frequently induces progression of OPLL compared with fusion surgery**

Lee et al: *Spine* **2016**

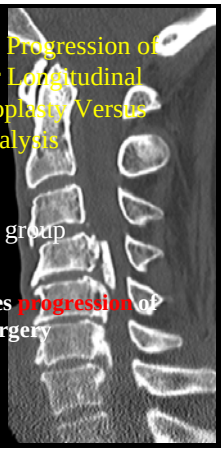

Cervical sagittal imbalance is a preoperative risk factor for kyphotic deformity after Laminoplasty

- Despite lordotic alignment- cervical sagittal imbalance (Sagittal Vertical Axis) leads to postoperative kyphotic deformity after Laminoplasty

Sakai CSRS **2013**

Indiana Spine Group

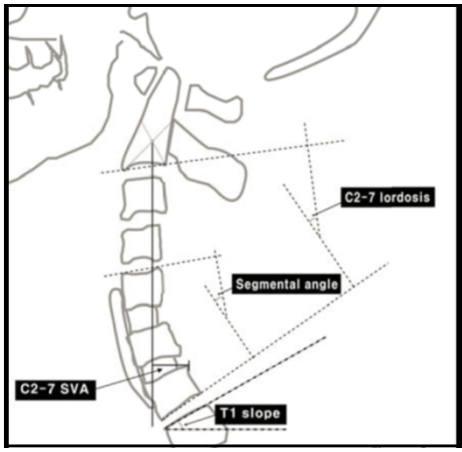

Indiana Spine Group

T1 slope as a predictor of kyphotic alignment change after Laminoplasty in patients with cervical myelopathy

- Despite normal cervical lordosis-a high T1 slope leads to postoperative kyphotic deformity after Laminoplasty

Kim CSRS **2013**

Indiana Spine Group

Impact of preoperative ce balance on surgical treatme spondylotic myelopathy ossification of the posterio ligament

- "Laminoplasty is NOT suitable for patie with cervical myelopathy caused by OPI who have cervical sagittal imbalance, ev cases with normal preoperative alignme

Sakai CSRS **2016**

The K-line Tilt

Indiana Spine Group

The K-line Tilt

- **Laminoplasty is NOT suitable for patients with a K-line tilt >20 degrees Even in cases with normal preoperative alignment**

Sakai CSRS **2016**

Indiana Spine Group

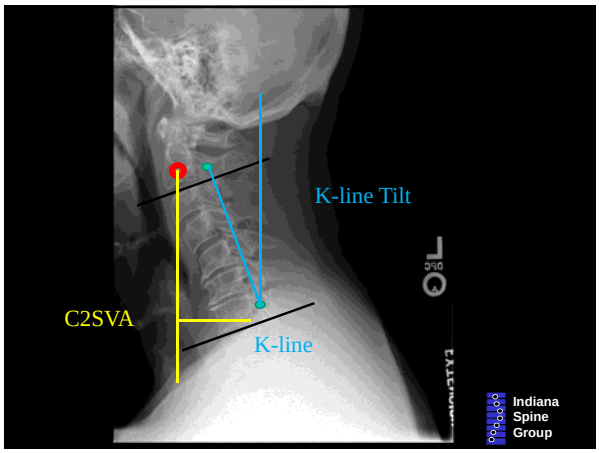

Surgical Strategy: multilevel OPLL

- 75 pts severe OPLL:> 3 levels, > 40% canal dia.
  - 22 Ant. Corpectomy and fusion
  - 28 Post. Lam. and instrumented fusion
  - 25 Laminoplasty
- Lordosis better with Corp. and Lam+fusion
  - Laminoplasty higher rate of kyphosis (7/25)
- JOA Neuro better with Corp. and Lam+fusion
  - Laminoplasty only group with neuro worse (4/25)
- CSF leak-main complication Ant approach
- C5 palsy-main complication Post approach
- Axial pain-main complication Laminoplasty

Chen JOSDT 2011

Indiana Spine Group

CSM: Factors associated with perioperative complications

•302 patients from the Prospective Multicenter AO Spine North American cervical spondylotic myelopathy study

•Posterior approach-higher infection rate

•Anterior approach-higher dysphagia

•C5 palsy-equal ant. Vs. post.

•Complications sig. assoc. with increased OP time; EBL

•Not assoc with age, BMI, smoking, prior surg. or number of levels

Fehlings *J NeuroSurg Spine* 2012

Indiana Spine Group

Spine

CERVICAL SPINE

SPINE Volume 38, Number 26, pp 2247-2252
©2013, Lippincott Williams & Wilkins

Anterior *Versus* Posterior Surgical Approaches to Treat Cervical Spondylotic Myelopathy

Outcomes of the Prospective Multicenter AOSpine North America CSM Study in 264 Patients

Michael G. Fehlings, MD, PhD,* Sean Barry, MD,* Branko Kopjar, MD,† Sangwook Tim Yoon, MD,‡
Paul Arnold, MD,§ Eric M. Massicotte, MD,* Alexander Vaccaro, MD, PhD,¶ Darrel S. Brodke, MD,‖
Christopher Shaffrey, MD,** Justin S. Smith, MD,** Eric Woodard, MD,†† Robert J. Banco, MD,‡‡
iman, MD,† Michael Janssen, DO,§§ Christopher Bono, MD,¶¶ Rick Sasso, MD,‖‖
iatoski, MD,*** and Ziya L. Gokaslan, MD†††