

Orthopedic Red Flags

Jill Bennison, CPNP and Jennifer Weiner, CPNP
Spring Ohio NAPNAP Conference
April 28, 2016

Disclosures

We have no declared conflicts of interest related to this program.

Objectives

- To identify potential Pediatric Orthopedic emergencies
- To determine treatment and referrals for Pediatric Orthopedic emergencies

Case study

A 3-year-old boy walks into your office with chief complaint of a limp
VS: HR 90 RR 22 Temp 102.3 Wt 13kg Ht 85cm
ROS: Cold symptoms 1 week ago, hip pain for 3 days, now won't stand on his left leg
PMH: Asthma
PSH: Circumcision at birth
Exam: NAD, alert and oriented. Abdomen soft, NT/ND, obese; RLE held in external rotation, flexed at hip. NVI

Differential Diagnosis


- Transient synovitis
- Septic arthritis
- Diskitis
- Toddler's fracture
- Cerebral Palsy
- DDH
- Fracture
- Pauciarticular juvenile arthritis
- Leukemia
- Osteomyelitis
- Legg-Calve-Perthes disease
- Discoid meniscus
- Limb length discrepancy
- SCFE
- Hip dysplasia
- Chondrolysis
- Overuse syndrome
- Osteochondritis dissecans
- Tumor

Osteomyelitis

- Presents with focal pain and decreased use of affected extremity
- Pain typically causes restlessness
- Physical exam
 - Limp or refusal to bear weight
 - Generally not toxic appearing
 - +/- fever
- Evaluation starts with plain films and lab work
- May request direct aspiration of site
- MRI is likely needed

Osteomyelitis

- Affects 1 in 5000 under the age of 13
- 2.5 times more common in boys
- 50% of cases are under age 5
- Risk factors
 - Diabetes mellitus
 - Hemoglobinopathy
 - Rheumatoid arthritis
 - Chronic renal disease
 - Immune compromise
 - Varicella infection



Osteomyelitis

- Treatment
 - Antibiotics
 - Surgery
- Complications
 - Chronic infection
 - Avascular necrosis
 - Growth disturbance
 - DVT
 - Pulmonary embolism
 - Multisystem involvement

Septic Arthritis of the hip

- Surgical emergency that requires immediate attention
- Presentation: ill-appearing, presents more rapidly than osteomyelitis, refuse to walk or bear weight
- Hip joint affected in 35% of cases
- Physical exam
- Inspection and Palpation
 - Localized swelling
 - Tenderness, effusion, warmth
 - Hip rests in position of flexion, abduction, external rotation
- Range of motion
 - Severe pain with passive motion
 - Unwillingness to move joint (pseudoparalysis)

Septic Arthritis of the hip

- Important to differentiate from transient synovitis
- Transient bacteremia is the most common cause
- Serious consequences if left untreated
- Evaluation: plain radiographs and laboratory studies
- May consider ultrasound

Kocher Criteria

- To differentiate between SA and Transient Synovitis
- 4 predictors
 - History of fever (oral temp >38.5C)
 - History of non-weight bearing
 - ESR greater than 40mm/hr
 - WBC greater than 12,000 cells/mL
- No substitute for clinical judgment

Septic Arthritis of the hip

- Immediately refer to ED for Ortho/ID consult
- Joint aspiration can help determine diagnosis
- Many different methods
- WBC greater than 50,000 cells/mL indicates septic joint

Septic Arthritis

- **Treatment**
 - Antibiotics - Partner with ID!
 - Can begin empirically after cultures obtained
 - Duration based on response of ESR
 - Surgery
 - Some form of decompression and washout
 - May need repeat trips to OR
- **Complications**
 - Delay in treatment is single most predictive factor affecting prognosis

Transient synovitis

- Most common cause of hip pain in pediatrics
- Most common in ages 4-8 years
- Male to female ratio 2:1
- Cause is largely unknown
 - Trauma
 - Bacterial or viral infection
 - Higher interferon concentration
 - Allergic reaction

Transient synovitis

- **History**
 - Children between 3-8 years old
 - Rapid onset of hip pain, limping, limited ROM
 - Recent history of viral illness
- **Physical**
 - Rarely have a temp above 38 C or signs of systemic illness
 - +/- weightbearing
 - Minimal pain with full-arc ROM

Transient synovitis

- **Labs/Diagnostics**
 - Usually WBC, CRP & ESR within normal limits
 - X-rays unremarkable but may show effusion,
 - US shows effusion
 - Aspiration = WBC 5000-15000 cells/mL
- **Prognosis/Complications**
 - Expect relief gradually in several days/weeks
 - Symptoms resolve 10 days avg.
 - No long-term concerns

Diskitis

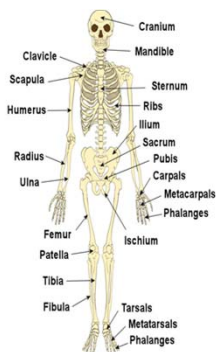
- Most often seen in ages 1-5
- S/Sx vary widely and less than half have a fever
- Physical exam reveals decreased ROM in spine
- May elicit tenderness to palpation on exam

Diskitis

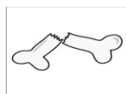- **Imaging:**
 - Plain radiographs
 - MRI
- **Labs:**
 - CBC with diff
 - ESR and CRP
- **Treatment:**
 - IV antibiotics
 - Bedrest
 - Possible surgery

Fractures

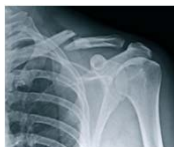- Types of fractures
- Salter -Harris fractures
- Non-accidental trauma(NAT)
- Compartment syndrome



" Does break = fracture?"



- Fracture: a crack or break
- Clear communication for families & patients
- Proper description of fracture
 - to other advanced providers/ specialists important for proper treatment plan
 - Documentation purposes



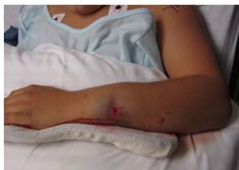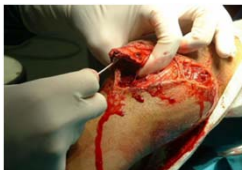OLD ACID

- Open vs closed fracture
- Location of fracture
- Degree (incomplete or complete fracture)

- Articular involvement
- Comminution/ Pattern
- Intrinsic bone quality
- Displacement, angulation, rotation

Open vs closed fracture

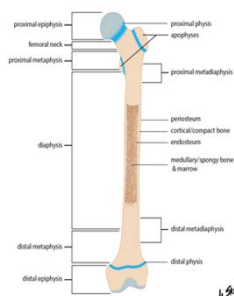
Open fracture: open wound, puncture or laceration near fracture, a disruption of skin integrity



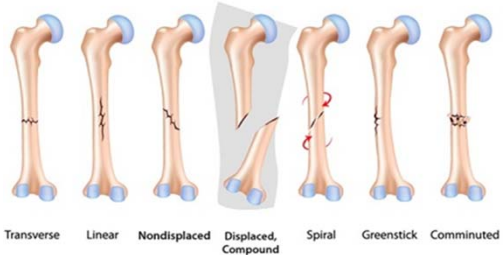
Closed fracture: Skin integrity intact

Location of fracture

- Identify which bone is fractured
- Anatomical landmarks
- Proximal, middle or distal third
- Segment
epiphysis, physis, metaphysis, diaphysis




Fractures Patterns



Complete vs Incomplete Fractures

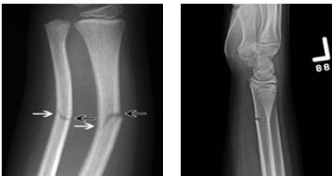
Complete fracture

- Through both bony cortices
- Bone fragments are completely separate from each other




Incomplete fracture

- Fracture disrupts only one side of bony cortex



Articular Involvement

- Intra-articular involvement
- Fracture extends into the joint surface
- Assess congruency of joint surface

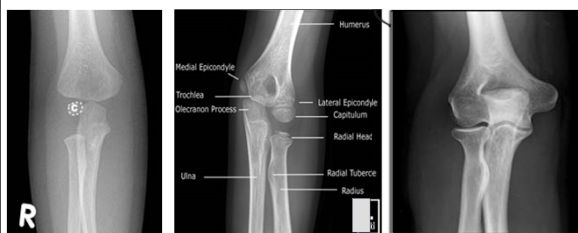



Pediatric bone anatomy

- Differs from mature adult
- Physes /growth plates- mostly cartilaginous in infants, until the development of ossification centers
- Apophysis or growth center can be mistaken for fractures to the untrained eye

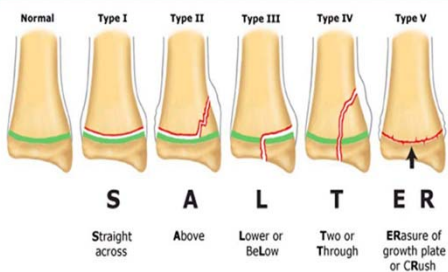
Anatomy of the developing elbow



toddler
adult

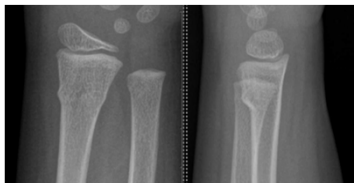
late childhood

Salter-Harris classification of physeal fractures



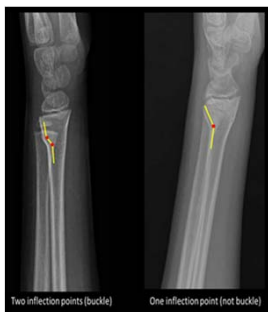Buckle or Torus fractures

- Distal radius buckle fractures are common in the pediatric population
- Distal radius buckle fractures are inherently stable fractures and heal reliably well



Buckle Fracture

- No angular deformity
- No visible fracture
- 2 Inflection points



Bone Remodeling


- Phases of bone healing: inflammatory, reparative, remodeling
- Main factors that affect pediatric bone remodeling are age, location and type of fracture

Both Bone Forearm Fracture

A. Hematoma and Inflammatory phase

B. Reparative phase at 8 weeks. Provisional callus

C. Remodeling phase. Angulation, displacement mostly resolved.

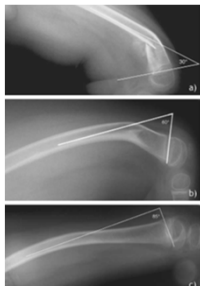


Child with CP- distal femur fracture


A. 2 weeks post fracture

B. @ 9 month

c. @ 18 months



Infant humerus fracture

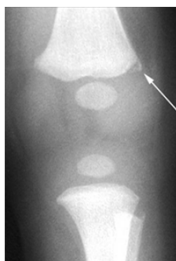

Fracture Treatment

- Immobilize and refer to ED/ Orthopedics for radiographs and evaluation.
- Non-weightbearing to affected extremity
- Splinting options
- Always protect the skin prior to application of splint

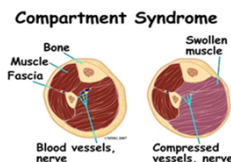
Non accidental trauma

- In our hospital, every child under 5 with an unwitnessed injury in the home is evaluated for NAT
- It's the most common cause of femur fractures in non-ambulatory children
- 50% of fractures in children less than 1 year of age attributable to abuse
- Red flags include long bone fractures in infant not yet walking, multiple bruises, multiple fracture in various stages of healing, corner fractures, posterior rib fractures, transphyseal separation of the distal humerus



Compartment Syndrome

- Compartment syndrome (CS) is a serious limb-threatening condition
- Occurs when the tissue pressure within a closed muscle compartment exceeds the perfusion pressure
- High suspicion and early recognition is key




Compartment Syndrome

- CS is largely a clinical diagnosis
 - High index of suspicion
 - 5 P's
 - 3 A's
- Can be aided by measurement of pressure within compartments
 - Positive if pressure >30mmHg or within 30mmHg of diastolic blood pressure
 - Must measure all compartments
 - Necessary in children and sedated/obtunded patients

Compartment Syndrome

Treatment

- Nonoperative
 - Observation
 - If evolving CS suspected, the limb should not be elevated
- Bivalve cast or remove dressings
 - Can reduce pressure by as much as 85%
- Hyperbaric oxygen therapy
- Operative
 - Fasciotomy—goal of decompression is restoration of muscle perfusion within 6 hours



Compartment Syndrome

Complications

- Volkmann's ischemic contracture
- Infection
- Chronic pain
- Loss of function
- Amputation

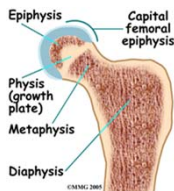
Case Study

Differential Diagnosis

- Transient synovitis
- Septic arthritis
- Diskitis
- Toddler's fracture
- Cerebral Palsy
- DDH
- Fracture
- Pauciarticular juvenile arthritis
- Leukemia
- Osteomyelitis
- Legg-Calve-Perthes disease
- Discoid meniscus
- Limb length discrepancy
- SCFE
- Hip dysplasia
- Chondrolysis
- Overuse syndrome
- Osteochondritis dissecans
- Tumor

SCFE(Slipped Capital Femoral Epiphysis)

- Most common hip disorder in adolescence
- Acquired condition
- Occurs when there is a displacement of the capital femoral epiphysis (femoral head) from the femoral neck (metaphysis) through the epiphyseal plate.



SCFE prevalence

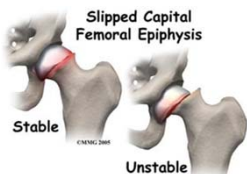
- 2 per 100,000
- Males > females; 2:1
- Left hip higher incidence
- Increased incidence in African Americans, Hispanics and Pacific Islanders
- Unilateral or bilateral

Symptoms of SCFE

- Vary on presentation
 - Subtle, intermittent, prodromal, or acute
- Commonly present with hip, thigh or groin pain
- Can also present with
 - Knee pain
 - Limp
 - Difficulty walking
 - Refusing to ambulate

SCFE classifications

Stable- Able to walk with or without crutches
Unstable- Unable to ambulate even with crutches




SCFE classifications


Acute - pain <3 weeks

Chronic - pain > 3 weeks

Acute on Chronic- prodromal symptoms for > 3 weeks, then immediate worsening
- can be months or years of prodromal symptoms



Pain Scale



Risk Factors that increase risk to develop SCFE

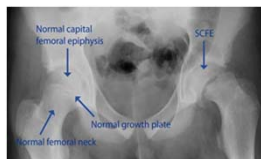- Obesity, > 95 % BMI
- Increased leptin levels
- Patients on growth hormone therapy
- Chronic illnesses
- Endocrine disorders including :
hyperthyroidism, hypothyroidism,
hyperparathyroidism, hypopituitarism and
hypogonadal states

Clinical Exam

- Limited internal rotation of involved hip
- Hip held in external rotation, often with knee flexed
- Pain with log roll of lower extremity
- Decreased hip abduction and flexion
- Leg weakness
- Muscle atrophy
- Limb shortening appearance

Standard Testing / Diagnosis

Radiographs if SCFE is suspected at all
 Pelvis - AP AND frog lateral view
 Knee - AP and lateral view



Immediate treatment

If diagnosed or suspected:

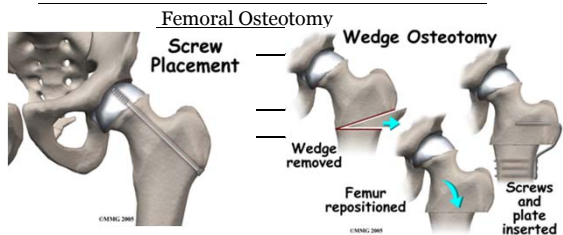
- Treat with urgency
 - Nonweightbearing
 - Bedrest
 - Refer immediately to ED (preferably pediatric)

SCFE Treatments

Stabilize the capital epiphysis on the femoral neck in its original position

In Situ pinning

Hip dislocation with



Complications

Short term

Pain, limp, altered range of motion, infection, DVT, respiratory GI, hardware failure

Long term- avascular necrosis (AVN), chondrolysis, leg length discrepancy

Oncologic Emergencies

- ALL/AML
 - Can present with a limp or leg pain
- Osteosarcoma
 - Generally affects ages 10-25
 - Pain is most common presenting symptoms, starts vague and may localize and be severe and constant
 - Radiographic picture characterized by destructive and osteoblastic changes

Oncologic emergencies

- Ewing's Sarcoma
 - Peak incidence in second decade of life
 - Second most common malignant bone tumor
 - Most common presenting symptom is localized pain, may have systemic signs
 - Important to differentiate from Osteomyelitis

Questions?



References

Bennison, J.M., Horn, P. L. (2015). Pediatric patients with slipped capital femoral epiphysis with knee pain. *The Journal for Nurse Practitioners*, 11, 954-959.

Dormans, J.P. (2005). *Pediatric Orthopedics: Core knowledge in orthopaedics*. Philadelphia: Mosby, Inc.

Herring, J.A. (2008). *Tachdjian's Pediatric Orthopedics*. Philadelphia: Elsevier, Inc.

Hip Septic Arthritis-Pediatric (2016) OrthoBullets online. Retrieved from <http://www.orthobullets.com/pediatrics/4092/hip-septic-arthritis-pediatric>

Osteomyelitis-Pediatric (2016). OrthoBullets online. Retrieved from <http://www.orthobullets.com/pediatrics/4031/osteomyelitis-pediatric>

Pediatric Abuse (2016) OrthoBullets online. Retrieved from www.orthobullets.com/pediatrics/4001/pediatric-abuse.

Transient Synovitis of Hip (2016) OrthoBullets online. Retrieved from <http://www.orthobullets.com/pediatrics/4030/transient-synovitis-of-hip>

Weiner, J.L., Horn, P.L., Scharschmidt, T.J., & Yeager, N.D. (2015). Ewing Sarcoma: Presentation, diagnosis, and treatment. *Consultant for Pediatricians*, 14, 444-448.

Wimberly, R.L. (2014). *General principles of managing orthopaedic injuries*. In Herring, J.A., Tachdjian's Pediatric Orthopaedics, 5th ed. Vol. 12. (Pp 1217-1219). Philadelphia: Elsevier

Witbreuk, M., van Kemedade, F. J., van der Shuijs, J. A. et al. (2013). Slipped capital femoral epiphysis and its association with endocrine, metabolic and chronic diseases: A systematic review of the literature. *Journal of Children Orthopedics*, 7, 213-223.
