

Management of Infectious Eye Disease-The Next Generation of Treatments

Bruce E. Onofrey, OD, RPh, FAAO
Professor, U. Houston
UEI

Enteroviruses: The “REAL “PINKEYE”

- Entero-from the gut
- EHC-Epidemic Hemorrhagic Conjunctivitis
- Called Apollo 11 disease after outbreak in Africa from 1969-70
- Enterovirus type 70
- Minimal corneal signs
- Big PA nodes common

KWIK CASE 2: Take a guess

S: 17 Y/O Female with c/o itching , watering red OD X 24 hours associated with flu-like symptoms.
O: “Mixed” conjunctivitis
NO Pre-Auricular node
Mucous like discharge with erythema OD
Pseudomembrane OD
Cornea: Multiple infiltrates
Unilateral presentation

Viral conjunctivitis is the #1 Cause of ACUTE INFECTIOUS Conjunctivitis (in adults)

- Adenovirus
- Enterovirus

Adenoviral Signs@@@@

- Follicular conjunctivitis-Variable most common in lower fornix
- Mild to moderate chemosis
- Lid swelling with mild ptosis
- “Watery” discharge
- Lymphadenopathy in **66%**


REMEMBER

ADENOVIRAL DISEASE IS BILATERAL

****EVENTUALLY****

CLASSIC PRESENTATIONS
ARE ONLY FOUND IN TEXTBOOKS

Adenovirus Family

- DNA Viruses
- At least 35 different serotypes
- Type 8 Classic EKC
- Types 10, 13, 19, and 37 NEW EKC
- NEW VIRUS =  INFLAMMATION

DOES SELF-LIMITING DISEASE NEED TREATMENT?

- SELF-LIMITING DOES NOT MEAN HARMLESS
- INFECTIVE PROCESS IS THE SELF LIMITED FACTOR
- INFLAMMATION IS NOT
- TREAT TO PREVENT INFLAMMATORY DAMAGE

TREATMENT OF BOTH SYMPTOMS AND PREVENTION OF INFLAMMATORY DAMAGE

- Cool compresses and ASA
- Lubrication
- Decongestants
- Steroids (infiltrates, membranes, inflammation)@@@
- Membrane removal
- Antibiotics??
- NOOOOOOOO!!!!
- A CURE?

Is there a Cure for the Common Cold of the eye? NOT QUITE

- **Spit and swish: Povidone 5% ophthalmic solution**
- **Don't spare the steroids**

THE CURE?

Decrease infection from 18 to 7 days
Fewer complications

Tabbara K, Jarade E. Ganciclovir effects in adenoviral keratoconjunctivitis. Invest Ophthalmol Vis Sci.

Currently in Animal Testing

- FORESIGHT PHARMACEUTICALS

Topical FST100 Dexamethasone 0.1% Containing Povidone-Iodine 0.4% Reduced the Clinical Signs and Infectious Viral Titers in a Rabbit Model of Adenoviral Conjunctivitis

**KWIK CASE #3
LIKE FATHER, LIKE SON**

- 3 Week old newborn with sudden onset mucopurulent mixed conjunctivitis
- Father with unilateral “GIANT” follicular conjunctivitis
- Marked pre-auricular nodes in both patients

CHLAMYDIA FACTOIDS

- #1 CAUSE OF CHRONIC CONJ. AND OPHTHAMIA NEONATORUM
- STD
- Mother should be checked prior to birth
- Onset in 2nd week post-partum
- Potential conjunctival scarring
- Systemic complications

**Chlamydia
Treatment**

- Both topical and systemic
- Treat parents and friends also
- The family that gets treated together stays together
- Erythromycin ophth. Oint
- Zithromax 10mg/kg/day X 1 day, then 5mg/kg/D X 4 days
- Adults: 1 gm SINGLE DOSE

KWIK CASE 3A

- 24 Y/O SCL patient
- Crusty lid lesion OD
- Red painful eye OD X 48 hours- getting worse
- “Mixed” conjunctivitis
- No CL X 24 hours
- 3rd time this year “pink eye”
- (+PA node on R side)

Disinfectants and infection

- **Broad anti-infective efficacy**
- **Ionic**
- **Some stain**
- **Uncomfortable**
- **Toxic**
- **Not all eye approved**
- **Skin infections**
- **Pre-op**

Herpes Family of Viruses@@@@

- Herpes simplex
- Herpes zoster
- Epstein Barr-Infectious mononucleosis
- CMV-Cytomegalovirus

Herpes Simplex

- Type I Above waist-Trigeminal ganglia
- Type II below waist-most severe in eye infection-Sacral ganglia@@@
- 50% reoccurrence within 2 years
- Multiple triggers@@@
- 90% carry antibodies by age 10

Herpes Simplex

- Primary disease
- Recurrent disease
 - Conjunctivitis
 - Keratitis
- Stromal disease
- Kerato-uveitis

Primary H. simplex

- @@@@
- Pre-auricular node common
- Vesicles
- Follicles
- No dendrite
- Self-limiting disease-BUT-
Treat aggressively to prevent recurrence

Recurrent H. simplex

- Pre-auricular node rare
- Virus involves deeper tissues with each episode
- 50% get recurrence within 2 years
- Steroids will exacerbate infectious H. simplex disease
- Contra-indicated in purely infectious

Stromal H. simplex- A whole new ball game

- Mechanism is primarily inflammation@@
@@
- Stromal infiltrates are the critical sign
- Balanced use of topical steroid (FML) with anti-

Topical vs Systemic Steroid vs no steroid

TX Mechanisms-not a Name

Know Your HEDS 1 and 2

#1: Topical for Everyone

Trifluorothymidine: THE OLD

- THE FORMER drug of choice for topical management of Herpes simplex ocular disease.@@@@
- Rapid absorption
- Toxicity occurs when used over 21 days
- Dosage-5-8X daily
- Viroptic 1%-7.5cc-Burroughs

ZIRGAN: THE NEW

- Selective Toxicity
- Gel formulation
- Adenoviral effective?

- 5X/D till re-epith, then TID X 3D

The Herpetic Eye Disease Study 1 and 2 (HEDS I and II) and it's impact on the current TX of H. Simplex Eye Disease

HX of HEDS I and II

- Multicenter study of H. Simplex
- 1992-1996
- 5 separate study groups to evaluate benefits of H. simplex TX modalities and prevention benefits of oral antiviral therapies
- HEDS I TX studies (active disease)
- HEDS II Prevention studies (prophylaxis)

The KWIK HEDS 1 RESULTS

1. STEROIDS FOR STROMAL HERPES - YES
2. ORAL ANTI-VIRALS for STROMAL HERPES – DOES NOT HASTEN RESOLUTION
3. ORAL ANTIVIRALS FOR IRIDOCYCLITIS- SMALL TEST GROUP, BUT STATISTICAL BENEFIT

The KWIK HEDS 2 RESULTS

1. Oral anti-virals DO NOT prevent conversion from epithelial to stromal Herpes
2. Prophylactic use of ORAL anti-virals DO prevent REOCURRENCE of ALL forms of H. simplex

USE OF ORAL ANTI-VIRALS IN HERPETIC DISEASE

EPITHELIAL HERPES
Combine with topical to maximize
therapy
Acyclovir 400mg 5X daily
Valacyclovir 500mg TID
Famcyclovir 250mg TID

USE OF ORAL ANTI-VIRALS IN HERPETIC DISEASE

DISIFORM HERPES
TOPICAL STEROID WITH
ORAL ANTIVIRAL
Acyclovir 400mg 2-5X daily
Famcyclovir 125mg BID
SLOWWWW TAPER
CONTINUE
PROPHYLACTIC ORALS
LONG TERM (YEARS)

USE OF ORAL ANTI-VIRALS IN HERPETIC DISEASE

DISIFORM HERPES W/
KERATO-UVEITIS
TOPICAL STEROID WITH ORAL
ANTIVIRAL
Acyclovir 400mg 5X daily
Valacyclovir 500mg TID
Famcyclovir 250mg TID
ORAL acetazolamide

USE OF ORAL ANTI-VIRALS IN HERPETIC DISEASE

HERPES ZOSTER
OPHTHALMICUS
TOPICAL STEROID WITH ORAL
ANTIVIRAL
Acyclovir 800mg 5X daily
Valacyclovir 1000mg TID
Famcyclovir 500mg TID
Glc drops as needed

NOW FOR SOMETHING TOTALLY SIMILAR

Asbell rabbit study

- Oral valacyclovir reduces risk of recurrent H. simplex after eximer PRK
- Response is highly dose dependant
- 150mg/kg X 14 days 0% reactivation
- Debridment did not reactivate virus
- Eximer produced reactivation
- Pre-TX?? Better results??

AND SOMETHING SOMEWHAT DIFFERENT

Scoper study

- 42 Dry eye patients with H. Simplex stromal keratitis
- Thermal punctalplasty
- Topical cyclosporin A
- 3 groups:
- Punctalplasty
- Cyclosporin A
- Both

Results

- Non-treated group: 6-7 months of disease/yr
- TX with EITHER thermal cautery or topical cyclosporin: 1.1 months/yr of active disease
- TX with both: 0.8 months/yr
- Learning point:
- OSD patients with H. simplex require aggressive management
- Topical cyclosporin A is safe and effective in H. simplex patients

Differential DX of Infection The Tests

- Cultures
- Diff-Quick
- Gram Stain

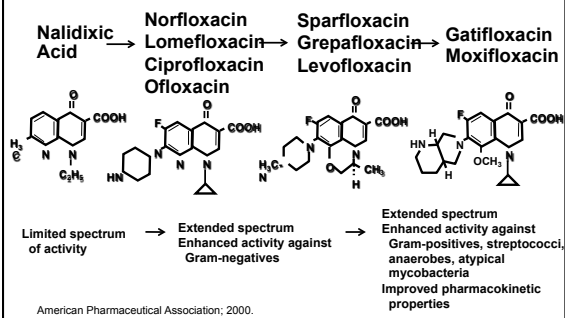
Gram Stain (FAST)

- Differentiates bacteria by differences in cell wall morphology@@@@
- Designates bacteria as Gram (+) or (-)@@@@

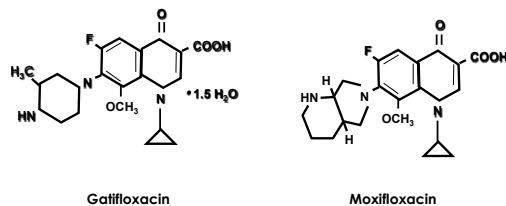
Bacterial Ulcer Guidelines

- Always culture if you have the means
- Patients that get better never sue-those that don't-DO
- Consider the 1-2-3-4 rule
- Fluoroquinolone mono-therapy is not fool-proof
- Grade the ulcer-Location, location, etc
- Step TX based on cultures

Evolution of the Quinolones



Fourth-Generation Fluoroquinolone Chemical Structures



The Latest

- Besivance: NEW Molecule
- Moxeza: Longer duration
- Zymaxid: Higher concentration

TWO MOXY's-What's the difference

Vigamox	Moxeza
• Active ingredient: 0.5% Moxafloxacin	• DITTO
• Indication Bacterial conjunctivitis	• DITTO
• Bottle size 5cc	• 3cc
• Dose TID	• BID
• Generic YES	• NO

For MRSA-Forget the Fluoroquinolones

Back to the OLD Drugs

- Trimethoprim (not just for kids)
- Tobramycin
- Vancomycin

Kids Conjunctivitis-NO drops alone if.....

- Recurrent or active otitis media
- Fever
- Sore throat
- Generally ill
- Treat with Polytrim/fluoroquinolone and effective oral anti H. Flu

The STYE that Wasn't

When topicals are NOT ENOUGH!

- 32 yowm swollen upper lid
- Very painful
- Warm to touch
- + HX frequent "Styes"

DON'T Forget Your Differential DX-The Bad Signs

- Decreased Acuity
- Proptosis
- Diplopia-Extraocular paralysis
- Febrile
- Elevated WBC's
- Get blood cultures
- Consider orbital CT scan

Orbital Cellulitis is a Life/Sight-Threatening Condition

- Patient must be hospitalized
- Parenteral IV therapy is mandatory
- Drug based on culture/sensitivity reports
- HX of trauma or insect bite is common

THE END

- MANY MANY THANKS!
- QUESTIONS?