Surgical repair of pelvic organ prolapse

November 2016

Concepts of Pelvic Support

- **Primary support** is pelvic floor muscles
  - Injured with childbirth
  - Atrophy with age (disuse, hormonal, neurologic)
  - Cannot restore surgically
- **Secondary support** is visceral "fascia" (fibromuscular connective tissues)
  - What we use surgically to re-support

Pelvic Floor Muscle ANATOMY

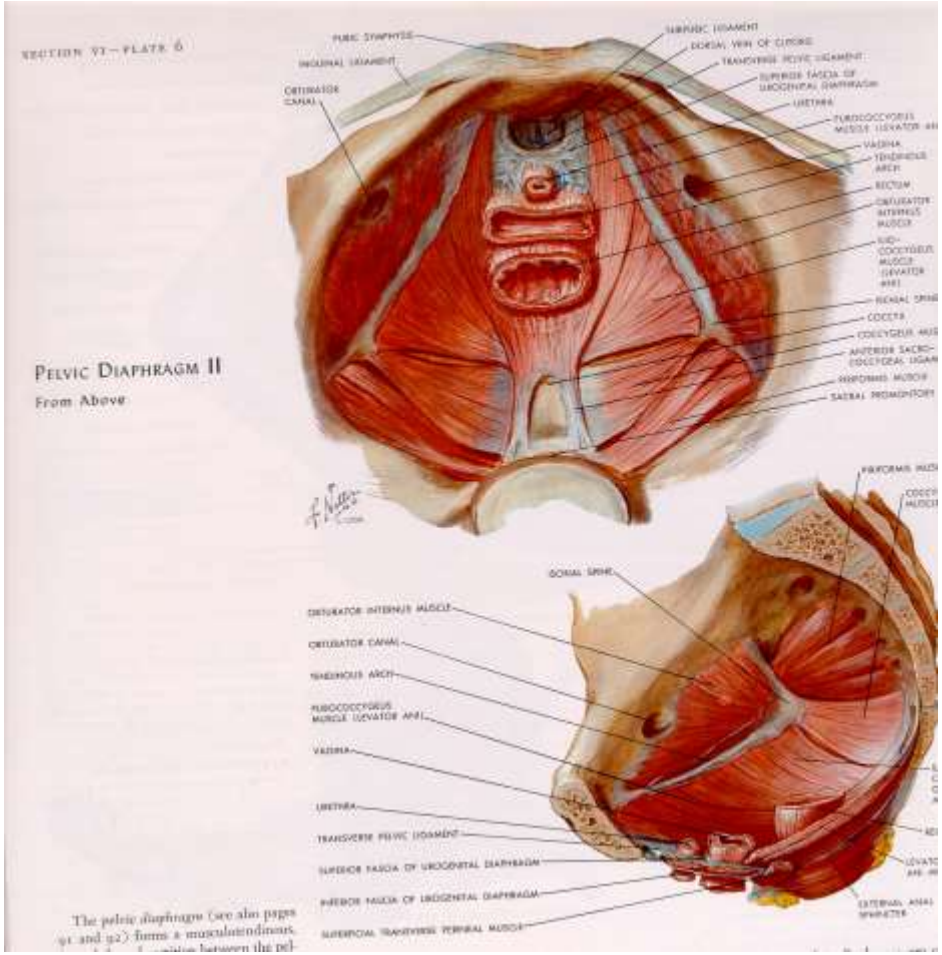

Ship in the dock analogy

Ship= pelvic organs (viscera)

Water= muscle support

Tethers= connective tissue support

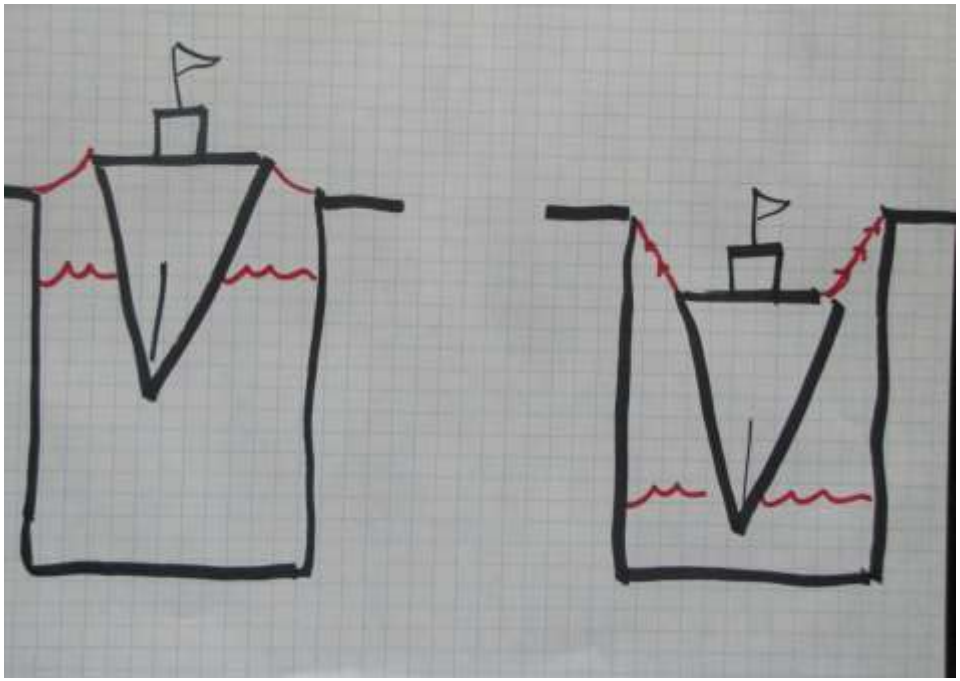

Concept of muscle support

- Sagittal view

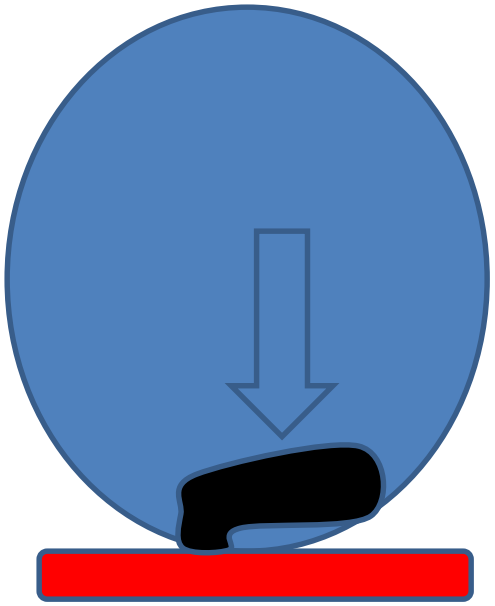

- Transverse view



Concept of muscle support effect of muscle loss

- Viscera through primary muscle support

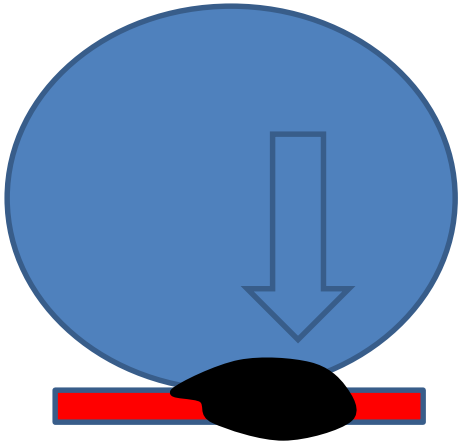

- Loss of pelvic floor muscle



Review

- Pelvic floor damage cause is multifactorial
  - Vaginal childbirth
  - Aging
  - Repetitive increases in intra-abdominal pressure
  - Genetics

- Pelvic floor supports the pelvic viscera by
  - #1. Muscle
  - #2Fibromuscular connective tissue

Anterior Vaginal Prolapse: Review of anatomy and techniques of surgical repair

Weber and Walters

Obstet and Gynecol 89:311-18 Feb 1997

Recommend that terminology describing vaginal tissue as fascia be abandoned

Term fascia should be reserved for the parietal fascia, which corresponds to established anatomic and histologic definitions (obturator fascia)

"Vaginal wall or muscularis" instead of "pubocervical fascia"

Endopelvic fascia describes the subperitoneal and perivascular connective tissue and loose areolar tissue that exist throughout the pelvis, around and between the pelvic organs

SMOOTH MUSCLE>COLLAGEN>ELASTIN

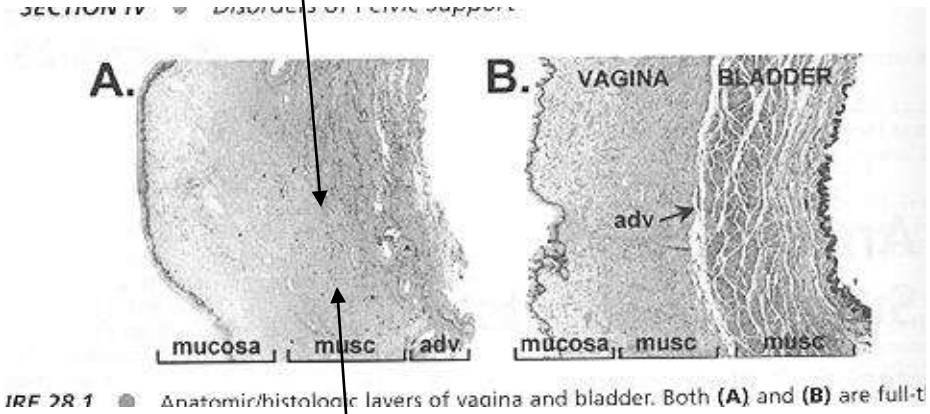

"PUBOCERVICAL FASCIA"

DeLancey Levels of Support

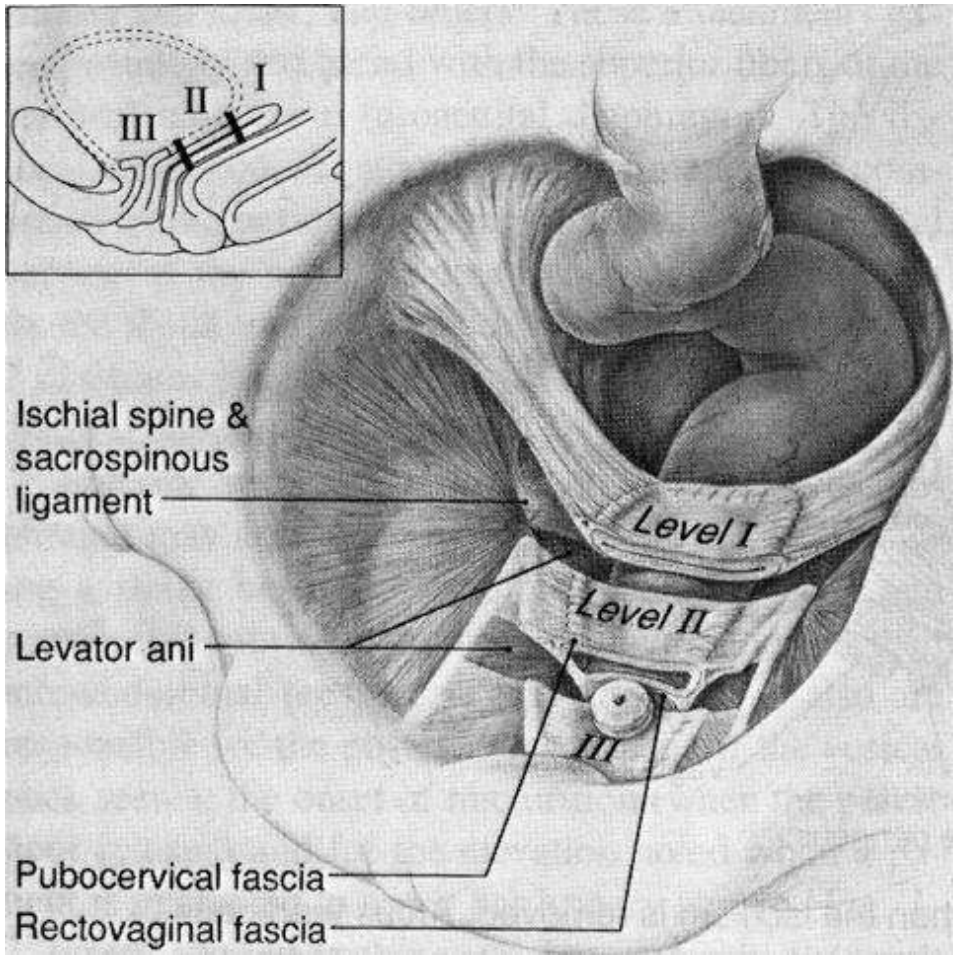

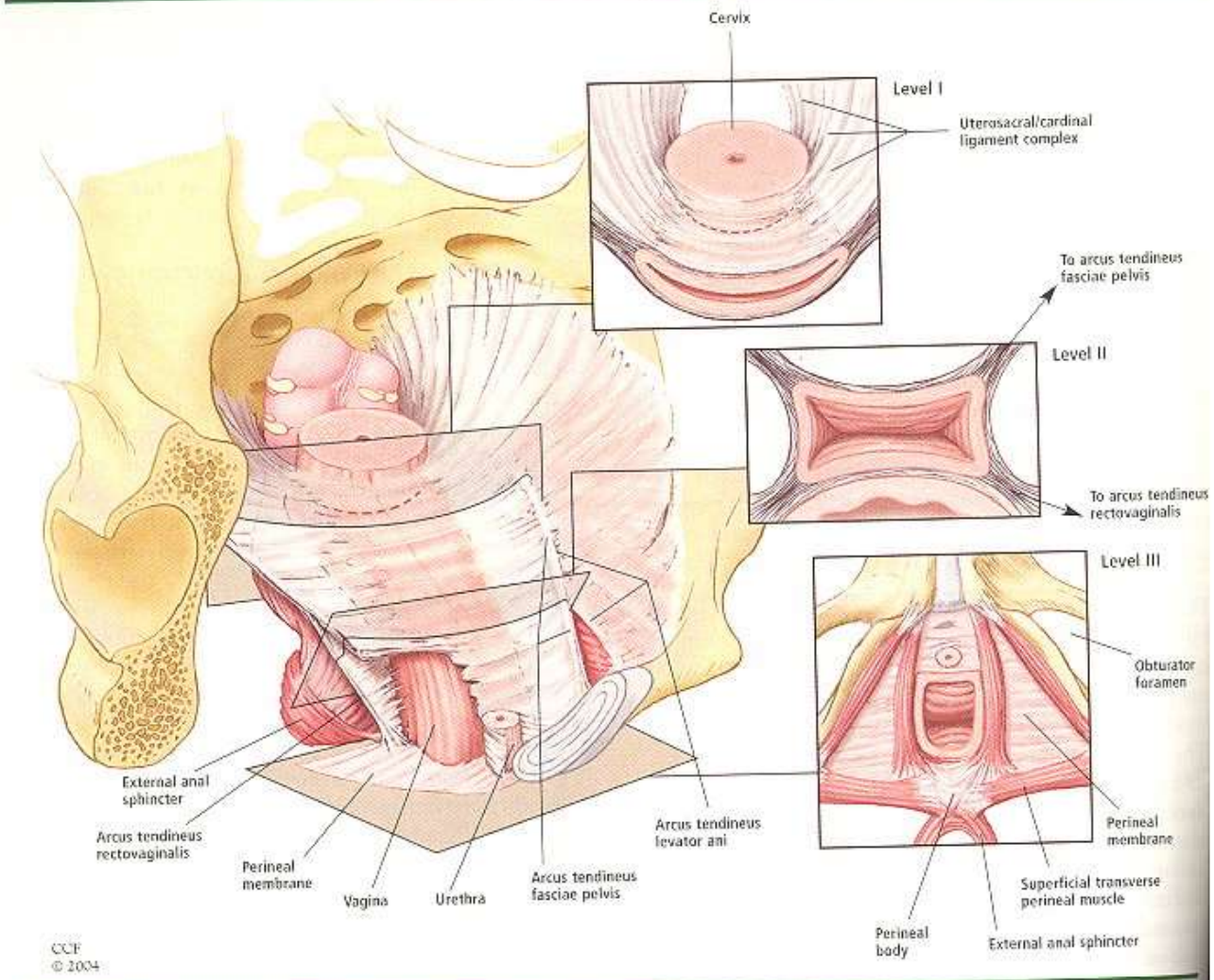

FIGURE 7. Integrated levels of support: illustration of the normal vaginal axis and the three levels of support of the vagina and uterus from the perspective of a standing woman. In level I, the endopelvic fascia suspends the upper vagina and cervix from the lateral pelvic walls. Fibers of level I extend both vertically and posteriorly toward the sacrum. In level II, the vagina is attached to the arcus tendineus fasciae pelvis and superior fascia of the levator ani muscles. In level III, the distal vagina is supported by the perineal membrane and muscles. The insets show transverse sections made through the vagina perpendicular to the normal vaginal axis at each level.

Summary of pelvic organ support DeLancey Levels

- Level I – Apical (cervix and proximal vagina)
  - Uterosacral ligaments
  - Normal is at the level of the ischial spines
- Level II- Mid-vagina
  - Pubocervical fascia anterior
  - Rectovaginal fascia posterior
  - Connections are lateral to the ATFP
- Level III- Distal vagina (urethra, ano-rectal)
  - Perineal body, perineal muscles, dense fibromusclular connective tissue

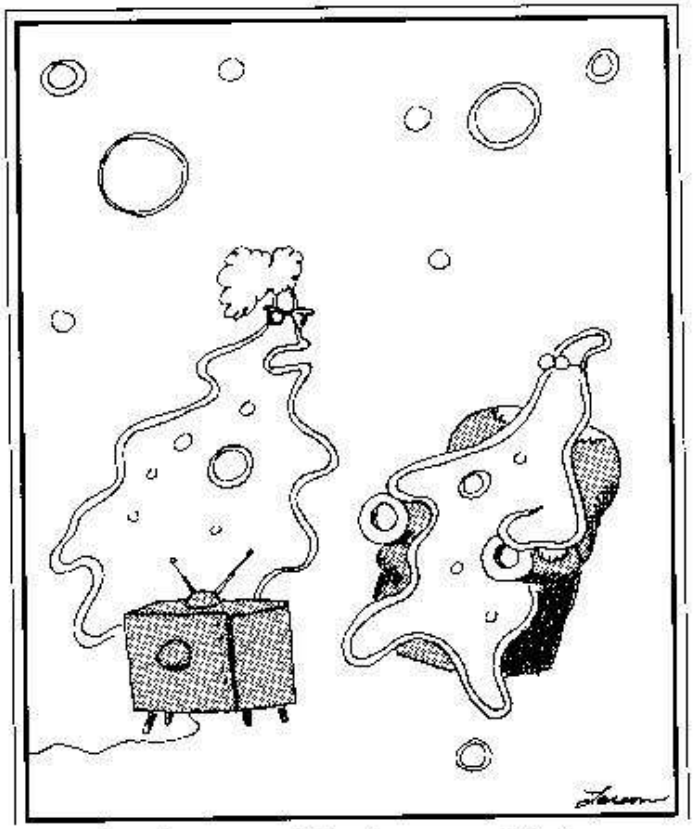

"Stimulus, response! Stimulus, response! Don't you ever *think*!"

Pelvic Organ Prolapse (POP) Surgical Repairs

- Anterior (cystocele) repair
- Posterior (rectocele) repair
- A+P Repair
- Kelly plication
- Retropubic urethropexy
- McCall
- High uterosacral ligament colposuspension (intraperitoneal colpopexy)
- Sacrospinous ligament fixation /colposuspension (extraperitoneal colpopexy)
- Iliococcygeus colposuspension
- Sacrocolpopexy
- Obliterative procedures (LeFort colpocleisis, colpectomy)

Surgical Correction of Utero-Vaginal Prolapse

- Native tissue vs. graft augmented
- Approaches
  - Trans-vaginal
  - Trans-abdominal
- Compartment
  - Anterior
  - Posterior
  - Apical
- Categorization
  - **Reconstructive** (restorative)
    - USL colposuspension, SSL fixation
  - **Compensatory**
    - Sacrocolpopexy, Sacrohysteropexy, Sacrocervicopexy
  - **Obliterative**
    - Colpectomy, Colpocleisis

Anterior Compartment

- Anterior is most common site of vaginal prolapse
- High incidence of recurrence after repair (30-70%)—depending on definition
- Subjective cure is higher than objective cure
- More than 50% of anterior support is from apical support

50% of anterior vaginal support is apical support

- Am J Obstet Gynecol. 2006 May;194(5):1438-43. Epub 2006 Mar 30.
- **The relationship between anterior and apical compartment support.**
- Summers A[1], Winkel LA, Hussain HK, DeLancey JO.
- **Author information**
- [1]Department of Obstetrics and Gynecology, University of Michigan, Ann Arbor, MI, USA.
- **Abstract**
- **OBJECTIVE:**
- The purpose of this study was to determine whether the degree of anterior compartment (bladder) and apical compartment (cervix) prolapse are correlated, and whether 2 anterior compartment elements (urethra and bladder) are related at maximal Valsalva.
- **STUDY DESIGN:**
- Women with a complete spectrum of pelvic support were recruited for a pelvic support study. Dynamic magnetic resonance scans were taken during Valsalva. A convenience sample of 153 women with a mean age of 53.3 +/- 12.5 (SD) years with a uterus in situ was studied. Anterior compartment status was assessed by the most caudal bladder point and the internal urinary meatus. The external cervical os was used to assess the apical compartment. The position of the bladder, urethra, and uterus were determined in 20 nulliparous women to determine their reference locations. The distances of each structure below the reference positions were calculated at maximum Valsalva.
- **RESULTS:**
- Average distances of the bladder base, urethra, and uterus from the reference positions at maximal Valsalva were 4.1 +/- 2.4 cm, 3.1 +/- 1.3 cm, and 4.3 +/- 2.4 cm, respectively. The Pearson correlation coefficient of the relationship between the bladder base and uterine distances was r = 0.73 (r2 = 0.53). The Pearson correlation coefficient of the bladder distance and urethral distance was r = 0.82 (r2 = 0.67).
- CONCLUSION:
- Half of the observed variation in anterior compartment support may be explained by apical support.

Association of anterior vaginal wall prolapse and apical prolapse

Advanced anterior vaginal wall prolapse is highly correlated with apical prolapse Rooney, Kenton, et al
Am J Obstet Gynecol 2006 195,1837-40

- Recurrent vaginal prolapse- cause remains controversial
- Difficult to differentiate persistence from recurrence
- 325 women cohort
  - Anterior prolapse occurred more frequently than apical or posterior
  - Strong linear correlation between Points C and Ba
  - Not affected by history of hysterectomy
  - Higher stage anterior prolapse more likely to have had hysterectomy
- Conclusion: Anterior vaginal wall prolapse is associated strongly with apical prolapse. Anterior vaginal wall defects that are surgically repaired usually require a concomitant repair of the apex.

Outcomes of Vaginal Prolapse Surgery Among Female Medicare Beneficiaries- The Role of Apical Support
Eilber KS, Alperin M,Khan A, Wu N, Pashos CL, Clemens JQ, Anger J
***Obstet and Gynecol* Vol 122, NO. 5, November 2013**

- 10 yr f/u of 2756 women ant colporrhaphy, post colporrhaphy, or both w/ or w/o apical suspension
- Reoperation rate twice as high for women who had isolated anterior colporrhaphy vs women who had anterior colporrhaphy with apical suspension procedure (20.2% vs 11.6%) .

Anterior prolapse (cystocele)

- Anterior vaginal prolapse is:
  1. most common
  2. highest recurrence
  3. nearly always associated with apical defect

Full thickness

Split thickness

Split and imbricate

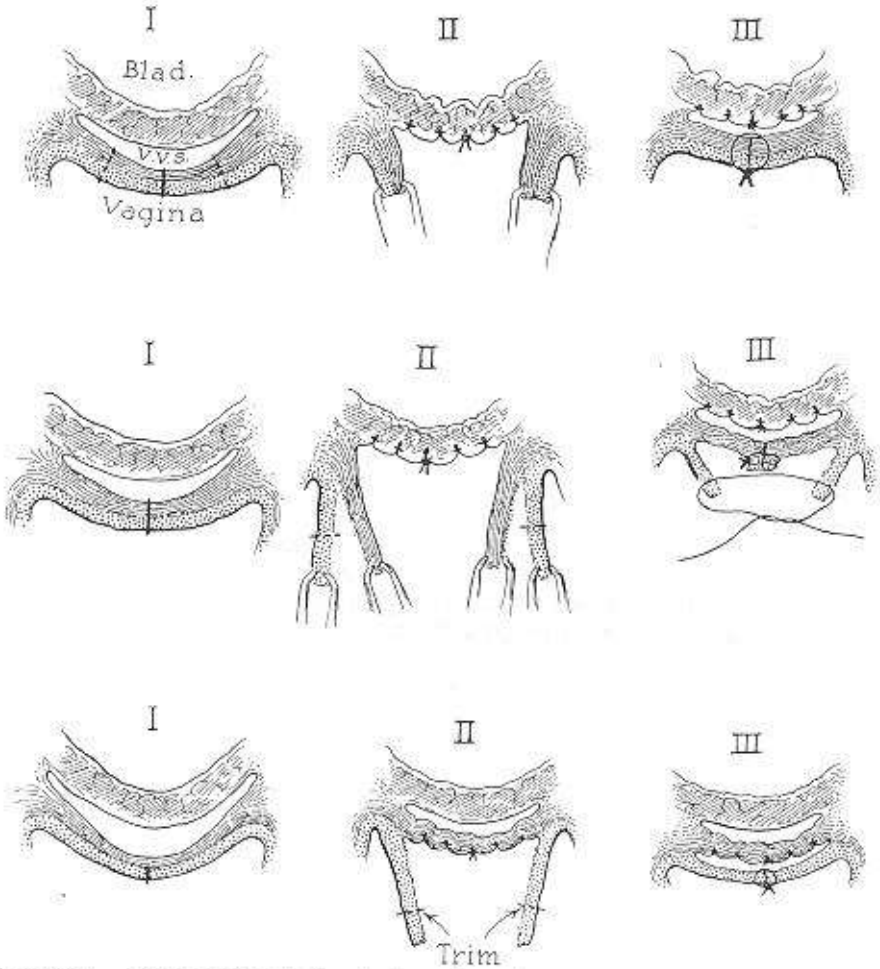

Figure 11.9 Three methods of

Transverse Cystocele

Most common or least common type?

- ***Transverse Cystocele (5% or 95% ?)***
  - Occurs from anterior disruption of pericervical ring during childbirth (where is narrowest pelvic diameter and at what level does this lie?)
  - Usually associated with superior paravaginal defect
  - "These are the only real causes of cystocele"-Kovac & Stubbs *Advances in Reconstructive Vaginal Surgery 2007*
  - "Site specific" defect repair

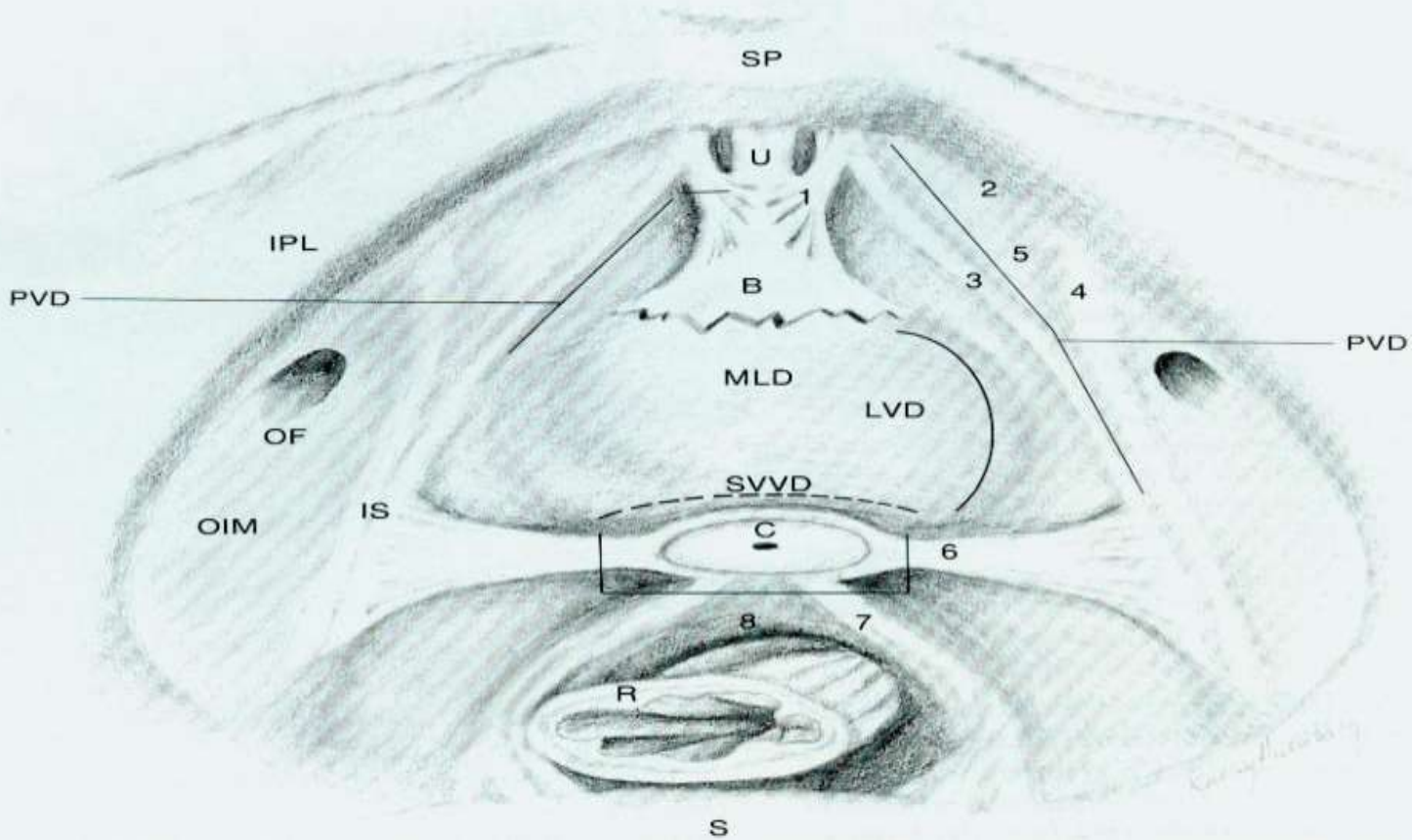

Figure 3–10. Fascial "framework" of vaginal supports. Structures: B, bladder; C, cervix; IPL, iliopectineal line; IS, ischial spine; OF, obturator foramen; OIM, obturator internus muscle; R, rectum; S, sacrum; SP, symphysis pubis; U, urethra. Fascial "sheath" defects (*solid lines*): MLD, midline defects; SVVD, superior vesicovaginal defects. Supports: 1, posterior pubourethral ligament; 2, anterior levator arch (ALA); 3, arcus tendineus fascia pelvis (paravaginal levator arch); 4, arcus tendineus levator ani (lateral levator arch); 5, superficial fascia levator ani; 6, paracervical ligament; 7, uterosacral ligament; 8, cul-de-sac. "Sheath support" defects (*broken lines*): LVD, lateral vesicovaginal defects; PVD, paravaginal defects. The fascial "framework" shows endopelvic fascial supports from above. Pararectal and perineal supports are not visible in this view.

From Baden & Walker

Surgical Repair of Vaginal Defects 1992

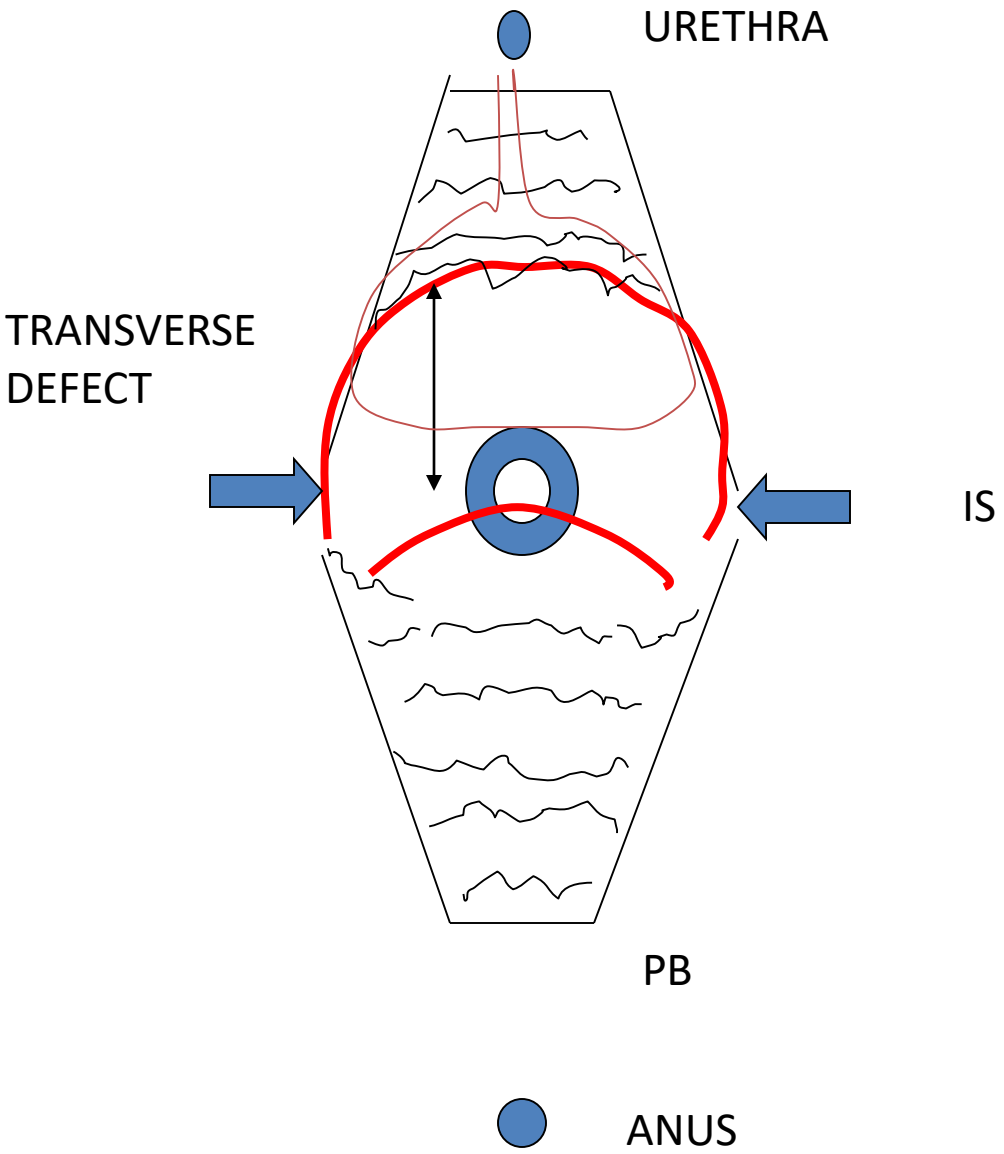
URETHRA
TRANSVERSE
DEFECT
IS
PB
ANUS

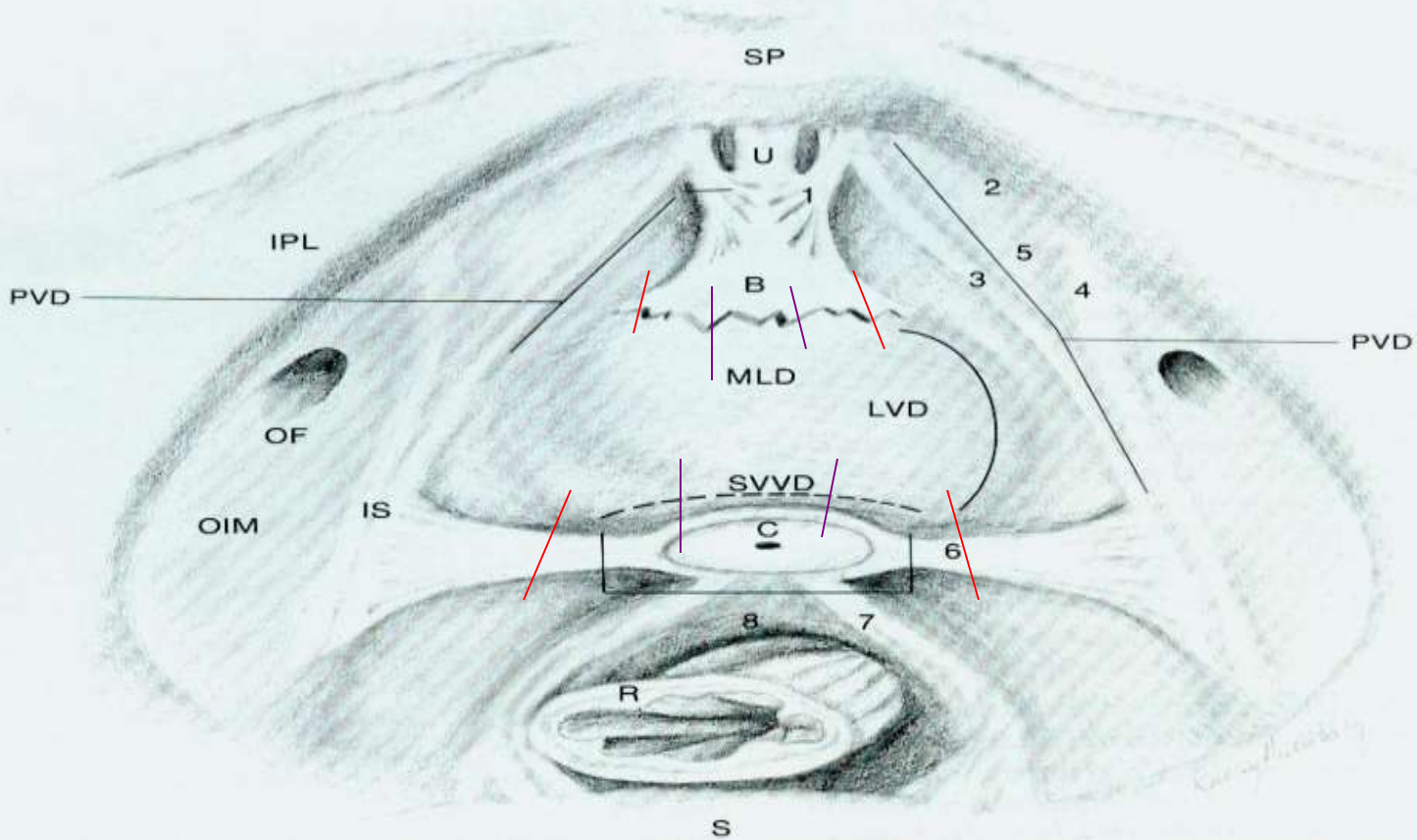

Figure 3–10. Fascial "framework" of vaginal supports. Structures: **B**, bladder; **C**, cervix; **IPL**, iliopectineal line; **IS**, ischial spine; **OF**, obturator foramen; **OIM**, obturator internus muscle; **R**, rectum; **S**, sacrum; **SP**, symphysis pubis; **U**, urethra. Fascial "sheath" defects (*solid lines*): **MLD**, midline defects; **SVVD**, superior vesicovaginal defects. Supports: 1, posterior pubourethral ligament; 2, anterior levator arch (ALA); 3, arcus tendineus fascia pelvis (paravaginal levator arch); 4, arcus tendineus levator ani (lateral levator arch); 5, superficial fascia levator ani; 6, paracervical ligament; 7, uterosacral ligament; 8, cul-de-sac. "Sheath support" defects (*broken lines*): **LVD**, lateral vesicovaginal defects; **PVD**, paravaginal defects. The fascial "framework" shows endopelvic fascial supports from above. Pararectal and perineal supports are not visible in this view.

Cystocele (anterior vaginal prolapse)

- A. Is highly correlated with apical (cervix or vaginal cuff) prolapse
- B. Surgical success is doubled with an apical suspension procedure in addition to traditional anterior colporrhaphy
- C. Is the most common observed vaginal compartment prolapse
- D. After a repair, has a higher risk of recurrent prolapse compared to rectocele

Posterior Compartment repair Similar to anterior

- Higher success than anterior
- Recurrence risk up to 18%
- De novo dyspareunia up to 18%
- Site specific vs muscle splitting vs levatorplasty
- MESH (synthetic or biograft) DO NOT improve outcomes.
- Improves abnormal defecation in 2/3

APICAL SUSPENSION PROCEDURES

- UTEROSACRAL LIGAMENT COLPOSUSPENSION= INTRAPERITONEAL COLPOPEXY
- SACROSPINOUS LIGAMENT COLPOSUSPENSION= EXTRAPERITONEAL COLPOPEXY
- SACROCOLPOPEXY

Use of uterosacral ligaments for vaginal apical reattachment

INTRA-PERITONEAL COLPOPEXY

High USL colposuspension / McCall cul de plasty

- Advantages
  - Less dissection
  - Restores natural upper vaginal axis
  - Less risk/morbidity than other vaginal procedures?
  - Just as efficacious as SSLF
- Disadvantages
  - May not be able to identify adequate “ligaments”
  - Cystoscopy required- ureteral obstruct /injury 2%

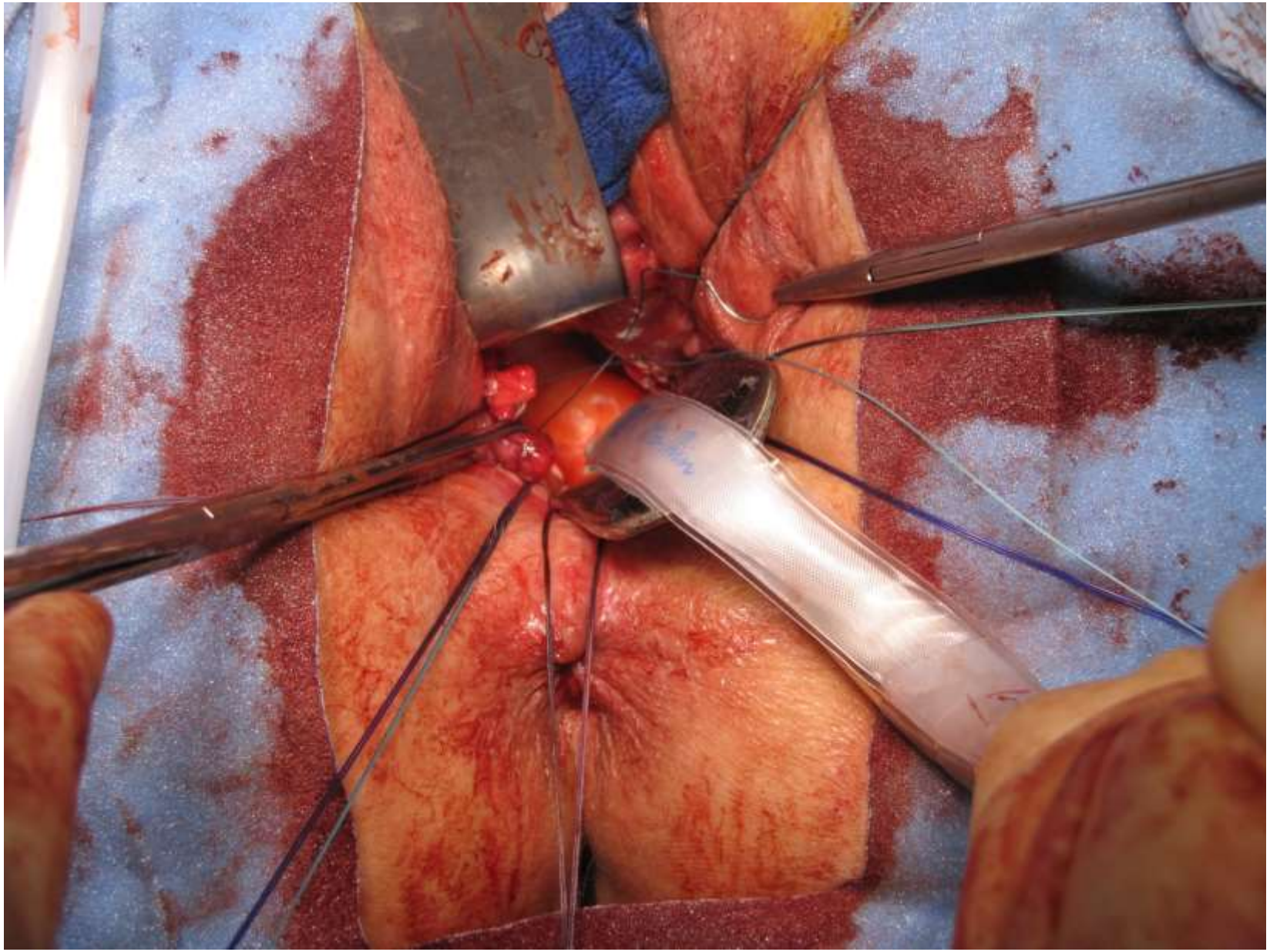

Sacrospinous Ligament Suspension (fixation)
EXTRA-PERITONEAL COLPOPEXY

- Attaches vaginal apex to sacrospinous ligament / coccygeus muscle complex
- Unilateral (traditional) or bilateral
- Permanent suture (delayed absorbable?)
- Access usually via posterior dissection-pararectal space, can be done via anterior dissection (blind application)
- Risks-bleeding, nerve injury, gluteal pain

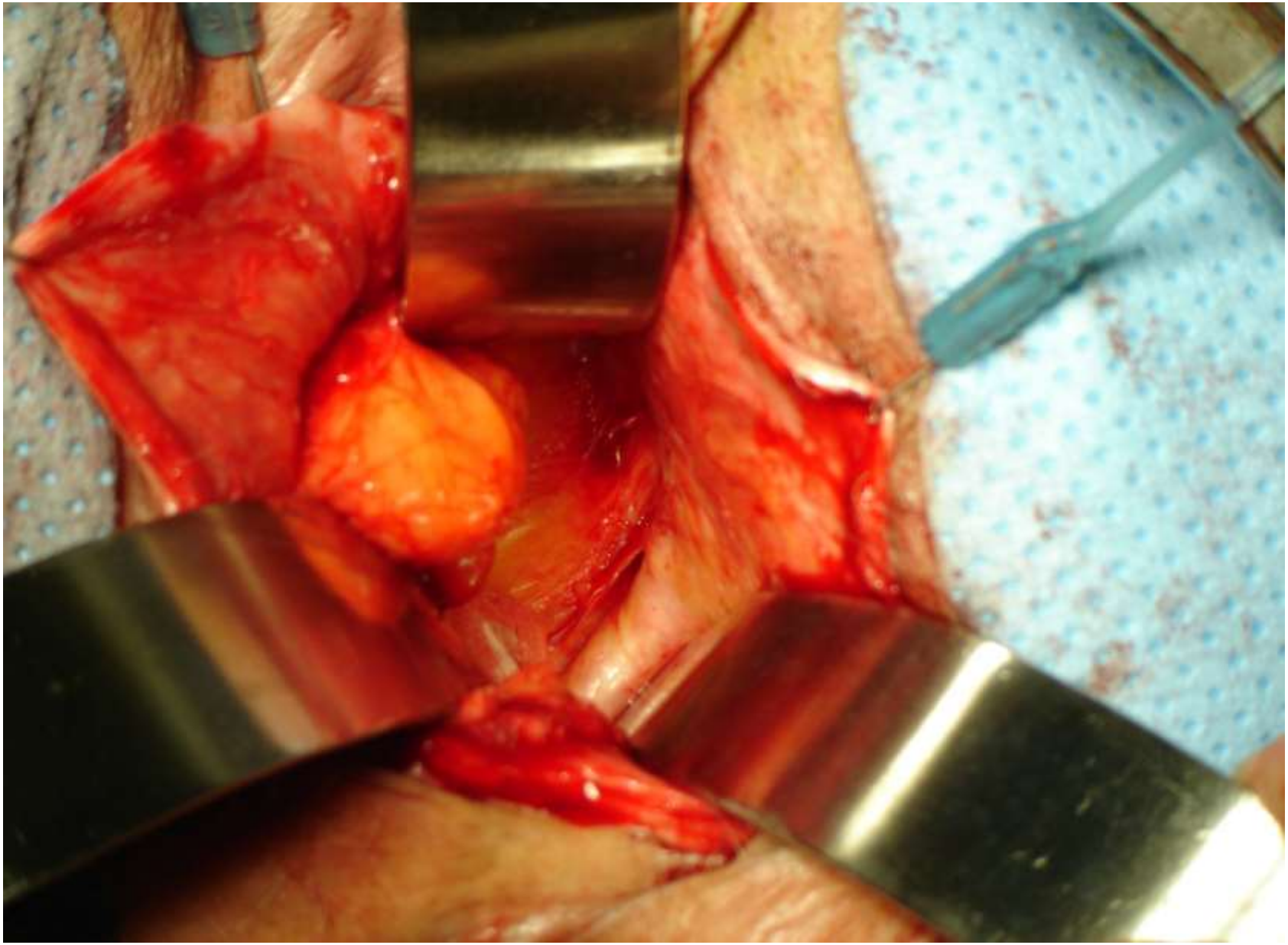

The abdominal sacral colpopexy:

Uses synthetic graft material

Dissection avoids opening of the vaginal wall

Requires precise dissection of the presacral space to avoid serious complications

Mesh to cover large surface area of vagina with multiple attachment points (dissection in vesico-vaginal space, rectovaginal space, presacral space)

Sacrocolopopexy- INDICATIONS

- Preserve vagina
- Preserve sexual function (shortened vagina)
- Previous vaginal repair failure
- Vagina scarred / retracted
- Need Retropubic urethropexy (MMK-Burch)
- Neurogenic /Genetic basis for POP

Which of the following are true concerning surgery for a POPQ Stage II uterine prolapse ?

- A. Hysterectomy is always required to eliminate the weight (force) of the uterus on the vagina
- B. If hysterectomy is performed, the preferred route is trans-vaginal
- C. Hysterectomy is current standard of care uterine prolapse POP-Q Stage II or greater
- D. May be corrected by intra or extra peritoneal colpopexy
- E. B + D

Deviation of vaginal axis due to surgical repair
SCP, RPU, USLS, SSLS

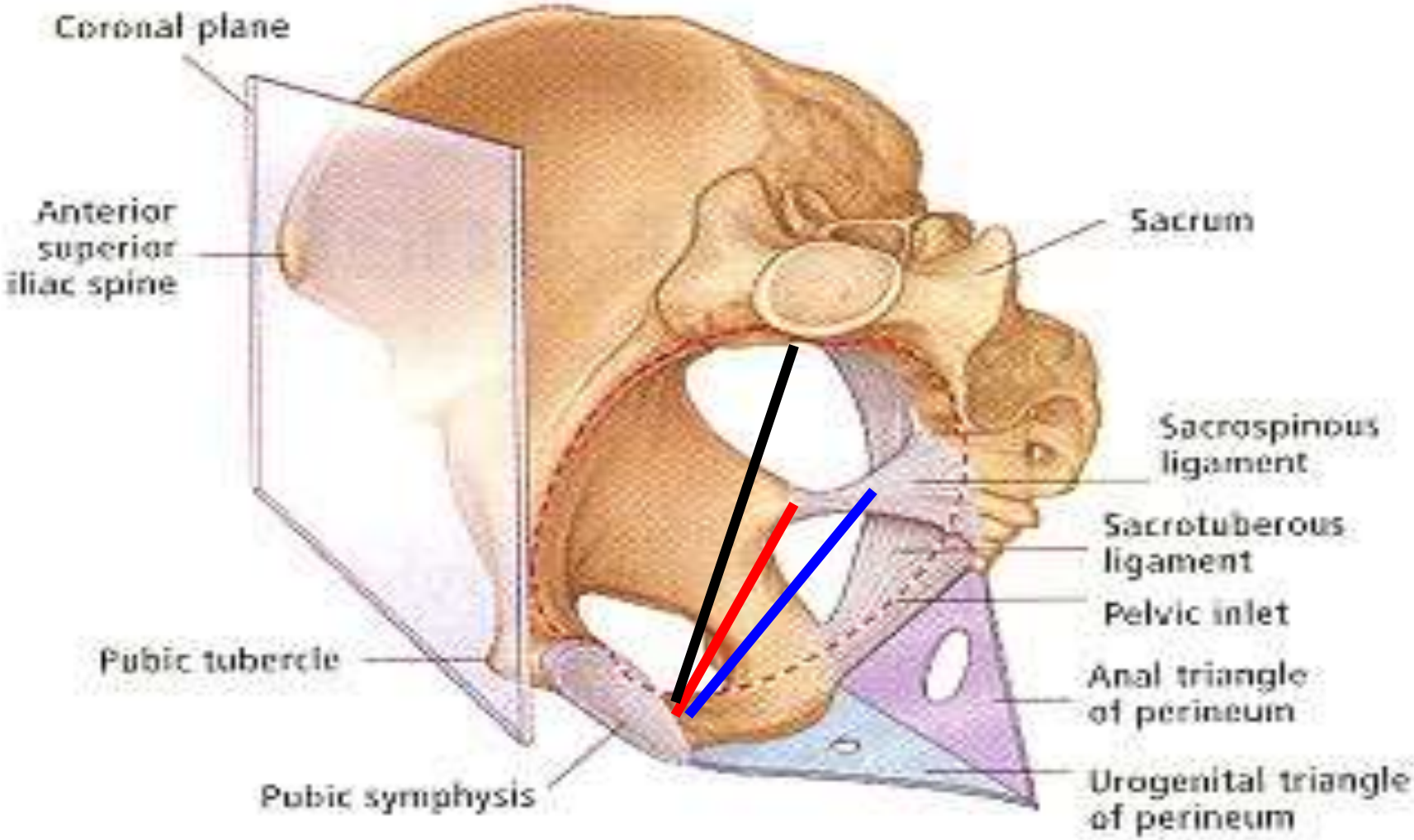

OBLITERATIVE PROCEDURES

LeFort colpocleisis

Colpectomy

Vaginal Obliterative Procedures

- Indications
  - No future desire for vaginal intercourse
  - Poor surgical risk for major operation / anesthesia
  - Unable to retain pessary
- Advantages
  - Quick
  - Less bleeding
  - Highly effective (if done properly)
- Disadvantages
  - Unable to assess AUB w/ LeFort
  - May require bladder neck support or MUS

Which of the following are true?

- A. Sacrocolpopexy has approximately a 6% risk of mesh erosion / exposure into the vagina
- B. LeFort colpocleisis is contraindicated in a woman desiring to preserve vaginal function
- C. Sacrocolpopexy deviates the vaginal axis more anterior to it's normal position
- D. Sacrocolpopexy carries risk of serious hemorrhage from the left common iliac vein, presacral/hypogastic veins, and presacral vessels.
- E. All above are true.

Before paper and scissors

The pelvic surgeon ideally is…..

- "… trained and prepared to perform a variety of operative techniques and to tailor the operation to the needs of the patient, rather than making all patients conform to his or her own specific skills."
  - Shull *Am J Obstet Gynecol* **1999** 181:6-11