Proximal Humeral Fractures

RSA v HHR

Xavier A. Duralde, MD
Peachtree Orthopaedic Clinic
Atlanta, GA

Proximal Humeral Fractures

RSA v HHR

Consultant: Smith+Nephew
Board of Directors: CORR

Introduction

- Incidence
  - PHF 5% of all fractures
  - 85%+ can be treated nonoperatively
  - 3 and 4-part fractures make up <5% of PHF
- All surgical candidates need to be generally healthy and able to comply with postop regimen

Introduction

- RSA v HHR
  - Indications
  - Technique
  - Comparative results

Basis of Comparison

RSA v HHR

- Functional results
  - ASES
  - Constant
- Radiographic results
  - Tuberosity healing
  - Notching
  - Loosening
- Morbidity/Mortality
  - Reoperation/revision rate
  - Mortality
- Costs

Overview

- Results of RSA for PHF are more consistent than HHR
  - HHR results inhomogeneous
- Well-done HHR has reasonable results
- Comparative studies are lacking due to heterogeneity of patient populations

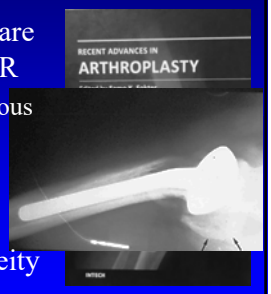

Trends in Treatment

- RSA use is rising
- 7714 patients treated with shoulder arthroplasty for PHF in 2011
- 2113 (27.4%) RSA
- 5604 (72.6%) HHR
  - Schairer, 2015

Treatment Challenges

HHR

- Functional Rotator Cuff is a prerequisite for a good outcome in HHR
  - AFE ~ 105° "All or none" (37-74%)
  - Nonunion/malunion in 50% of cases
    - Boileau
- RSA does not require tuberosity healing for reasonable result
  - Semi-constrained/fixed fulcrum
  - Fxn and stability better if tuberosities repaired

Indications for Arthroplasty

Proximal Humeral Fracture

- Complex 3 + 4-part fractures in elderly patients
  - Irreparable fractures
  - High risk of AVN
  - Poor tuberosity/ bone quality
  - Pre-existing RCT or arthritis
  - ? Varus fractures

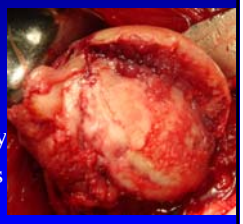

- Head split fractures

Contraindications

RSA

- Absolute
  - Axillary n./ plexus palsy
  - Global deltoid dysfunction
- Relative
  - Acromial/scapula fracture
  - Inadequate glenoid
  - Open fracture
  - Inability to comply with postop restrictions

RSA >HHR

- RSA definitely preferred in cases of pre-existing rotator cuff tear

Patient Evaluation

- H+P
  - General health
  - NV status
  - Functional demands

Patient Evaluation

- Radiographic Exam
  - Trauma series
  - CT scan with 3D

Surgical Technique

- Interscalene Block
  - Paralysis
- Beach chair
- Deltopectoral approach (?)
- Excision of HH
- Control of tuberosities

HHR

Surgical Technique

- Challenges
  - Loss of landmarks for prosthetic placement
    - Height
    - Version
  - Tuberosity fixation
    - Resistance to vertical and horizontal deforming forces

Stem Placement

- Stem characteristics
  - Narrow
  - Holes for bone graft
  - Ingrowth
- Version
  - 20 – 40° retroversion
  - Use forearm
  - Fin just posterior to bicipital groove = 30° retro

Stem Placement

- Height
  - Measure medial calcar fragment
  - Measure GT fragment
  - 56mm superior to pec insertion
  - Lengthening > 10mm associated with GT NU

Tuberosity Fixation

- Vertical and horizontal sutures
  - 1. Tuberosity to tuberosity around stem
  - 2. Shaft to tuberosity
  - Avoid over-reduction
    - 10-16 mm distal to HH

Poor Tuberosity Placement

Risk Factors

- Poor initial placement of prosthesis
- Poor initial placement of tuberosities
- Female patient
- Age >75
  - Boileau

RSA

Surgical Technique

- Glenoid preparation
  - Excellent exposure
  - Inferior placement and tilt of baseplate
  - Centered glenosphere as large as possible

Stem Placement

- Version ~20° retro
- Height
  - Check stability
    - Axial shuck test
    - Strap tightness
    - Lateral instability
- Adjust tension
  - Stem height, liner
  - Glenoid

Tuberosity Fixation

- Vertical and horizontal sutures
- Functional results better with repair than excision
- Healing more reliable than in HHR
  - ? Stress shielding

Postoperative Management

- Sling/passive motion
  - 6 weeks
  - Check healing radiographically
- Active-assisted at 6 weeks
- Resistive exercises at 12 weeks

Results

HHR

- Pain relief is reliable
- AFE 55-117°/ER 13-34°
- Revision rate 2-9%
- Patient satisfaction 61%
- Tuberosity healing 37-74%
- Complications 4-13%
  - Systematic reviews
  - Namdari '13, Mata-Fink '13, Ferrell '15

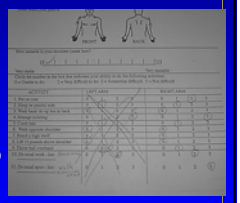

Results

RSA

- Pain relief reliable
- AFE 97-139
- Tuberosity healing 64-84%
- ASES 70-90
- Constant ~60
- Scapular notching 0-52%
- Complications 10-20%

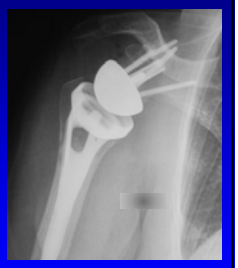

Complications

RSA

- Humeral loosening 3.5%
- Instability 2.5%
- Glenoid loosening 2.5%
- Infection 1%

Tuberosity Healing

- 55yo office manager
- Slip and fall on ice 1/19/16
- HHR 1/21/16
- Axillary nerve palsy
- GT displacement 7/20/16
- Revision to RSA 10/17/16

Comparative Studies

- Multiple studies including Meta analyses
- Tend to favor RSA > HHR
- Not comparable groups
  - Gallinet 2009, Young 2010, Garrigues 2013, Cuff 2013, Chalmers 2014, Baudi 2014, Sevastia-Forcada 2014
  - Metanalyses – Shukla 2015, Wang 2015
  - Systematic reviews - Namdari '13, Mata-Fink '13, Ferrell '15

Comparative Studies

Who wins?

	RSA	HHR
Tuberosity Healing	+	
Forward Elevation	+	
Abduction	+	
Active Rotation		+
Constant Score	+	
DASH Score	+	
ASES Score	+	

Comparative Studies

Who wins?

	RSA	HHR
Complications		+
Revision rate	+	
Reoperation rate		+
Mortality	=	=
Costs	+	

Speaker's Preference

- ORIF v RSA
  - Locking plate even in some severe cases in young patients
  - RSA in older patients

Summary

- The need for shoulder arthroplasty for proximal humeral fracture is indicated in < 5% of patients
- Results of RSA are more reliable than HHR because a reasonable result can be obtained even in the face of tuberosity nonunion or malunion in RSA but not HHR
  - "All or none" with HHR

Summary

- Determination of stem height and version critical with shoulder arthroplasty for fracture
- Tuberosity fixation must resist vertical and horizontal deforming forces
- Proximal humeral locking plate has increased the indication for ORIF and should be considered in younger patients

Summary

- A well-performed HHR can still achieve good clinical results
  - Preexisting rotator cuff tear a contraindication
- Further evaluation of the RSA for fracture is required but it offers promising results in this challenging population
  - Complications remain a concern

Xavier A. Duralde, M.D.
PEACHTREE ORTHOPAEDIC CLINIC, P.A.