# DIAGNOSIS AND MANAGEMENT OF THE DIFFICULT OR SHARED AIRWAY

Paul Harvey FRCA

Derriford Hospital, Plymouth.

- Diagnosis and management of the difficult airway
- Failed intubation/ventilation
- Airway obstruction
- Airway management devices
- Awake intubation
- Anaesthesia and laser surgery

USA

More than 85 % of respiratorily related closed malpractice suits involve brain damage or death.

30 % of deaths attributable wholly to anaesthesia are from the inability to successfully manage very difficult airways (estimate).

J. Caplan
Anesthesiology 1990

## Editorial

Predicting difficult intubation – worthwhile exercise or pointless ritual ?

S.M.Yentis Anaesthesia, 2002, 57 p 105-9

**Preoperative airway evaluation using multi-slice three-dimentional computed tomography for a patient with severe tracheal stenosis**

K.Toyota BJA 93(6): 865-7 (2004)

Female 71 Thyroid carcinoma – severe tracheal stenosis

Multi-slice CT scan – simulated fibrescopic intubation showed tracheal mobility

Uneventful anaesthesia using same technique.

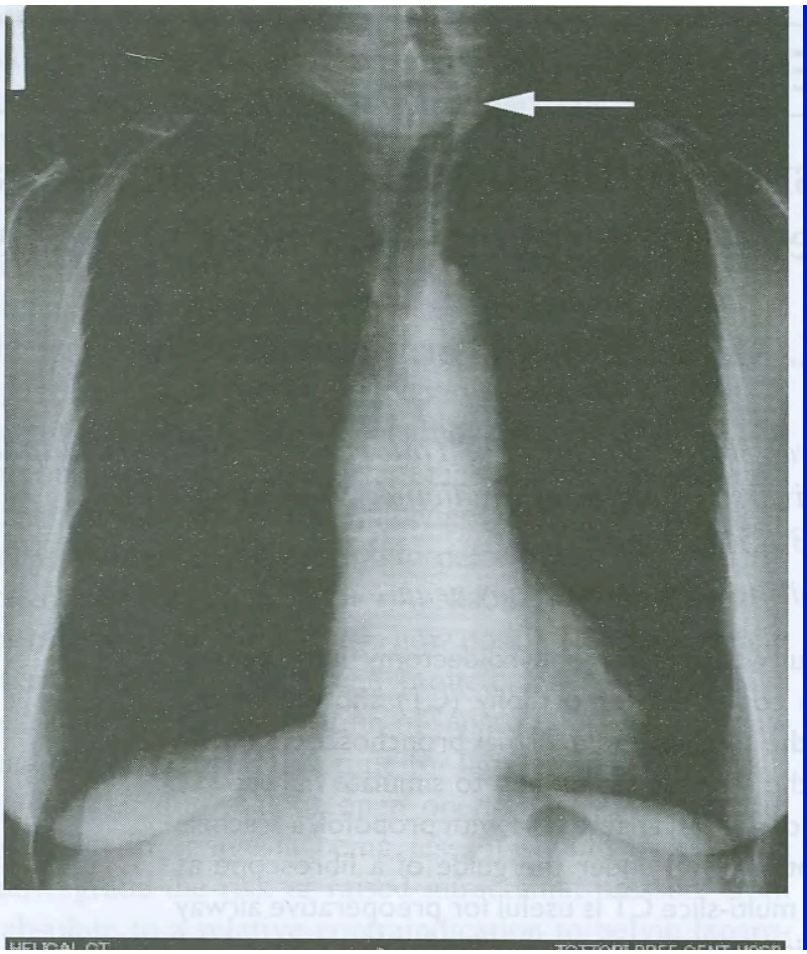

Multi-slice 3D CT

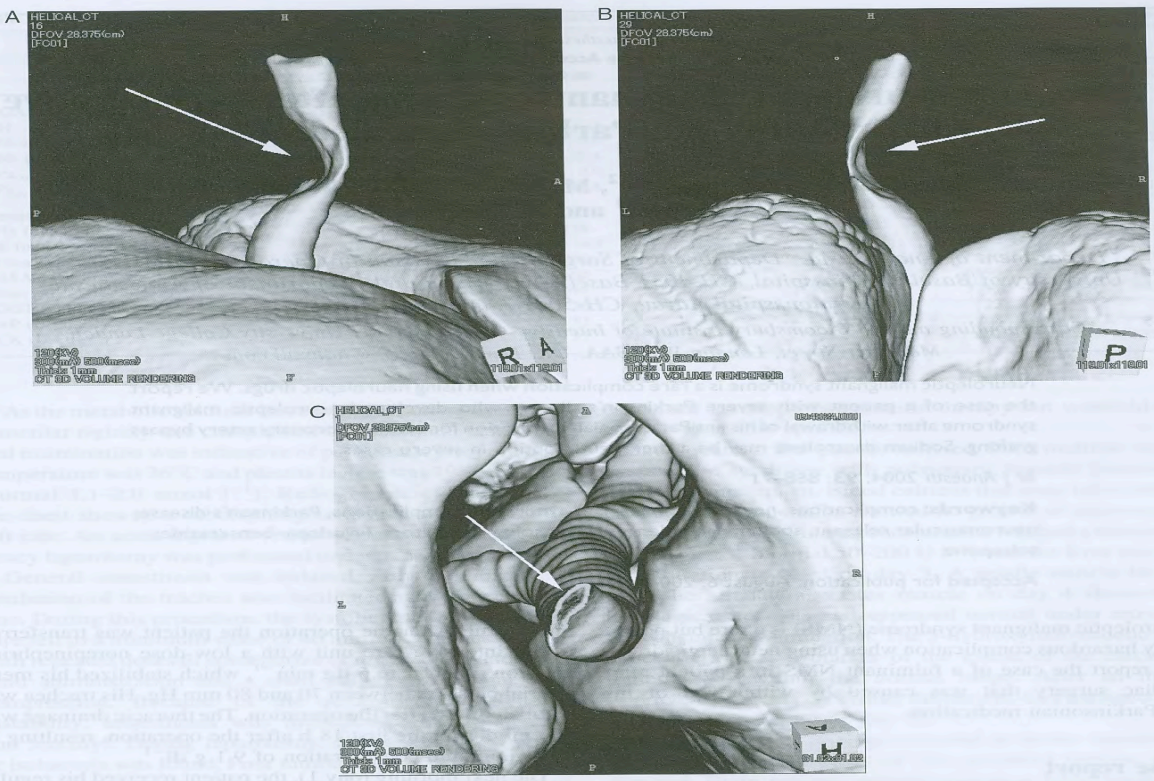


**Fig 2** 3D images of the trachea obtained from multi-slice CT. Diagonal right frontal view (A), rear view (B). Image (C) has been reconstructed downwards from the region of maximal narrowing. Arrows indicate the narrowest region of the trachea.

## Review

## Training in airway management

**K.R.Stringer, S.Bajenov and S.M.Yentis Anaes. 2002,57, 967-983**

- **Training aids**
- **Structured training programmes**
- **Learning curves and assessment**
- **Ethics**
- **Recommendations**

## MASK VENTILATION

Natural airway

Easy - chin lift only

One person - jaw thrust/ mask seal

One person - jaw thrust/ mask seal

Oropharyngeal(orNP) Airway (or both)

Two person - jaw thrust/ mask seal

ditto

Gas exchange unsatisfactory or non-existant

IF NOTHING FURTHER DONE = BRAIN DAMAGE OR DEATH

## LARYNGOSCOPY AND INTUBATION

1 attempt, increasing lifting force

1 attempt, increasing force and reposition head

GRADE 1 or 2 view

Multiple attempts, external pressure, different blades, introducers and bougies

Multiple attempts by more than one laryngoscopist

GRADE 3 or 4 view

Failure /impossible

If oxygenation not guaranteed by other means

BRAIN DAMAGE / DEATH

(Benumof, Anesthesiology 1991)

## INCIDENCE OF EACH DEGREE OF AIRWAY DIFFICULTY

| | |
|---|---|
| 2 or 3 | 1 to 18% |
| Definite 3 | 1 to 4 % |

Failed intubation ( ? severe grade 3 or 4 ) : 0.05 - 0.35%

CAN`T INTUBATE / CAN`T VENTILATE

0.01 - 2 of 10,000 patients

( Multiple authors )

However, in pregnancy –

- Obesity
- Restricted cervical spine movement
- Difficult laryngoscope insertion
- Reduced cardiorespiratory reserve
- Airway oedema (pregnancy induced HT)
- Haste, anxiety, stress

## Failed tracheal intubation in obstetrics: no more frequent but still managed badly

K.Rahman and J.G.Jenkins  Anaesthesia, 2005, 60, 168-171

SW Thames region of UK  1999-2003

4768 obstetric general anaesthetics

20 failed intubations (incidence 1:238)

Notes examined - half failed to follow accepted FTI protocol

## Trainees` experience of difficult and failed intubation in obstetrics

NL Lewis, F Plaat  Anaesthesia 2006,61,64-5 (letter)

173/390 OAA trainees responded

79% reported experience of difficult intubation

42 failed intubations

## Initial management of failed intubation

| | |
|---|---|
| Facemask +/- airway | 17 |
| Facemask, followed by LMA | 13 |
| LMA | 10 |
| Intubating LMA | 1 |
| Immediate intubation by senior help | 1 |

## Definitive management of failed intubation

| | |
|---|---|
| Converted to regional block | 10 |
| Awake fibreoptic intubation | 2 |
| Woken then re-anaesthetised by senior help | 2 |
| Spontaneous ventilation via LMA | 12 |
| Intubated by another anaesthetist | 11 |
| Spontaneous ventilation via facemask and airway | 2 |
| (Unreported) | 3 |

*All general anaesthetics for Caesarean Section should be induced in theatre with full monitoring*

**FAILED INTUBATION DRILL**
*( For obstetric anaesthesia)*

If McCoy laryngoscope and bougie do not rapidly achieve intubation, **do not** persist with repeated attempts. Risks of hypoxia, regurgitation, airway trauma etc. increase with time. Accept defeat and follow these guidelines.

- **Do not** give a second dose of suxamethonium.
- **Maintain** cricoid pressure.
- **Oxygenate** by facemask IPPV until breathing starts.
- **SUMMON IMMEDIATE SENIOR ANAESTHETIC ASSISTANCE.**
- **Aspirate** pharynx if necessary.
- **Then :**

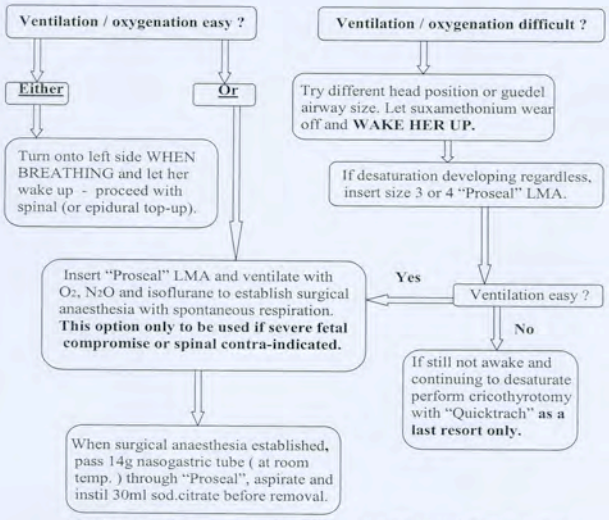


If spinal anaesthesia contra-indicated ( e.g. severe maternal haemorrhage ) or time very short ( e.g. severe fetal bradycardia ) and patient now awake, ask surgeon to proceed with local infiltration. PBH (Revised 6/2003)

**Failed intubation in obstetrics**

**Derriford 2004**

## "A Survey of Emergency Airway Management in the United Kingdom"

**B. Ratnayake & R. Langford  Anaesthesia October 96**

**Questionnaire to all R.C.A. tutors**
**( Response rate 74.9% )**

**Portex Minitrach (58.6 %) most often used**

**Complication rate 65 %, > half serious**

- failure to cannulate
- multiple attempts
- pneumothorax
- severe bleeding

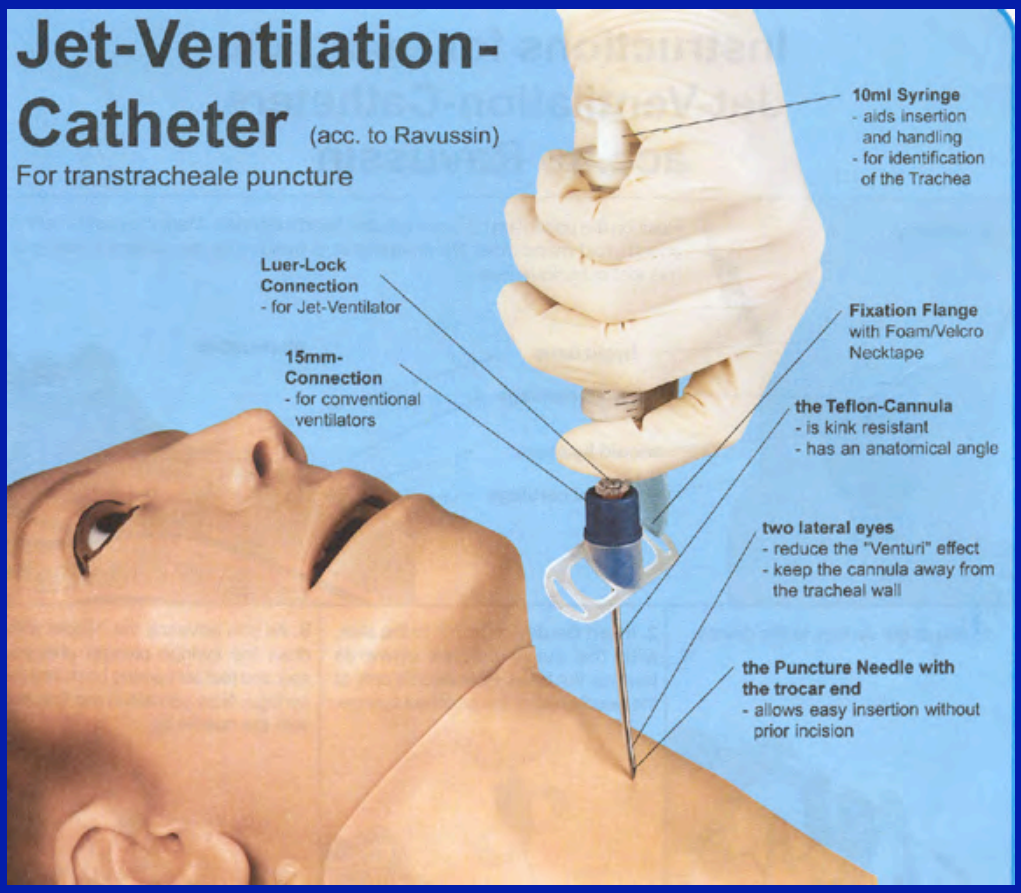


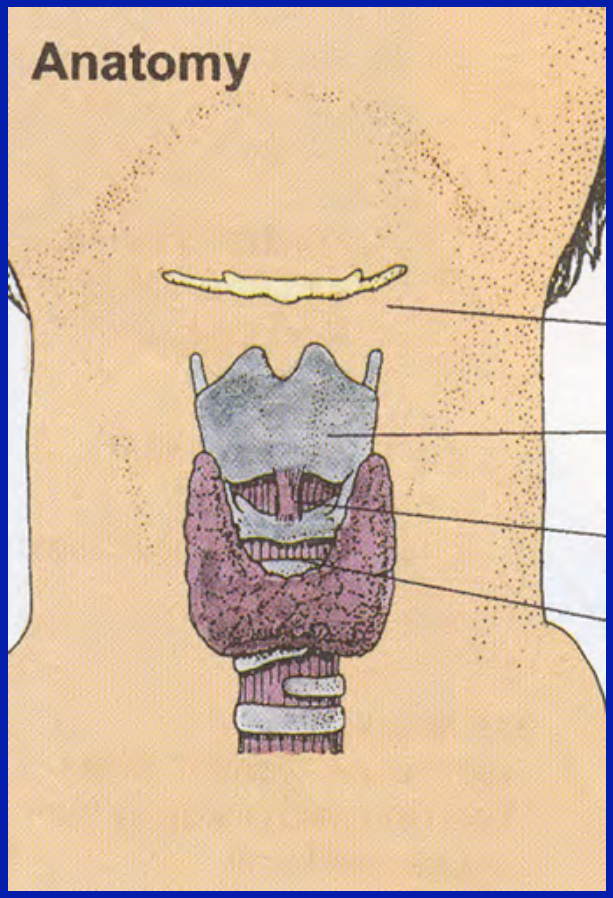


Hyoid bone

Thyroid cartilage

Cricothyroid membrane

Tracheal ring

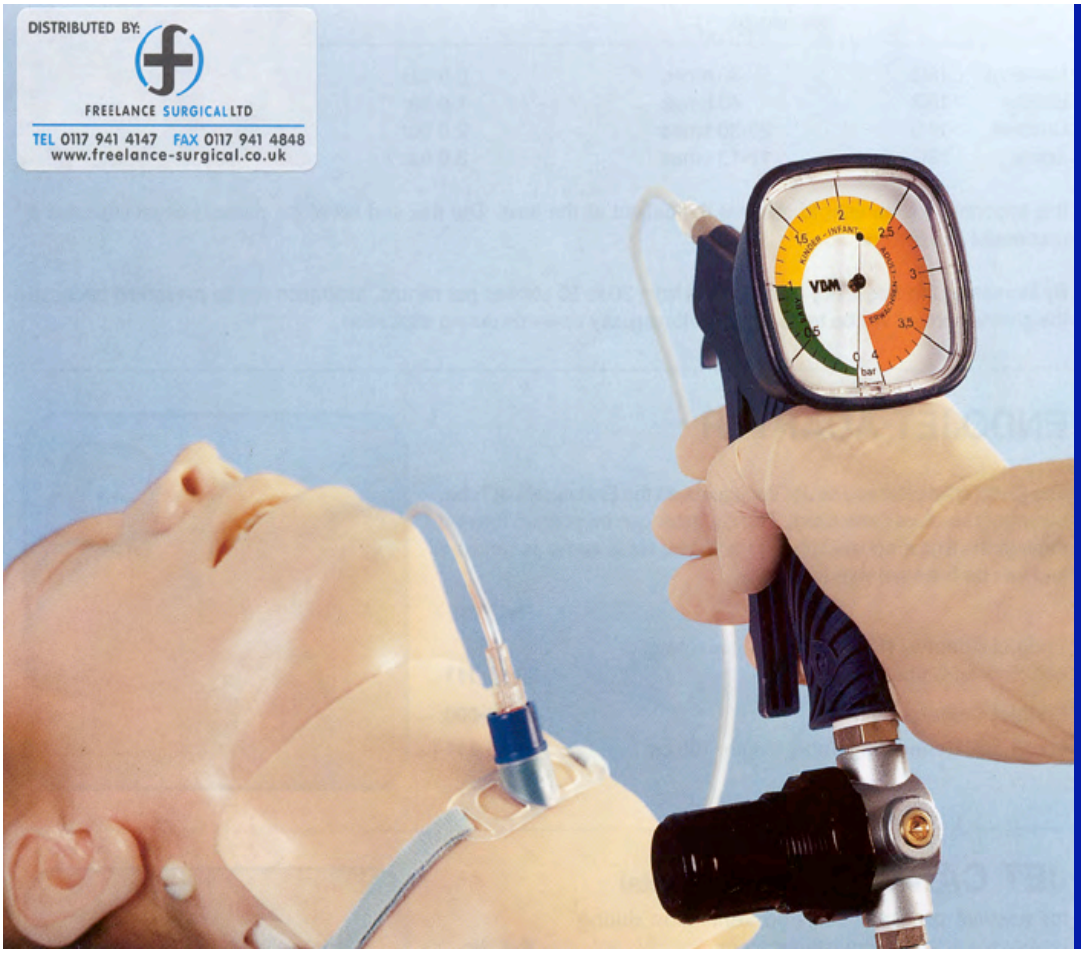


**Manujet III**

**VBM**

**Emergency cricothyrotomy: a randomised crossover trial comparing the wire-guided and catheter-over-needle techniques**

**B.G. Fikkers et al  Anaesthesia, 2004,59, 1008-1011**

**10 anaesthesiology, 10 ENT residents**

**Pig larynxes**

**Correct positioning 85% (WG) and 95% (CON)**

**Complication rate 5 and 1 respectively**

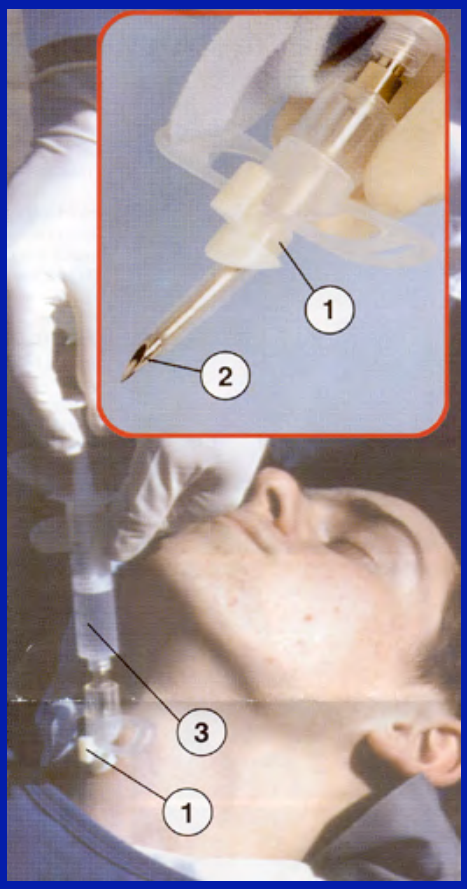


# “ Quicktrach “

**VBM Medizintechnik**

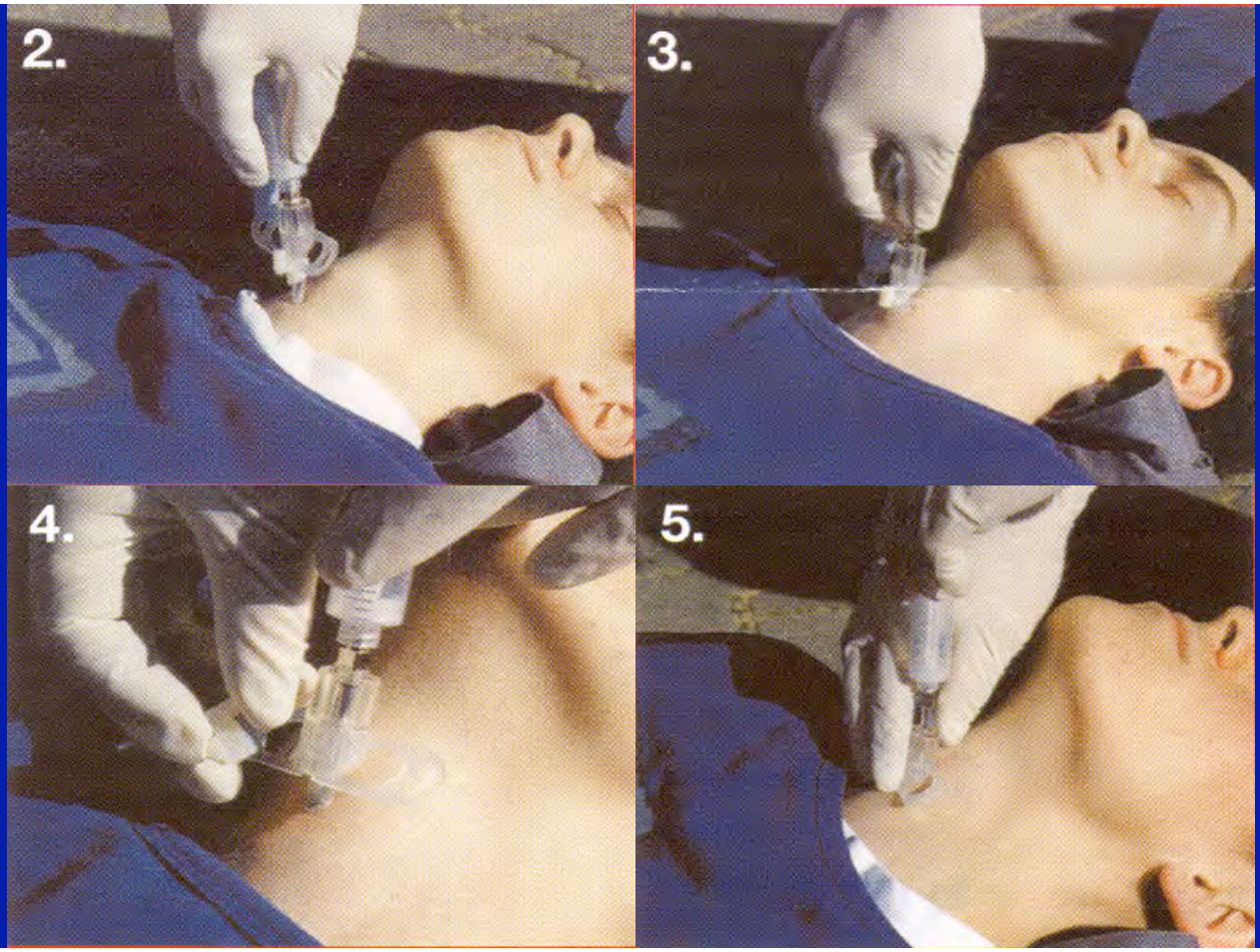


## COMPLICATIONS OF AIRWAY DIFFICULTY

**DIRECT TRAUMA** - *face, teeth etc. , upper airway*
*eyes, cervical spine, pulmonary*

**REFLEX ACTIVITY** - *laryngovagal , laryngosympathetic*

**INTERRUPTION OF GAS EXCHANGE** -
*hypoxia, hypercarbia*

**Increased difficulty = increased force = more complications**
**( 63 % in prolonged difficult intubation**
**- Bellhouse 1988, Anaes. and Intens. Care )**

## DIAGNOSIS OF THE DIFFICULT AIRWAY

**A. Pathological**

- *congenital facial and upper airway deformities*
- *maxillofacial airway trauma*
- *airway tumours and abscesses*
- *requirement for stable cervical spine*
- *fibrosis*
- *surgically induced deformities*
- *some systemic diseases*

**- ALL CONDITIONS WHICH MAY MAKE MASK VENTILATION DIFFICULT IN ITSELF.**

**( * NOT the cause of much morbidity or mortality )**

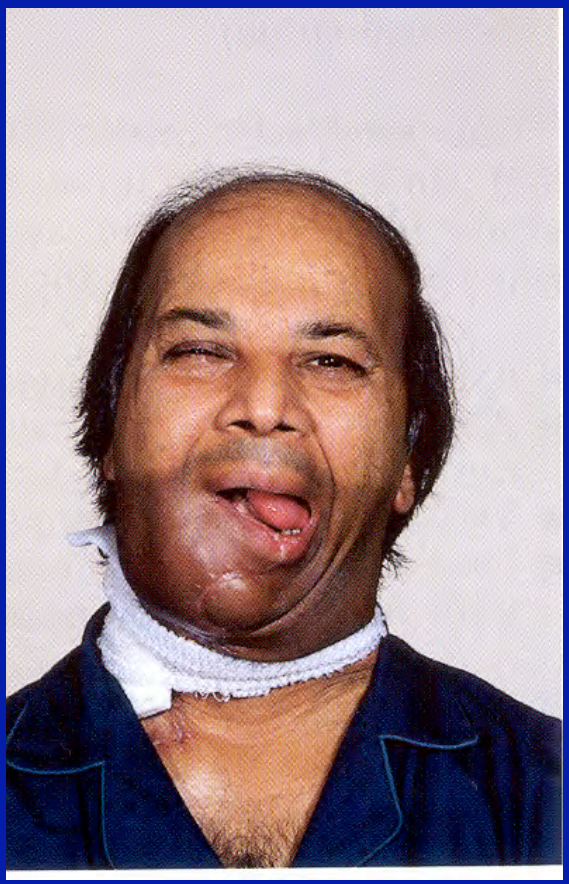

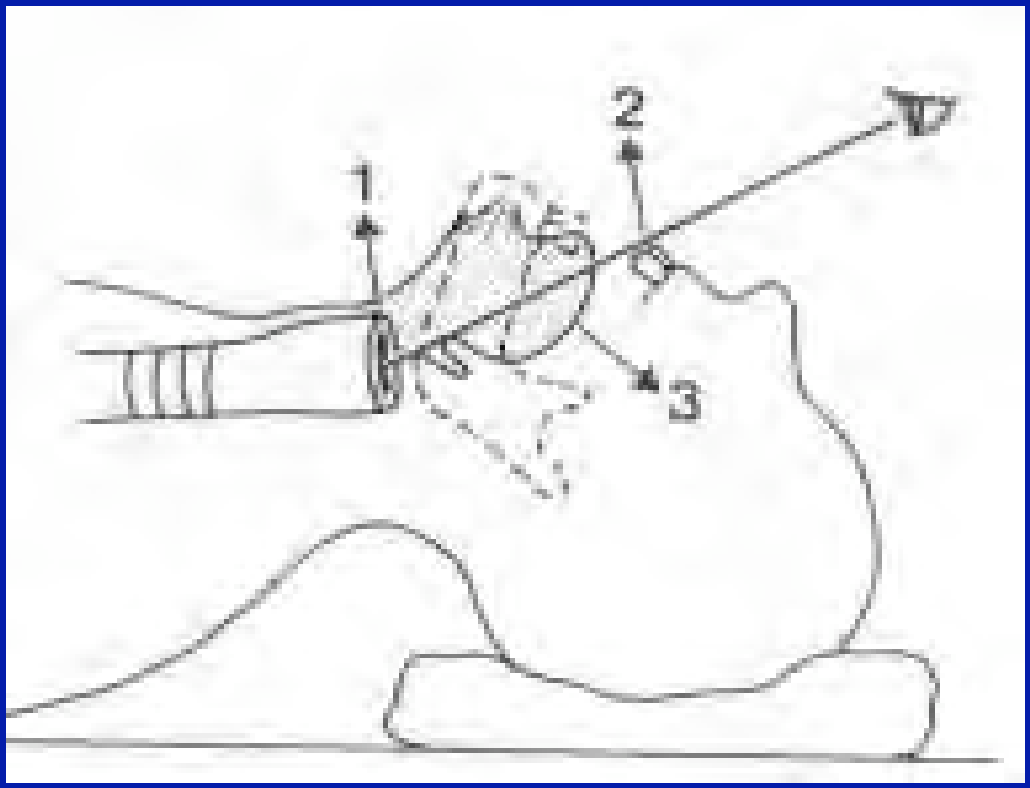


# Airway assessment

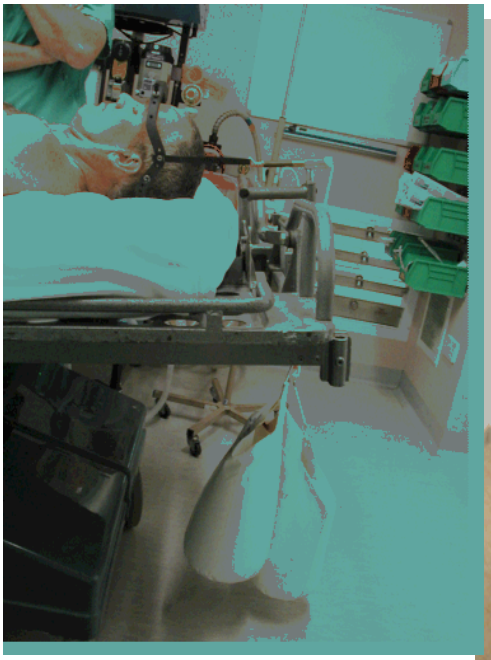

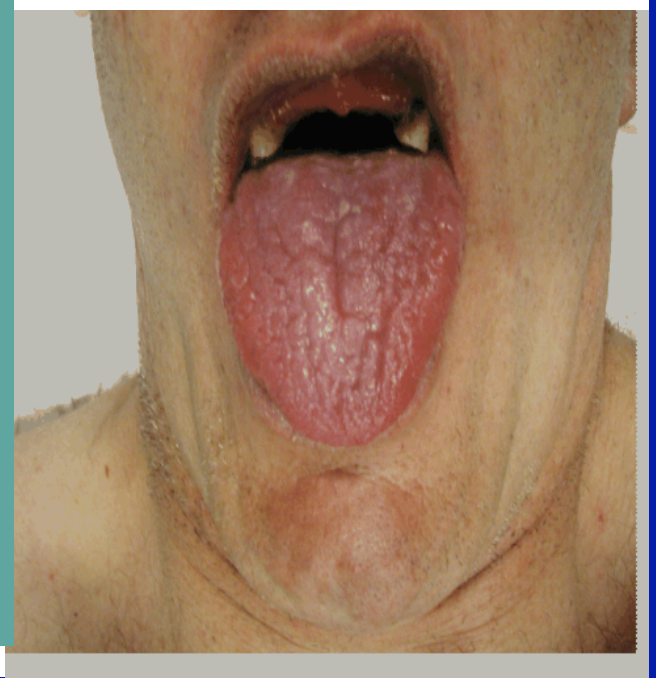

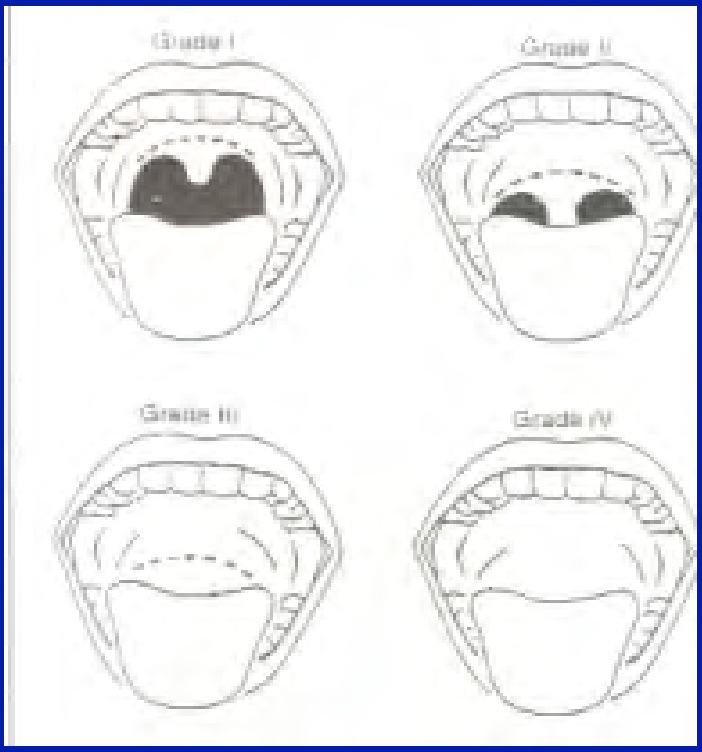


B. Anatomical

1. RELATIVE TONGUE TO PHARYNGEAL SIZE

Mallampati et al

Canadian Anes Soc J 1985

- may be 50 % false + predictor of difficult intubation

Wilson M.E.

Anaesthesia 1990

## 2. ATLANTO-OCCIPITAL JOINT EXTENSION

*35 degrees extension possible at the normal A-O joint*

Grading and reduction of A-O extension

| | |
|---|---|
| Grade 1 | None |
| 2 | One third |
| 3 | Two thirds |
| 4 | Complete |

( Implies very small occiput to C1 Gap )

## 3. MANDIBULAR SPACE

Thyromental/hyomental distance

Short T-M distance - laryngeal axis makes a more acute angle with pharyngeal axis.

T-M distance > 6 cm and horizontal mandibular length > 9 cm , direct laryngoscopy ( probably ) easy

## 4. OWN TEETH, OVERBITE

## RADIOGRAPHIC PREDICTORS

A : B > 3.6 : 1

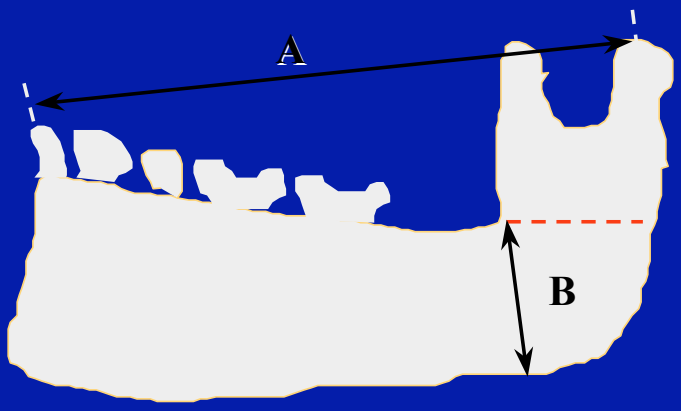


+ reduced atlanto - occipital gap

White & Kander Anaesthesia 1975

Why not a combination test ?

e.g. Mallampati + thyromental distance ( Frerk, Anaesthesia 91 )

## Sternomental distance as the sole predictor of difficult laryngoscopy in obstetric anaesthesia

SAL Ramadhani et al BJA 1996;77:312-316

523 parturients undergoing LSCS under GA

18 ( 3.5% ) classified as grade 3 or 4

Significant difference between sternomental distance in these as compared to grade 1 and 2

But – sensitivity 67% and specificity 71% only

## Predicting difficult intubation: a multivariable analysis

K. Karkouti et al Can J Anesth 2000/47:8/730-739

444 randomly selected patients + 27 classed as difficult previously

10 patients excluded – 38 of 461 classed as difficult to intubate

7 different airway tests used by one assessor blinded to intubation difficulty information

87% sensitivity

96% specificity

## Multivariable analysis predicted three tests that were highly significant in predicting difficult intubation

- Mouth opening
- Chin protrusion
- Atlanto-occipital extension

**P***rotrusion (at rest)*

**O***pening*

**T***hyromental*

**T***emporo-mandibular*

**E***xtension*

**D***entition*

**S***ize*

**P***rotrusion (chin thrust)*

**A***ppearance*

**M***allampati*

**L.Sanai Anaesthesia 1999,54,309**

## DIAGNOSTIC PLAN FOR DIFFICULT AIRWAY PREDICTION

1. Exclude pathological problems ( from history ) + CHECK ANAESTHETIC RECORDS. ASK ABOUT DENTURES ETC.
2. Perform Mallampati
3. Check mouth opening
4. Thyromental distance
5. Atlanto-occipital movement
6. Look for maxillary overbite and ability to jaw thrust

*from in front*

*from the side*

**SIMPLE, QUICK – includes Karkouti and more.**

# Difficult Airway Society guidelines for management of the unanticipated difficult intubation

J.J.Henderson et al  Anaesthesia, 2004, 59, 675-694

**Plan A:  Initial tracheal intubation plan**

**Plan B:  Secondary intubation plan**

**Plan C:  Maintenance of oxygenation & ventilation**

**Plan D:  Rescue techniques for "Can`t intubate, can`t ventilate situation"**

Basic structure of DAS Guidelines flow-chart

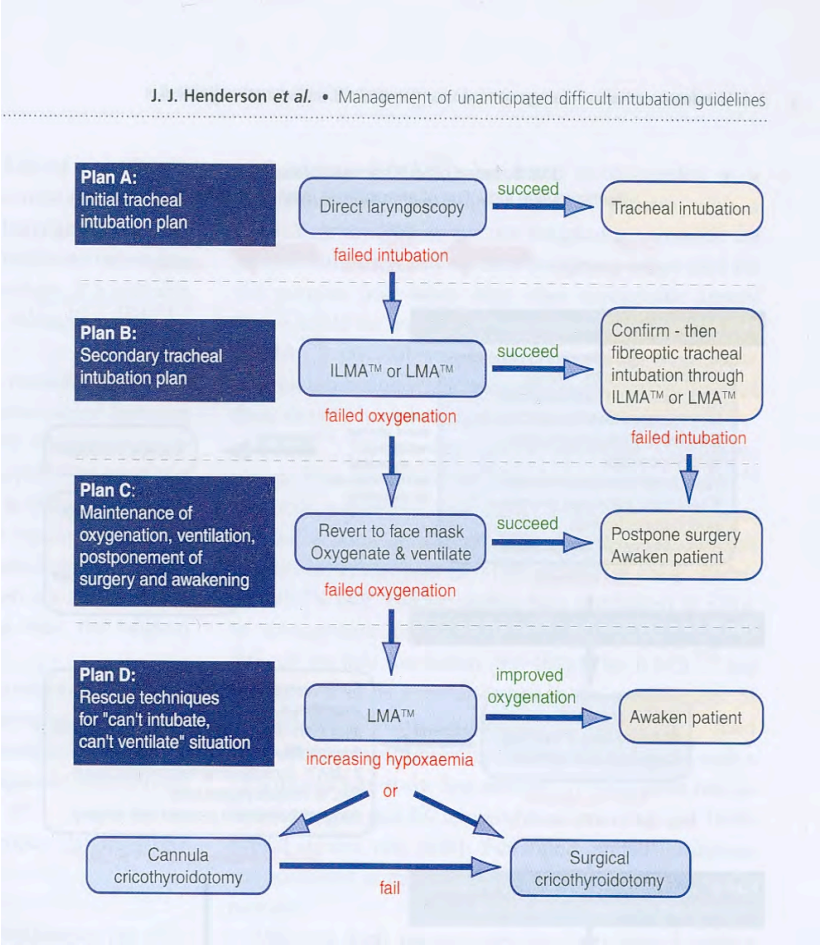


LARGE
Adult Bullard Elite
Laryngoscope


HEINE


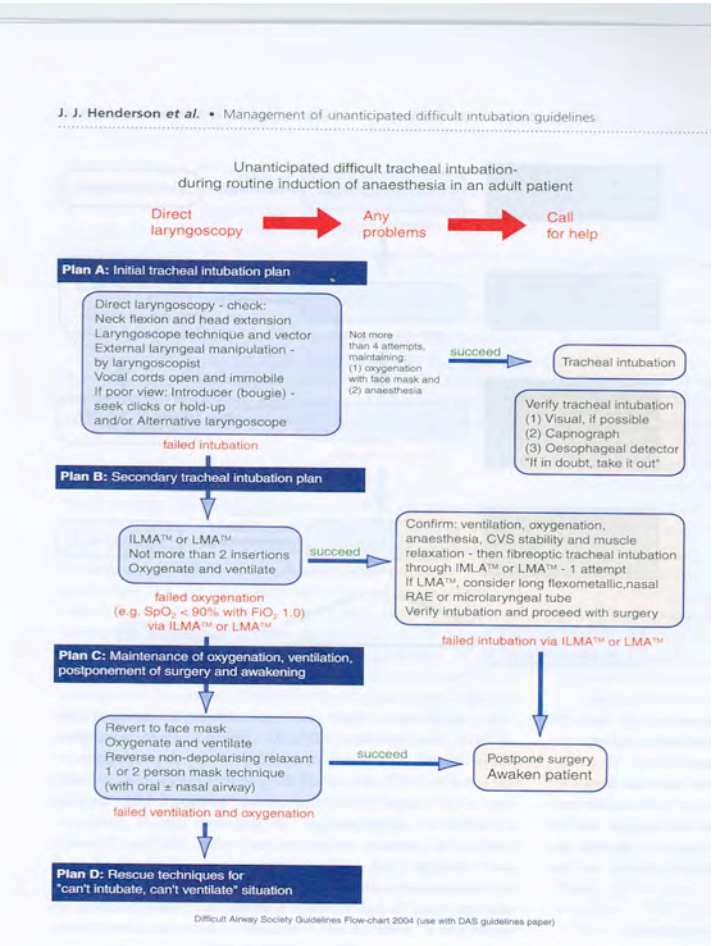


Management of unanticipated difficult tracheal intubation – during routine induction of anaesthesia in an adult patient

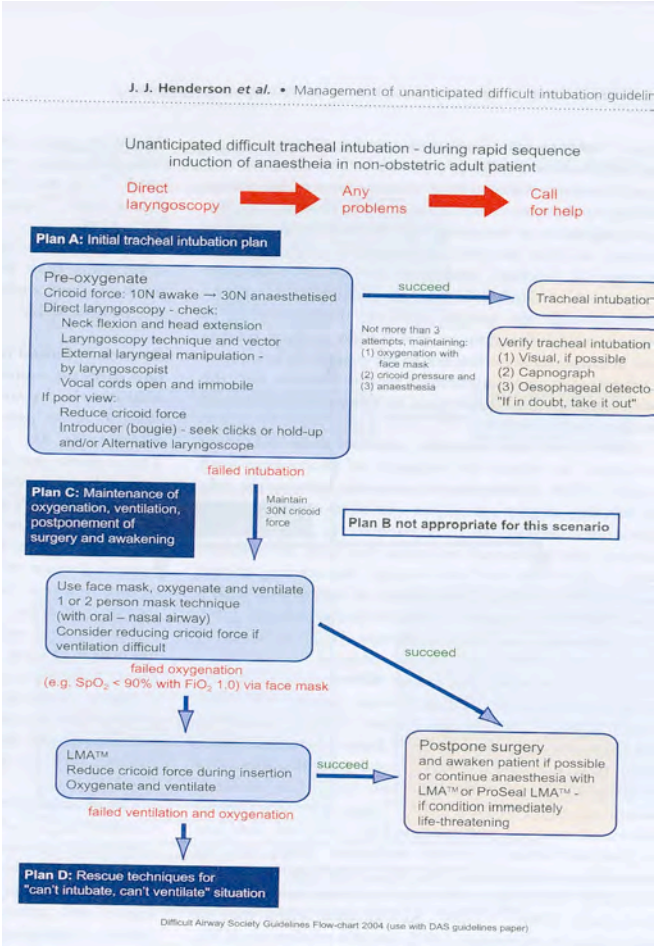


Management of unanticipated difficult tracheal intubation – during rapid sequence induction of anaesthesia (with succinylcholine) in a non-obstetric patient

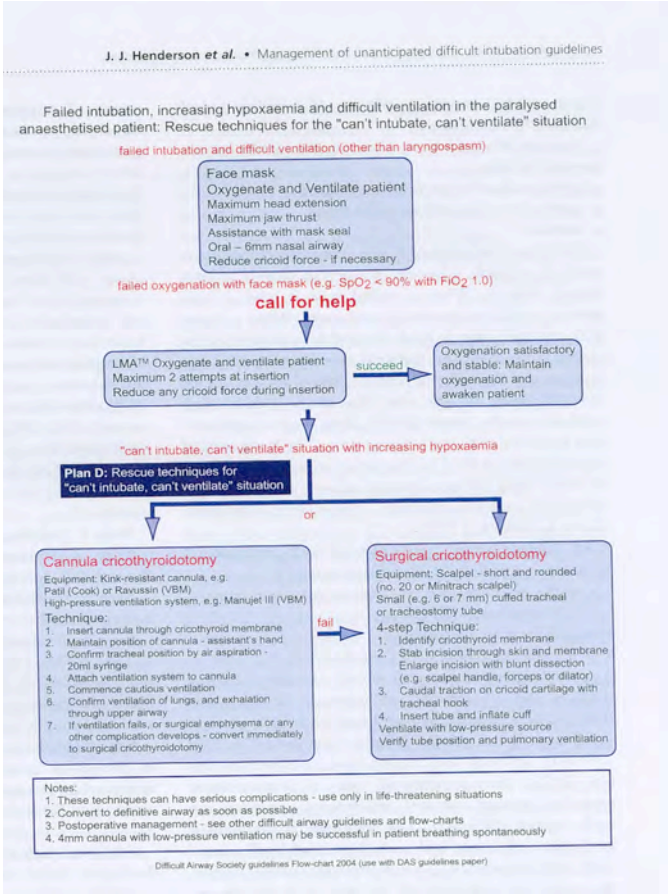


Management of failed intubation, increasing hypoxaemia and difficult ventilation in the paralysed anaesthetised patient.

A J Mulcahy

& S M Yentis

Anaesthesia 2005,60,1144

"Fiddle, larry

and stick !"

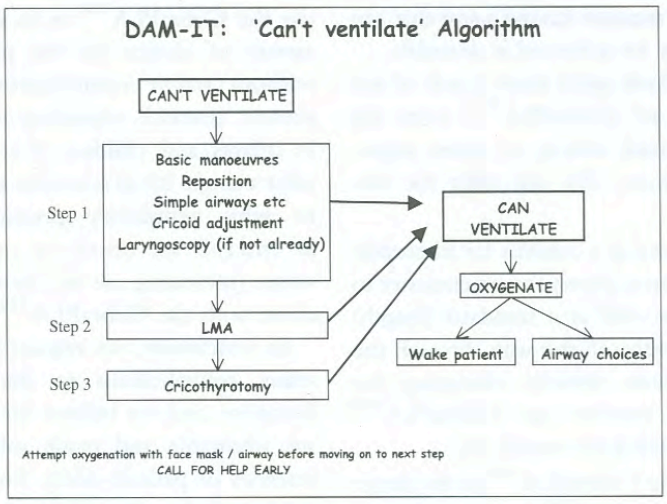


Failed intubation alone is not a crisis if the lungs can still be ventilated, whereas failed ventilation may well be. The priority is to oxygenate the lungs.

If ventilation cannot be achieved, **rapidly** follow the steps in the Figure:

i) Step 1: basic manoeuvres
ii) Step 2: LMA (may have to release cricoid pressure to insert)
iii) Step 3: cricothyrotomy

Once ventilation is achieved, there should be time to consider the options: either wake the patient or continue using one of a variety of airway choices:

i) Laryngeal mask
ii) Intubating laryngeal mask + tube
iii) Fibreoptic intubation through mouth / nose / laryngeal mask
iv) Other device

In most cases, wake the patient unless his/her life is in imminent danger, and seek more senior help.

If a tracheal tube is place, its position should always be checked. Extubation (when, where and how) should also be considered.

**2** The 'DAM-IT' airway algorithm and accompanying text.

## " Airway Alerts ". How UK anaesthetists organise, document and communicate difficult airway management

F.A.Barron et al Anaesthesia, 2003, 58, 73-77

Airway alert scheme encompassing principles of ASA Task Force on Difficult Airway Management, Canadian Airway Focus Group and DAS ( UK )

Who to inform, what documentation, nature of the airway problem, ? Medicalert bracelet etc.

? Consent

# The Management of Airway Obstruction

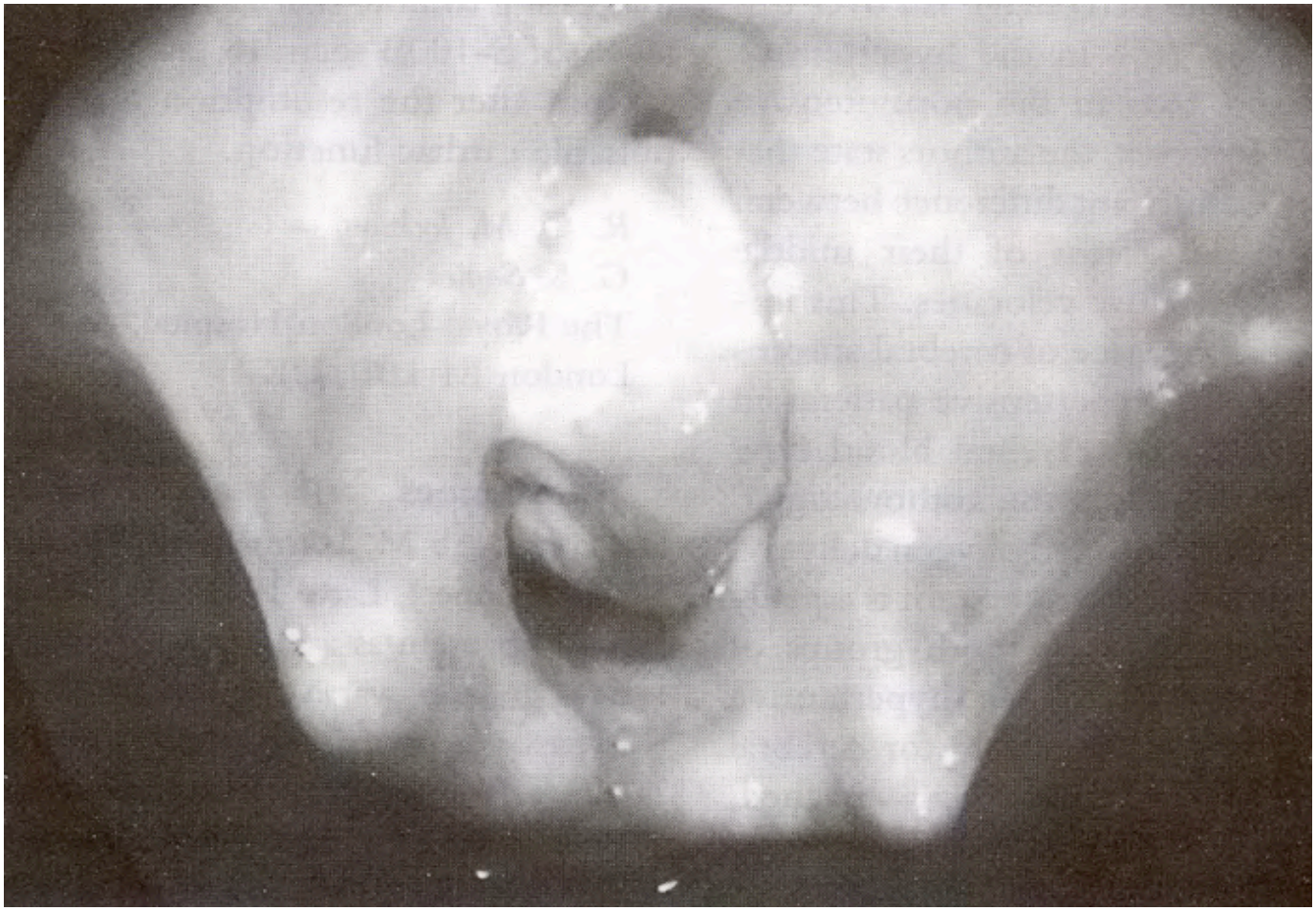

# Management of Tracheal Obstruction

**CASE REPORT** Male 57 Known laryngeal carcinoma

Presentation inspiratory/expiratory stridor

Declining laryngectomy

**Problem** : surgeon wishing to debulk tumour without performing tracheostomy

Anaesthetic technique ?

INDUCTION

MAINTENANCE

RECOVERY

What can go wrong ?

ALWAYS HAVE THE ESCAPE ROUTE PLANNED !

CASE REPORT 2 Female 67 Recurrent Ca upper oesophagus

High resection ( Ivor Lewis ) 5 years prior

Presenting with extreme dysphagia +

inspiratory/expiratory stridor

Intended procedure - insertion of oesophageal stent

under Xray control

Anaesthetic considerations ?

**The Report of the**

**National Confidential**

**Enquiry into**

**Perioperative Deaths**

**1996 / 1997**

NATIONAL ***CEPOD***

- **Management of the partly obstructed airway should be a carefully planned procedure between senior surgical and anaesthetic staff. This is a clinical situation for which a local protocol could be devised.**

- **Wherever possible the level and the full extent of the airway difficulty should be defined by preoperative investigations including the use of fibreoptic nasendoscopy.**

**NCEPOD 96 / 97**

- Early consultation between surgeon and anaesthetist is essential, with consideration of all options and the formation of a management plan.

- Awake fibreoptic intubation and tracheostomy using local anaesthesia should be considered amongst the options.

- Fibreoptic intubation is an established part of anaesthetic practice. Several individuals within a department need to ensure that they maintain these skills.

NCEPOD 96 / 97

| TABLE 1: SOME CAUSES OF LARGE AIRWAY OBSTRUCTION IN CHILDREN |
|---|
| Depressed conscious level |
| Foreign body |
| Infection:<br>Viral: croup, papillomatosis<br>Bacterial: epiglottitis, tracheitis, tonsillitis, abscess adjacent to airway |
| Trauma |
| Thermal injury |
| Congenital abnormalities: choanal atresia, choanal stenosis, micrognathia, macroglossi laryngomalacia, laryngeal web |
| Neoplasm: haemangioma, lymphoma, mediastinal mass |
| Peripheral neurological disease |
| Neuromuscular disease |
| Iatrogenic: subglottic stenosis, post-intubation stridor, neck haematoma |
| Anaphylactoid reactions |

## The obstructed airway in head and neck surgery

Editorial Anaesthesia 1999, 54 625-628

Questionnaire to experienced anaesthetists asked specifically about the management of laryngeal carcinoma and stridor (McSorley P. and Farling P. 1999)

74% said " awake fibreoptic intubation "

No universal answer

Consider each patient according to the level of the obstruction and the individual clinical circumstances.

## Broadly, three groups of patients :

- Obstruction above, in and around the glottis
- Mid tracheal obstruction ( e.g. goitre )
- Lower tracheal and bronchial obstruction

1. Obstruction in and around the glottis (upper airway)

e.g. supraglottic, pharyngeal, pyriform fossa, epiglottic, vocal cord and subglottic lesions.

Stridor at rest (implies < 50 % of normal airway diameter)

Diagnosis - flexible nasendoscopy +/- CT scan

? Nocturnal dyspnoea, panic attacks - *suggests critical obstruction*

If significant stridor at rest :

Is intubation considered possible ?

Yes - inhalational induction of G.A. in theatre (PLAN A)

- surgeon ready to perform tracheostomy (PLAN D)

- rigid bronchoscopy

No - tracheostomy under topical anaesthesia

If GA induction, ~~oral airways~~, nasopharyngeal airways ✓

If severe stridor, a large tumour, fixed hemilarynx, gross anatomical distortion

or - larynx not visible with nasendoscope

PLAN D only - tracheostomy under local anaesthesia

DON`T

- Induce anaesthesia with intravenous agents
- Immediately reach for the fibrescope !

DO

- Have surgical expertise immediately available
- Consider insertion of jet ventilation cannula pre-induction.

Management of mobile laryngeal tumours (Letter)

N. Randhawa Anaesthesia 2002, 57, 721-2

## 2. Mid tracheal obstruction

Fibrescope *may* be useful when obstruction is further down the airway

CT scan is mandatory for lesions of the trachea and main bronchi, except in life-threatening situation.

PLAN A - fibrescopic airway evaluation/intubation - awake if possible

PLAN D - is a tracheostomy feasible ?

Most cases of retrosternal goitre have sufficient airway diameter.

## 3. Lower tracheal and bronchial obstruction

Sudden airway obstruction can occur at any stage of the anaesthetic

- after muscle relaxant administration
- on inhalational induction
- after reversal of NM blockade
- on extubation
- in recovery

# Anterior mediastinal masses : an anaesthetic challenge

M.H.Goh et al  Anaesthesia 1999, 54  670 - 682

Case Report  20 year old female - 1 month cough, no stridor

CXR - 2/3 chest cavity filled by ant. mediastinal mass

CT scan showed bilateral main bronchi compression

Anaesthesia for biopsies -  awake fibreoptic intubation

↓

thio, atracurium, isoflurane

↓

peak airway pressure ↑ ++


Frozen section revealed lymphoma

NM blockade reversed - airway pressure still high

Transferred to ITU still intubated and ventilated

On waking, airway pressure falling

Extubated 4 hours after ITU admission

## The anaesthetic management of the patient with an anterior mediastinal mass

Neuman GG et al Anesthesiology 1984: 60: 144 - 7

3 reasons for obstruction under GA

- lung volume reduced under GA
- relaxation of bronchial smooth muscle = greater airway compressibility from any overlying mass
- loss of spontaneous diaphragmatic movement with muscle relaxants reduces the normal transplural pressure gradient which dilates the airway

Goh et al

Management plan

- consider femoral vessel cannulation prior to anaesthesia
- awake fibreoptic intubation after invasive monitoring established
- avoid muscle relaxants if possible
- expect to have to intubate (least obstructed) main bronchus
- have ENT or cardiothoracic surgeon ready for rigid bronchoscopy
- as last resort, convert to CPB anaesthetic
- ITU admission post biopsy is mandatory

The following cases with known airway obstruction illustrate a variety of airway managements.

| | Age | Diagnosis | Operation | Airway control | Outcome |
|---|---|---|---|---|---|
| 1 | 85 | Retrosternal goitre | Resection | Awake fibreoptic intubation | Inoperable, extubated and returned to the ward |
| 2 | 58 | Subglottic and thyroid secondaries from primary renal tumour | Subglottic resection | Propofol/vecuronium, grade four laryngoscopy | Extubated, had an undiagnosed pharyngeal mass, airway obstruction followed by cardiac arrest and death in recovery area |
| 3 | 69 | Cricoarytenoid joint fixation | Tracheostomy | Gaseous induction, no relaxant, tracheal intubation | Uneventful |
| 4 | 76 | Retrosternal goitre in a patient with rheumatoid arthritis and fixed cervical spine flexion | Resection | Thiopentone/ suxamethonium two doses, failed intubation, severe hypoxia | 45 minutes later, on mask ventilation and with hypoxia, difficult tracheostomy, cardiac arrest and died in theatre |
| 5 | 83 | Subglottic tumour | EUA | Awake fibreoptic intubation | Inoperable, extubated and returned to the ward |
| 6 | 41 | Supraglottic stenosis | Tracheostomy | Gaseous induction, assisted spontaneous ventilation adequate so no oral intubation | Uneventful |
| 7 | 79 | Subglottic tumour | Tracheostomy | Propofol/atracurium | Uneventful |
| 8 | 85 | Ca larynx | EUA | Gaseous induction, no relaxant, tracheal intubation | Extubated under deep anaesthesia, uneventful |
| 9 | 83 | Thyroid tumour | Debulking and tracheostomy | Failed awake fibreoptic intubation, intubated by awake direct laryngoscopy | Haemodynamic instability peroperatively, ventilated in recovery area overnight (ICU was full) |
| 10 | 64 | Extensive tumour in supraglottis and hypopharynx | EUA | Gaseous induction, "difficult mask ventilation", then mivacurium given, two anaesthetists and surgeon failed to intubate. Airway oedema and hypoxia supervened | Cricothyroid puncture and oxygenation using Sanders injector, then tracheostomy in the anaesthetic room. Pneumothorax diagnosed in the recovery area. CVA immediately postoperatively, died day two |
| 11 | 81 | Lymphomatous swelling R side of neck and stridor | Tracheostomy | Propofol/suxamethonium | Undiagnosed mid-tracheal obstruction, initially ventilated through orotracheal tube, then unable to ventilate via tracheostomy and subsequently by endotracheal tube, died in theatre |
| 12 | 73 | Thyroid goitre and obesity (112kg.) | Thyroidectomy | Etomidate/fentanyl/ suxamethonium two doses "nightmare intubation" | Uneventful |

**Extract from *NCEPOD* 1996/7**

# + RELAXANTS

# AIRWAY OBSTRUCTION MANAGEMENT PLAN

- Preoperative evaluation
- Provisional diagnosis
- Planning of anaesthetic management
- Preparation of patient
- Preparation of equipment and drugs
- Planning escape route !
- Postoperative period

## Airway devices: where now and where to ?

Charters P  Editorial BJA 2000 504-5

- **Efficient conduit for ventilation, bypassing upper airway**
- **Easy insertion, even by non-specialists**
- **Efficacy not drastically impaired by sub-optimal position**
- **Stable in use ( “hands free” operation )**
- **Works equally well in abnormal airways**
- **Easily converted to tracheal tube placement**

## ( continued )

- Minimal/no aspiration risk
- Easy seal allowing IPPV
- Sealing should minimally distort the pharynx
- Cricoid pressure friendly !
- Negligible side effects profile

## Alternatives to LMA Classic :

- Disposable LMA ( LMA – Unique ) 1998
- C.O.P.A.
- PA Xpress
- Intubating LMA ( Fastrach )
- LMA Proseal
- Airway Management Device (AMD)
- Laryngeal tube/Cobra etc etc
- ( Oesophageal Obturators )

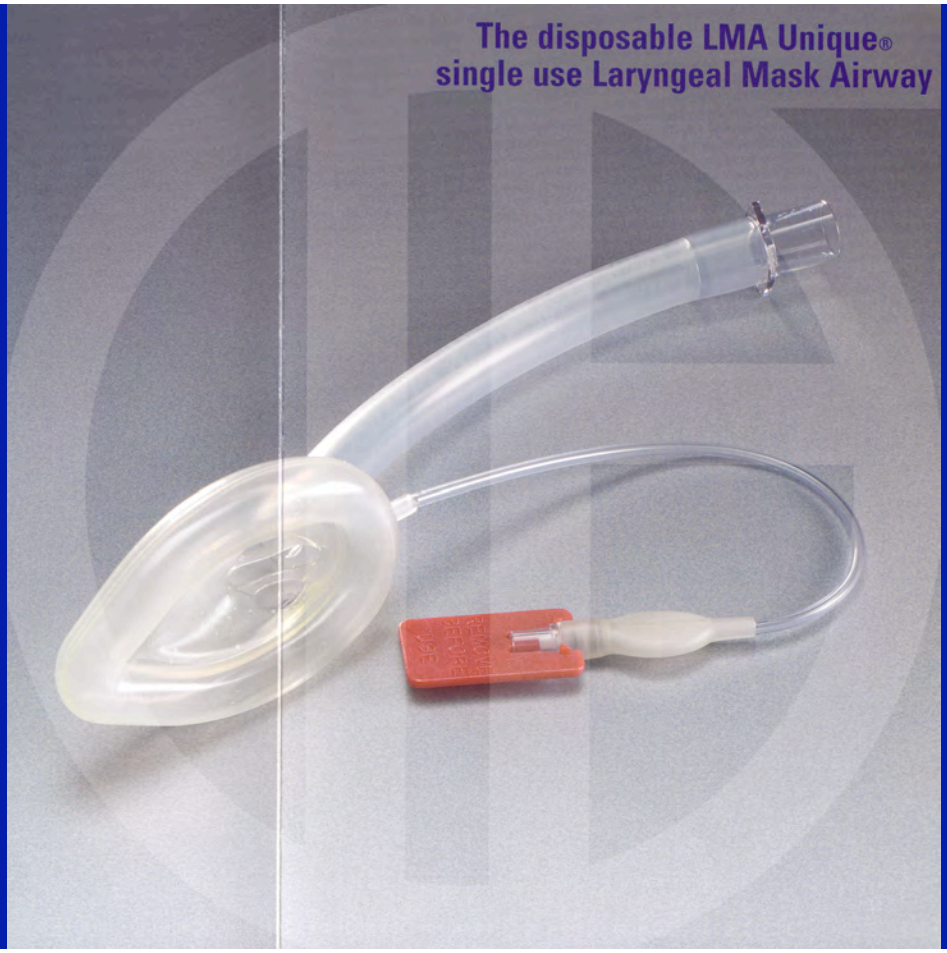
The disposable LMA Unique®
single use Laryngeal Mask Airway


As experts in the production of airway management products, Portex can offer an integrated solution to all your airway management requirements.
The Portex SOFT SEAL Laryngeal Mask is an important addition to this wide portfolio of products, offering many benefits to clinicians.

# A randomised comparison of the Portex Softseal ™ laryngeal mask airway with the LMA-Unique ™ during anaesthesia

T M Cook et al Anaesthesia, 2005, 60, 1218 - 1225

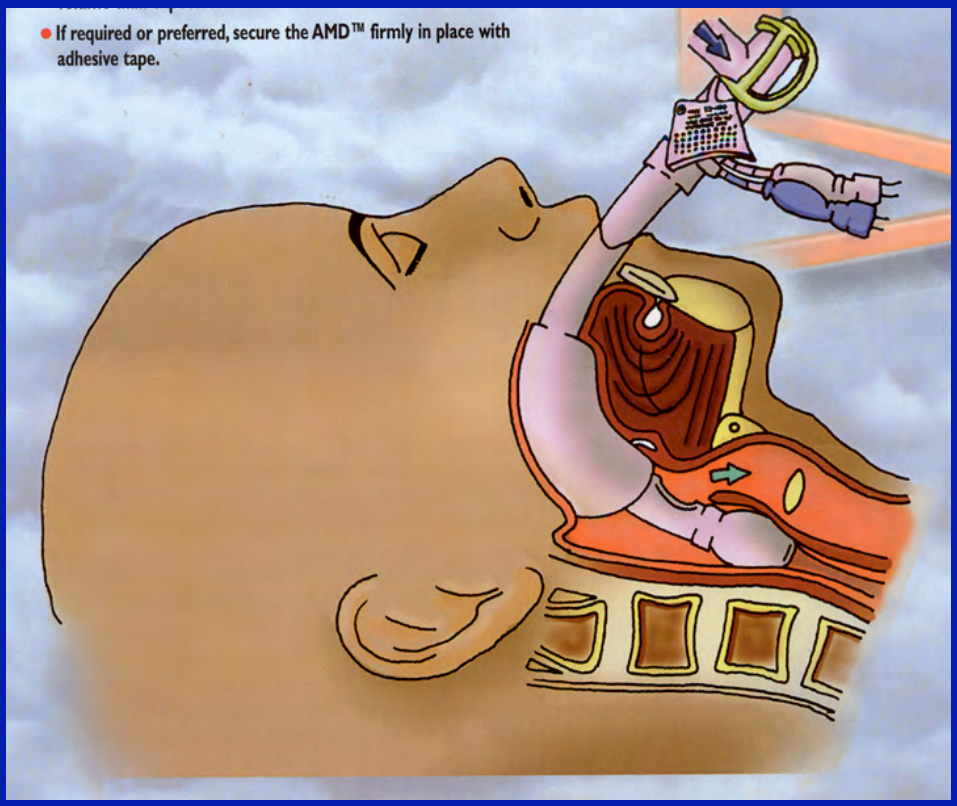


**Airway Management Device**

**“ AMD “**

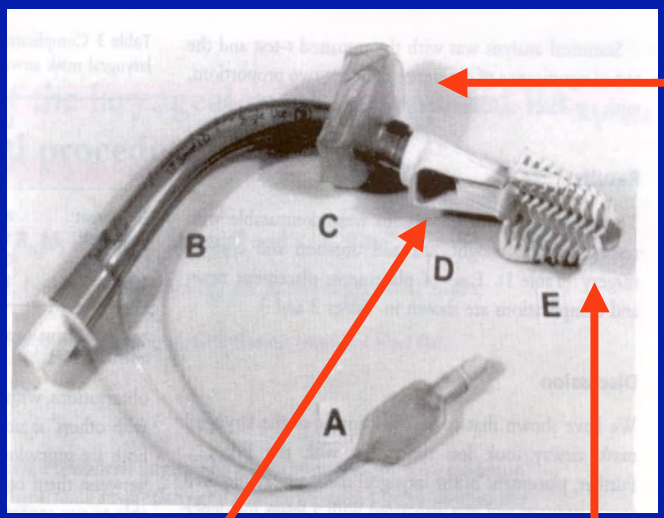


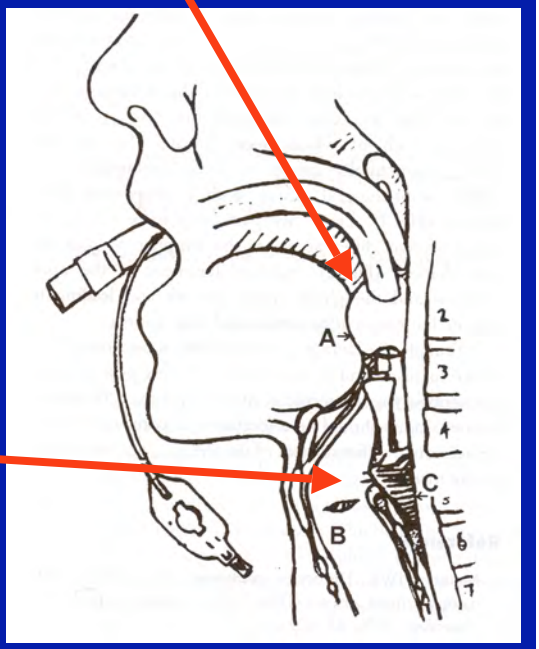


**PAXpress**

## The intubating laryngeal mask - Results of a multicentre trial with experience of 500 cases

P.J.F.Baskett, M.J.A.Parr and J.P.Nolan Anaesthesia 1998 , 53, 1174-1179

Successful insertion in all 500 cases

Satisfactory ventilation in 475 ( 95% )

Difficult ventilation in 20 ( 4% )

Unsatisfactory in 5 ( 1% )

## ILMA ( continued )

Blind tracheal intubation successful in 481 ( 96.2% ) within 3 attempts - ( 79.8% at the first attempt )

Unsuccessful intubation - 19 ( 3.8% )

No relationship between Mallampati grade and success rate

Appears to be about a 20 case learning period for most people.

## The intubating laryngeal mask airway compared with direct larngoscopy

M.S.Avidan et al, BJA 1999

60 patients - randomised crossover study

Doctors , nurses and med students with no intubating experience

Initial manikin training + demonstration on anaesthetised patient

Each participant attempted intubation in up to five adult patients using both DL and ILMA in random sequence (max 2 attempts with each technique)

Also asked to ventilate with mask and bag (but no Guedel airway)

| Results | Success rates |
|---|---|
| ILMA insertions | 98% |
| ILMA intubations | 43% |
| DL intubations | 35% |
| ILMA ventilations | 98% |
| Face mask ventilations | 72% |
| ILMA intubations by investigators | 89% |

## Comparison of laryngeal mask and intubating laryngeal mask insertion by the naïve intubator

Choyce A et al, BJA 2000

- 75 inexperienced participants inserting LMA and ILMA into one of five cadavers
- ILMA insertion was faster and ventilation better - 89% compared to 71% adequacy when compared to LMA
- Results suggest ILMA is the best airway adjunct for emergency ventilation by the inexperienced

## The intubating laryngeal mask airway does not facilitate tracheal intubation in the presence of a neck collar in simulated trauma

Wakeling HG and Nightingale J BJA 84 (2) 254-6

10 patients - ILMA used in simulated trauma scenario

- neck collar ( "Stiffneck Select" ) + CP
- difficult insertion <u>and</u> ventilation
- only 2 successful intubations


**Intubating laryngeal mask airway allows tracheal intubation when the cervical spine is immobilised by a rigid collar**

R.Komatsu et al BJA 93 (5) 655-9 (2004)

50 patients undergoing cervical spine surgery in tracheostomy Philadelphia collar

Vs

50 patients undergoing general surgery without collar

No sig. difference in intubation success (96v98%)

**“Philadelphia” Collar**

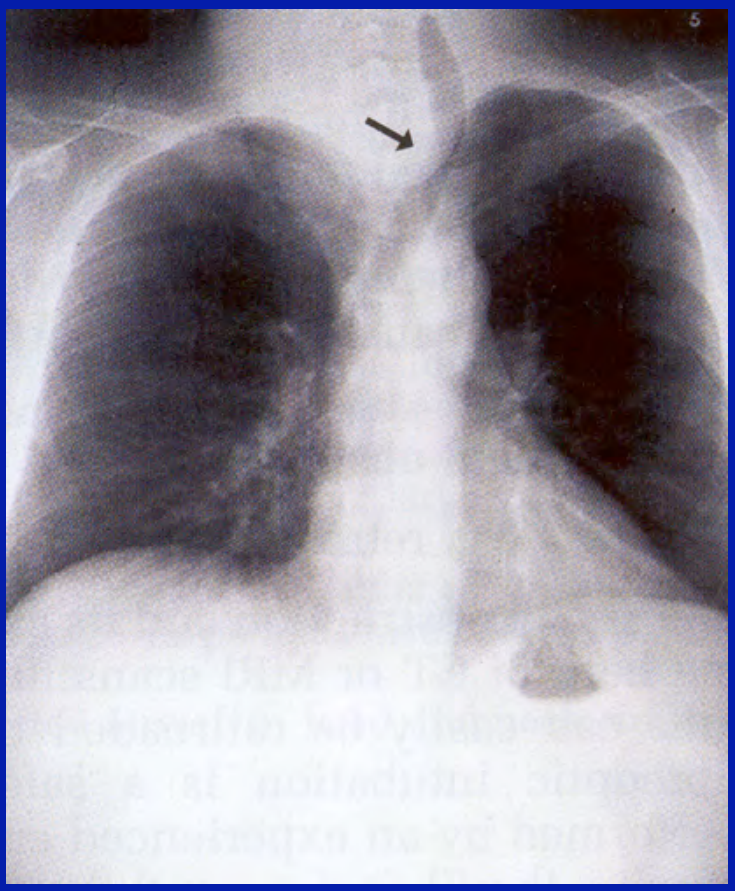

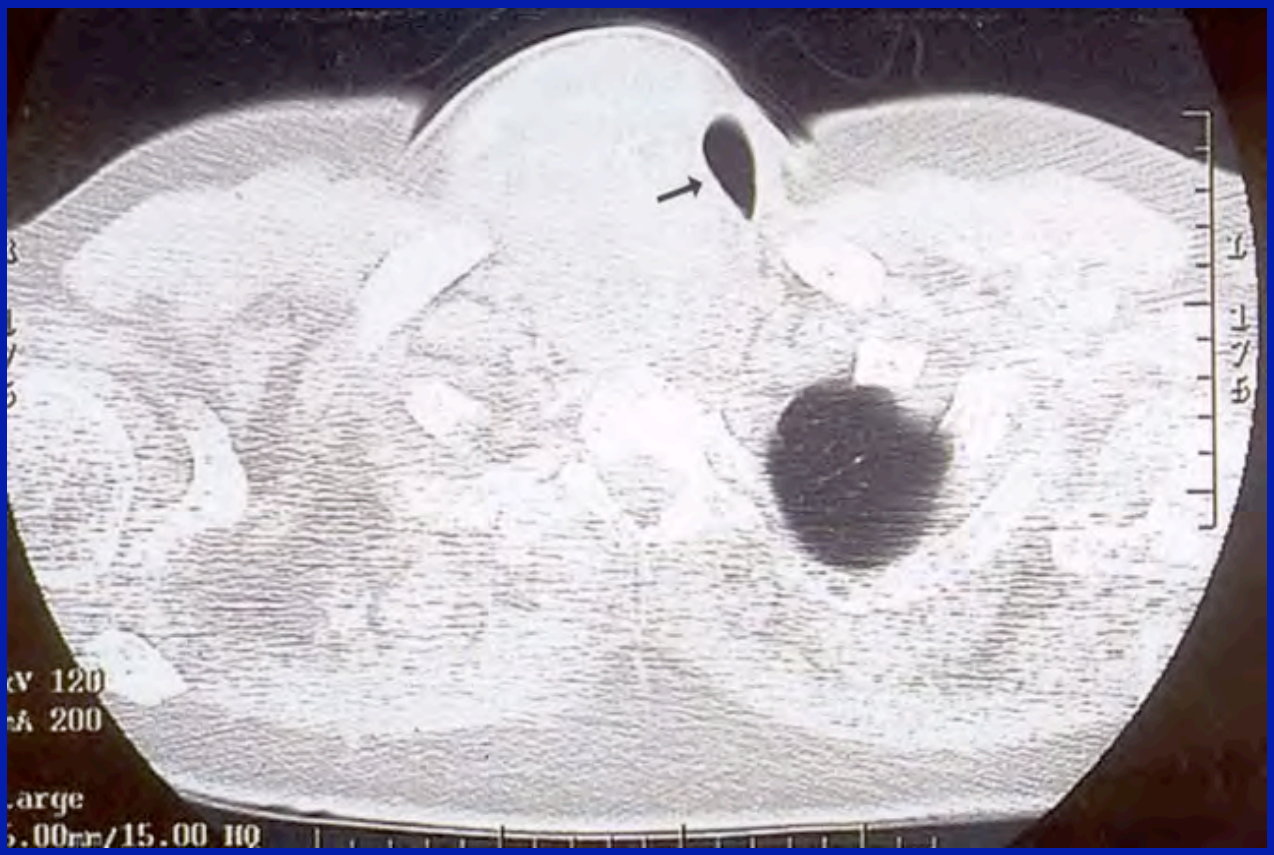
kV 120
mA 200
Large
5.00mm/15.00 HO

# An unexpected complication of the intubating laryngeal mask

M.Branthwaite, Anaesthesia 1999

Case report of fatal oesophageal perforation following ILMA use in cataract surgery.

Intubation achieved with difficulty in a 77 year old ( who might or might not have had an oesophageal diverticulum ) .

# Awake tracheal intubation with the intubating laryngeal mask in a patient with diffuse idiopathic skeletal hyperostosis

Palmer JHM, Ball DR Anaesthesia 2000,55, 70-78

<u>Case report</u>

Female 48 BMI 34.2 Known grade 4 laryngoscopy

For laparotomy

TCI low dose propofol, fentanyl + topical/injected airway anaesthesia.

ILMA size 3 - fibrescope examination - awake intubation

**“ Diffuse idiopathic skeletal hyperostosis - D.I.S.H. ”**

Anaesthesia 2000, 55 p70-78

J H MacG Palmer, D R Ball

## Selected cases for ILMA

- Known C & L grade 3
- Overbite and TMJ mouth opening limitation - ? Gd 3
- 140 kg female, very short neck
- Severe RA - previously only intubated nasally
- More than one consultant said “ very difficult “
- Limited mouth opening - probable grade 3
- Overbite - previous grade 3 ( 2 cases )
- Card carrying grade 4 ( severe RA + retrognathic )

## Failures

1. Patient with Marfan`s syndrome
2. Wrong size ILMA selected

3 and 4. Don`t know why !

5. Late failure – severe RA, small mouth, bleeding from attempted FONI. Even ventilation difficult. Abandoned and FOOI performed with extreme difficulty.

## How good is it really ?

- Emergency airway management - SPEED + superior ventilation to standard LMA
- Steep learning curve
- Assisted fibreoptic oral intubation
- Cervical spine rigidity - head in neutral position
- Cervical spine trauma ?

## Intubating laryngeal mask use in neck injury patients

Letters x 2 Anaesthesia 2002,57, 407-410

- Cervical injury patients must be treated as needing RSI.
- ILMA insertion hindered by cricoid pressure.
- Always some (albeit slight) C spine movement.
- Securing the airway should be near 100 % guaranteed.
- No room for " blind " technique in these cicumstances.
- ( Little mention of fibreoptic intubation ).

## The LMA " ProSeal" – a laryngeal mask with an oesophageal vent

A I J Brain et al

BJA 84 (5): 650-4 (2000)

X 2 seal pressure at 60 cm H2O pressure of standard LMA

Successful blind NGT insertion in 30 adult females

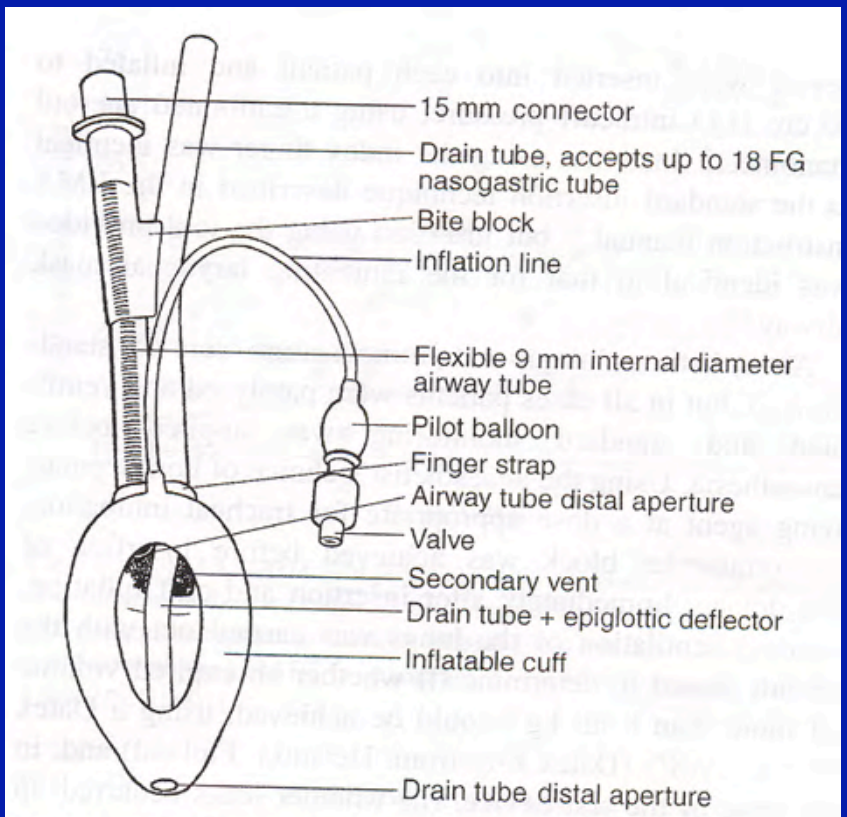


**Fig 2** The size 4 LMADT seen from the front.

# The LMA

# " ProSeal"

## A laryngeal mask with an oesophageal vent

A.I.J.Brain et al

BJA 84 (5) 650-4 (2000)

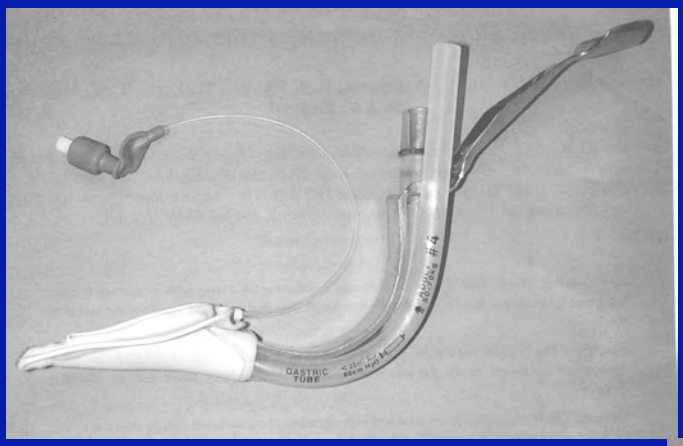

Essential – cuff fully deflated for insertion

Desirable – cuff over inflated compared to standard LMA

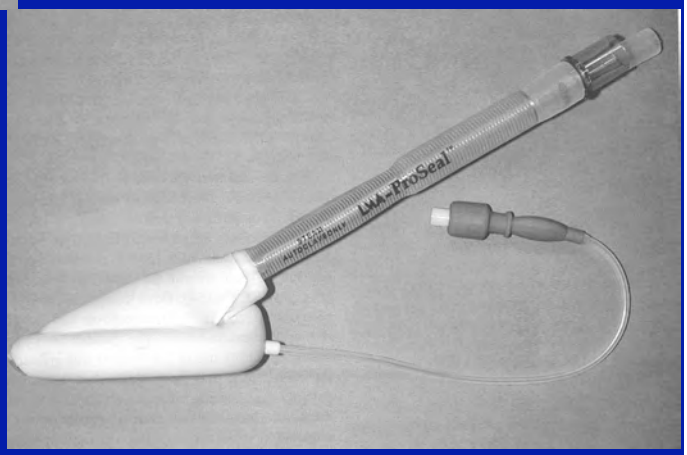

## Randomised crossover comparison of the ProSeal with the classic laryngeal mask airway in unparalysed anaesthetized patients

T.M.Cook et al BJA 88 (4) 527-33 (2002)

180 patients randomised ( no NMBA used )

First insertion 90% standard LMA, 80% ProSeal

Seal pressure > 20 cm $H_2O$ in 41% standard LMA

> 20 cm $H_2O$ in 87% ProSeal

( NGT placement possible in 92% ProSeal patients )

Conclusion : ProSeal better for IPPV

## At Derriford :

Bougies

McCoy

ILMA

Proseal LMA

Fibrescope

Quicktrach

## The future ?

? Glidescope

? Video guided ILMA

## AWAKE INTUBATION

( ? + SEDATION )

FOLLOWING FAILED INTUBATION

ELECTIVE, WHEN DIFFICULTY PREDICTED

ORAL - ANTEROGRADE - ( FIBRESCOPE )

- RETROGRADE

NASAL - BLIND - now historical

- FIBRESCOPE

TRACHEOSTOMY UNDER TOPICAL ANAESTHESIA.

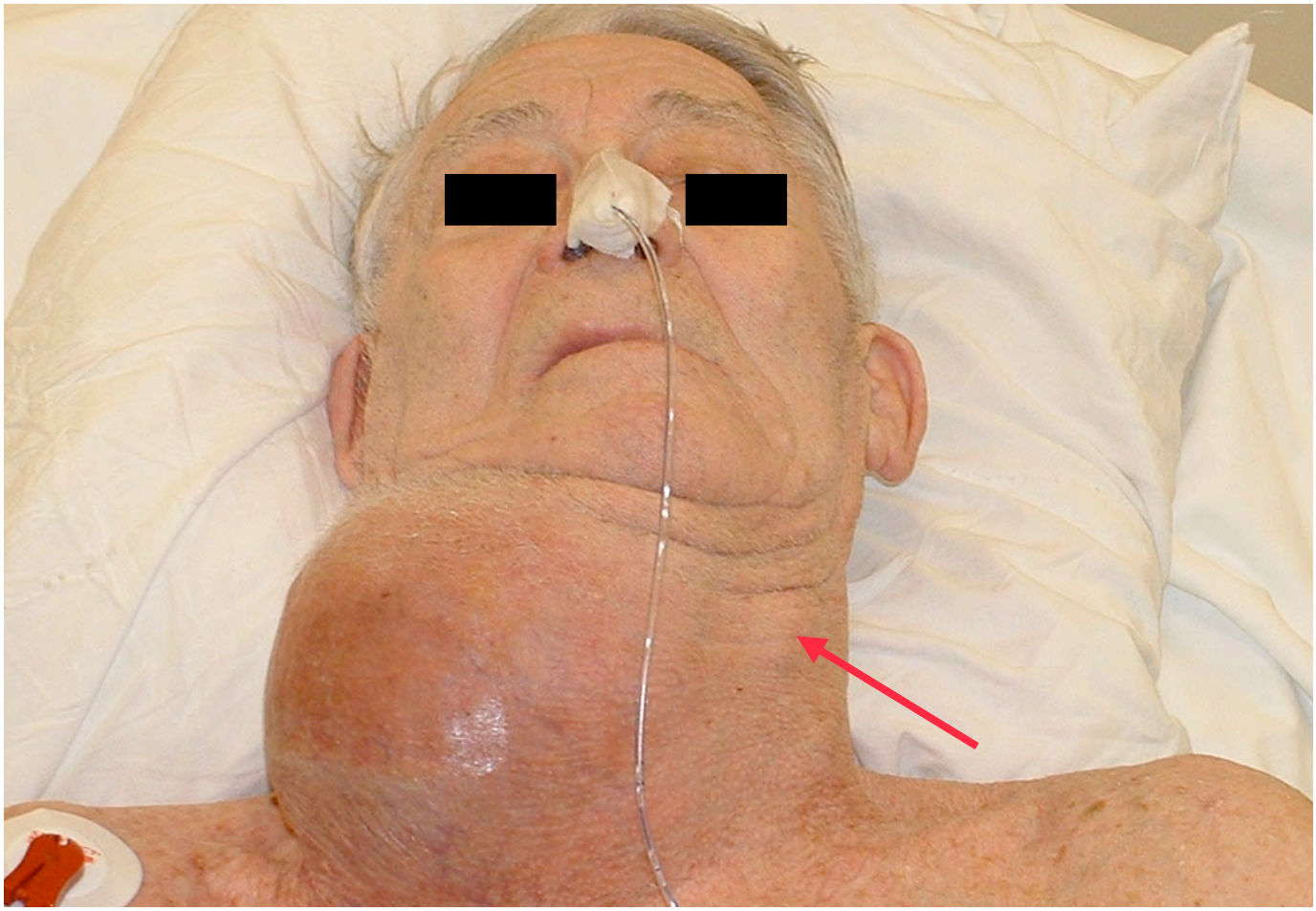


Reliable Performance
Wherever You Need It

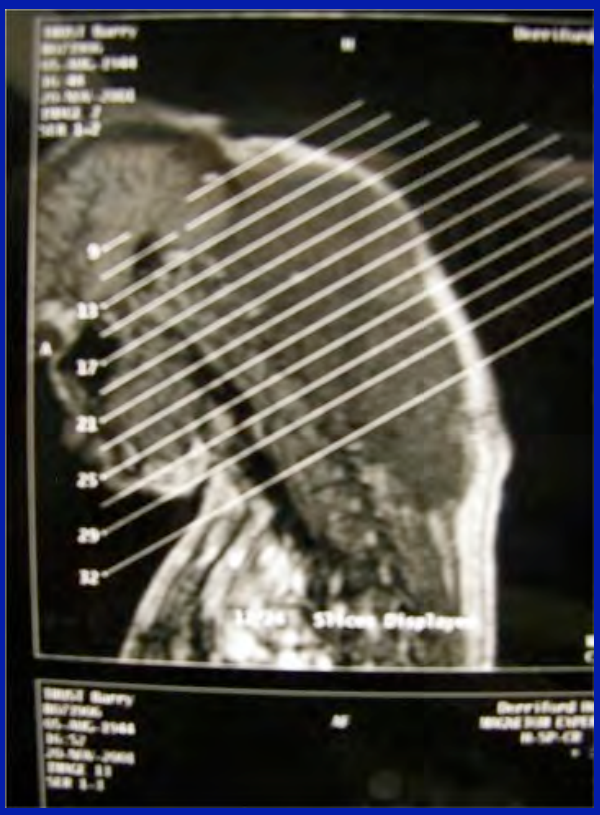
9
13
17
21
25
29
32

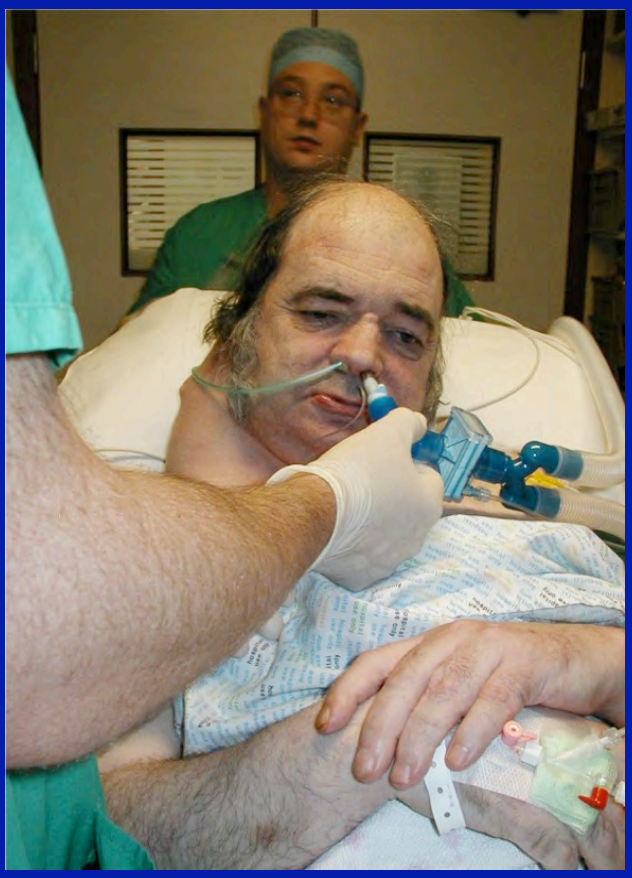

# Securing tube


Oxford
Radcliffe

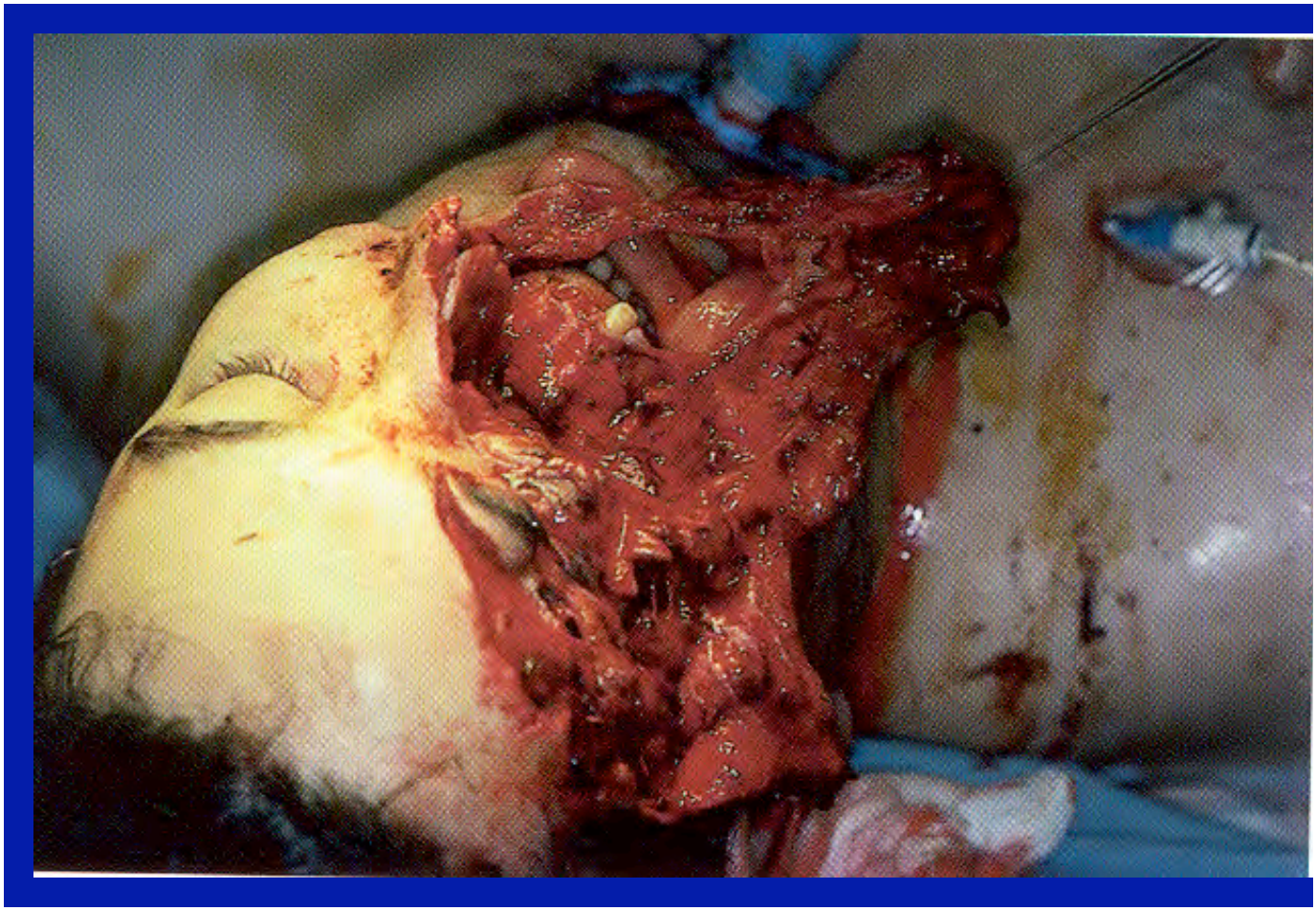

## NASAL FIBREOPTIC INTUBATION

PBH

- Preoperative preparation and assessment
- Premedication ? - certainly a drying agent ? when
- Monitoring
- Cannulation
- ? Sedation + oxygen therapy
- Vasoconstrictor

( continued )

( continued )

- Nasal topical local anaesthesia
- Head position / nurse assistant
- View cords + LA spray ( if no cricothyroid injection )
- Wait
- Pass fibrescope to above carina
- Intubate
- Complete anaesthetic

# LASER SURGERY IN ENT AND MAXILLO-FACIAL SURGERY

## MECHANISM

HIGH ENERGY SOURCE → LASER MEDIUM → LIGHT GUIDE → FOCUS

Laser light - coherent, monochromatic , minimal dispersion

Intense energy to small target sites

## LASER ACTION

Depends on :

POWER DENSITY

DURATION

WAVELENGTH



ABSORPTION

SCATTER

THERMAL CONDUCTIVITY

LOCAL CIRCULATION

## Types of surgical laser

Argon - 500 nm (blue/green visible) - skin, retinas

Carbon dioxide - 10600nm (far infra-red) – penetration only 200 microns – ideal surface laser

NdYAG - 1060 nm (near infra-red) – fibreoptic transmission – absorbed by dark pigments - ideal for GI work

## Problems associated with the use of lasers

- Risk of explosion/fire in the airway (gas ignition)

  ( = internal )

- Risk of airway fire due to tracheal tube ignition

  ( = external )

- Hazard to operating department personnel

  ( skin, eyes )

## Precautions :

- Theatre environment
- Eye protection
- Surgical instruments
- Patient – skin,eyes
- ETTs – composition,shielding,cuffs
- Effect of gas mixture

## ETT FIRES !

EXTERNAL

INTERNAL - " BLOW - TORCH "

Clear PVC tubes laser resistant in vitro

( not necessarily in vivo )

Therefore tube protection ++

0r Special laser tube

# FIRE !

- STOP VENTILATING
- DISCONNECT BREATHING CIRCUIT
- SURGEON REMOVES ETT

AT ONCE

- VENTILATE WITH 100% OXYGEN ( + VOLATILE )
- LARYNGOSCOPY + / - RIGID BRONCHOSCOPY
- RE-INTUBATE + / - LAVAGE + / - VENTILATION
- ? STEROIDS
- CXR