

Radiologic Diagnosis of Rickets

Vitamin D Deficiency or Abuse Is There Reason for Confusion?

Jeannette M Perez-Rossello, MD



**Children's Hospital Boston
Harvard Medical School
Boston, Massachusetts**



Rachitic Changes

- Loss of the zone of provisional calcification, apparent physal widening
- Fraying, flared/cupped metaphysis
- Demineralization
- Findings most apparent in bones with rapid growth: distal radius and femur, costochondral junctions

Current controversy: Rickets vs. abuse

Keller & Barnes, *Pediatr Radiol* 2008; 38:1210-6

Slovis & Chapman, *Pediatr Radiol* 2008; 38:1221-1224

Feldman, *Pediatr Radiol* 2008; 39:1127-9

Jenny, *Acta Paediatrica* 2010;99:491-493

Vitamin D Deficiency

The prevalence of vitamin D deficiency (25OHD < 20 ng/mL) in the USA is high, 22-58%, in otherwise healthy infants and young children

At what level...

do we begin to see rickets?

is there increase in fracture risk?

3 Rickets Scenarios

- 1. Metabolic Bone Disease of Prematurity**
- 2. Nutritional Vitamin D deficiency Rickets**
- 3. Congenital Rickets**

But there are many more...

Metabolic Bone Disease of Prematurity

- Rachitic changes: 22-53%
- Fractures, with or without rachitic changes: 8-16%
 - Upper extremity > lower extremity:
Transverse/greenstick metaphyseal or diaphyseal
 - No physeal fractures
 - Rib fractures: mid posterior arch and lateral

McIntosh. Arch Dis Child 1982;57:848-850

Lyon. Pediatr Radiol 1987;17:56-58

Dabezies. Clin Orthop Relat Res 1997;335:233-239

Nutritional Vitamin D Deficiency Rickets

- **Seen as early as 3-6 mo.**
- **At risk:**
 - **Breast fed infant without supplements:
breast milk is low in vitamin D**
 - **Dark skin**
 - **Limited sun light**

Vitamin D Deficiency Rickets in Riyadh

Annals Saudi Medicine 1991;11:35-39

- 500 infants and young children, less than 2 years old with clinical findings of rickets
 - **ONLY 1 FRACTURE**
- Control group: 1213 children from outpatient clinic screened with wrist x-rays and Alk Phos
 - 85 (7%) “subclinical” rickets= Alk Phos>400, early cupping and fraying of the metaphysis

Congenital Rickets

- India: 337.68 million surveyed
- 165 mothers, severe osteomalacia
 - 3 infants with neonatal hypocalcemic seizures
 - 3 infants with congenital rickets
 - Frontal and parietal bossing, swollen wrists and ankles, wide anterior fontanelle
 - Radiographic rachitic changes
 - ↓ Vitamin D ↑ PTH ↓ Calcium

Teotia. Indian J Med Res 2008;127:219-228

Teotia. Indian J Pediatr 1995;62:55-61

Pub Med: Congenital Rickets

- 12 papers (1968-present)
 - 10 cases reports = 23 patients
 - 2 series = 22 patients
- Infants: newborns - 2 months old
 - Biochem: ↓ Vitamin D ↑ PTH ↓ Calcium
 - X-rays: all with rachitic changes
 - Fractures: *rare, all associated with rachitic changes*

Epidemiology

Fractures in Infants

- Infants < 12 months: 0.14 – 1%
- Toddlers 1-2 years old: 0.06 – 3%

Fractures in infants are uncommon

Hall et al. Osteoporos Int 2009. 20:1873

Thandrayen et al. Osteoporos Int 2009. 20:47-52

Leventhal. Pediatrics 2008;122;599

100 x more common for a fracture to be abuse 12% vs. metabolic abnormality (rickets) 0.12%

TABLE 2 Causes of Injuries In Children <36 Months of Age With Fractures In the 2003 KID (Weighted N = 15 143)

Cause	Proportion, %
Fall	50.42
Abuse	12.08
Other accident	11.60
Motor vehicle accident	11.40
Uncertain whether accidental or intentional	2.17
Bone abnormality	0.85
Metabolic abnormality	0.12
Birth trauma	0.05
No injury E-code	11.32
Total	100.01

Vitamin D Status in Abused and Nonabused Children Younger Than 2 Years Old With Fractures

Samantha Schilling, Joanne N. Wood, Michael A. Levine, David Langdon and Cindy W. Christian

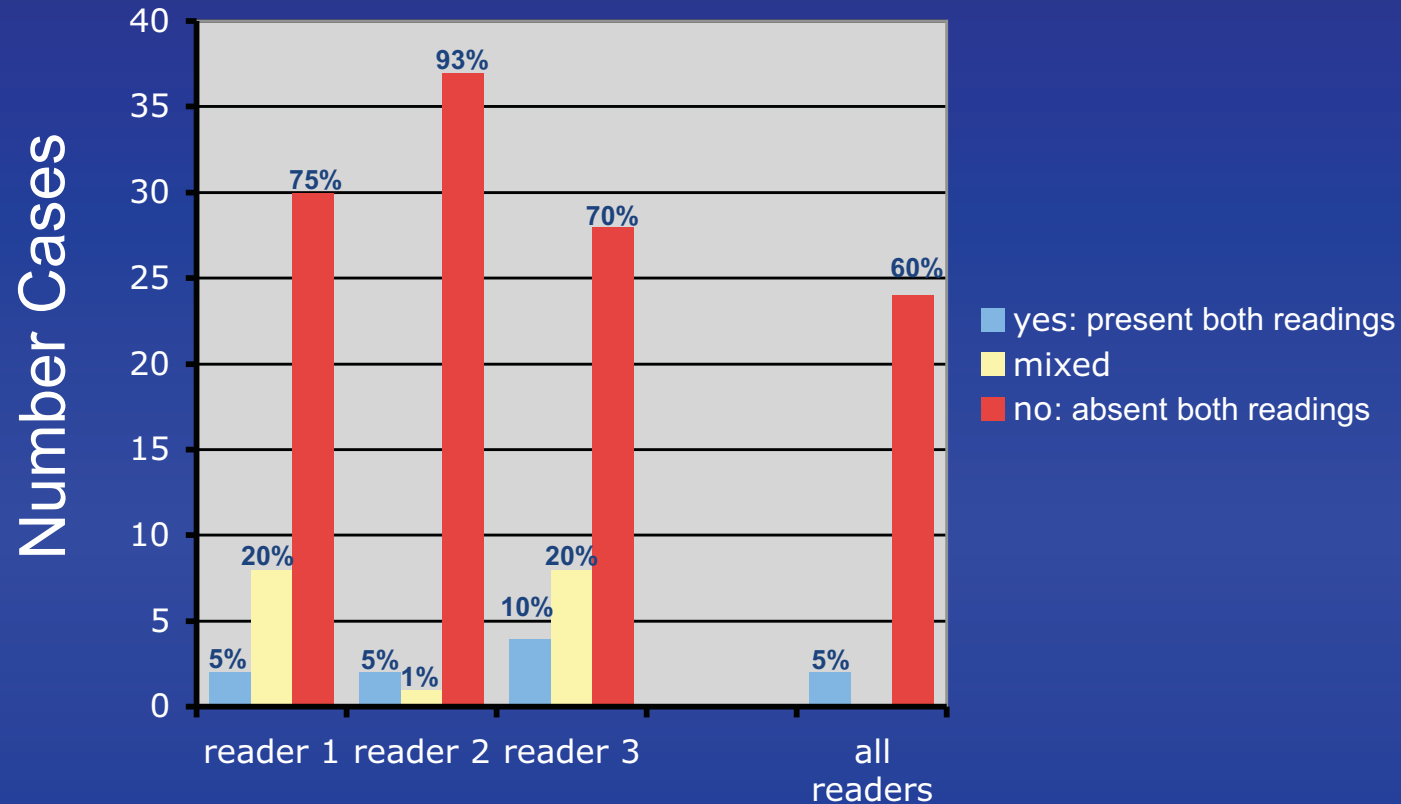
Pediatrics 2011;127;835; originally published online April 11, 2011;

TABLE 3 Characteristics of Abused and Nonabused Subjects ($n = 108$)

	Accidental, $n = 71, 60\%$	Nonaccidental, $n = 37, 31\%$	<i>p</i>
Number of fractures, n (%)			
Single	63 (89)	12 (32)	<.001
Multiple	8 (11)	25 (68)	
25(OH)D, n (%)			
Deficient, <20 ng/mL	6 (8)	2 (5)	
Insufficient, $\geq 20 < 30$ ng/mL	24 (34)	10 (27)	.32
Sufficient, ≥ 30 ng/mL	41 (58)	25 (68)	
Elevated PTH, $n = 107, n$ (%) ^a	6 (9)	8 (22)	.07
Elevated ALKP, $n = 104, n$ (%) ^b	9 (13)	6 (17)	.77
Radiologic abnormalities, n (%) ^c	3 (4)	2 (5)	1.00
Rib fracture, n (%)	4 (6)	18 (49)	<.001
Metaphyseal fracture, n (%)	2 (3)	12 (32)	<.001
Skeletal survey performed, n (%)	39 (55)	37 (100)	<.001

Vitamin D deficiency is not associated with diagnosis of abuse or presence of multiple fractures, metaphyseal and rib fractures

Vitamin D deficiency: Rachitic Changes



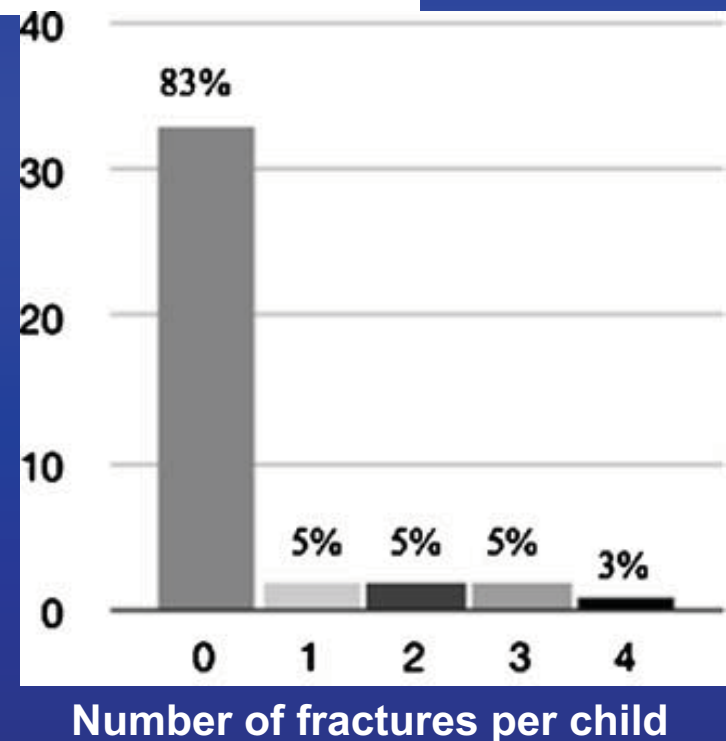
- 360 healthy infants and toddlers (8-24 mo.)
- 44 (12%) had Vitamin D deficiency (25 OHD<20 ng/mL)
- Mild rachitic changes in 5%
- **Fracture prevalence = 0** (95% CI: 0-0.10)

ORIGINAL ARTICLE

Fractures in infants and toddlers with rickets

Teresa Chapman · Naomi Sugar · Stephen Done ·
Joanne Marasigan · Nicolle Wambold ·
Kenneth Feldman

- 45 children, 2-24 mo.
- Rickets varying causes:
nutritional (71%)
- 17% had fractures not
resembling abuse
 - 13% more than >1 fracture



Rachitic Changes in Deceased Infants: A Radiologic and Pathologic Study

- **26 deceased infants with inflicted skeletal injuries whose distal femurs were resected**
- **14 (53%) infants had intracranial injuries**
- **All the patients had radiographs with skeletal injuries suspicious for abuse**

**NO radiologic or pathologic rachitic changes
in 26 infant fatalities with multiple fractures**

Take Home Points

- **Vitamin D deficiency is common in infants but rachitic changes are not**
- **When rachitic changes are present in infants fractures are uncommon and do not resemble the abuse**
- **In infants, with or without vitamin D deficiency presenting with multiple fractures, the most likely etiology is child abuse**
- **A multidisciplinary team approach - child abuse pediatrician, radiologist, endocrinologists, orthopedic surgeons - is needed for optimal evaluation in cases of suspected abuse**