

Functional MRI Follow-Up Study of Language Processes in Healthy Subjects and During Recovery in a Case of Aphasia

Bruno Fernandez, MD; Dominique Cardebat, PhD; Jean-François Demonet, MD, PhD;
Pierre Alain Joseph, MD; Jean-Michel Mazaux, MD; Michel Barat, MD; Michèle Allard, MD, PhD

Background and Purpose—The goal of this study was to develop a functional MRI (fMRI) paradigm robust and reproducible enough in healthy subjects to be adapted for a follow-up study aiming at evaluating the anatomical substratum of recovery in poststroke aphasia.

Methods—Ten right-handed subjects were studied longitudinally using fMRI (7 of them being scanned twice) and compared with a patient with conduction aphasia during the first year of stroke recovery.

Results—Controls exhibited reproducible activation patterns between subjects and between sessions during language tasks. In contrast, the patient exhibited dynamic changes in brain activation pattern, particularly in the phonological task, during the 2 fMRI sessions. At 1 month after stroke, language homotopic right areas were recruited, whereas large perilesional left involvement occurred later (12 months).

Conclusions—We first demonstrate intersubject robustness and intrasubject reproducibility of our paradigm in 10 healthy subjects and thus its validity in a patient follow-up study over a stroke recovery time course. Indeed, results suggest a spatiotemporal poststroke brain reorganization involving both hemispheres during the recovery course, with an early implication of a new contralateral functional neural network and a later implication of an ipsilateral one. (*Stroke*. 2004; 35:2171-2176.)

Key Words: language ■ magnetic resonance imaging ■ recovery of function ■ stroke

Recovery from vascular aphasia is a major issue that implies functional reorganization of the language system in the brain. Several neuroimaging studies have pointed to the critical role of the immediate surroundings of the infarction in recovery capabilities,¹⁻⁵ whereas others have suggested an essential role for the contralateral undamaged hemisphere.^{6,7} Those discrepancies should make us take into account the dynamic changes observed across time^{8,9} during the recovery course and draw a distinction between different language components (eg, semantic and phonological processes), depending on partially distinct networks that can be differently damaged depending on aphasia type.¹⁰

The present study aimed at (1) developing a reproducible functional MRI (fMRI) paradigm that could be used for follow-up of different types of mild or moderate aphasia, and (2) documenting relationships between recovery and evolution of activation in the left perilesional cortex and homologous areas.

Brain activation was studied using 2 language tasks: (1) in a group of healthy subjects who underwent 2 fMRI sessions to evaluate the reproducibility; and (2) in an aphasic patient named PL with conduction aphasia, who was scanned twice (1 month and 1 year after stroke).

Materials and Methods

Case History

PL, a 44-year-old highly educated (postgraduate), right-handed man (Edinburgh Inventory),¹¹ experienced a left sylvian stroke involving Wernicke's area, the posterior part of the insula, and the inferior part of the supramarginal gyrus (SMG) without motor impairment. Language evaluation was conducted at 1 month and 1 year after stroke. His aphasia was characterized using the Montreal-Toulouse battery (MT86).¹² Quantitative tests evaluating comprehension (token test),¹³ picture-naming abilities (Boston Naming Test [BNT]),¹⁴ and word fluency¹⁵ were performed.

MT86 showed mild conduction aphasia with preserved semantic access, contrasting with difficulties of word-form retrieval. Reading and writing from dictation were the most impaired tasks, with many phonological errors. The token test showed impairment emphasized with length of instructions. These 2 tests showed significant improvement during follow-up (Table). BNT, showing mild naming impairment (concerning word-form access), and fluency test, showing important evocation impairment without difference between literal and categorical evocation, did not show significant improvement.

Control Subjects

Ten healthy right-handed subjects (4 men, 6 women, mean age 44±9.7) matched for educational level participated in this study as controls. To assess intrasubject reproducibility, fMRI experiments

Received February 2, 2004; final revision received May 16, 2004; accepted June 22, 2004.

From the Service de Médecine Physique et Réadaptation (B.F., P.A.J., J.-M.M., M.B.) and ERT-Centre National de la Recherche Scientifique Imagerie Moléculaire et Fonctionnelle (M.A.), Université de Bordeaux 2, Bordeaux Cedex, France; and the Institut National de la Santé et de la Recherche Médicale U455 et Service de Neurologie (D.C., J.-F.D.), CHU Purpan, Toulouse, France.

Correspondence to Dr Bruno Fernandez, Service de Médecine Physique et Réadaptation, CHU Pellegrin, Place Amélie Raba Léon, 33076 Bordeaux Cedex, France. E-mail b.fernandez@tiscali.fr

© 2004 American Heart Association, Inc.

Stroke is available at <http://www.strokeaha.org>

DOI: 10.1161/01.STR.0000139323.76769.b0

fMRI Task Scores and Language Evaluations for PL (Token Test, Montreal–Toulouse Battery)

	fMRI Scores		
	Errors, %	Omissions, %	Reaction Time
Rhyme task 1	10*	33.4*	1949 ms*
Rhyme task 2	5*	18.7	2031 ms
Controls	1.1	12.8	1934 ms
Semantic task 1	6.7	25	1657 ms*
Semantic task 2	0	12.5	1862 ms
Controls	1.9	21.1	1865 ms

	Token Test Scores	
	First evaluation	Second evaluation
	48/62	59/62

	MT86 Scores	
	First evaluation	Second evaluation
Reading aloud	27/33	32/33
Dictation	21/35	32/35

*Significant difference from controls.

were performed twice for 7 of them (with a minimal 3-month interval).

MRI Protocol**MRI Acquisition**

Each subject underwent a high-resolution T1-weighted anatomic scan on a 1.5-T Gyroscan ACSNT Power Track 6000, including 30 slices parallel to intercommissural line (no gap; thickness 3.5 mm; repetition time [TR]/echo time [TE]=274/25 ms; matrix=256×256; field of view=260 mm). Then, echo planar imaging was performed (30 slices; no gap; thickness 3.5 mm; TR/TE=3000/60ms; flip angle=90°; matrix=64×64). The blocked design fMRI paradigm comprised 5 baseline blocks alternating with 4 activation blocks, each lasting 30 seconds.

fMRI Stimuli

Each scanning session consisted of 2 separate tasks that involved a combined visual and auditory stimulation. Visual stimuli consisted of line drawings chosen from the Snodgrass Corpus¹⁶ and were projected via a video system; auditory stimuli were digitized spoken words presented via magnet earphones. Word–picture pairs were presented every 3 seconds (Figure 1).

The 2 tasks consisted of (1) a word–picture rhyming (“phonological”) task, in which subjects had to decide whether the picture and the simultaneously heard word rhymed or not; and (2) a word–

picture semantic matching task, in which subjects had to decide whether the items belonged to the same semantic category or not.

For both tasks, active blocks included 10 pairs of items (with 40% of matching pairs). Subjects were instructed to respond to matching pairs by pressing a computer key with their right hand. Responses were recorded via the PsyScope Button box system. During “baseline” blocks, subjects were presented with a visual stimulus composed of 3 dots inserted in a square.

Image Processing

Images were analyzed with SPM99 (Wellcome Department of Cognitive Neurology, London, UK). The 90-volume images of each run were realigned to the first image to correct for head movement and normalized into Talairach’s space¹⁷ using the intercommissural line as reference plane. Data were thereafter expressed in terms of standard coordinates in the *x*, *y*, *z* axes. Transformed functional data were smoothed with a Gaussian kernel of 10 mm (full-width half maximum).

Statistical Analysis

Individual statistical maps of significant relative regional blood oxygenation level–dependent response changes were generated using a box car model convoluted by hemodynamic response function.

For the control group, data were analyzed using the “random effect” model¹⁸ for contrasts between each task and baseline, with a spatial extent $k > 20$ voxels and an amplitude threshold set at $P < 0.007$ ($t = 3$), uncorrected for multiple comparisons.

Compound contrasts involving “task baseline” main contrasts between the 2 sessions or groups (ie, the patient PL as a “group of 1” and the control group) were performed by using 2-sample *t* tests using the random effect model. For instance, these compound contrasts allowed us to compare PL at 1 month and 1 year after stroke (PL^{MR11}, PL^{MR12}) or control subjects at 1 month and 3 months later (CT^{MR11}, CT^{MR12}).

For each brain region (superior frontal, inferior frontal, parieto-temporal, occipitotemporal, and parietal cortices), a lateralization index (LI) [(right activation volume – left activation volume)/(right activation volume + left activation volume)] was calculated.

Results**fMRI Performances Analysis****Semantic Task**

No significant difference in terms of hits or errors (false-positive [FP], false-negative [FN], bilateral *Z* test for proportion comparison) was observed between PL and controls, whatever the session. The PL’s response times (RTs) were significantly shorter than those of controls ($P = 0.008$; bilateral Student *t* test) at session 1, but this difference disappeared at session 2.

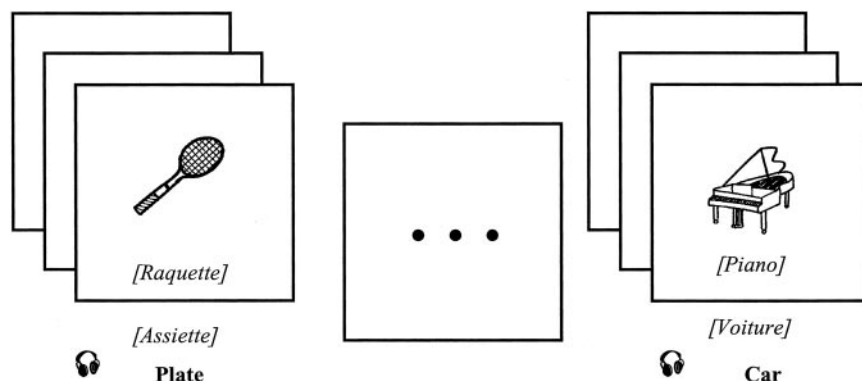


Figure 1. fMRI paradigm. In rhyme task, subjects had to decide whether “picture–heard word” pair rhymes (then they pushed a button) or not. In baseline task, they had to look at 3 dots on a square. Semantic pairs are identically built. The headphones symbol represents heard words.

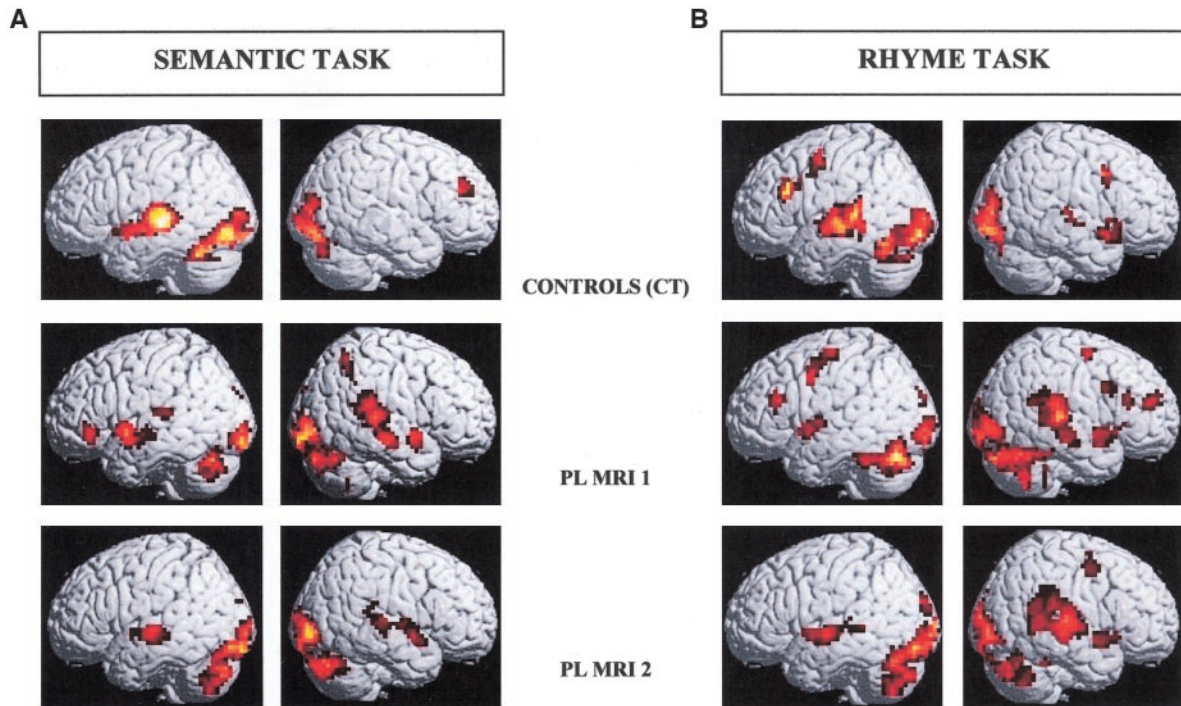


Figure 2. Activations obtained from PL and controls during semantic (a) and rhyme tasks (b). Images show main contrasts obtained in controls and in PL 1 month (PL MRI1) and 1 year (PL MRI2) after stroke. They show an early strong right homologous area involvement and the role of prefrontal areas in PL. One year after stroke, PL MRI2 shows enhanced left perilesional contribution.

Word–Picture Rhyming Task

FP rates were significantly different between PL and controls at session 1 (10% versus 1%; $P=0.0001$) and session 2 (5% versus 1%; $P=0.024$). FN rates were significantly different only at session 1 (33% versus 12%; $P=0.025$). PL's RTs were not significantly different from those of controls, whatever the session.

Intertask Difficulty

Controls did not show any performance difference either in terms of responses or in terms of RTs, whatever the tasks or the sessions, whereas PL showed more difficulties in rhyme detection at both sessions (session 1: RTs 1950 ms for rhyming versus 1650 ms for semantic, $P=0.019$; session 2: RTs 2000 ms for rhyming versus 1860 ms for semantic, $P=0.014$).

fMRI Results

Semantic Task

In controls (Figure 2a), the activation pattern observed at session 1 in the semantic task included right superior dorso-lateral frontal (Brodmann's area 9 [BA9]), left superior temporal (Heschl gyrus, Wernicke's area, with an extension to the anterior temporal pole; $LI=-1$) and bilateral inferior occipitotemporal (BA18–BA19, 37; $LI=-0.29$) regions.

Two-sample t tests between first and second sessions ($CT^{MRI2}-CT^{MRI1}$ and $CT^{MRI1}-CT^{MRI2}$) did not show any activation at our usual group study thresholds ($t=3$; $P=0.006$ uncorrected for multiple comparisons; voxel extent $k=20$).

For PL (Figure 2a), the activation pattern observed at session 1 in the semantic task involved left frontal (supplementary motor area [SMA], BA47) and bilateral, although

rather predominantly right-sided, parietotemporal regions ($LI=0.27$). Posterior occipitotemporal regions were activated bilaterally ($LI=0.20$), as well as cerebellar hemispheres. At session 2, the pattern included middle bilateral temporal (middle temporal gyrus [MTG] BA21–BA22; $LI=0.04$) and right SMG. The contrast $PL^{MRI2}-PL^{MRI1}$ (Figure 3a) showed significant clusters in the left superior temporal gyrus (STG; BA21–BA22; $LI=-1$).

Comparisons between controls and PL at session 1 ($CT^{MRI1}-PL^{MRI1}$ and $PL^{MRI1}-CT^{MRI1}$; Figure 3a) showed more activation in the left SMG (BA7–BA40) and in the left STG (BA22) for controls and more activation in the right SMG for patient ($LI=1$ in parietotemporal region).

At session 2, areas that were more activated for PL ($PL^{MRI2}-CT^{MRI2}$) were not only in the right SMG but also in the left MTG (BA21–BA22; $LI=-0.55$ in parietotemporal region).

Rhyming Task

In controls (Figure 2b), the activation pattern at session 1 included frontal cortex ($LI=-0.66$) in right and left motor–premotor areas, left dorsolateral frontal cortex (BA9–BA46), right anterior insula and BA47, and SMA. Parietotemporal cortices were involved, with a left predominance (BA41, BA21–BA22; SMG; $LI=-0.71$). Occipital regions were activated bilaterally (BA18–BA19), with a left extension to the fusiform gyrus (BA37–BA20). As for semantic task, 2-sample t tests between first and second sessions did not show any significant changes of activation.

For PL (Figure 2b), the activation pattern observed at session 1 showed a right parietotemporal predominance (SMG; STG; $LI=0.66$), with the perilesional anterior tempo-

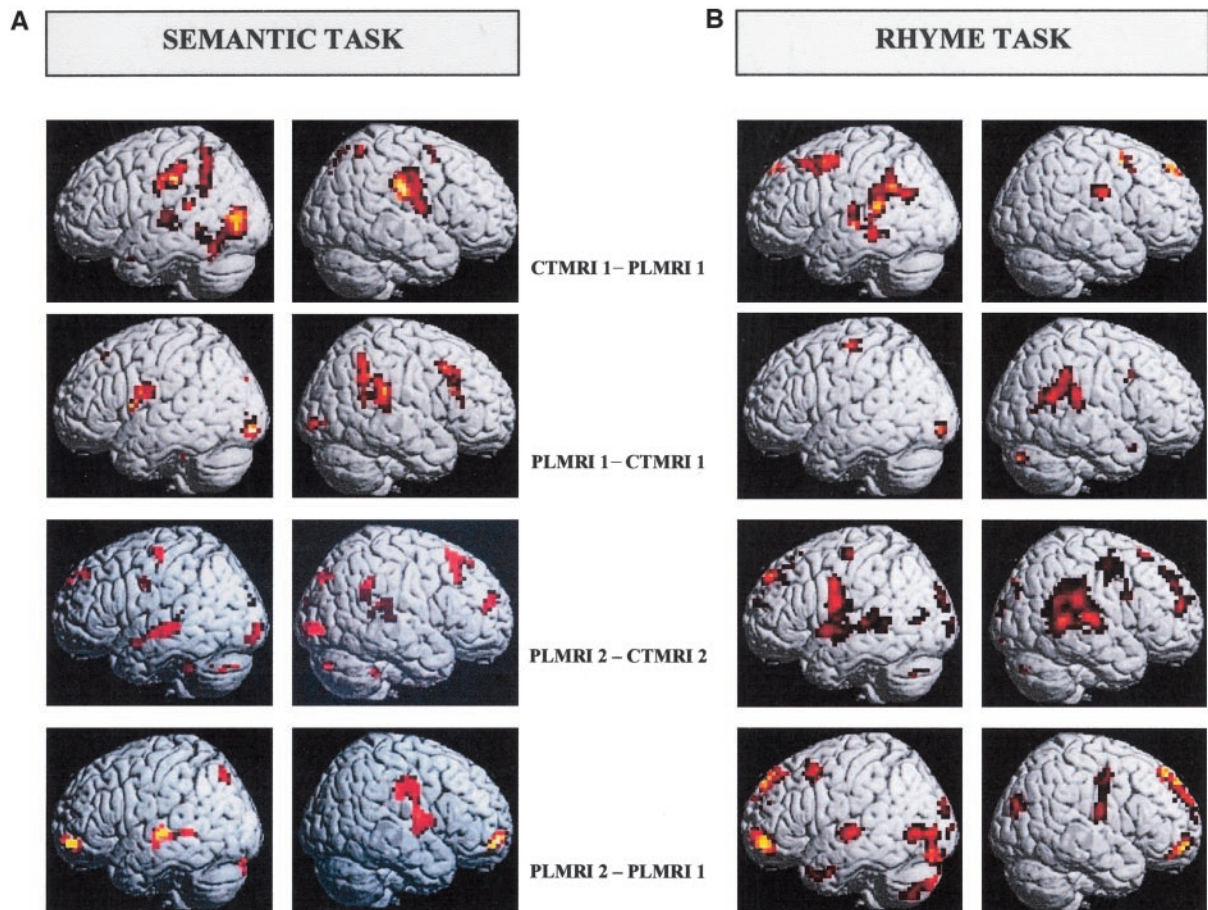


Figure 3. Activations obtained by compound contrasts between PL and controls during semantic (a) and rhyme tasks (b). Enhancement of left perilesional involvement is revealed, whereas right perisylvian activation persisted for the patient by subtracting (1) PL 1 year after stroke and controls (PLMRI2–CTMRI2), (2) subtracting PLMRI2–PLMRI1.

ral cortex being only weakly activated (anterior part of BA22, BA38). Moreover, dorsolateral frontal cortices (BA9–BA46) were activated bilaterally, as well as SMA, motor, and premotor areas (LI=0.49). Frontal activations also concerned right ventral regions (BA13, BA47, and BA10). Occipitotemporal as well as cerebellar regions were involved bilaterally.

At session 2, only right BA6, extending to BA4, was activated in dorsofrontal cortex. Temporal areas remained strongly activated, with an increase in left perilesional areas (MTG; BA21–BA22; LI=0.55). Occipitotemporal cortices still showed a bilateral activation confluent with a cerebellar one.

The contrast $PL^{MRI2} - PL^{MRI1}$ (Figure 3b) showed strong activations in the left hemisphere, particularly in the anterior parts of STG and MTG (LI=-1), occipitotemporal (LI=-0.59), and cerebellar regions. Superior and inferior frontal regions (BA6, BA10–BA47) were bilaterally involved with a right predominance (LI=0.75 and 0.36, respectively).

Comparisons between controls and PL (Figure 3b) at session 1 ($CT^{MRI1} - PL^{MRI1}$) showed more activation in the left SMG and STG, and in the left dorsolateral frontal cortex for controls. The reverse comparison showed a strong activation of SMG in the right hemisphere (LI=1).

At session 2, in parietotemporal regions, higher activation was observed in the right SMG (as at session 1) and the left MTG and STG (BA21–BA22) for PL (LI0.25).

Discussion

In the current study, brain activation was examined during 2 language tasks (“rhyme” and “semantic”) in a group of 10 healthy subjects. The intersubject robustness and the intrasubject reproducibility of these tasks were demonstrated, thus entailing their validity in a patient follow-up study over a stroke recovery time course. Indeed, we showed feasibility of this paradigm in a patient as early as 1 month after stroke, and the longitudinal study during the first 12 months of rehabilitation evidenced spatiotemporal characteristics of changes in brain activation pattern in relation to language recovery. Feasibility of this paradigm will have to be demonstrated further in different types and degrees of aphasia, comprehension of instructions and difficulty in performing a long-lasting fMRI session being the critical points for patients.

In controls, both tasks exhibited different distributed networks (Figure 2a and 2b). Semantic task especially involved 2 regions: (1) left STG, including Wernicke’s area, classically considered critical for decoding auditory verbal information,^{19–24} semantic access being reported to involve an anterior, ventral temporal pathway,²⁵ as observed here; and (2) bilateral occipital and posteroinferior temporal cortices (fusiform gyri), which are related to identification of visual items, reflecting the necessary implicit picture naming underlying word–picture comparison.^{26–28}

Phonological task also involved left STG, but with an extension to its posterior part, and SMG. It could be related to the hypothesis of a dorsal way for decoding auditory verbal information, involving posterior part of Wernicke's area, planum temporale, and SMG as interface between external auditory perception (and internal word representation), and production, allowing for internal rehearsal according to the cognitive models of verbal working memory.^{10,25,29,30}

In both tasks, an involvement of prefrontal cortex (BA9–BA46 and mesial cortex) was noticed, more pronounced for phonological task, especially in the left side, suggesting a higher attentional load for this task³¹ or a higher involvement of the articulatory loop.³²

Language testing for PL showed numerous phonemic mistakes, contrasting with good access to the semantic target, as evidenced by MT86 testing. Indeed, PL presented similar performance scores to controls on semantic task during fMRI session but differed in rhyme task performance, with an improvement between first and second sessions. These data are in agreement with mild conduction aphasia and with lesion topography.³³

In contrast with controls, whatever the task and the session, PL's fMRI exhibited 3 more activated regions as follows: (1) right parietotemporal region, homologous of damaged left areas; (2) bilateral prefrontal areas, including BA9–BA46 (Figure 3a and 3b), medial BA6 (SMA), extending to anterior cingulum, particularly in rhyming task. Prefrontal cortex has been proved to play a critical role in coping strategies.³⁴ Activation of this region could be attributed to the nonspecific "attentional and executive control load," which was expected (especially in phonological task) because the patient found tasks much harder to perform than the control subjects.³¹ This hypothesis is supported by the decreasing trend of prefrontal overactivation during recovery, when PL presented an improvement of language abilities. In addition, it could represent enhanced recruitment of verbal rehearsal system of the articulatory loop to compensate the failing of verbal short-term storage.^{4,32} PL's cerebellar activations could be related with frontal ones, regarding the well-known connections between these 2 regions and the possible role of this system in working memory; and (3) left perilesional temporal cortex (BA21–BA22, BA38 for semantic task and BA22, BA38 for rhyme 1), suggesting relative sparing of semantic access abilities, the word–picture phonological task inducing an implicit semantic access.²⁵

Along with recovery process, enhanced perilesional recruitment was observed, characterized by a reduction of the laterality index. This dynamic phenomenon may thus be interpreted as a direct involvement of tissue nearby the permanently damaged region, which would take over its altered functions.

Together, our results and previous data regarding motor function recovery³⁵ lead to the hypothesis that recovery may be either restorative from left temporal areas or compensatory from different neural circuits that permit re-enablement of the lost or impaired function. Involvement of right temporal areas in PL lends support for such a compensatory mechanism. The respective role of each mechanism, and consequently of each

hemisphere in recovery, is not yet clear. Confusing results between studies emphasizing the role of the right hemisphere⁶ or of the left^{1,3} could be explained by lesion size and anatomical heterogeneity between subjects,³⁶ differences in cognitive deficit,⁵ in rehabilitation or strategical procedures,⁸ or different task designs.^{37–39} Among these, the delay after stroke seems to be a critical parameter for determining findings about neural pattern plasticity. Indeed, selecting aphasics on strict lesional anatomical criteria, Rosen⁴⁰ evidenced early right homotopic area activation too recurrent to be the consequence of an interindividual variability. The precocity of their recruitment and the absence of correlation with performance scores suggest that they represent the early loss of a transcallosal inhibition, demasking prelesional bilateral redundant networks,⁴¹ relayed later by perilesional plasticity leading to constitution of new neural networks. Our results highlight such a relationship between dynamic changes in brain activation and those in language recovery after stroke.

In summary, using semantic and rhyming tasks with intersubject robustness and intrasubject reproducibility, we evidenced spatiotemporal characteristics of brain plasticity in 1 patient with left parietotemporal lesion. The remaining question is whether right homologous and perilesional areas are interdependent parts of a new distributed system relevant for individual prognosis, leading to specific rehabilitation programs or pharmacological treatments. This pilot study suggests that a larger functional neuroimaging project of the same follow-up design in patients with left sylvian lesion with aphasia should investigate the contribution and chronology of ipsilateral and contralateral brain reorganization to recovery language abilities, and moreover, should allow for examining the anatomical substratum of coping strategies.

Acknowledgments

This study was supported by the Unité de Gestion de la Recherche Clinique of the University Hospital of Bordeaux and by the Conseil Régional d'Aquitaine (grants to M.A.). Methodology was established in collaboration with the Unité de Soutien Méthodologique à la Recherche Clinique et Epidémiologique of the University of Bordeaux 2. We would like to thank members of Institut National de la Santé et de la Recherche Médicale Unit 378 of the University Victor Segalen Bordeaux 2 for their assistance.

References

1. Heiss WD, Kessler J, Thiel A, Ghaemi M, Karbe H. Differential capacity of left and right hemispheric areas for compensation of post stroke aphasia. *Ann Neurol*. 1999;45:430–438.
2. Karbe H, Thiel A, Weber-Luxemburger G, Herholz K, Kessler J, Heiss WD. Brain plasticity in poststroke aphasia: what is the contribution of the right hemisphere? *Brain Lang*. 1998;64:215–230.
3. Cao Y, Vikingstad EM, George KP, Johnson AF, Welch KM. Cortical language activation in stroke patients recovering from aphasia with functional MRI. *Stroke*. 1999;30:2331–2340.
4. Warburton E, Price CJ, Swinburn K, Wise RJ. Mechanisms of recovery from aphasia: evidence from positron emission tomography studies. *J Neurol Neurosurg Psychiatry*. 1999;66:155–161.
5. Leger A, Demonet JF, Ruff S, Aithamon B, Touyeras B, Puel M, Boulanouar K, Cardebat D. Neural substrates of spoken language rehabilitation in an aphasic patient: an fMRI study. *Neuroimage*. 2002;17:174–183.
6. Weiller C, Isensee C, Rijntjes M, Huber W, Muller S, Bier D, Dutschka K, Woods RP, Noth J, Diener HC. Recovery from Wernicke's aphasia: a positron emission tomographic study. *Ann Neurol*. 1995;37:723–732.

7. Thulborn KR, Carpenter PA, Just MA. Plasticity of language-related brain function during recovery from stroke. *Stroke*. 1999;30:749–754.
8. Cappa SF, Perani D, Grassi F, Bressi S, Alberoni M, Franceschi M, Bettinardi V, Todde S, Fazio F. A PET follow-up study of recovery after stroke in acute aphasics. *Brain Lang*. 1997;56:55–67.
9. Mimura M, Kato M, Kato M, Sano Y, Kojima T, Naeser M, Kashima H. Prospective and retrospective studies of recovery in aphasia. Changes in cerebral blood flow and language functions. *Brain*. 1998;121:2083–2094.
10. Demonet JF, Chollet F, Ramsay S, Cardebat D, Nespoulous JL, Wise R, Rascol A, Frackowiak R. The anatomy of phonological and semantic processing in normal subjects. *Brain*. 1992;115:1753–1768.
11. Oldfield RC. The assessment and analysis of handedness: the Edinburgh inventory. *Neuropsychologia*. 1971;9:97–113.
12. Nespoulous JL, Lecours AR, Lafond D. MT-86—*Protocole Montréal-Toulouse d'examen linguistique de l'aphasie*. Ortho-Edition, Isbergues; 1986.
13. De Renzi E, Vignolo L. The token test: a sensitive test to detect receptive disturbances in aphasics. *Brain*. 1962;85:665–678.
14. Goodglass H, Kaplan E. *The Assessment of Aphasia and Related Disorders*. 2nd ed. Philadelphia, Pa: Lea and Febiger; 1983.
15. Cardebat D, Doyon B, Puel M, Goulet P, Joanne Y. Formal and semantic lexical evocation in normal subjects. Performance and dynamics of production as a function of sex, age and educational level. *Acta Neurol Belg*. 1990;90:207–217.
16. Snodgrass JG, Vanderwart M. A standardized set of 260 pictures: norms for name agreement, image agreement, familiarity, and visual complexity. *J Exp Psychol [Hum Learn]*. 1980;6:174–215.
17. Talairach P, Tournoux J. *A Stereotactic Coplanar Atlas of the Human Brain*. Stuttgart, Germany: Thieme; 1988.
18. Holmes AP, Friston KJ. Generalisability, random effects and population inference. *Neuroimage*. 1998;7:363–371.
19. Mesulam MM. Large-scale neurocognitive networks and distributed processing for attention, language, and memory. *Ann Neurol*. 1990;28:597–613.
20. Samson Y, Belin P, Thivard L, Boddaert N, Crozier S, Zilbovicius M. Auditory perception and language: functional imaging of speech sensitive auditory cortex. *Rev Neurol (Paris)*. 2001;157:837–846.
21. Binder JR, Frost JA, Hammeke TA, Cox RW, Rao SM, Prieto T. Human brain language areas identified by functional magnetic resonance imaging. *J Neurosci*. 1997;17:353–362.
22. Binder JR, Frost JA, Hammeke TA, Bellgowan PSF, Springer JA, Kaufman JN. Human temporal lobe activation by speech and nonspeech sounds. *Cereb Cortex*. 2000;10:512–528.
23. Frost JA, Binder JR, Springer JA, Hammeke TA, Bellgowan PSF, Rao SM, Cox RW. Language processing is strongly left lateralized in both sexes. Evidence from fMRI. *Brain*. 1999;122:199–208.
24. Zahn R, Huber W, Drews E, Erberich S, Krings T, Willmes K, Schwarz M. Hemispheric lateralization at different levels of human auditory word processing: a functional magnetic resonance imaging study. *Neurosci Lett*. 2000;287:195–198.
25. Wise RJSS, Blank SC, Mummery CJ, Murphy K, Warburton EA. Separate neural subsystems within “Wernicke’s area.” *Brain*. 2001;124:83–95.
26. Humphreys GW, Price CJ, Riddoch MJ. From objects to names: a cognitive neuroscience approach. *Psychol Res*. 1999;62:118–130.
27. Murtha S, Chertkow H, Beauregard M, Evans A. The neural substrate of picture naming. *J Cogn Neurosci*. 1999;11:399–423.
28. Stewart L, Meyer B, Frith U, Rothwell J. Left posterior BA37 is involved in object recognition: a TMS study. *Neuropsychologia*. 2001;39:1–6.
29. Demonet JF, Price C, Wise R, Frackowiak RS. Differential activation of right and left posterior sylvian regions by semantic and phonological tasks: a positron-emission tomography study in normal human subjects. *Neurosci Lett*. 1994;182:25–28.
30. Becker JT, MacAndrew DK, Fiez JA. A comment on the functional localization of the phonological storage subsystem of working memory. *Brain Cognit*. 1999;41:27–38.
31. Seitz RJ, Stephan KM, Binkofski F. Control of action as mediated by the human frontal lobe. *Exp Brain Res*. 2000;133:71–80.
32. Paulsen E, Frith CD, Frackowiak RS. The neural correlates of the verbal component of working memory. *Nature*. 1993;362:342–345.
33. Hickok G, Erhard P, Kassubek J, Helms-Tillery AK, Naeve-Velguth S, Strupp JP, Strick PL. A functional magnetic resonance imaging study of the role of left posterior superior temporal gyrus in speech production: implications for the explanation of conduction aphasia. *Neurosci Lett*. 2000;287:156–160.
34. Calvert GA, Brammer MJ, Morris RG, Williams SC, King N, Matthews PM. Using fMRI to study recovery from acquired dysphasia. *Brain Lang*. 2000;7:391–399.
35. Friel KM, Nudo RJ. Recovery of motor function after focal cortical injury in primates: compensatory movement patterns used during rehabilitative training. *Somatosens Mot Res*. 1998;15:173–189.
36. Kim YH, Ko MH, Parrish TB, Kim HG. Reorganization of cortical language areas in patients with aphasia: a functional MRI study. *Yonsei Med J*. 2002;43:441–445.
37. Newman SD, Twieg DB, Carpenter PA. Baseline conditions and subtractive logic in neuroimaging. *Hum Brain Mapp*. 2001;14:228–235.
38. Price CJ. The critical relationship between the timing of stimulus presentation and data acquisition in blocked designs with fMRI. *Neuroimage*. 1999;10:36–44.
39. Demonet JF, Thierry G. Language and brain: what is up? What is coming up? *J Clin Exp Neuropsychol*. 2001;23:49–73.
40. Rosen HJ, Petersen SE, Linenweber MR, Snyder AZ, White DA, Chapman L, Dromerick AW, Fiez JA, Corbetta MD. Neural correlates of recovery from aphasia after damage to left inferior frontal cortex. *Neurology*. 2000;55:1883–1894.
41. Lee RG, van Donkelaar P. Mechanisms underlying functional recovery following stroke. *Can J Neurol Sci*. 1995;22:257–263.

Functional MRI Follow-Up Study of Language Processes in Healthy Subjects and During Recovery in a Case of Aphasia

Bruno Fernandez, Dominique Cardebat, Jean-François Demonet, Pierre Alain Joseph, Jean-Michel Mazaux, Michel Barat and Michèle Allard

Stroke. 2004;35:2171-2176; originally published online August 5, 2004;
doi: 10.1161/01.STR.0000139323.76769.b0

Stroke is published by the American Heart Association, 7272 Greenville Avenue, Dallas, TX 75231
Copyright © 2004 American Heart Association, Inc. All rights reserved.
Print ISSN: 0039-2499. Online ISSN: 1524-4628

The online version of this article, along with updated information and services, is located on the World Wide Web at:

<http://stroke.ahajournals.org/content/35/9/2171>

Permissions: Requests for permissions to reproduce figures, tables, or portions of articles originally published in *Stroke* can be obtained via RightsLink, a service of the Copyright Clearance Center, not the Editorial Office. Once the online version of the published article for which permission is being requested is located, click Request Permissions in the middle column of the Web page under Services. Further information about this process is available in the [Permissions and Rights Question and Answer](#) document.

Reprints: Information about reprints can be found online at:
<http://www.lww.com/reprints>

Subscriptions: Information about subscribing to *Stroke* is online at:
<http://stroke.ahajournals.org/subscriptions/>