Received: 15th February 2015 Accepted: 18th April 2015 Conflict of Interest: None

Source of Support: Nil

Case Report

Rehabilitation of an Orbital Defect: A Simplified Technique

B C Muddugangadhar[1], Radhika Sonika[2], Pratik S Chheda[3], Ashu Garg[2]

Contributors:

[1]Reader, Department of Prosthodontics including Crown and Bridge and Implantology, MR Ambedkar Dental College and Hospital, Bengaluru, Karnataka, India; [2]Post Graduate Student, Department of Prosthodontics including Crown and Bridge and Implantology, MR Ambedkar Dental College and Hospital, Bengaluru, Karnataka, India; [3]Senior Lecturer, Department of Prosthodontics including Crown and Bridge and Implantology, Guardian College of Dental Sciences, Ambernath, Thane, Mumbai, Maharashtra, India.

Correspondence:

Dr. Sonika R. Department of Prosthodontics including Crown and Bridge and Implantology, MR Ambedkar Dental College and Hospital, Bengaluru, Karnataka, India. Phone: +91-9900409216. Email: sonika.radhika@gmail.com

How to cite the article:

Muddugangadhar BC, Sonika R, Chheda PS, Garg A. Rehabilitation of an Orbital defect: A simplified technique. J Int Oral Health 2015;7(7):121-123.

Abstract:

Loss of tissue, whether congenital or traumatic or resulting from malignancy or radical surgery, is accompanied by esthetic and psychologic effects. This loss is more pronounced when the affected part is the eye and all orbital contents, resulting in gross mutilation. Success in maxillofacial prosthetics depends on the full cognizance of the principles that underlie facial harmony, color matching, anchorage and retention, weight bearing and leverage, durability and strength of materials used, tissue compatibility and tolerance. The restoration of orbital defects presents a challenge in maxillofacial prosthetics. Many variations exist in techniques and materials for fabricating orbital prostheses. Careful positioning of the ocular portion of the orbital prosthesis is one of the requirements for a successful esthetic result. A change of this position, which may occur during fabrication or may be due to distortion of the prosthetic housing or loss of retention of the prosthesis, may result in an unsatisfactory appearance. This article presents a simplified technique for fabricating an orbital prosthesis.

Key Words: Orbital, rehabilitation, room temperature vulcanized silicone

Introduction

Loss of tissue, whether congenital or traumatic or resulting from malignancy or radical surgery, is accompanied by esthetic and psychologic effects. This loss is more pronounced when the affected part is the eye and all orbital contents, resulting in gross mutilation.[1] Success in maxillofacial prosthetics depends on the full cognizance of the principles that underlie facial harmony, color matching, anchorage and retention, weight bearing and leverage, durability and strength of materials used, tissue compatibility and tolerance.

The restoration of orbital defects presents a challenge in maxillofacial prosthetics.[2] Many variations exist in techniques and materials for fabricating orbital prostheses.[3] Careful positioning of the ocular portion of the orbital prosthesis is one of the requirements for a successful esthetic result. A change of this position, which may occur during fabrication or may be due to distortion of the prosthetic housing or loss of retention of the prosthesis, may result in an unsatisfactory appearance.[2]

This article presents a simplified technique for fabricating an orbital prosthesis.

Case Report

A 65-year-old male patient reported to Department of Prosthodontics, MR Ambedkar Dental College and Hospital, Bangalore, India with an orbital defect (Figure 1) and loss of teeth. The patient was unaware of the facility to rehabilitate his defect. When he came to know about the available facility in our institution, he was motivated and consented to rehabilitate his defect. He had lost his eye due to a traumatic accident 30 years ago and reported with an anophthalmic socket with a facial defect on his right side. The surgical wound was completely healed. Intraoral examination revealed completely edentulous maxilla and mandible. Various treatment options were discussed, and his economic status limited us to the silicone prosthesis. We explained the clinical procedures to the patient before fabrication of the prosthesis.

Figure 1: An orbital defect.

Impression making

The impression for the facial moulage was made with a thin mixture of alginate (irreversible hydrocolloid) (Figure 2). The hydrocolloid was reinforced with open gauze pads, which aid in the retention of the Plaster of Paris backing. After removal, the impression is cleaned and inspected for accuracy and detail. Type IV gypsum product is poured in the defect area, and Type III stone is poured in the remaining area and a cast is obtained.

Orientation of ocular prosthesis

Orientation points are marked on the master cast (Figure 3). A suitable acrylic resin ocular prosthesis, with the color of its iris/pupil complex, dimensions, and sclera similar to the contralateral eye, was selected and adapted in the anophthalmic area of the working cast with the baseplate wax. The ocular prosthesis was seated and roughly oriented in the defect according to the orientation marks. This wax pattern was transferred to the patient's anophthalmic area, and the patient was instructed to look straight. The stock ocular prosthesis was adjusted anteroposteriorly, mediolaterally, and superioinferiorly in accordance with the contralateral eye. The oriented ocular prosthesis with the wax pattern was then transferred to the working cast. The eyelids were sculpted by using baseplate wax.



Figure 2: Moulage of the defect.

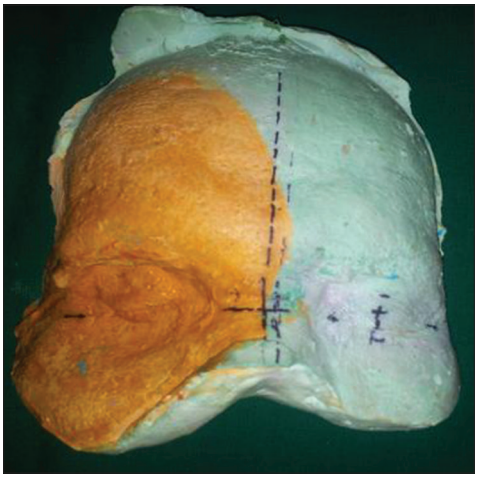

Figure 3: Orientation marks.

Making wax pattern of facial defect

After sculpting the eyelids, modeling wax was added to the defect side of the face and sculpted by comparing the normal contralateral side of the face. Final surface contour and skin texture were established by carving in lines and wrinkles observed around the normal eye (Figure 4).

Selection of spectacle frame

Select a well fitted, comfortable frame that blends with the personality of the patient and adequately covers the defect when viewed from the front, the sides, and above.

Fabrication of mold

Working cast was duplicated, and the duplicate cast was used for mold construction. The pattern was then sealed to the duplicate cast and invested in the conventional denture flask. Indexing with sticky wax in the form of two pyramids was done on the surface of the ocular segment. This index was reproduced in the cope segment of the mold (Figure 5). The cope was carefully removed to avoid damage to the indexing wax. The ocular segment was removed from the wax pattern and placed into the index indentations with an adhesive.

Figure 4: Wax pattern trial.

Figure 5: Indexing and flasking.

Shade matching and packing

An adequate amount of silicone material was dispensed (room temperature vulcanized [RTV] silicone) on the ceramic tile. Intrinsic color pigments were added and mixed to achieve the shade of the skin color of the contralateral side of the face. Silicone material was packed and kept for polymerization for 24 h in a bench press. After 24 h, molds were separated, the silicone prosthesis retrieved, and finishing done. Cosmetic eyelashes were attached to the prosthesis using an adhesive.

Attachment of prosthesis to the spectacles

The prosthesis was held in place in the orbital defect, and the patient was asked to wear the spectacles over the prosthesis. Auto polymerizing acrylic resin was mixed and used to attach the prosthesis to the spectacles. One end of the prosthesis is tacked onto the nose pad and the other onto the side of the spectacle frame, with the acrylic resin keeping the spectacles and prosthesis *in situ*. After removal of the spectacles from the patient's face, the additional acrylic resin is added for final attachment. The acrylic was painted black to match the frame of the spectacles (Figure 6).

Figure 6: An orbital prosthesis.

Discussion

The replacement of the facial defect and lost eye promotes physical and psychological well-being.[4] An accurate alignment of the artificial eye plays a major role in the success of the orbital prosthesis. The esthetics achieved at the end of the treatment depend on the amount of tissue removed, good contour of the inferior margin and minimal sagging due to the weight of the prosthesis. The anatomy of the defect can be recorded accurately by rapid prototyping rather than conventional impression techniques to restore the facial prosthesis.[5] Various methods of retention of a facial prosthesis are eye patches, spectacles, magnets, adhesives, or a combination of those and osseointegrated implants. Although osseointegrated implants provide superior retention, the patient's unwillingness for another surgery and his economic status limited us to spectacle retained silicone prosthesis.[4]

Silicone elastomers are characterized by excellent heat stability and are chemically inert, particularly in body tissues.[6,7] Flexibility of silicone becomes advantageous when the defect includes movable soft tissue. Silicones can be easily processed, cleaned, molded, and colored to give a texture and appearance closely simulating skin.[4]

Technique used for the mold fabrication was a modification of the method given by Taylor *et al*. We simplified the technique by not duplicating the ocular portion of the prosthesis, since a RTV silicone was used the indexes made of sticky wax would not melt and thus suffice to keep the ocular portion in position.

Thus, Fabrication of the prosthesis is relatively short, and the clinician has much control over the color, shape, and size. The facial prosthesis may require replacement because the elastomer and its additives undergo changes.

Conclusion

This article presents the steps used in fabricating an orbital prosthesis. Major considerations such as selection of the spectacle frame and the artificial eye, eye alignment, and mold fabrication are emphasized to ensure an esthetically acceptable prosthesis. A simple and cost effective technique for fabrication of silicone orbital prosthesis was described.

References

1. Joneja OP, Madan SK, Mehra MD, Dogra RN. Orbital prostheses. J Prosthet Dent 1976;36(3):306-11.
2. Shifman A, Levin AC, Levy M, Lepley JB. Prosthetic restoration of orbital defects. J Prosthet Dent 1979;42(5):543-6.
3. Mekayarajjananonth T, Salinas TJ, Chambers MS, Lemon JC. A mold-making procedure for multiple orbital prostheses fabrication. J Prosthet Dent 2003;90(1):97-100.
4. Padmanabhan TV, Mohamed K, Parameswari D, Nitin SK. Prosthetic rehabilitation of an orbital and facial defect: A clinical report. J Prosthodont 2012;21(3):200-4.
5. Sykes LM, Parrott AM, Owen CP, Snaddon DR. Applications of rapid prototyping technology in maxillofacial prosthetics. Int J Prosthodont 2004;17(4):454-9.
6. Kanter JC. The use of RTV silicones in maxillofacial prosthetics. J Prosthet Dent 1970;24(6):646-53.
7. Vashisht R, Kaur H, Prithviraj DR. Finger prosthesis using silicone elastomer: A novel methodology. Int J Contemp Dent Med Rev 2015;2015:Article ID: 280115. doi: 10.15713/ins.ijcdmr.73.