

RESEARCH ARTICLE

Safety and Efficacy of Sequential Transcatheter Arterial Chemoembolization and Portal Vein Embolization prior to Major Hepatectomy for Patients with HCC

Chuan Xu¹, Peng-Hua Lv^{1*}, Xin-En Huang^{2*}, Shu-Xiang Wang¹, Ling Sun¹, Fu-An Wang¹, Li-Fu Wang¹

Abstract

Objective: To evaluate the safety and efficacy of sequential transcatheter arterial chemoembolization (TACE) and portal vein embolization (PVE) before major hepatectomy for patients with hepatocellular carcinoma (HCC). **Methods:** In this retrospective case-control study, data were collected from patients who underwent sequential TACE and PVE prior to major hemihepatectomy. Liver volumes were measured by computed tomography volumetry before TACE, and preoperation to assess degree of future remnant liver (FRL) hypertrophy and to check whether intro- or extrohepatic metastasis existed. Liver function was monitored by biochemistry after TACE, prior to and after major hepatectomy. **Results:** Mean average FRL volume increased 32.3-71.4% (mean 55.4%) compared with preoperative FRL volume. After TACE, liver enzymes were elevated, but returned to normal in four weeks. During PVE and resection, no patient had intro- or extrohepatic metastasis. **Conclusion:** Sequential TACE and PVE is an effective method to improve resection opportunity, expand the scope of surgical resection, and greatly reduce postoperative intra- and extrahepatic metastasis.

Keywords: Future liver remnant volume - TACE - PVE - HCC surgery

Asian Pac J Cancer Prev, 15 (2), 703-706

Introduction

Tumor resection is still a curative method for patients with hepatocellular carcinoma (HCC), However, most patients diagnosed with HCC lost opportunity for surgery (Ribero et al., 2007; Hwang et al., 2009). Extensive liver resection is contraindicated in many patients with HCC because of the future remnant liver volume (FRLV) is too small to receive operation, which could increase the risk of postoperative hepatic dysfunction. FRL volume smaller than 25-30% of total preoperative liver volume is generally considered insufficient in patients with normal liver parenchyma (Abdalla et al., 2006). Previous studies confirmed that the size of FRLV before hepatic resection is an independent risk factor for mortality and postoperative liver failure (Ribero et al., 2007).

TACE is considered to be a basic treatment for unresectable patients with HCC (Kong et al., 2012; Ma et al., 2013; Wang, 2013; Wang et al., 2013). Portal vein embolization (PVE) has been widely accepted as an effective means to increase the future remnant liver volume (FRLV) in patients requiring extensive liver resection (Palavecino et al., 2009). The safety and efficacy of PVE have been confirmed by several studies and a recent meta-analysis (Di Stefano et al., 2005; Hayashi

et al., 2007). With the development of research, there is growing evidence that PVE stimulates not only the growth of the FRL but also affects tumor size in embolized liver segment (Ribero et al., 2007). Although PVE can promote hypertrophy of the FRL, it can't control the progress of the tumor, which may leads to patients with HCC lose opportunities for operation if intrahepatic or extrahepatic tumor metastasis during the period between PVE and Hepatectomy (Wilmar et al., 2009).

How to control the tumor progression during PVE and preoperation, the treatment of sequential TACE and PVE before major hepatectomy for patients with HCC has got people's attention.

Our aim of this study was to evaluate the safety and efficacy of sequential TACE and PVE before major hepatectomy for patients with hepatocellular carcinoma (HCC).

Materials and Methods

Patients Characteristics

Between January 2008 and July 2013, a total of 37 patients underwent sequential TACE and PVE in our department, which was indicated in patients underdoing right hepatectomy for HCC and with only a small future

¹Department of Interventional Radiology, Subei People Hospital of Jiangsu Province, Clinical Hospital of Yangzhou University, Yangzhou, ²Department of Chemotherapy, Jiangsu Cancer Hospital, Nanjing Medical University, Nanjing, Jiangsu, China *For correspondence: whycn7@sina.com, huangxinen06@aliyun.com

Table 1. Clinical Characteristics of the Patients

Characteristics (n=37)	
Gender, male	24 (75.0 %)
Age (years)	61 [47 to 78]
Disease HCC	
Prothrombin time (second)	12 [8 to 21]
Albumine (g/L)	36.2 [30.7 to 47.8]
Total bilirubine (umol/L)	13.2 [4.3 to 37.6]
ALT (u/L)	34.5 [10.4 to 80.8]
AST (u/L)	29.8 [9.8 to 66.4]
TV (cm ³)	1,038 [796 to 2676]
FLR-pre (cm ³)	267 [173 to 387]
%FLR-pre (%)	24.7 [18.1 to 29.4]

HCC, hepatocellular carcinoma; TV, total liver volume; FLR-pre, future remnant liver volume before PVE, %FLRpre (FLR-pre \times 100)/(total liver volume–tumor volume); *Values are median [range]

Table 2. Follow-up the Liver Function Three Days after TACE

	before TACE	three das after TACE
Prothrombin time (second)	12 [8 to 21]	13 [8 to 21]
Albumine (g/L)	36.2 [30.7 to 47.8]	33.1 [29.8 to 36.4]
Total bilirubine (umol/L)	13.2 [4.3 to 37.6]	22.5 [11.3 to 66.8]
ALT(u/L)	34.5 [10.4 to 80.8]	107.8 [57.8 to 223.3]
AST(u/L)	29.8 [9.8 to 66.4]	99.8 [75.6 to 198.6]

Table 3. CT Scan Was Performed Before TACE and Preoperation

	before TACE	preoperation
TV (cm ³)	1,038 [796 to 2676]	1457 [1096 to 3176]
FLR-pre (cm ³)	367 [243 to 787]	589 [393 to 1871]
%FLR-pre (%)	23.7 [18.1 to 29.4]	55.4 [32.3 to 71.4]

liver remnant (FRL) of less than 30% of total liver volume. The patients' characteristics are summarized in table 1. All patients provided written, informed consent for the procedure, and our institutional review board approved the retrospective review of the patients' medical and imaging records.

TACE

Common hepatic and superior mesenteric arteriographies were initially performed to assess patient anatomy, tumor burden, vascularity, and portal vein patency. After selective catheterization of the right hepatic artery using a microcather (Lipiodial and Epirubicin hybrid emulsion) was infused into the selected segmental feeding artery until arterial flow stasis achieved.

Portal Vein Embolization

According to worldwide, there is consensus on this indications. The selection of patients for PVE is based traditionally on CT volumetry. Most studies use a FRL volume of 25-30% of original liver volume as threshold to select patients for PVE when no compromised liver function is expected.

In 37 patients who had received TACE, PVE was performed 2 weeks to 4 weeks (mean 2.2 \pm 0.6weeks) after TACE, following recovery of liver function. PVE was performed in patients in whom the estimated FRLV, based on CT volumetry, was <30% in case of normal liver

parenchyma. PVE was performed using the ipsilateral percutaneous approach. After retrograde catheterization via a portal branch (segment 6 or 7), the right portal trunk and intrahepatic tributaries were occluded using a combination of coils and gelatin sponge.

Follow up Liver Function Tests

We check the liver function one day before TACE, two weeks after TACE, one day before PVE and two weeks after PVE. Assess the liver function changes according to the ALT, AST, TBIL, albumin and PT values, which may affect the liver volume increase after sequential TACE and PVE.

It is important to calculate the percentage of FRL volume following PVE to ensure that enough functional liver tissue is left resection. Ribero et al. showed that both small FRL and limited degree of hypertrophy are strongly associated with postoperative hepatic dysfunction.

The measurement of FRL

In the pre-procedural workup computed tomography (CT) scans were performed to measure the volumes of the total liver, the part planned to be resected, total tumor volume, and the FRL. In most studies, the absolute volumes were used to calculate the percentage FRL.

$$\%FRL = \frac{FRLV}{TLV - TV} \times 100\%$$

Hepertrophy Response

The growth of the FRL as a result of PVE can be calculated such way: the difference in FRL volume before and after embolization in relation to the FRL volume before embolization (percentage volume increase): %FRL volume increase = $(\%FRL_{post-PVE} - \%FRL_{pre-PVE}) / \%FRL_{pre-PVE} \times 100\%$

Results

37 patients received TACE and the procedure were all successful. We follow-up the liver function three days after TACE, all liver enzymes were elevated (Table 2), after conservative therapy, 21 patients liver function return to their baseline level. Two weeks after TACE these patients received PVE. 16 patients' liver function are abnormal whose ALT and AST increased obviously, we recheck the liver function 1 month after TACE and all patients become normal and received PVE.

The remaining 36 patients received sequential TACE and PVE performed enhanced CT after three weeks, the mean average FRL volume increasing was 32.3-71.4% (mean 55.4%) (Table 3) increased obviously compared with preoperative FRL volume. During the period of PVE and hepatectomy, no patient has intrahepatic or extrahepatic metastases.

Discussion

Portal vein embolization (PVE) has been accept as an effective optional treatment for a patient who has insufficient FRL volume required for a major hepatectomy which induce hypertrophy of the nonembolized future remnant liver (Cui et al., 2012). PVE can safely widen

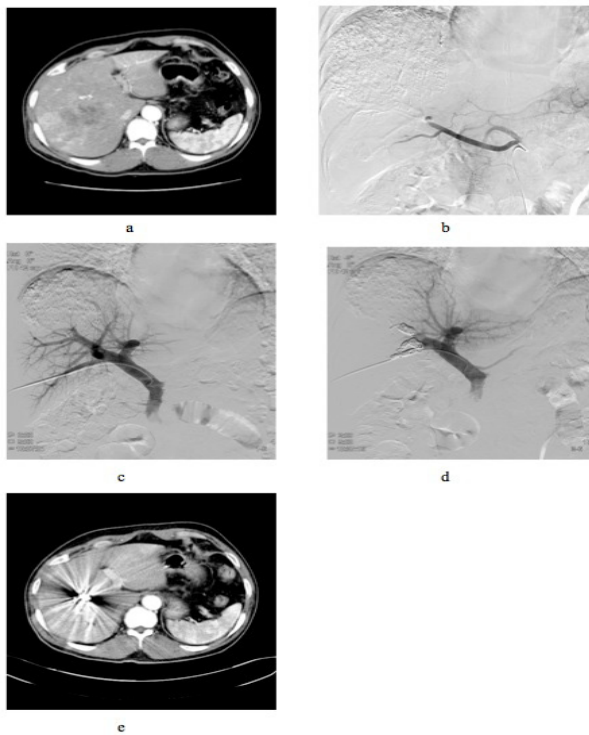


Figure 1. Patient: Man, 65 Years, HCC. a. FRL volumes were measured by computed tomography(CT) volumetry before TACE. %FLR-pre is about 28.7%. b.TACE: Lipiodol and Epirubicin hybrid emulsion was infused into the selected segmental feeding artery until arterial flow stasis achieved. c-d. PVE: Two weeks after TACE when recovery of liver function, PVE was performed using the ipsilateral percutaneous approach. e. Computed tomography(CT) scans were performed three weeks after PVE to measure the volumes of the total liver, the part planned to be resected, total tumor volume, and the FRL. The tumor volume didn't change so much, but the FRL volume increase almost 41.4% compared with before TACE. The %FLR-pre is about 40.2%

the indications for hepatectomy even in a patient with liver cirrhosis. Because of the liver has a dual blood supply with about 75% being contributed by portal vein and 25% by the hepatic vein. Clinical and experimental studies demonstrate a significant increase in hepatic arterial blood flow in the occlude liver lobers resulting from an increase in common hepatic arterial blood supply (Gerunda et al., 2006). Compensatory increased arterial perfusion, known as the hepatic arterial buffer response, occurs after reduction of segmental portal flow. Because liver tumors are mainly fed by the hepatic artery, the hepatic arterial buffer response potentially stimulates tumor growth in the embolized liver lobes (Kollmar et al., 2007). Increased hepatic arterial blood flow after embolization of the ipsilateral portal branch is another factor potentially stimulating tumor growth after PVE. PVE as a means to induce hypertrophy of the FRL is clearly established (Abulkhir et al., 2008). Little has been reported, however, about the negative side-effects of PVE. Several studies have shown tumor progression in patients with primary liver tumors after PVE (Heinrich et al., 2006; Lewandowski et al., 2011). Studies from Japan reported that additional ipsilateral TACE before or after PVE improved the hypertrophy response of the FRL in patients with HCC (Nagao et al., 2006). In our study, 37 patients

received sequential TACE and PVE performed enhanced CT after three weeks, the mean average FRL volume increasing 32-71% (mean 55.4%), increased obviously compared with preoperative FRL volume.

The rationale behind this combination was not only to improve the regenerative capacity after PVE by closing down arterial-portal shunts but also to reduce the risk of tumor progression secondary to compensatory increase in arterial blood flow (Lewandowski et al., 2011). Aoki et al. (Aoki et al., 2004) described a group of 17 patients who underwent PVE 7-10 days after TACE. The combination generated sufficient hypertrophy of the nonembolized lobes within 2 weeks. No tumor progression was noted in the waiting time until resection as measured by CT volumetry. In our study during the period of PVE and hepatectomy, no patient has intrahepatic or extrahepatic metastases. Ogata et al. mean increase in FRL volume and rate of hypertrophy were significantly higher in the group in which PVE was combined with TACE (Ogata et al., 2006). Using this combination, complete tumor necrosis was achieved in 80% of the patients compared with 5% in the PVE group. In addition 1-3-5-year recurrence-free survival rates were higher in the combined group. This clearly demonstrates that TACE combined with PVE is effective in reducing tumor progression in HCC patients.

A drawback of the combination of TACE with PVE is the risk of ischemic parenchymal damage (Okabe et al., 2011). The combination of TACE before PVE is effective in inducing tumor necrosis and thereby in inhibiting tumor progression after PVE (De Graaf et al., 2011). There is nevertheless, a risk of massive necrosis with serious complications. In our study, three days after TACE, all liver enzymes were elevated. The time interval between the two procedures is therefore crucial to safely undertake the combination. More research is needed to define which patients benefit most from sequential TACE and PVE and to determine the optimal time interval between both procedures. Vetelainen et al. demonstrated that simultaneous ligation of the hepatic artery and portal vein in rats resulted in massive liver cell necrosis with increased systemic inflammatory response and decreased liver function (Vetelainen et al., 2006). An interval of 48 h between both procedures decreased the risk of liver injury (Kele et al., 2012). Usually, we wait two weeks when the liver function become normal and then do the PVE. In our department, we usually check the liver function two weeks after TACE. If the liver function is abnormalities, the follow-up time is two weeks. In 37 patients, 21 patients have no obvious abnormalities and received PVE. 16 patients' liver function are abnormal which ALT and AST increased obviously, we recheck the liver function 1 month after TACE and all patients become normal and received PVE. Some studies reported, in a clinical study, that simultaneous hepatic arterial and portal venous embolization resulted in necrosis and infarction of the embolized tissue (Kang et al., 2009; Gruttadauria et al., 2006). Aoki et al. used intervals of 7-10 days in their clinical study and described a transient increase in liver damage parameters (Aoki et al., 2004). Two patients however had segmental infarction in the embolized lobes. Ogata et al. used time intervals of 3-4

weeks which resulted in significant increase in aspartate aminotransferase (AST)/alanine aminotransferase (ALT) levels, however without decrease in liver function (Ogata et al., 2006).

Sequential TACE and PVE can improve the patients' resection opportunity, expand the scope of surgical resection, the main is received TACE before PVE greatly reduces postoperative intrahepatic and extrahepatic metastases after PVE, and increase the possibility of liver operation.

References

- Abdalla EK, Adam R, Bilchik AJ, et al (2006). Improving respectability of hepatic colorectal metastases: expert consensus statement. *Ann Surg Oncol*, **13**, 1271-80.
- Abulkhir A, Limongelli P, Healey AJ, et al (2008). Preoperative portal vein embolization for major liver resection: a meta-analysis. *Ann Surg*, **247**, 49-57.
- Aoki T, Imamura H, Hasegawa K, et al (2004). Sequential preoperative arterial and portal venous embolizations in patients with hepatocellular carcinoma. *Arch Surg*, **139**, 766-74.
- Cui L, Liu XX, Jiang Y, et al (2012). Comparative study on transcatheter arterial chemoembolization, portal vein embolization and high intensity focused ultrasound sequential therapy for patients. *Asian Pac J Cancer Prev*, **13**, 6257-61.
- de Graaf W, van den Esschert JW, van Lienden KP, van Gulik TM (2009). Induction of tumor growth after preoperative portal vein embolization: is it a real problem? *Ann Surg Oncol*, **16**, 423-30.
- De Graaf W, van Lienden KP, van den Esschert JW, et al (2011). Increase in future remnant liver function after preoperative portal vein embolization. *Br J Surg*, **98**, 825-34.
- Di Stefano DR, de BT, Denys A, et al (2005). Preoperative portal vein embolization: evaluation of adverse events in 188 patients. *Radiology*, **234**, 625-30.
- Gerunda GE, Neri D, Merenda R, et al (2006). Role of transarterial chemoembolization before liver resection for hepatocarcinoma. *Liver Transpl*, **6**, 619-26.
- Gruttadauria S, Luca A, Mandala L, et al (2006). Sequential preoperative ipsilateral portal and arterial embolization in patients with colorectal liver metastases. *World J Surg*, **30**, 576-8.
- Hayashi S, Baba Y, Ueno K, et al (2007). Acceleration of primary liver tumor growth rate in embolized hepatic lobe after portal vein embolization. *Acta Radiol*, **48**, 721-7.
- Heinrich S, Jochum W, Graf R, et al (2006). Portal vein ligation and partial hepatectomy differentially influence growth of intrahepatic metastasis and liver regeneration in mice. *J Hepatol*, **45**, 35-42.
- Hwang S, Lee SG, Ko GY, et al (2009). Sequential preoperative ipsilateral hepatic vein embolization after portal vein embolization to induce further liver regeneration in patients with hepatobiliary malignancy. *Ann Surg*, **249**, 608-16.
- Kang BK, Kim JH, Kim KM, et al (2009). Transcatheter arterial chemoembolization for hepatocellular carcinoma after attempted portal vein embolization in 25 patients. *AJR Am J Roentgenol*, **193**, W446-51.
- Kele PG, de Boer M, van der Jagt ET, et al (2012). Early hepatic regeneration index and completeness of regeneration at 6 month after partial hepatectomy. *Br J Surg*, **99**, 1113-9.
- Kollmar O, Corsten M, Scheuer C, et al (2007). Portal branch ligation induces a hepatic arterial buffer response, microvascular remodeling, normoxxygenation, and cell proliferation in portal blood-deprived liver tissue. *Am J Physiol Gastrointest Liver Physiol*, **292**, G1534-42.
- Kong WD, Cao JM, Xu J, et al (2012). Impact of low versus conventional doses of chemotherapy during transcatheter arterial chemo-embolization on serum fibrosis indicators and survival of liver cancer patients. *Asian Pac J Cancer Prev*, **13**, 4757-61.
- Lewandowski RJ, Geschwind JF, Liapi E, et al (2011). Transcatheter intraarterial therapies: rationale and overview. *Radiology*, **259**, 641-57.
- Ma TC, Shao HB, Xu Y, et al (2013). Three treatment methods via the hepatic artery for hepatocellular carcinoma - a retrospective study. *Asian Pac J Cancer Prev*, **14**, 2491-4.
- Nagio M, kamiya J, Nishio H, et al (2006). Two hundred forty consecutive portal vein embolizations before extended hepatectomy for biliary cancer: surgical outcome and long-term follow-up. *Ann Surg*, **243**, 364-72.
- Ogata S, Belghiti J, Farges O, et al (2006). Sequential arterial and portal vein embolizations before right hepatectomy in patients with cirrhosis and hepatocellular carcinoma. *Br J Surg*, **93**, 1091-8.
- Okabe H, Beppu T, Ishiko T, et al (2011). Preoperative portal vein embolization for patients with hepatocellular carcinoma can improve resectability and may improve disease-free survival. *J Surg Oncol*, **104**, 112-9.
- Palavecino M, Chun YS, Madoff DC, et al (2009). Major hepatic resection for hepatocellular carcinoma with or without portal vein embolization: perioperative outcome and survival. *Surgery*, **145**, 399-405.
- Ribero D, Abdalla EK, Madoff DC, et al (2007). Portal vein embolization before major hepatectomy and its effects on regeneration, respectability and outcome. *Br J Surg*, **94**, 1386-94.
- van Lienden KP, van den Esschert JW, de Graaf W, et al (2013). Portal vein embolization before liver resection: a systematic review. *Cardiovasc Intervent Radiol*, **36**, 25-34.
- Vetelainen R, Dinant S, van VA, et al (2006). Portal vein ligation is as effective as sequential portal vein and hepatic artery ligation in inducing contralateral liver hypertrophy in a rat model. *J Vasc Interv Radiol*, **17**, 1181-8.
- Wang SY, Zhu WH, Vargulick S, et al (2013). Nausea and vomiting after transcatheter arterial chemoembolization for hepatocellular carcinoma: incidence and risk factor analysis. *Asian Pac J Cancer Prev*, **14**, 5995-6000.
- Wang ZJ, Wang MQ, Duan F, et al (2013). Clinical application of transcatheter arterial chemoembolization combined with synchronous C-arm cone-beam CT guided radiofrequency ablation in treatment of large hepatocellular carcinoma. *Asian Pac J Cancer Prev*, **14**, 1649-54.