

Diagnosis and Management of Distal Clavicle Osteolysis

STEVEN F. DEFRODA, MD, MENG; CHRISTOPHER NACCA, MD; GREGORY R. WARYASZ, MD; BRETT D. OWENS, MD

abstract

Distal clavicle osteolysis is an uncommon condition that most commonly affects weight lifters and other athletes who perform repetitive overhead activity. Although this condition most commonly presents in young active men, it is becoming increasingly more common in women with the rise in popularity of body building and extreme athletics. Distal clavicle osteolysis can be debilitating, especially in those with rigorous training regimens, preventing exercise because of pain with activities such as bench presses and chest flies. Aside from a careful history and physical examination, radiographic evaluation is essential in distinguishing isolated distal clavicle osteolysis from acromioclavicular joint pathology, despite a potentially similar presentation of the 2 conditions. Nonoperative therapy that includes activity modification, nonsteroidal anti-inflammatory drugs, and cortisone injections is the first-line management for this condition. Patients whose conditions are refractory to nonoperative modalities may benefit from distal clavicle resection via either open or arthroscopic techniques. Arthroscopic techniques typically are favored because of improved cosmesis and the added benefit of the ability to assess the glenohumeral joint during surgery to rule out concomitant pathology. There are varying operative techniques even within arthroscopic management, with pros and cons of a direct and an indirect surgical approach. Patients often do well after such procedures and are able to return to their preinjury level of participation in a relatively short period. [*Orthopedics*. 2017; 40(2):119-124.]

half (25) improved with modification of their lifting technique; the remaining 20 patients required surgical intervention and underwent distal clavicle resection.³

Distal clavicle osteolysis also has been diagnosed in other patients who undergo repetitive motions of the upper extremity, including a delivery man, an air-hammer operator, a judo athlete, and a handball player.^{2,4,5} One case in the literature attributed DCO to a fall from a bicycle.⁵ Although predominantly affecting men, DCO also has been reported in women, as the interest in female body building has risen.⁶ It is important to be aware of both the traumatic and atraumatic causes of DCO as it can commonly be misdiagnosed as acromioclavicular (AC) joint

The authors are from the Department of Orthopaedic Surgery, Brown University, Warren Alpert School of Medicine, Providence, Rhode Island.

Dr Owens is a previous Blue Ribbon Article Award recipient (Orthopedics, January/February 2017).

Drs DeFroda, Nacca, and Waryasz have no relevant financial relationships to disclose. Dr Owens is a paid consultant for Mitek and Conmed/MTF.

Correspondence should be addressed to: Brett D. Owens, MD, Department of Orthopaedic Surgery, Brown University, Warren Alpert School of Medicine, 100 Butler Dr, Providence, RI 02906 (owensbrett@gmail.com).

Received: August 15, 2016; Accepted: October 10, 2016.

doi: 10.3928/01477447-20161128-03

Distal clavicle osteolysis (DCO), first described by Dupas et al¹ in 1936, was believed to be caused by trauma. Since then, DCO has been classified to occur by either traumatic or atraumatic means. A relatively rare condition, DCO typically affects male weight

lifters or individuals who subject their shoulder girdle to repetitive microtrauma.²

In a series of 46 men with acromioclavicular joint pain without an acute traumatic event, Cahill³ reported that 45 lifted weights at least 3 times a week. The average age was 23 years.³ Approximately

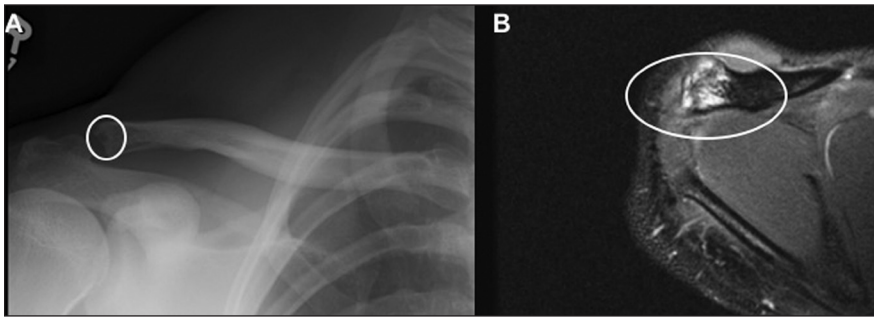


Figure 1: Preoperative anteroposterior radiograph (A) and T2-weighted axial magnetic resonance image (B) showing lytic changes in the distal clavicle (white circle) in a male weight lifter with distal clavicle osteolysis.

separation, especially following an acute injury. This article provides an overview of DCO and treatment options including the current authors' preferred surgical technique for operative management.

OVERVIEW

Anatomy

The AC joint is the articulation of the distal clavicle and acromion, and is stabilized by several ligamentous attachments. The joint is diarthrodial in nature.² A meniscus composed of fibrocartilage is present between the distal clavicle and the acromion. The AC joint is stabilized both in the horizontal and vertical planes by several ligaments. The AC ligaments provide stabilization in the horizontal plane, and the coracoclavicular (conoid and trapezoid) ligaments maintain stability in the vertical plane. It is important to be aware of these ligaments when assessing AC joint stability following trauma as well as when performing distal clavicle excision for conditions such as DCO.

Pathophysiology

Although there are many theories regarding the pathophysiology of DCO, there are 2 generally accepted mechanisms. The first was proposed by Cahill,³ who suggested DCO was caused by repetitive microtrauma leading to microfracture in the subchondral bone of the AC joint. This theory hypothesizes repetitive stress, such as that caused by bench presses and

chest flies, may place excessive traction on the AC joint, which causes DCO in an atraumatic fashion. Cahill³ reported 50% of the 21 patients who underwent surgery in their series had microfractures in subchondral bone indicative of repetitive fracture and attempt at healing. In addition, the distal end of the clavicle of symptomatic patients exhibited fissuring and areas of complete cartilage absence, representing a traumatic process secondary to repetitive stress.³

An additional mechanism was proposed by Brunet et al,⁷ who hypothesized that DCO was caused by synovial invasion of the subchondral bone leading to osteolysis. This hypothesis has been supported by findings on magnetic resonance imaging (MRI).^{2,7} Although the precise mechanism is debated, it is a widely held belief that DCO is caused secondary to repetitive stress at the AC joint via repetitive microtrauma as proposed by Cahill.³

History and Presentation

Most patients are young, athletic men who participate in repetitive activities such as weight training; however, women also have been diagnosed with DCO secondary to weight lifting or push-ups. Pain is often insidious in nature but exacerbated by these loading activities.³ Although many exercises have been implicated, the most commonly reported are bench presses, chest flies, and push-ups, as well as power cleans.⁸

Patients will complain of vague anterior shoulder girdle pain without the sensation of subluxation. They may have tenderness over the AC joint. Often, patients will not be able to recall an isolated traumatic event. Pain may radiate to the trapezius or deltoid region and is relieved with decreased activity and time off from the offending action.

Haupt et al⁸ referred to DCO as "weight lifter's shoulder" and reported that patients experienced more pain at night following intense weight lifting during the day. As far as provocative maneuvers, examination typically reveals tenderness to palpation at the AC joint and pain with cross body adduction. Range of motion typically is normal.⁹

Diagnostic Workup

Radiographic evaluation of the AC joint should be the first step in the diagnostic workup. To make the diagnosis of DCO, pathologic changes should be limited to the distal clavicle and spare the acromion. Typically, imaging of the AC joint is performed via the Zanca view, which involves angling the radiographic beam 15° cephalad in the anteroposterior plane. This view allows for visualization of the AC joint without overlap from the spine of the scapula.¹⁰

Imaging may reveal loss of subchondral bone in the distal clavicle as well as cystic changes in the subchondral bone and widening of the AC joint (Figure 1).³ Evidence of sclerotic changes in the AC joint typically is not present in DCO and instead indicates AC joint arthritis. Distal clavicle osteopenia and tapering may be evident.⁶

More advanced diagnostic imaging such as MRI also can be performed. Magnetic resonance imaging will demonstrate increased signal intensity on fat-suppressed T2-weighted and short-tau inversion recovery (STIR) images.¹¹ Bone marrow edema at the distal clavicle also is a common finding and correlates with severity of symptoms.¹¹

In symptomatic patients, technetium-99 scintigraphy will demonstrate increased

uptake in the distal clavicle and may confirm the diagnosis earlier than plain radiographs and MRI.³ It is theorized that this increased uptake is due to the increased bone turnover caused by osteoblastic attempt at repair of the microfractures caused during DCO. Although critics claim this increased bone turnover should be present in most normal active men, Cahill³ compared 31 patients without DCO with those with the diagnosis and did not find any positive technetium-99 scans within the unaffected control group.

Corticosteroid injection with local anesthetic with or without image guidance can be a useful diagnostic and therapeutic tool. As with other joints, corticosteroid injections typically only offer short-term relief; however, pain relief can identify the AC joint as the source of pathology. Pain relief also may be predictive of successful surgical outcome. Worcester and Green¹² reported that in patients with AC joint arthritis, 100% of patients who received temporary relief with injection ultimately achieved pain relief following surgical intervention. Sopov et al¹³ reported a successfully treated case of DCO via computed tomography-guided injection following failure of nonoperative management in a 20-year-old parachutist.

NONOPERATIVE MANAGEMENT

Treatment of DCO is driven primarily by patient-specific factors (eg, activity level, age, level of impairment, and desire to return to competition) rather than degree of degenerative change on radiographic evaluation. A young body builder may find mild degeneration crippling compared with an older patient with severe degenerative disease. Treatment ranges from conservative nonsurgical options to more invasive options including both arthroscopic and open surgical management.

Activity Modification and Therapy

The most common initial approach to conservative management is activity mod-

ification, nonsteroidal anti-inflammatory drugs (NSAIDs), and therapy.¹⁴ In young athletes, it typically is necessary to avoid certain provocative exercises and activities. For example, eliminating specific exercises engaging the pectoralis major such as bench presses and push-ups can be beneficial.¹⁵ Sometimes even minor adjustments such as changing bar grip distance may alleviate symptoms.³ Often, though, compliance to such recommendations by young active individuals can be poor. In certain instances of concomitant rotator cuff or impingement pathology, formal physical therapy can be of potential benefit with goals aimed at restoring flexibility and strength.¹⁶ However, there is limited evidence to support physical therapy in isolated cases of osteolysis.

Injections

Steroid injections may be considered an adjunct for persistent pain despite activity modification. Steroid injections also may be considered as a diagnostic test if the etiology of the patient's pain is in question. The current authors' preferred injection consists of 1 mL of 1% lidocaine and 1 mL of triamcinolone acetonide infiltrated directly into the AC joint after palpation and sterile preparation. Typically, a 23-gauge or smaller sized needle is used. A gentle pop or change in resistance is indicative of joint penetration. There should be no resistance when injecting the solution.

After the injection, immediate pain relief is diagnostic of AC joint pathology and also has been regarded as a reliable prognostic indicator of successful distal clavicle resection.¹² Avoidance of strenuous activity for 1 week typically is recommended. Successful joint penetration can be difficult, with true accuracy questioned.^{17,18} Borbas et al¹⁷ injected 40 patients without ultrasound guidance and 40 patients with ultrasound guidance. They reported 90% accuracy with ultrasound guidance and 70% accuracy without ultrasound guidance.¹⁷

OPERATIVE MANAGEMENT

Surgery is indicated when conservative treatment is unsuccessful and patients typically continue to experience persistent pain. It is important to consider concomitant shoulder pathology such as rotator cuff tears and biceps tendinopathy, which have been demonstrated to be present in up to 81% and 22% of patients, respectively.¹⁹

Both open and arthroscopic surgical approaches have been described in the literature with variable success.²⁰ Arthroscopic approaches ultimately have become more popular due to improved cosmesis, quicker recovery, and return to activity.²¹⁻²³ Both direct and indirect arthroscopic techniques have been described.^{20,21,24} Advanced imaging should be obtained for distal clavicle resection alone either through an open Mumford-style procedure or direct AC arthroscopy to ensure there is no concomitant intra-articular pathology that could be assessed with a full diagnostic arthroscopy such as rotator cuff or biceps tendonitis.

Open Technique

In 1941, Mumford²⁵ and Gurd²⁶ independently were the first to describe distal clavicle excision to treat chronic AC joint instability. Neviasser et al²⁷ expanded this technique in 1982 by adding decompression of the acromion and distal clavicle to address both impingement and biceps tenosynovitis.

The open technique involves an incision overlying the AC joint with subperiosteal dissection directly exposing the distal clavicle. The amount of distal clavicle resected should not exceed 10 mm, and resection is performed with an oscillating saw or burr drill. Overzealous excision may compromise the superior AC ligament capsule and deltoid insertion, resulting in clavicular instability and chronic pain.^{20,28}

Advantages of the open technique include direct visualization ensuring adequate resection and theoretically increased speed. A diagnostic arthroscopy often is performed prior to resection to rule out concomitant shoulder pathology.

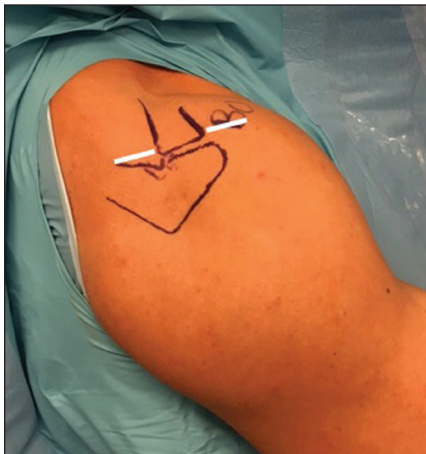

Figure 2: Preoperative photograph showing the landmarks drawn on the shoulder including the acromion, acromioclavicular joint, distal clavicle, and anterior and posterior portals (white lines are parallel to the acromioclavicular joint).

Arthroscopic Techniques

With the rise in popularity and familiarity of arthroscopy, as well as its proposed advantages noted earlier, both indirect (subacromial/bursal) and direct (superior) approaches have been described.^{24,29-32} In the indirect approach, a traditional posterior shoulder arthroscopy portal is established, and the combination of both anterolateral and anteroinferior portals are used to optimize visualization of the distal clavicle within the subacromial space. Typically, decompression and debridement are performed from inferior to superior, with medial decompression being performed last to ensure adequate decompression. A radiograph can be obtained to ensure adequacy of resection.

The direct or superior approach was developed with the theoretical advantages of direct access to the joint, complete joint visualization, and decreased bony debris and disruption within the subacromial space.²⁴ Overall criticisms of the arthroscopic approach include the high technical demand, operative time, destruction of the joint capsule (especially with the indirect approach), and the risk of inadequate resection.^{33,34}

Surgical Technique. The current authors' preferred arthroscopic surgical technique uses a direct approach. After induc-

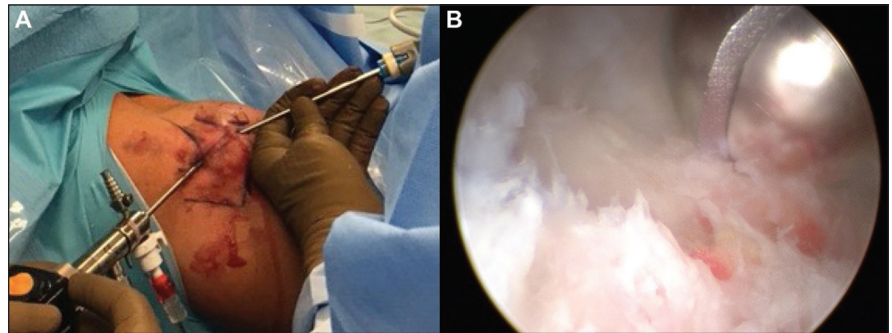


Figure 3: Intraoperative photograph showing the direct approach with the camera in the posterior portal (left) and the shaver in the anterior portal (right) (A). Arthroscopic intraoperative photograph showing debridement of the distal clavicle (B).

tion of general anesthesia, the patient is placed in the beach-chair position. Landmarks are palpated and marked (**Figure 2**).

Two 5-mm portal incisions are made. The first incision is approximately 1 cm posterior to the AC joint, and the second incision is 1 cm anterior to the AC joint. A small 2.7-mm arthroscope is inserted directly into the posterior portal. Using spinal needle localization, a 3.5-mm shaver is introduced through the anterior portal (**Figure 3**). For visualization purposes, the soft tissues and meniscus of the joint are debrided initially.

In contrast to the indirect approach, the inferior AC joint capsule is preserved, and the remaining surgery is performed through the already established arthrotomies. Electrocautery is used to undermine and separate the capsule from the bone within the joint. As the capsule and ligaments are elevated periosteally, this avoids creating iatrogenic instability and also allows improved visualization of the bone to be resected.

Using a 4-mm wide burr through the anterior portal, approximately 8 mm of the anterior portion of the clavicle is resected. The width of the burr is used to guide the amount of resection. Next, the burr drill and arthroscope are switched, and the remaining posterior portion of the clavicle is resected using the same technique. The final amount of resection is evaluated with the arthroscope in the posterior portal and confirmed under fluoroscopy.

The joint and portals then are injected with local anesthetic and closed in a standard fashion, and the patient is placed in a sling. Aesthetically, the portals may be more appealing for the bodybuilder, fitness competitor, or model as the portals are smaller, and the procedure typically can be performed with only 2 portals.

Postoperative Care. Patients are instructed to decrease use of the sling gradually during the first several postoperative days as their pain improves. Patients are referred to physical therapy to work on range of motion and strengthening, and they also are given exercise instruction sheets prior to participating in therapy. Athletes are encouraged to return to full activity during the next month as tolerated. Ten to 14 days after surgery, patients are examined in the office, and postoperative radiographs are reviewed (**Figure 4**).

DISCUSSION

Distal clavicle osteolysis is an uncommon but potentially limiting condition in young, highly active patients. Conservative therapy with NSAIDs and activity modification has been shown to be successful as a first-line treatment. Jacob and Sallay³⁵ reported 25 of 27 patients (93%) who received lidocaine injection into their AC joint experienced improvement in pain and function. However, this improvement was reported at a mean of 20 days, and within 4 months, 18 patients (67%) required distal clavicle excision for insidious

pain. Two patients who received lidocaine injections did remarkably well, reporting pain relief for 1.5 and 2 years, respectively.

For patients who fail conservative treatment, especially those who are young and competitive athletes, surgical options must be considered. Deciding on the optimal surgical technique typically is based on an individual surgeon's experience, secondary to the lack of level I or II studies comparing approaches.²⁸

Open distal clavicle excision has been reported to produce excellent results for various types of AC joint pathology including DCO. Slawski and Cahill³⁶ examined 14 consecutive patients who underwent 17 distal clavicle resections for atraumatic DCO. Mean follow-up was 25 months, and the UCLA Shoulder Rating Scale was used for evaluation. Eight patients had a good result, and 9 patients had an excellent result; all of the patients returned to sport or work at a satisfactory level.³⁶

The largest case series of open clavicle resection for DCO was performed by Cahill.³ In this series, 21 patients underwent surgery, and 25 patients underwent nonoperative treatment. Nineteen of the 21 patients (90%) who underwent surgery reported symptom relief with a mean follow-up of 7 years.

Arthroscopic intervention also has produced positive outcomes. Auge and Fischer²⁹ reported on 10 weight lifters (average age, 30.4 years) with unilateral DCO refractory to nonoperative management who underwent arthroscopic clavicle resection. At mean follow-up of 18.7 months, all of the patients had returned to their previous training program at an average of 9.1 days.²⁹ The authors commented that the ability to continue training with minimal interruption and improved cosmetic appearance were both advantages of the arthroscopic approach.²⁹

Zawadsky et al³⁷ examined the long-term outcomes of 41 shoulders in 37 patients following arthroscopic intervention. Distal clavicle osteolysis was traumatic in 18 shoulders and atraumatic in 23 should-

ers. At a mean follow-up of 6.2 years, 22 shoulders had excellent results, 16 had good results, and 3 were failures; the failures occurred in all patients with DCO due to trauma.³⁷

In their systematic review, Rabalais and McCarty²⁸ concluded that distal clavicle excision, both open and arthroscopic, improved symptoms in the presence of osteolysis and osteoarthritis; however, this was based mainly on level III and IV evidence. The systemic review found that open techniques achieved good or excellent results in 76.3% of patients, whereas isolated arthroscopic excision resulted in good or excellent outcomes in 92.5%. However, many of the studies reviewed by Rabalais and McCarty²⁸ used several different systems of determining functional outcomes, making them difficult to compare directly. In addition, they found that in combination with other procedures such as subacromial decompression, retrospective studies reported an average outcome of 94.7% good or excellent results.

Although there are multiple studies comparing the results of open vs arthroscopic procedures, there is a paucity of studies comparing various arthroscopic techniques. Charron et al²¹ performed a level II prospective study comparing 34 athletes via direct and indirect approach with a minimum of 2 years of follow-up. The direct approach group had statistically significantly higher American Shoulder and Elbow Surgeons (ASES) scores at final follow-up and demonstrated significantly faster return to sport (average 21 vs 42 days). Overall, both groups demonstrated excellent clinical outcomes.

It is important to distinguish DCO from AC joint arthritis, and outcomes can differ following operative injury between the 2 conditions. Distal clavicle osteolysis can be diagnosed when pathologic changes such as sclerosis, reactive bone formation, and subchondral cysts are isolated to the distal clavicle only. A majority of studies examining outcomes following distal clavicle do not distinguish between pa-

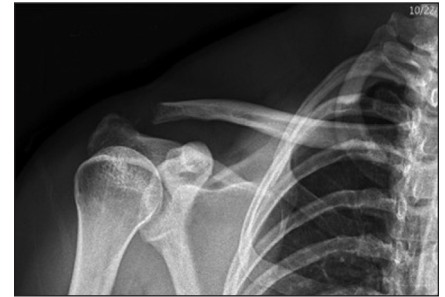

Figure 4: Postoperative Zanca radiograph showing adequate decompression of the acromioclavicular joint.

tients treated for DCO vs AC joint arthritis; however, several such studies do exist. Specifically, patients with traumatic AC joint arthritis and degenerative arthritis tend to do worse than patients with DCO.

Eskola et al³⁸ performed distal clavicle resection in a total of 73 patients. Of these, 32 patients had symptomatic AC joint separation, 8 patients had lateral clavicle fracture, and 33 patients had primary AC joint osteoarthritis. The results were good in 21 patients, satisfactory in 29 patients, and poor in 23 patients. A poor result was more common in patients with distal clavicle fracture, and a good result was more common in patients in whom less than 10 mm of clavicle was resected. The authors concluded that distal clavicle excision should be performed with caution in patients following fracture or patients with severe arthritis, and if performed, minimal distal clavicle should be resected. Additional prospective studies are required to further evaluate differences in treatment outcomes of these 2 conditions.

CONCLUSION

Although relatively uncommon, DCO can be a debilitating condition, especially for young athletes. Many patients will improve with conservative treatment consisting primarily of activity modification; however, a subset of patients ultimately will require surgical treatment. Both open and arthroscopic techniques have demonstrated acceptable clinical outcomes. Arthroscopic techniques appear to be

used more commonly, with the ability to address concomitant shoulder pathology. The literature overall appears to be slightly in favor of the direct arthroscopic approach compared with the indirect approach; however, both have demonstrated excellent long-term outcomes.

REFERENCES

- Dupas J, Badelon DG. Aspects radiologiques d'une osteolyse essentielle progressive de la main gauche. *J Radiol*. 1936; (20):383-387.
- Schwarzkopf R, Ishak C, Elman M, Gelber J, Strauss DN, Jazrawi LM. Distal clavicular osteolysis: a review of the literature. *Bull NYU Hosp Jt Dis*. 2008; 66(2):94-101.
- Cahill BR. Osteolysis of the distal part of the clavicle in male athletes. *J Bone Joint Surg Am*. 1982; 64(7):1053-1058.
- Ehrlich HG. Osteolysis of the lateral clavicular end after compressed air damage [in German]. *Arch Orthop Unfallchir*. 1959; 50:576-582.
- Orava S, Virtanen K, Holopainen YV. Post-traumatic osteolysis of the distal ends of the clavicle: report of three cases. *Ann Chir Gynaecol*. 1984; 73(2):83-86.
- Matthews LS, Simonson BG, Wolock BS. Osteolysis of the distal clavicle in a female body builder: a case report. *Am J Sports Med*. 1993; 21(1):150-152.
- Brunet ME, Reynolds MC, Cook SD, Brown TW. Atraumatic osteolysis of the distal clavicle: histologic evidence of synovial pathogenesis: a case report. *Orthopedics*. 1986; 9(4):557-559.
- Haupt HA. Upper extremity injuries associated with strength training. *Clin Sports Med*. 2001; 20(3):481-490.
- Nuber GW, Bowen MK. Arthroscopic treatment of acromioclavicular joint injuries and results. *Clin Sports Med*. 2003; 22(2):301-317.
- Zanca P. Shoulder pain: involvement of the acromioclavicular joint. Analysis of 1,000 cases. *Am J Roentgenol Radium Ther Nucl Med*. 1971; 112(3):493-506.
- de la Puente R, Boutin RD, Theodorou DJ, Hooper A, Schweitzer M, Resnick D. Post-traumatic and stress-induced osteolysis of the distal clavicle: MR imaging findings in 17 patients. *Skeletal Radiol*. 1999; 28(4):202-208.
- Worcester JN Jr, Green DP. Osteoarthritis of the acromioclavicular joint. *Clin Orthop Relat Res*. 1968; 58:69-73.
- Sopov V, Fuchs D, Bar-Meir E, Groshar D. Stress-induced osteolysis of distal clavicle: imaging patterns and treatment using CT-guided injection. *Eur Radiol*. 2001; 11(2):270-272.
- Robertson WJ, Griffith MH, Carroll K, O'Donnell T, Gill TJ. Arthroscopic versus open distal clavicle excision: a comparative assessment at intermediate-term follow-up. *Am J Sports Med*. 2011; 39(11):2415-2420.
- Shaffer BS. Painful conditions of the acromioclavicular joint. *J Am Acad Orthop Surg*. 1999; 7(3):176-188.
- Cibulka MT, Hunter HC. Acromioclavicular joint arthritis treated by mobilizing the glenohumeral joint: a case report. *Phys Ther*. 1985; 65(10):1514-1516.
- Borbas P, Kraus T, Clement H, Grechenig S, Weinberg AM, Heidari N. The influence of ultrasound guidance in the rate of success of acromioclavicular joint injection: an experimental study on human cadavers. *J Shoulder Elbow Surg*. 2012; 21(12):1694-1697.
- Daley EL, Bajaj S, Bisson LJ, Cole BJ. Improving injection accuracy of the elbow, knee, and shoulder: does injection site and imaging make a difference? A systematic review. *Am J Sports Med*. 2011; 39(3):656-662.
- Brown JN, Roberts SN, Hayes MG, Sales AD. Shoulder pathology associated with symptomatic acromioclavicular joint degeneration. *J Shoulder Elbow Surg*. 2000; 9(3):173-176.
- Pensak M, Grumet RC, Slabaugh MA, Bach BR Jr. Open versus arthroscopic distal clavicle resection. *Arthroscopy*. 2010; 26(5):697-704.
- Charron KM, Schepsis AA, Voloshin I. Arthroscopic distal clavicle resection in athletes: a prospective comparison of the direct and indirect approach. *Am J Sports Med*. 2007; 35(1):53-58.
- Elhassan B, Ozbaydar M, Diller D, Massimini D, Higgins LD, Warner JJ. Open versus arthroscopic acromioclavicular joint resection: a retrospective comparison study. *Arthroscopy*. 2009; 25(11):1224-1232.
- Freedman BA, Javernick MA, O'Brien FP, Ross AE, Doukas WC. Arthroscopic versus open distal clavicle excision: comparative results at six months and one year from a randomized, prospective clinical trial. *J Shoulder Elbow Surg*. 2007; 16(4):413-418.
- Levine WN, Soong M, Ahmad CS, Blaine TA, Bigliani LU. Arthroscopic distal clavicle resection: a comparison of bursal and direct approaches. *Arthroscopy*. 2006; 22(5):516-520.
- Mumford EB. Acromioclavicular dislocation. *J Bone Joint Surg Am*. 1941; 23(4):799-802.
- Gurd FB. The treatment of complete dislocation of the outer end of the clavicle: an hitherto undescribed operation. *Ann Surg*. 1941; 113(6):1094-1098.
- Neviaser TJ, Neviaser RJ, Neviaser JS, Neviaser JS. The four-in-one arthroplasty for the painful arc syndrome. *Clin Orthop Relat Res*. 1982; 163:107-112.
- Rabalais RD, McCarty E. Surgical treatment of symptomatic acromioclavicular joint problems: a systematic review. *Clin Orthop Relat Res*. 2007; 455:30-37.
- Auge WK II, Fischer RA. Arthroscopic distal clavicle resection for isolated atraumatic osteolysis in weight lifters. *Am J Sports Med*. 1998; 26(2):189-192.
- Erickson SJ, Kneeland JB, Komorowski RA, Knudson GJ, Carrera GF. Post-traumatic osteolysis of the clavicle: MR features. *J Comput Assist Tomogr*. 1990; 14(5):835-837.
- Gartsman GM. Arthroscopic resection of the acromioclavicular joint. *Am J Sports Med*. 1993; 21(1):71-77.
- Kay SP, Dragoo JL, Lee R. Long-term results of arthroscopic resection of the distal clavicle with concomitant subacromial decompression. *Arthroscopy*. 2003; 19(8):805-809.
- Jerosch J, Steinbeck J, Schröder M, Castro WH. Arthroscopic resection of the acromioclavicular joint (ARAC). *Knee Surg Sports Traumatol Arthrosc*. 1993; 1(3-4):209-215.
- Tolin BS, Snyder SJ. Our technique for the arthroscopic Mumford procedure. *Orthop Clin North Am*. 1993; 24(1):143-151.
- Jacob AK, Sallay PI. Therapeutic efficacy of corticosteroid injections in the acromioclavicular joint. *Biomed Sci Instrum*. 1997; 34:380-385.
- Slawski DP, Cahill BR. Atraumatic osteolysis of the distal clavicle: results of open surgical excision. *Am J Sports Med*. 1994; 22(2):267-271.
- Zawadsky M, Marra G, Wiater JM, et al. Osteolysis of the distal clavicle: long-term results of arthroscopic resection. *Arthroscopy*. 2000; 16(6):600-605.
- Eskola A, Santavirta S, Viljakka HT, Wirta J, Partio TE, Hoiikka V. The results of operative resection of the lateral end of the clavicle. *J Bone Joint Surg Am*. 1996; 78(4):584-587.



To see more Blue Ribbon Articles online,
visit www.Healio.com/Ortho/BlueRibbon.