

# Intravenous Administration of Acetylsalicylic Acid During Endovascular Treatment of Cerebral Aneurysms Reduces the Rate of Thromboembolic Events

Thorsten Ries, MD; Jan-Hendrik Buhk, MD; Thomas Kucinski, MD; Einar Goebell, MD; Ulrich Grzyska, MD; Hermann Zeumer, MD; Jens Fiehler, MD

**Background and Purpose**—The purpose of this study is to analyze the effect of a modified intraoperative anticoagulation strategy including acetylsalicylic acid (ASA) on complication rates during endovascular coil embolization.

**Methods**—Two hundred and sixty-one cerebral aneurysms were treated in 247 patients by endovascular coil embolization from January 2001 to September 2004. Additional intravenous administration of 250 mg ASA was applied since January 2003. Patients treated before (–ASA; n=102 aneurysms) and after that date (+ASA; n=159 aneurysms) were compared. End points were rates of thromboembolism and severity of hemorrhages after intraoperative aneurysm rupture.

**Results**—Thromboembolic events during the procedure were observed more often in the –ASA group (18/102 aneurysms, 17.6%) in comparison with the +ASA group (14/159 aneurysms, 8.8%;  $P=0.028$ ; Fisher exact test). Aneurysm perforation events occurring during or immediately after the procedure were observed equally often in the –ASA group (7/102 aneurysms, 6.9%) in comparison with the +ASA group (10/159 aneurysms, 6.3%).

**Conclusion**—Intravenous application of ASA is feasible and safe during interventional aneurysm embolization. ASA seems to be associated with a significant reduction in the rate of thromboembolic events without increase in the rate or severity of intraoperative bleedings. (*Stroke*. 2006;37:1816-1821.)

**Key Words:** anticoagulants ■ aspirin ■ cerebral aneurysm ■ embolism ■ rupture ■ subarachnoid hemorrhage

Endovascular embolization of cerebral aneurysms is associated with low morbidity and mortality rates and has become widely used in patients with ruptured and unruptured intracranial aneurysms.<sup>1-5</sup> Selective occlusion of intracranial aneurysms with detachable coils has an overall estimated procedure-related permanent complication rate of 3.7% to 6.8%.<sup>2,6</sup> Thromboembolic events with partially or completely persisting neurological deficits are reported in 2.4% to 5.2% of endovascular-treated patients.<sup>1,4,7</sup> Intraprocedural systemic administration of heparin is widely used in several institutes to reduce the risk of thromboembolism.<sup>1,4,8</sup> Acute clotting at the thrombogenic interventional materials is considered the most important source of thromboembolism during endovascular embolization of cerebral aneurysms. Inhibition of the platelet function by acetylsalicylic acid (ASA) might be an effective strategy to minimize the rate of thromboembolism. It has been known for some time from coronary angioplasty that ASA reduces the risk of thrombosis if started before the procedure.<sup>9</sup> Presently, no valid data exist about antiplatelet therapy and prevention of thromboembolic events during or after endovascular treatment. Even if the anticoagulation strategy is the most important factor to decrease the rate of

embolic events during aneurysm treatment, the strategy has to balance the risks of thromboembolism and bleeding. Based on these considerations, we introduced an additional intravenous administration of ASA during endovascular treatment of aneurysms in our institution for ruptured and unruptured aneurysms. This article describes the effect of the modified intraoperative anticoagulation strategy on the rate of thromboembolism and the rate and severity of hemorrhages after intraoperative aneurysm rupture.

## Methods

Between January 2001 and September 2004, endovascular aneurysm embolization was performed in 247 consecutive patients with 261 cerebral aneurysms in our institution.

## Anticoagulation Strategy

In order to minimize thromboembolic complications, all flush solutions including the guiding-catheters and the microcatheters were heparinized. Heparin was applied intravenously in ruptured and unruptured aneurysms before placement of the guiding-catheter. From January 2003, 250 mg ASA (Aspisol, Bayer, Germany) was additionally administered intravenously during Guglielmi detachable coil treatment after deployment of the first coil, in ruptured and unruptured aneurysms. In the case of aneurysm perforation before or during the first coil, ASA

Received November 25, 2005; final revision received January 26, 2006; accepted March 21, 2006.

From the Department of Neuroradiology, University Medical Center Hamburg-Eppendorf, Hamburg, Germany.

Correspondence to Jens Fiehler, MD, Department of Neuroradiology, University Medical Center Hamburg-Eppendorf, Martinistrasse 52, 20246 Hamburg, Germany. E-mail fiehler@uke.uni-hamburg.de

© 2006 American Heart Association, Inc.

Stroke is available at <http://www.strokeaha.org>

DOI: 10.1161/01.STR.0000226933.44962.a6

**TABLE 1. Initial Anticoagulation Strategy Until January 2003 (–ASA)**

Drug	Ruptured Acute Treatment	Unruptured	
		Premedication	Acute Treatment
Low-molecular-weight heparin	...	40 mg SC on day before intervention 20 mg SC on day of intervention	...
Heparin	ACT 250–300 s before guiding-catheter	...	ACT 250–300 s before guiding-catheter

ACT indicates activated clotting time.

was not applied. Patients were categorized in all cases based on treatment date before or after January 2003 as –ASA and +ASA on an intention-to-treat basis. The initial and modified anticoagulation strategies are specified in Tables 1 and 2.

### Definition of Clotting and Perforation

A thromboembolic event was angiographically defined as any event with complete or partial occlusion of arteries in any vascular territory. Aneurysm perforation was assumed in case of any amount of contrast agent extravasation with or without any clinical impact.

### Data Analysis

The patients treated with intraoperative ASA administration (+ASA, n=159) and without intraoperative ASA administration (–ASA, n=102) were compared with regard to thromboembolic and perforation events. Furthermore, we analyzed clinical presentation, morphological findings, and clinical outcome. Statistical analysis was performed using SPSS10.07. Fischer exact test was used for comparison of the rate of incidents. The significance level was defined as  $P < 0.05$ .

### Results

Two hundred and sixty-one aneurysms were treated with Guglielmi detachable coils in 247 patients (195 women, 52 men). The median age of the patients was 52 (20 to 80) years. We observed clotting in 6/77 (7.7%) of the patients with unruptured aneurysms and in 26/184 (10.3%) in patients with

**TABLE 2. Modified Anticoagulation Strategy Since January 2003 (+ASA)**

Drug	Ruptured Acute Treatment	Unruptured	
		Premedication	Acute Treatment
ASA	250 mg IV after the first coil	...	250 mg IV after the first coil
Clopidogrel	...	75 mg PO daily (3 d)	...
Low-molecular-weight heparin	...	40 mg SC on day before intervention 20 mg SC on day of intervention	...
Heparin	2000–3000 IU IV before guiding-catheter	...	2000–3000 IU IV before guiding-catheter

PO indicates per os; IU, international units.

subarachnoid hemorrhage (SAH). Intraoperative aneurysm perforation occurred in 2/77 (2.6%) of the patients with unruptured aneurysms and in 15/184 (8.2%) in patients with SAH.

Before modification of anticoagulation regimen, we treated 102 aneurysms (–ASA group) and after introduction of ASA 159 aneurysms (+ASA group). The rate of unruptured aneurysms was 27/102 patients (26.5%) in the –ASA group and 50/159 (31.4%) patients in the +ASA group. Among SAH patients there was no significant difference in the rate of poor initial Hunt & Hess grades (4 and 5) between the groups: 48.6% (–ASA group) versus 40.5% (+ASA group).

There were also no significant differences between –ASA and +ASA regarding the aneurysm sizes and localizations. We treated 41%/49% (–ASA/+ASA) aneurysms <6 mm, 53%/45% aneurysms 6 to 15 mm, and 6%/5% aneurysms 15 to 25 mm. Aneurysm localizations were internal carotid artery 17%/26% (–ASA/+ASA), middle cerebral artery 6%/5%, anterior cerebral artery 34%/38%, posterior communicating artery 12%/10%, posterior cerebral artery (P2) 1%/0%, basilar artery 19%/13%, basilar tip 7%/4%, vertebral artery 2%/1%, and posterior inferior cerebellar artery 3%/3%.

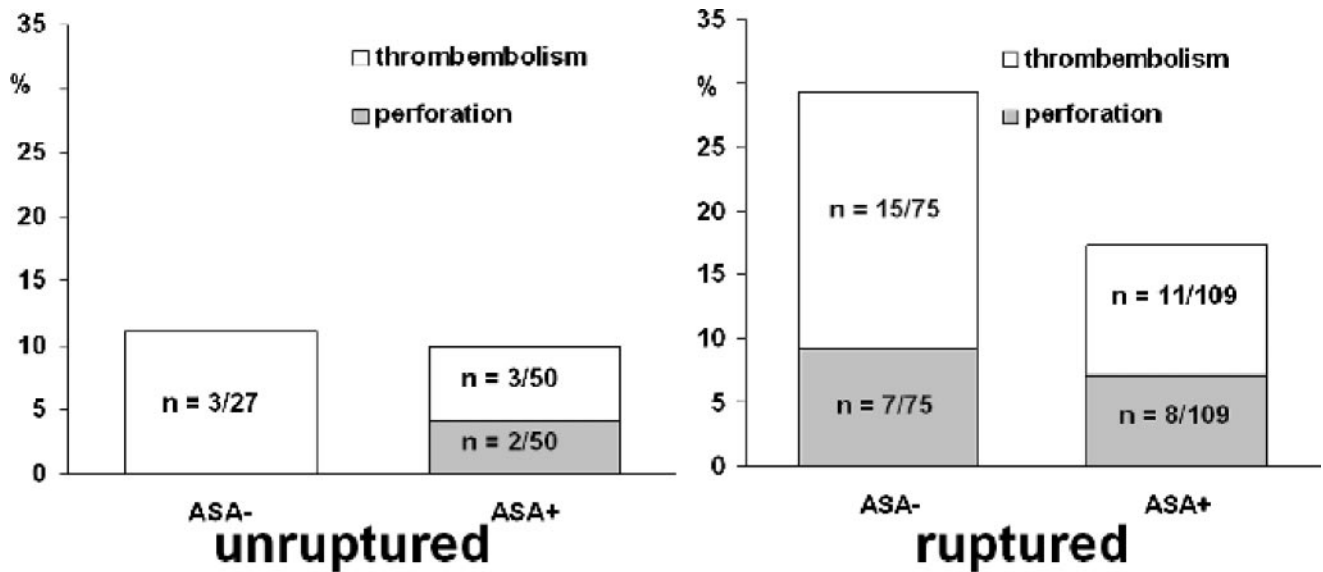
### Thromboembolic Events

Thromboembolic events occurring during or immediately after the procedure were observed more often in the –ASA group (18/102 patients, 17.6%) in comparison with the +ASA group (14/159 patients, 8.8%;  $P=0.028$ ). In a separate analysis of patients with ruptured aneurysms we found fewer ( $P=0.047$ ) thromboembolic events in the +ASA group (11/109 patients, 10.1%) in comparison with the –ASA group (15/75 patients, 20.0%). In patients with unruptured aneurysms we observed an unequivocal trend (not significant) toward fewer patients with thromboembolism in the +ASA group (3/50 patients, 6.0%) in comparison with the –ASA group (2/27 patients, 11.1%). For illustrations and numbers see the Figure.

After occurrence of embolism we intra-arterially applied GPIIb/IIIa antagonists (ReoPro) in 10 patients and tissue plasminogen activator (tPA) in 4 patients (Actilyse). No thrombolytic therapy was applied in cases of incomplete vessel narrowing, spontaneously resolving thrombi, good collateralization, and very peripheral location of the embolus and in cases of concomitant hemorrhage (Table 3). An infarct in the corresponding vascular territory was found on follow-up CT in 17/32 (47.2%) of the patients. In 1 case no follow-up CT was performed. There was no difference in outcome in case of a thromboembolism between both groups. Good outcome (Glasgow Outcome Scale 4 or 5) was observed in 10/18 (56%) of the patients in the –ASA group and 8/14 (57%) of the patients in the +ASA group.

### Aneurysm Perforation

Intraoperative aneurysm perforation events were observed equally often in both groups: 7/102 patients in the –ASA group (6.9%) versus 10/159 patients in the +ASA group (6.3%). A perforation was recorded before or during the first coil in 7/17 patients (41%) and, therefore, without intraoperative application of ASA even in the +ASA group (Table 4).



Rates and absolute numbers of cases with thromboembolism and intraprocedural aneurysm perforation.

Two of these 7 patients had unruptured aneurysms (+ASA group) and had received clopidogrel preoperatively (Table 2).

There were no differences in outcome after perforation between the -ASA and the +ASA group. Good outcome was observed in 3/7 of the patients in the -ASA group and 5/10 of patients in the +ASA group. The mortality rate after intraoperative aneurysm perforation was 2/7 in the -ASA group and 4/10 of the patients in the +ASA group. Among surviving patients, there was no difference in outcome after intraoperative aneurysm perforation between both groups (Table 4).

### Discussion

We found a decrease in the rate of thromboembolic events without an increase of the intraoperative bleeding rate after introduction of intraoperative ASA application. In cases of parent vessel or aneurysm perforation, we found no evidence for a different outcome after ASA application.

#### Current Standards in Anticoagulation/Antiplatelet Strategy

Because of the absence of evidence-based data, the guidelines of several neuroradiological and neurointerventional societies state that anticoagulant therapy for patients with cerebral aneurysms should be at the discretion of the endovascular therapist.<sup>10</sup> There seems to be fundamental agreement among institutions about the usage of heparin during aneurysm embolization because reported anticoagulation strategies are similar.<sup>11,12,8,13</sup> This is somewhat supported by a review comparing observational series with and without administration of heparin or ASA after the procedure which showed a lower rate of thromboembolic complications when heparin or ASA was used.<sup>14</sup> Furthermore, a meta-analysis did not confirm an increase in morbidity and mortality rates after intraprocedural perforation in heparinized patients in comparison to patients without heparin.<sup>15</sup>

#### Pathophysiology of Thromboembolism and ASA

Thromboembolism during endovascular embolization of cerebral aneurysms may result from acute clotting originating from arterial catheters, contrast agents, implanted devices such as coils and stents and mobilization of thrombus from within the aneurysm which may lead to distal embolism. Intraprocedural thrombosis of the parent artery probably primarily develops at the interface of coils attributable to platelet aggregation. Anticoagulation using heparin has primarily antithrombotic effects through its activity on several coagulation factors and shows minor platelet effects, whereas ASA shows strong and irreversible blocking of the platelet aggregation. As compared with conventional anticoagulant therapy, combined antiplatelet therapy after the placement of coronary-artery stents reduces the incidence of cardiac events and vascular complications.<sup>16</sup> The different action of ASA might have an additive effect on coagulation to heparin alone in endovascular therapy. Our data support this hypothesis: administration of ASA in addition to heparin seems to reduce the rate of thromboembolic events.

SAH patients who had salicylates on admission revealed a reduced risk of cerebral infarction compared with those without salicylates.<sup>17</sup> Patients who had already used ASA before SAH and continued these medication after SAH revealed an increased risk for rebleeding.<sup>17</sup> It has been suggested by a recent meta-analysis that ASA can prevent delayed cerebral ischemia after SAH with only modest effects on the rate of intracranial hemorrhage.<sup>18</sup>

#### Frequency of Thromboembolism

Using the highly sensitive diffusion-weighted MRI, predominantly silent embolism was detected in up to 61% of the patients.<sup>19,20</sup> The intraoperative rate of symptomatic thromboembolic events is reported to be 2.4% to 5.2% of the endovascularly treated aneurysm patients.<sup>1,4,7</sup>

Using angiography, we found 6.0% to 20% thromboembolic events dependent on the presence of SAH and application of ASA. This is well within the range found in the

TABLE 3. Patients With Clotting Events

	Treatment Group	Sex	Hunt & Hess Grade	GOS	Location of Aneurysm	Size, mm	Location of Thrombus	Acute Therapy	Infarct on CT/ Cause of Death
1	+ASA	F	II	5	ACom	4	MCA	ReoPro	Yes
2	+ASA	M	0	UC	ICAo	8	MCA	ReoPro	Yes
3	+ASA	F	0	1	ICAo	9	MCA	ReoPro	No/MSOI
4	+ASA	F	V	1	ACom	5	ICA	ReoPro	Yes/CDICP
5	+ASA	F	I	5	ACom	3	MCA	ReoPro	No
6	+ASA	F	II	5	ACom	7	ACA	...	No
7	+ASA	F	II	4	BAtip	14	PCA	...	Yes
8	+ASA	F	V	3	ICA	2	ACA	...	No
9	+ASA	F	IV	4	BAtip	2	PCA	ReoPro	Yes
10	+ASA	M	I	5	ACA	8	MCA	ReoPro	No
11	+ASA	F	III	3	ICAo	11	MCA	ReoPro	No
12	+ASA	F	0	UC	PCom	7	MCA	rtPA	Yes
13	+ASA	F	III	3	BA tip	6	PCA	ReoPro	No
14	+ASA	F	IV	5	ACom	9	ACA	ReoPro	Yes
15	-ASA	F	V	5	ICA	14	ICA	...	No
16	-ASA	F	0	UC	PCom	10	PCA	...	No
17	-ASA	M	I	5	ACom	3	MCA	...	Yes
18	-ASA	F	III	4	PCom	10	MCA	rtPA	Yes
19	-ASA	F	II	5	BAtip	8	PCA	...	No
20	-ASA	F	V	1	BAtip	11	PCA	...	No/CDICP
21	-ASA	F	0	UC	ICAo	4	ICA	...	No
22	-ASA	F	I	5	ACA	6	ACA	...	No
23	-ASA	F	V	1	ACA	10	MCA	...	Yes/MSOI
24	-ASA	M	V	1	ACom	12	MCA	rtPA	Yes/sepsis
25	-ASA	F	V	1	ACom	5	ACA	...	Yes/CDICP
26	-ASA	F	II	1	MCA	18	MCA	rtPA	Yes/hemorrhage
27	-ASA	M	V	5	ACA	8	ACA	...	No
28	-ASA	F	0	UC	PCom	8	PCA	...	Yes
29	-ASA	M	IV	2	ACom	4	MCA	...	Yes
30	-ASA	F	II	5	ICAo	15	ICA	...	Yes
31	-ASA	F	V	1	ACom	7	ACA	...	Yes/MSOI
32	-ASA	F	V	1	ACom	9	ICA/MCA	...	No CT/MSOI

GOS indicates Glasgow Outcome Scale; UC, outcome unchanged; ACA, anterior cerebral artery; ACom, anterior communicating artery; BAtip, basilar tip; ICA, internal carotid artery; ICAo, internal carotid artery, ophthalmic artery; MCA, middle cerebral artery; PCA, posterior cerebral artery; PCom, posterior communicating artery; PICA, posterior inferior cerebellar artery; CDICP, cerebral deregulation, intracranial pressure increase; MSOI, multiple space occupying infarcts, intracranial pressure increase.

literature of 2.4% to 28% of patients.<sup>1,7</sup> A major finding of our analysis is the significant decrease in the rate of thromboembolic events from 20.0% to 10.1% in SAH patients after intravenous application of ASA during the procedure. Because of heterogeneity in the patients we did not attempt to find a difference in the clinical outcome.

### Treatment and Clinical Relevance of Thromboembolism

An infarct in the corresponding vascular territory was found in 47.2% of patients with angiographically confirmed thromboembolism. Treatment options in case of thromboembolism include local application of tPA, urokinase or GPIIb/IIIa antagonists. Red thrombi (low-flow-thrombus; rich in fibrin

and trapped erythrocytes, thought to be caused by guiding catheter) can be treated by tPA, whereas white thrombi (high-flow-thrombus; mainly platelet aggregation, thought to be coil-related) do much better respond to GPIIb/IIIa antagonists. The local treatment of thromboembolic events may have disastrous consequences.<sup>21</sup> Coil-related platelet aggregation is unlikely to respond to fibrinolytics but has a high risk of hemorrhage. In the International Subarachnoid Aneurysm Trial (ISAT), all 5 patients who had received thrombolytic therapy with tPA to treat a thromboembolic complication after endovascular treatment rebled and all of these patients died.<sup>22</sup> In our series, 2/4 patients treated by tPA died (1 by a space-occupying hemorrhage and 1 by a sepsis later on).

TABLE 4. Patients With Intraoperative Rupture Events

	Treatment Group	ASA Administration?	Sex	Hunt & Hess Grade	Location of Aneurysm	Size, mm	GOS	Cause of Death
1	+ASA	Yes	F	III	ICAo	5	5	...
2	+ASA	Yes	F	II	BAtip	6	3	...
3	+ASA	Yes	F	III	BAtip	5	1	CDICP
4	+ASA	Yes	F	III	BAtip	3	4	...
5	+ASA	No	F	II	PICA	4	1	CDICP
6	+ASA	No	F	0	PCom	3	5	...
7	+ASA	No	F	V	ACom	3	1	MSOI
8	+ASA	No	F	V	ACA	4	4	...
9	+ASA	No	F	II	ICAo	7	1	MSOI
10	+ASA	No	F	0	ICAo	10	5	...
11	-ASA	No	F	V	ACA	4	3	...
12	-ASA	No	F	III	ACA	8	1	CDICP
13	-ASA	No	F	II	PICA	6	5	...
14	-ASA	No	M	III	ACom	2	3	...
15	-ASA	No	F	I	ACA	4	5	...
16	-ASA	No	F	II	MCA	18	1	CDICP
17	-ASA	No	F	II	ICAo	15	5	...

See legend for Table 3.

Recently, GPIIb/IIIa antagonists are considered the main progress for the treatment of procedure-related thromboembolism.<sup>23–25</sup> We found a mortality rate in 2/10 patients treated with GPIIb/IIIa antagonists (abciximab). Both patients died from secondary complications of SAH, not from a procedure-related hemorrhage. This supports the view that abciximab does not resolve slow flow thrombi within the aneurysm but the white thrombus related embolism. However, numbers are too low to allow sound conclusions.

### Perforation and Aneurysm Perforation

One of the main risks of endovascular treatment is the perforation of the parent vessel or aneurysm. Reported rates are 0.5% to 2.4% of the patients with unruptured aneurysms<sup>15,26</sup> and 2.3% to 4.3% of the SAH patients.<sup>1,2,4,15,27</sup> However, unrecognized perforations almost certainly occur in an uncertain number of more patients.<sup>2</sup>

An adverse event after application of ASA could be a larger hematoma in case of intraoperative aneurysm perforation while the perforation risk itself should not be increased. In our series, first catheterization of the aneurysm sac with its inherently increased perforation risk attributable to the manipulation with guide wire and microcatheter was done without ASA because it was applied intravenously after placement of the first coil. It is uncertain in the literature whether the perforation risk is higher during administration of the first coil<sup>27</sup> or during later filling of the sac.<sup>27–30</sup> Our strategy to apply ASA after placement of the first coil allows confirmation of the correct placement of the microcatheter, thereby enabling quick progress of the procedure in case of perforation and bleeding. Probably based on similar reasoning Bendok et al describe that the second half of the heparin dose is administered after the first coil has been securely placed in the aneurysm.<sup>31</sup> We found perforation in 7/17 (41%)

of the cases before or during the deployment of the first coil and thus without ASA application. Six of these patients were treated after January 2003 and were categorized as +ASA on an intention-to-treat basis. There was no unequivocal difference in outcome after perforation between patients who truly received ASA (n=4) compared with patients who did not receive ASA (n=13; Table 4).

### Conclusion

Intravenous application of ASA is feasible and safe during interventional aneurysm treatment both in unruptured aneurysms and after SAH. The presented data suggest that intraoperative ASA application is associated with a significant reduction in the rate of thromboembolic events without increasing in the rate or severity of intraoperative bleedings. Before ASA can be routinely recommended during endovascular aneurysm therapy, a randomized clinical trial would be desirable.

### Acknowledgments

We thank Dr Matthew Wing of Hamburg for his advice on language.

### Disclosures

None.

### References

- Murayama Y, Nien YL, Duckwiler G, Gobin YP, Jahan R, Frazee J, Martin N, Vinuela F. Guglielmi detachable coil embolization of cerebral aneurysms: 11 years' experience. *J Neurosurg.* 2003;98:959–966.
- Henkes H, Fischer S, Weber W, Miloslavski E, Felber S, Brew S, Kuehne D. Endovascular coil occlusion of 1811 intracranial aneurysms: Early angiographic and clinical results. *Neurosurgery.* 2004;54:268–280; discussion 280–265.
- Groden C, Kremer C, Regelsberger J, Hansen HC, Zeumer H. Comparison of operative and endovascular treatment of anterior circulation aneurysms in patients in poor grades. *Neuroradiology.* 2001;43:778–783.

4. Gallas S, Pasco A, Cottier J, Gabrillargues J, Drouineau J, Cognard C, Herbreteau D. A multicenter study of 705 ruptured intracranial aneurysms treated with Guglielmi detachable coils. *AJNR Am J Neuroradiol*. 2005; 26:1723–1731.
5. Solymsi L, Chapot R, Bendszus M. Stent, balloon, or clip? The problem of wide-necked aneurysms. *Klinische Neuroradiologie*. 2005;3:145–160.
6. Brillstra EH, Rinkel GJ, van der Graaf Y, van Rooij WJ, Algra A. Treatment of intracranial aneurysms by embolization with coils: A systematic review. *Stroke*. 1999;30:470–476.
7. Pelz DM, Lownie SP, Fox AJ. Thromboembolic events associated with the treatment of cerebral aneurysms with Guglielmi detachable coils. *AJNR Am J Neuroradiol*. 1998;19:1541–1547.
8. Byrne JV, Molyneux AJ, Brennan RP, Renowden SA. Embolisation of recently ruptured intracranial aneurysms. *J Neurol Neurosurg Psychiatry*. 1995;59:616–620.
9. Willard J, Lange R, Hillis L. The use of aspirin in ischemic heart disease. *N Engl J Med*. 1992;327:175–181.
10. Education ACoGM. Aneurysm endovascular therapy. *AJNR Am J Neuroradiol (Suppl)*. 2001;22:S4–S7.
11. Gonzalez NR, Murayama Y, Nien YL, Martin N, Frazee J, Duckwiler G, Jahan R, Gobin YP, Vinuela F. Treatment of unruptured aneurysms with GDCs: Clinical experience with 247 aneurysms. *AJNR Am J Neuroradiol*. 2004;25:577–583.
12. Friedman JA, Nichols DA, Meyer FB, Pichelmann MA, McIver JI, Toussaint LG 3rd, Axley PL, Brown RD Jr. Guglielmi detachable coil treatment of ruptured saccular cerebral aneurysms: Retrospective review of a 10-year single-center experience. *AJNR Am J Neuroradiol*. 2003;24: 526–533.
13. Workman MJ, Cloft HJ, Tong FC, Dion JE, Jensen ME, Marx WF, Kallmes DF. Thrombus formation at the neck of cerebral aneurysms during treatment with Guglielmi detachable coils. *AJNR Am J Neuroradiol*. 2002;23:1568–1576.
14. Qureshi AI, Mohammad Y, Yahia AM, Luft AR, Sharma M, Tamargo RJ, Frankel MR. Ischemic events associated with unruptured intracranial aneurysms: Multicenter clinical study and review of the literature. *Neurosurgery*. 2000;46:282–289; discussion 289–290.
15. Cloft HJ, Kallmes DF. Cerebral aneurysm perforations complicating therapy with Guglielmi detachable coils: A meta-analysis. *AJNR Am J Neuroradiol*. 2002;23:1706–1709.
16. Schomig A, Neumann FJ, Kastrati A, Schuhlen H, Blasini R, Hadamitzky M, Walter H, Zitzmann-Roth EM, Richardt G, Alt E, Schmitt C, Ulm K. A randomized comparison of antiplatelet and anticoagulant therapy after the placement of coronary-artery stents. *N Engl J Med*. 1996;334: 1084–1089.
17. Juvela S. Aspirin and delayed cerebral ischemia after aneurysmal subarachnoid hemorrhage. *J Neurosurg*. 1995;82:945–952.
18. Dorhout Mees SM, Rinkel GJ, Hop JW, Algra A, van Gijn J. Antiplatelet therapy in aneurysmal subarachnoid hemorrhage: A systematic review. *Stroke*. 2003;34:2285–2289.
19. Rordorf G, Bellon RJ, Budzik RE Jr, Farkas J, Reinking GF, Pergolizzi RS, Ezzeddine M, Norbash AM, Gonzalez RG, Putman CM. Silent thromboembolic events associated with the treatment of unruptured cerebral aneurysms by use of Guglielmi detachable coils: Prospective study applying diffusion-weighted imaging. *AJNR Am J Neuroradiol*. 2001;22:5–10.
20. Soeda A, Sakai N, Sakai H, Iihara K, Yamada N, Imakita S, Nagata I. Thromboembolic events associated with Guglielmi detachable coil embolization of asymptomatic cerebral aneurysms: Evaluation of 66 consecutive cases with use of diffusion-weighted MR imaging. *AJNR Am J Neuroradiol*. 2003;24:127–132.
21. Hahnel S, Schellinger PD, Gutschalk A, Geletneky K, Hartmann M, Knauth M, Sartor K. Local intra-arterial fibrinolysis of thromboemboli occurring during neuroendovascular procedures with recombinant tissue plasminogen activator. *Stroke*. 2003;34:1723–1728.
22. Molyneux A, Kerr R, Stratton I, Sandercock P, Clarke M, Shrimpton J, Holman R. International Subarachnoid Aneurysm Trial (ISAT) of neurosurgical clipping versus endovascular coiling in 2143 patients with ruptured intracranial aneurysms: A randomised trial. *Lancet*. 2002;360: 1267–1274.
23. Ng PP, Phatouros CC, Khangure MS. Use of glycoprotein IIb-IIIa inhibitor for a thromboembolic complication during Guglielmi detachable coil treatment of an acutely ruptured aneurysm. *AJNR Am J Neuroradiol*. 2001;22:1761–1763.
24. Mounayer C, Piotin M, Baldi S, Spelle L, Moret J. Intraarterial administration of abciximab for thromboembolic events occurring during aneurysm coil placement. *AJNR Am J Neuroradiol*. 2003;24:2039–2043.
25. Song JK, Niimi Y, Fernandez PM, Brisman JL, Buciu R, Kupersmith MJ, Berenstein A. Thrombus formation during intracranial aneurysm coil placement: Treatment with intra-arterial abciximab. *AJNR Am J Neuroradiol*. 2004;25:1147–1153.
26. Roy D, Milot G, Raymond J. Endovascular treatment of unruptured aneurysms. *Stroke*. 2001;32:1998–2004.
27. Doerfler A, Wanke I, Egelhof T, Dietrich U, Asgari S, Stolke D, Forsting M. Aneurysmal rupture during embolization with Guglielmi detachable coils: Causes, management, and outcome. *AJNR Am J Neuroradiol*. 2001;22:1825–1832.
28. McDougall CG, Halbach VV, Dowd CF, Higashida RT, Larsen DW, Hieshima GB. Causes and management of aneurysmal hemorrhage occurring during embolization with Guglielmi detachable coils. *J Neurosurg*. 1998;89:87–92.
29. Tummala RP, Chu RM, Madison MT, Myers M, Tubman D, Nussbaum ES. Outcomes after aneurysm rupture during endovascular coil embolization. *Neurosurgery*. 2001;49:1059–1066; discussion 1066–1057.
30. Sluzewski M, Bosch JA, van Rooij WJ, Nijssen PC, Wijnalda D. Rupture of intracranial aneurysms during treatment with Guglielmi detachable coils: Incidence, outcome, and risk factors. *J Neurosurg*. 2001;94: 238–240.
31. Bendok BR, Hanel RA, Hopkins LN. Coil embolization of intracranial aneurysms. *Neurosurgery*. 2003;52:1125–1130; discussion 1130.

**Intravenous Administration of Acetylsalicylic Acid During Endovascular Treatment of Cerebral Aneurysms Reduces the Rate of Thromboembolic Events**  
Thorsten Ries, Jan-Hendrik Buhk, Thomas Kucinski, Einar Goebell, Ulrich Grzyska, Hermann Zeumer and Jens Fiehler

*Stroke*. 2006;37:1816-1821; originally published online June 15, 2006;

doi: 10.1161/01.STR.0000226933.44962.a6

*Stroke* is published by the American Heart Association, 7272 Greenville Avenue, Dallas, TX 75231

Copyright © 2006 American Heart Association, Inc. All rights reserved.

Print ISSN: 0039-2499. Online ISSN: 1524-4628

The online version of this article, along with updated information and services, is located on the World Wide Web at:

<http://stroke.ahajournals.org/content/37/7/1816>

**Permissions:** Requests for permissions to reproduce figures, tables, or portions of articles originally published in *Stroke* can be obtained via RightsLink, a service of the Copyright Clearance Center, not the Editorial Office. Once the online version of the published article for which permission is being requested is located, click Request Permissions in the middle column of the Web page under Services. Further information about this process is available in the [Permissions and Rights Question and Answer](#) document.

**Reprints:** Information about reprints can be found online at:  
<http://www.lww.com/reprints>

**Subscriptions:** Information about subscribing to *Stroke* is online at:  
<http://stroke.ahajournals.org/subscriptions/>