

Long-term Follow-up of Infrared Coagulator Ablation of Anal High-Grade Dysplasia in Men Who Have Sex With Men

Robert N. Goldstone, M.D. • Andrew B. Goldstone, M.D. • James Russ, B.A.
Stephen E. Goldstone, M.D.

Department of Surgery, Mount Sinai School of Medicine, New York, New York

BACKGROUND: We previously reported on infrared coagulator ablation of anal high-grade intraepithelial squamous lesions in HIV-positive and HIV-negative men who have sex with men (MSM) with a median follow-up of 1.5 years.

OBJECTIVE: We sought to determine high-grade intraepithelial squamous lesion recurrence rates after long-term follow-up for infrared coagulator ablation, and whether patients progressed to invasive cancer.

DESIGN: This study investigated a retrospective cohort.

SETTING: This study was set in an office-based practice.

PATIENTS: The patients evaluated were MSM who underwent at least 1 infrared coagulator anal high-grade intraepithelial squamous lesion ablation between 1999 and 2005 with at least 1-year additional follow-up.

INTERVENTION: Infrared coagulator ablation had been performed.

MAIN OUTCOME MEASUREMENT: The primary outcomes measured were high-grade intraepithelial squamous lesion recurrence and progression to anal squamous-cell carcinoma.

Financial Disclosures: No conflicts of interest exist for Robert N. Goldstone, Andrew B. Goldstone, and James Russ. Stephen E. Goldstone received Teflon tips for the infrared coagulator from Redfield Corporation early on when the cohort was first treated.

Poster presentation at the meeting of The American Society for Colon and Rectal Surgeons, Minneapolis, MN, May 15 to 19, 2010.

Correspondence: Stephen E. Goldstone, M.D., 420 West 23rd St, New York, NY 10011. E-mail: SEGMD@prodigy.net

Dis Colon Rectum 2011; 54: 1284–1292
DOI: 10.1097/DCR.0b013e318227833e
©The ASCRS 2011

RESULTS: Ninety-six MSM were included (44 HIV-positive) with a median follow-up of 48 and 69 months in HIV-negative and HIV-positive MSM. Thirty-five percent of HIV-positive and 31% of HIV-negative subjects from the original cohort were lost to follow-up. In HIV-negative MSM, 32 (62%) had a recurrence in a mean of 14 months. Recurrence rates after the second and third treatments were 48% and 57%. In HIV-positive MSM, 40 (91%) had a recurrence in a mean of 17 months. Recurrence rates after the second, third, and fourth infrared coagulator ablations were 63%, 85%, and 47%. After the first ablation, HIV-positive MSM were 1.9 times more likely to have a recurrence than HIV-negative MSM ($P = .009$). One year after the first ablation, 61% of HIV-positive MSM had recurrent high-grade intraepithelial squamous lesions in comparison with 38% of HIV-negative MSM. One year after the second ablation, 49% of HIV-positive MSM had recurrent high-grade intraepithelial squamous lesions in comparison with 28% of HIV-negative MSM. In HIV-negative and HIV-positive MSM, the probability of curing an individual lesion after first ablation was 80% and 67%. Most recurrence was due to the development of metachronous lesions occurring in 82% and 52% of HIV-positive and HIV-negative subjects after their first infrared coagulator treatment. The mean number of recurrent lesions for both HIV-positive and HIV-negative MSM was never >2 . No MSM developed squamous-cell carcinoma, and there were no serious adverse events. At last visit, 82% of HIV-positive MSM and 90% of HIV-negative MSM were high-grade intraepithelial squamous lesion free.

LIMITATIONS: This was a retrospective, observational study with significant loss to follow-up.

CONCLUSIONS: Infrared coagulator ablation is an effective treatment for high-grade intraepithelial squamous lesions, and no patients progressed to cancer.

HIV-positive patients are significantly more likely to have a recurrence, and recurrence occurred more rapidly in these patients. Continued follow-up is important.

KEY WORDS: High-grade squamous intraepithelial lesion; Infrared coagulator ablation; HIV; Anal dysplasia.

Although anal squamous-cell carcinoma (SCC) is a relatively rare cancer, its incidence, particularly in men who have sex with men (MSM), has continued to rise.¹ One recent series reported anal cancer rates of 69 and 14 per 100,000 for HIV-positive and HIV-negative MSM in a multicenter AIDS cohort study, and highly active antiretroviral therapy did not decrease the risk.²

The paradigm for developing anal SCC mimics that of cervical cancer. Both carcinomas are believed to develop secondary to infection with oncogenic human papillomavirus (HPV), most commonly HPV 16 and 18.³ The integration of the viral genome into epithelial cell DNA promotes malignant transformation, with progression from normal epithelium, to dysplasia, to invasive carcinoma.⁴ Dysplasia may be detected in both the cervix and anus through cytologic examination of epithelial cells obtained via cervical or anal Papanicolaou smear.⁵ In fact, anal cytology and high-resolution anoscopy (HRA) have detected high-grade squamous intraepithelial lesions (HSILs) in up to 52% of HIV-positive MSM.⁶

Intraepithelial neoplasia, in particular, HSIL, is believed to be the precursor for both cervical and anal SCC.⁷ Removal or eradication of HSIL reduces the incidence of invasive cervical cancer and may reduce the incidence of invasive anal cancer.⁸⁻¹¹ Cervical HSIL is treated through partial or complete excision of the squamocolumnar transition zone by a variety of procedures, including loop electrosurgical excision, cone biopsy, or surgical excision.¹² Although the anal squamocolumnar transition zone histopathologically resembles that of the cervix,¹³ it is not amenable to complete excision secondary to high risk of anal stenosis, abscess formation, anal spasm, and dyschezia.^{14,15} Instead, early management of anal HSIL has largely centered around local ablation of individual lesions with a laser, cryotherapy, or electrocautery.¹⁵⁻¹⁹

Before 2005, only one study had evaluated the efficacy of surgical ablation of HSIL with electrocautery in 37 patients.²⁰ Reported recurrence rates in HIV-positive and HIV-negative subjects were 79% and 0%, although follow-up time was short and patients did not undergo reoperation. While surgical ablation was well-tolerated, in general, approximately half of the subjects experienced significant postoperative pain for a mean duration of 2.9 weeks. In an effort to more effectively treat HSIL, we developed a technique of in-office ablation with the infrared coagulator (IRC) (Redfield IRC 2100; Redfield Corporation, Rochelle Park, NJ) after administration of local anes-

thesia.¹¹ We have previously reported the short-term efficacy of this procedure in both HIV-positive and HIV-negative patients who were followed up for a median of 18 months and 19 months after their first IRC ablation, where we achieved a per-individual lesion ablation success rate of 72% in HIV-positive and 81% in HIV-negative MSM.^{11,21} Metachronous lesions (lesions at a location other than the prior treatment site) were a major cause for recurrence. After a first and second IRC ablation of HSIL, 59% and 45% of HIV-positive MSM and 45% and 22% of HIV-negative MSM developed a metachronous lesion. Median time to any recurrence in HIV-positive and HIV-negative MSM after a first IRC was 7 and 11 months. No subjects progressed to SCC.

Pineda et al¹⁰ published results of their 10 years of experience treating HSIL in 246 patients in the operating room with standard surgery combined with in-office IRC ablation. They reported a 57% recurrence rate at a mean of 19 months (similar for both HIV-positive and HIV-negative subjects) and 1.2% progressed to SCC. At last follow-up, 78% were HSIL free. Here, we report a long-term follow-up of our original cohort with repeat in-office IRC ablation of biopsy-proven HSIL. It was our goal to determine whether recurrence rates, including both metachronous and persistent lesions, decreased with time. We also wanted to see whether treatment results differed between HIV-positive and HIV-negative patients and if patients progressed to invasive anal cancer.

MATERIALS AND METHODS

Identification of Subjects

With institutional review board approval from Essex Investigational Review Board and in accordance with Health Insurance Portability and Accountability Act regulations, we performed a retrospective chart review of all MSM patients who were included in the original study cohorts and underwent at least one IRC ablation of biopsy-proven intra-anal HSIL between 1999 and 2005.^{11,21} In the original study, subjects were included who had at least 6 months follow-up and were excluded if they were treated with an experimental therapeutic HPV vaccine, had extensive disease not amenable to local ablation, or demonstrated lack of follow-up. In this study, all subjects from the original cohorts were included as long as they had ≥ 1 year of additional follow-up. Data abstracted from patient charts included patient demographics, HIV status, dates and location of HSIL, and dates of IRC.

Identification and Management of HSIL

The standard procedure for detection and management of HSIL is similar to that reported in our previous studies.^{11,21} In brief, all subjects had a specimen for liquid-based anal cytology obtained with a wetted Dacron swab in

accordance with standard technique.²² Following anal cytology sampling, a digital rectal examination and standard anoscopy were performed. HRA, as described by Jay et al,²³ was completed for all MSM with abnormal anal cytology reported as atypical squamous cells of undetermined significance, atypical squamous cells—cannot exclude HSIL, low-grade squamous intraepithelial neoplasia, or HSIL, or those in whom a lesion was visualized with standard anoscopy. Lesions suspicious for HSIL were photographed, biopsied, and immediately fixed in 10% formalin solution. All cytology and pathology specimens were sent to Enzo Clinical Laboratories (Farmingdale, NY) or Quest Diagnostics (Teterboro, NJ), and the results were reported in accordance with the Bethesda system.²⁴ MSM with localized, intra-anal, biopsy-proven HSIL were treated with in-office IRC ablation after infiltration of local anesthetic by the technique previously reported.¹¹ Each lesion was identified, infiltrated with local anesthesia, and repeatedly coagulated with the IRC in 1.5-second pulses. The eschar was removed, and the process was repeated until the submucosal vessels were coagulated. All high-grade lesions present were treated at the time of ablation. All procedures were performed by a surgeon (S.G.) or a nurse practitioner experienced in HRA and IRC ablation.

Patients received routine evaluations with digital rectal examination and standard anoscopy at 3- to 6-month intervals after IRC. At 6-month intervals, we obtained anal cytology, and those with abnormalities on cytology or standard anoscopy had HRA. Patients with biopsy-proven HSIL were offered repeat IRC ablation. All patients with benign cytology or no evidence of HSIL on HRA continued follow-up.

Study Definitions

Treatment success was defined as a patient with benign cytology or no evidence of HSIL on HRA after ablation. Recurrence was classified as a patient who had cytologic or biopsy-proven HSIL. Recurrence at anytime in the same location as the previous HSIL was considered a persistent lesion, whereas recurrence in a new location was considered a metachronous lesion. Time to recurrence was the time elapsed from IRC ablation to the date of HSIL diagnosis.

Statistical Analysis

Statistical analyses were performed with SAS Version 9.2 (SAS Institute Inc., Cary, NC). χ^2 tests were used to compare proportions, and Student *t* tests were used to compare means. Probabilities of recurrence were estimated using the Kaplan-Meier product limit method with comparison between groups evaluated by the log-rank statistic. The Cox proportional hazards model was used to estimate hazard ratios (equivalent of relative risks adjusted for follow-up time) and 95% confidence intervals. In addition, general estimating equations were used to determine

whether recurrence and persistence rates diminished over time following continued IRC treatment. In these general estimating equation models a Poisson distribution was assumed with a compound symmetric covariance structure where the dependent variable was the number of recurrent HSIL lesions (or the number of persistent HSIL lesions), and the offset was the natural log of the total patient days followed after each IRC treatment (or the natural log of the total lesion days followed).

RESULTS

From the original cohort of 68 HIV-positive and 75 HIV-negative MSM, 44 (65%) HIV-positive and 52 (69%) HIV-negative MSM had at least one additional year of follow-up and were included in this analysis. Thirty-five percent of HIV-positive and 31% of HIV-negative subjects from the original cohort were unavailable for analysis because they were lost to follow-up. The clinical characteristics and details of follow-up are listed in Table 1. For the HIV-positive cohort, the median age at study inclusion was 41.5 years, with a median follow-up from first IRC ablation of 69 months, and 75% had >3 years of follow-up, and 57% had ≥ 5 years of follow-up. For the HIV-negative cohort, the median age at study inclusion was 35.9 years, with a median follow-up from first IRC ablation of 48 months, and 52% had >3 years of follow-up, and 27% had ≥ 5 years of follow-up. Ninety percent of HIV-positive MSM received their first IRC within 55 days of HSIL diagnosis, and 90% of HIV-negative MSM received their first IRC within 64 days of HSIL diagnosis.

HSIL Recurrence After IRC

Table 2 describes HSIL recurrence rates for both HIV-positive and HIV-negative MSM. After the first IRC ablation, a greater number of both HIV-positive and HIV-negative

TABLE 1. Clinical features

	HIV-positive subjects	HIV-negative subjects
No. of subjects	44	52
Median age at inclusion, years (range)	41.5 (28.9–62.4)	35.9 (22.7–71.8)
Mean number of lesions treated at first IRC (range)	1.6 (1–5)	1.5 (1–3)
Median follow-up from first IRC; months (range)	69 (12–102)	48 (13–87)
Median days from HSIL diagnosis to		
First IRC	23	25
Second IRC	28	23
Third IRC	15	28

HSIL = high-grade squamous intraepithelial lesion; IRC = infrared coagulator.

TABLE 2. Recurrence of HSIL after IRC ablation

	HIV-positive subjects		HIV-negative subjects	
	Recurrence n (%)	No recurrence n (%)	Recurrence n (%)	No recurrence n (%)
After first IRC ablation				
No. of patients	40 (91)	4 (9)	32 (62)	20 (38)
Mean months after first IRC (range) ^a	17 (4–99)	35 (25–46)	14 (2–46)	48 (12–75)
Mean number of lesions (range)	1.9 (1–4)	0	1.6 (1–4)	0
After second IRC ablation				
No. of patients ^b	22 (63)	13 (37)	12 (48)	13 (52)
Mean months after second IRC (range) ^a	10 (2–31)	44 (7–92)	14 (5–47)	41 (8–77)
Mean number of lesions (range)	1.5 (1–2)	0	1.2 (1–2)	0
After third IRC ablation				
No. of patients ^c	17 (85)	3 (15)	4 (57)	3 (43)
Mean months after third IRC (range) ^a	18 (2–81)	47 (27–68)	8 (4–17)	34 (2–57)
Mean number of lesions (range)	1.5 (1–4)	0	1.5 (1–2)	0
After fourth IRC ablation^d				
No. of patients	7 (47)	8 (53)		
Mean months after fourth IRC (range) ^a	24 (4–60)	21 (5–47)		
Mean number of lesions (range)	1.3 (1–3)	0		

HSIL = high-grade squamous intraepithelial lesion; IRC = infrared coagulator.

^aFor those who had a recurrence, this is the number of months from IRC treatment to the time of new HSIL(s), and for those who did not have a recurrence it is the follow-up time in months to their last visit.

^bFive of the 40 HIV-positive patients did not have their HSIL treated with IRC. Six of the 32 HIV-negative patients did not have their HSIL treated with IRC, and 1 of the 32 patients had his first recurrence on his last visit and thus could not be followed up for further recurrence.

^cOne of the 22 HIV-positive patients did not have their second recurrence treated with IRC. Another 1 of the 22 patients had their last IRC on their last visit. Five of the 12 HIV-negative patients did not have their second recurrence treated with IRC.

^dTwo of the 17 HIV-positive patients did not have their third recurrence treated with IRC. No HIV-negative patients received a fourth IRC ablation.

MSM had recurrences than did not. Forty (91%) HIV-positive MSM had recurrences after the first ablation with a mean of 1.9 lesions over a mean of 17 (range, 4–99) months, whereas 4 (9%) patients did not have a recurrence over a mean of 36 (range, 25–46) months. For HIV-negative MSM, 32 (62%) subjects had recurrences after the first IRC ablation, with a mean of 1.7 lesions over a mean of 14 (range 2–46) months, whereas 20 (38%) did not have a recurrence over a mean time of 48 (range 12–75) months. The mean number of recurrent lesions for both HIV-positive and HIV-negative MSM was never greater than 2. HSIL recurrence rates significantly decreased with continued IRC ablation for HIV-positive MSM ($P = .009$), but not for HIV-negative subjects ($P = .52$). It is interesting that the number of HSIL lesions treated was not found to significantly affect recurrence by proportional hazards analysis ($P > .05$; data not shown).

Table 3 lists the incidence of metachronous lesions following each individual IRC ablation in both HIV-positive and HIV-negative MSM. Of the 44 initially treated HIV-positive subjects, 36 (82%) developed metachronous HSILs over a mean of 17 (range, 4–99) months after ablation. After the second and third IRC treatments, 16 (46%) and 15 (75%) patients developed metachronous lesions over a mean of 9 (range, 2–31) months and 18 (range 2–81) months. For HIV-negative MSM, 27 (52%) subjects developed metachronous lesions over a mean of 13 (range, 2–46) months. After the second and third IRC treatments,

12 (48%) and 3 (43%) subjects developed metachronous lesions over a mean of 14 (range, 5–47) months and 10 (range, 4–17) months.

HSIL persistence after treatment in HIV-positive and HIV-negative MSM is shown in Table 4. Following treatment, persistent HSILs were identified in 27 (61%) HIV-positive MSM. Of a total of 147 HSIL lesions initially treated, only 48 persisted, with a probability that a single lesion was successfully ablated of 67%. The probability that a lesion was successfully ablated increased to 77% after the second ablation. Similarly, for the HIV-negative cohort, 18 (35%) MSM developed persistent HSILs. Of 112 HSILs treated, 22 persisted, with a probability of ablating a single lesion of 80%. The probability of ablating an individual lesion increased to 82% after the second ablation.

No patients developed serious adverse events following IRC ablation, including no anal stricture formation, persistent bleeding, significant postoperative hemorrhage, failure to heal, or infection requiring antibiotic therapy. Pain was the most common postprocedure concern, and was adequately controlled by, at most, mild narcotic analgesia. Importantly, no patient developed anal SCC during the study period.

Comparison of HSIL Recurrence Between HIV-Positive and HIV-Negative MSM

HSIL recurrence was significantly greater among HIV-positive than HIV-negative patients only after the first IRC

TABLE 3. Incidence of metachronous HSIL after each IRC ablation

	HIV-positive subjects		HIV-negative subjects	
	Metachronous n (%)	No metachronous n (%)	Metachronous n (%)	No metachronous n (%)
After first IRC ablation				
No. of patients	36 (82)	8 (18)	27 (52)	25 (48)
Mean months after first IRC (range) ^a	17 (4–99)	23 (7–46)	13 (2–46)	42 (6–75)
Mean number of lesions (range)	1.6 (1–3)	0	1.4 (1–3)	0
After second IRC ablation				
No. of patients ^b	16 (46)	19 (54)	12 (48)	13 (52)
Mean months after second IRC (range) ^a	9 (2–31)	34 (6–92)	14 (5–47)	41 (8–77)
Mean number of lesions (range)	1.1 (1–2)	0	1.1 (1–2)	0
After third IRC ablation				
No. of patients ^c	15 (75)	5 (25)	3 (43)	4 (57)
Mean months after third IRC (range) ^a	18 (2–81)	37 (8–68)	10 (4–17)	27 (4–57)
Mean number of lesions (range)	1.4 (1–3)	0	1.3 (1–2)	0
After fourth IRC ablation ^d				
No. of patients	6 (40)	9 (60)		
Mean months after fourth IRC (range)	27 (4–60)	19 (5–47)		
Mean number of lesions (range)	1.2 (1–2)	0		

The numbers of patients for each ablation do not necessarily equal the number of patients treated immediately before, because patients without metachronous lesions but who were retreated for a persistent lesion become eligible for follow-up for a potential metachronous recurrence going forward. Therefore, seemingly additional patients at subsequent ablations are those treated for persistent lesions.

HSIL = high-grade squamous intraepithelial lesion; IRC = infrared coagulator.

^aFor those who developed a metachronous lesion, this is the number of months from IRC to the time of new HSIL(s), and for those who did not develop a metachronous lesion, it is the follow-up time in months. For those who had a recurrence but did not have a metachronous lesion, this is still the number of months from IRC to the next new HSIL.

^bHIV-positive patients: Four of 36 patients with metachronous lesions were not retreated with IRC. Five of 8 patients without metachronous lesions remained HSIL free and cannot be followed up any further, leaving 35 patients to be followed up after their second IRC. HIV-negative patients: Six of 27 patients with metachronous lesions were not retreated with IRC. Twenty of 25 patients without metachronous lesions remained HSIL free and cannot be followed up any further. In addition, 1 patient was lost to follow-up after his IRC, leaving 25 patients to be followed up after their second IRC.

^cHIV-positive patients: One of 16 patients with metachronous lesions were not re-treated with IRC. Thirteen of 19 patients without metachronous lesions remained HSIL free and cannot be followed up any further. In addition, 1 patient was lost to follow-up, leaving 20 patients to be followed up after their third IRC. HIV-negative patients: Five of 12 patients with metachronous lesions were not re-treated with IRC. All 13 patients without metachronous lesions remained HSIL free and cannot be followed up further, leaving 7 patients to be followed up after their third IRC.

^dHIV-positive patients: Two of 15 patients with metachronous lesions were not re-treated with IRC. Three of 5 patients without metachronous lesions remained HSIL free and cannot be followed up any further, leaving 15 patients to be followed up after their fourth IRC. No HIV-negative patients received a fourth IRC ablation.

ablation (Fig. 1, $P = .008$). In fact, the median time to recurrence after the first IRC treatment for HIV-positive MSM (12 ± 1 month) was half the median time to recurrence for HIV-negative MSM (24 ± 6 months). On proportional hazards analysis, positive HIV status was found to be a significant predictor of recurrence after the first IRC ablation with a hazard ratio of 1.9 (95% CI: 1.2–3.0). Kaplan-Meier and proportional hazards analyses did not demonstrate significant differences in HSIL recurrence between HIV-positive and HIV-negative MSM after the second and third IRC treatments (Figs. 2 and 3). However, 1 year after the first ablation, 61% of HIV-positive MSM had recurrent HSILs compared with 38% of HIV negative MSM. One year after the second ablation, 49% of HIV-positive MSM had recurrent HSIL compared with 28% of HIV-negative MSM, and 1 year after the third ablation, 50% of HIV-positive MSM had recurrent HSIL compared with 46% of HIV-negative MSM. It is noteworthy that 82% of HIV-positive MSM and 90% of HIV-negative MSM were free of HSIL at the last visit.

DISCUSSION

Although studies have evaluated the short-term efficacy of IRC ablation of anal HSIL,^{11,14,21,25} this is the first study that reports on long-term follow-up in both HIV-positive and HIV-negative MSM. We now present approximately 5 years and 2.5 years longer follow-up for HIV-positive and HIV-negative MSM than in our initial report.

In the present study, we maintain that IRC ablation in both HIV-positive and HIV-negative MSM continues to serve as an effective method to manage anal HSIL. Importantly, no patients in this study progressed to anal SCC, which is the ultimate goal of surveillance and treatment of this high-risk population. Pineda et al¹⁰ reported a progression rate to SCC of 1.2% a mean of 29 months after surgery. Although no prospective, randomized trials exist on the expectant management of HSIL, retrospective studies demonstrate an 8.5% to 13% progression to SCC with expectant management.^{9,26,27} The effectiveness of IRC ablation in the management of anal HSIL is likely secondary

TABLE 4. Persistent HSIL after IRC ablation

	HIV-positive subjects		HIV-negative subjects	
	Persisted n (%)	Not persisted n (%)	Persisted n (%)	Not persisted n (%)
After first IRC ablation				
No. of patients	27 (61)	17 (39)	18 (35)	34 (65)
Mean months after first IRC (range)	19 (2–78)	52 (5–106)	16 (2–62)	46 (6–85)
No. of persistent lesions	48	99	22	N/A
Probability of lesion cured	67%	N/A	80%	N/A
After second IRC ablation^a				
No. of patients	6 (24)	19 (76)	2 (13)	13 (87)
Mean months after second IRC (range)	19 (6–55)	53 (7–92)	7 (7–9)	36 (8–69)
No. of persistent lesions	10	34	3	N/A
Probability of lesion cured	77%	N/A	82%	N/A
After third IRC ablation^b				
No. of patients	3 (60)	2 (40)		
Mean months after third IRC (range)	17 (7–34)	34 (6–55)		
No. of persistent lesions	3	6		
Probability of lesion cured	67%	N/A		

HSIL = high-grade squamous intraepithelial lesion; IRC = infrared coagulator; N/A = not applicable.

^aHIV-positive patients: Two of 27 patients that had persistent lesions did not have their lesion(s) treated with IRC, so they could not be followed up for further persistence.

HIV-negative patients: Three of 18 patients that had persistent lesions did not have their lesion(s) treated with IRC, so they could not be followed up for further persistence.

^bHIV-positive patients: One of 6 patients that had persistent lesions did not have their lesion(s) treated with IRC, so they could not be followed up for further persistence. HIV-negative patients: Neither of the 2 HIV-negative patients who had persistent lesions had their lesions treated with IRC.

to its very high individual lesion cure rate, in both HIV-positive and HIV-negative MSM. The probability of successful ablation of individual high-grade lesions was 67% and 77% after first and second IRC ablation in HIV-positive MSM, respectively, and 80% and 82% after first and second IRC ablation in HIV-negative MSM, respectively. These individual lesion cure rates in HIV-positive patients are similar to previously reported values of between 65% and 72%.^{11,14,25} Moreover, recurrence rates in HIV-positive women following loop electrosurgical excision of cervical dysplasia are over 55% despite clear margins.²⁸

Although the cure rates for individual lesions were relatively high regardless of HIV status, HSIL recurrence after first IRC ablation was significantly greater among HIV-positive patients than among HIV-negative patients. In fact, HIV-positive MSM were 1.9 times more likely to have a recurrence after the first IRC treatment. HIV-positive MSM had recurrences twice as quickly as HIV-negative MSM, with a median time to recurrence for HIV-positive MSM vs HIV-negative MSM of 12 ± 1 month vs 24 ± 6 months (*P* = .008). It is noteworthy, however, that this difference in HSIL recurrence by HIV status

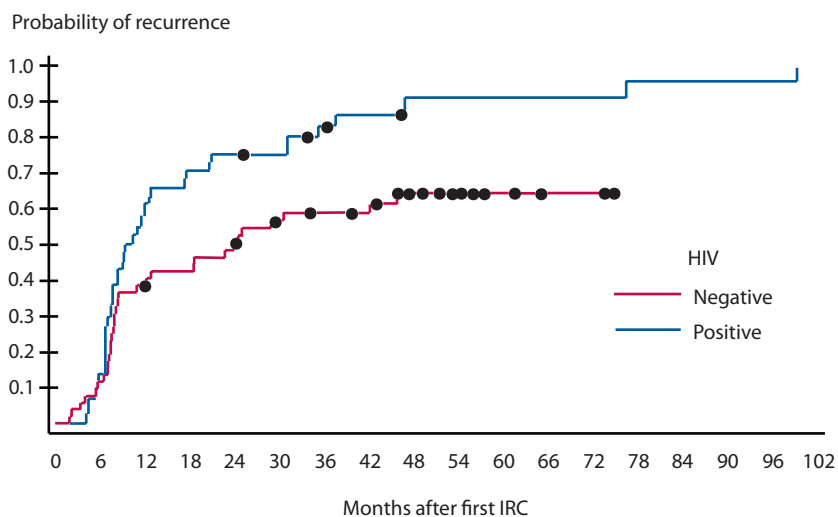


FIGURE 1. HSIL recurrence in HIV-positive MSM vs HIV-negative MSM after the first IRC ablation (*P* = .008). HSIL = high-grade squamous intraepithelial lesion; MSM = men who have sex with men; IRC = infrared coagulator.

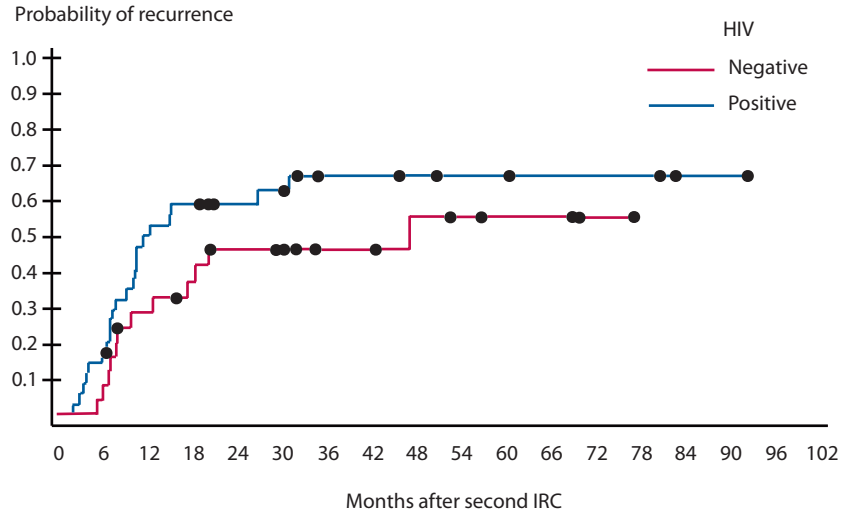


FIGURE 2. HSIL recurrence in HIV-positive MSM vs HIV-negative MSM after the second IRC ablation ($P = .18$). HSIL = high-grade squamous intraepithelial lesion; MSM = men who have sex with men; IRC = infrared coagulator.

after the first IRC treatment was not present after the second and third IRC treatments. The equilibration of the recurrence rates between the 2 cohorts may be secondary to the significant reduction in recurrence with each successive IRC treatment among HIV-positive MSM that was not observed among HIV-negative MSM. The reason for reduced recurrence with continued IRC treatment among HIV-positive and not among HIV-negative MSM is unclear and could be related to small sample size.

Although no patients developed anal SCC, the recurrence rates and incidence of metachronous lesions remained fairly high, even after the third and fourth IRC treatments. Even though IRC appears to be effective at eradication of individual lesions, the high rate of metachronous lesions indicates the need for continued surveil-

lance. Moreover, surveillance intervals should be guided by HIV status. We report that 50% of HIV-positive MSM will have a recurrence after each ablation within 1 year and that 50% of HIV-negative MSM will have a recurrence within 2 and 4 years after their first and second IRC ablations, respectively. Thus, HIV-positive MSM require shorter surveillance intervals than HIV-negative MSM.

Although we had previously hoped that continued IRC treatment might induce significant disease-free status, especially in HIV-negative individuals, complete cure now appears unlikely. In our original short-term follow-up study on HIV-negative MSM treated for HSIL with successive IRC ablation, success rates after the first, second, and third IRC treatment were 47%, 72%, and 100%.²¹ In the

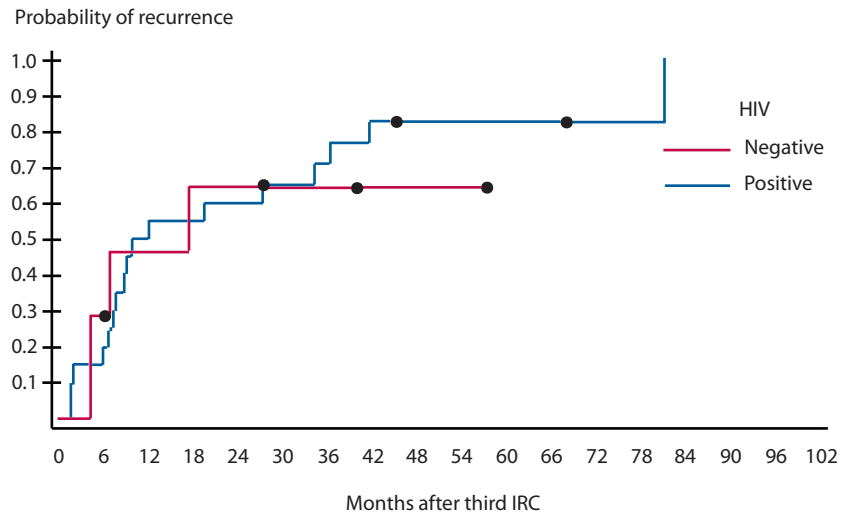


FIGURE 3. HSIL recurrence in HIV-positive MSM vs HIV-negative MSM after the third IRC ablation ($P = .76$). HSIL = high-grade squamous intraepithelial lesion; MSM = men who have sex with men; IRC = infrared coagulator.

present study, on the other hand, success rates after the first, second, and third IRC ablation in HIV-negative MSM were 38%, 52%, and 43%, which is no doubt related to the fact that increased follow-up time leads to ultimate recurrence. It is encouraging, however, that the cure rate of an individual lesion for the first and second IRC treatments with increased follow-up time has remained essentially unchanged. Furthermore, given the long duration of follow-up, it is possible that lesions categorized for this study as persistent were truly metachronous with recurrence in the same location as the index lesion. The prospect of complete disease eradication by continued local IRC treatment, however, does not appear probable and could be related to frequent HPV reinfection or reactivation over time. As a prior report suggested, testing for oncogenic HPV infection may ultimately be a better predictor of disease-free survival.²⁹ In addition to the long-term series of Pineda et al,¹⁰ 2 other series reported on IRC ablation of HSIL. Cranston et al²⁵ reported an individual lesion cure rate in 68 HIV-positive patients after a mean of 140 days follow-up of 64%. In a small prospective series of 18 HIV-positive patients, Stier et al¹⁴ reported a lesion cure rate of 66% at 3 months. Our results are clearly consistent with the literature.

Our study has a number of potential limitations. First, this was a retrospective study, and results may not be identical if a prospective study with longer follow-up is performed. Second, although HRA remains the standard for detection of anal dysplasia, it is by no means perfect, and lesions may not have been detected, leading to an underestimation of recurrence rates. Third, the study was performed only on male patients, and these data may not be applicable to other populations. Furthermore, we only performed IRC ablation on biopsy-proven HSIL, and expectant management of HSIL that was not confirmed by biopsy may have led to increased recurrence rates. Patients with benign cytology and negative standard anoscopy did not undergo HRA and were scored as a nonrecurrence, which could underestimate true recurrence rates. Moreover, it should be noted that patients were excluded from this study if they had extensive disease that was not amenable to in-office IRC ablation. Thus, our results may not be generalized to patients with extensive disease burden. Another limitation of our study relates to the relatively small number of subjects who completed successive ablations. A large number of subjects were lost to follow-up, reducing our study sample size, and may have limited our ability to discern the true difference in HSIL recurrence following second and third IRC treatments between HIV-negative and HIV-positive subjects. And last, although we are encouraged that 82% of HIV-positive MSM and 90% of HIV-negative MSM were HSIL free at their last visit, the fact remains that over 30% of subjects from the original cohort were not eligible for analysis because they were lost to follow-up.

CONCLUSIONS

IRC ablation is an effective treatment modality for the management of HSIL in both HIV-positive and HIV-negative MSM. HIV-positive patients are significantly more likely to have recurrences, and to have recurrences at much more rapid rates, than HIV-negative MSM. Continued surveillance is necessary because recurrence rates, largely from the development of metachronous lesions, remain high. Future prospective treatment studies are indicated.

ACKNOWLEDGMENTS

The authors thank the pathologists at Enzo Clinical Laboratories (Farmingdale, NY) and Quest Diagnostics (Teterboro, NJ) for their time and guidance with the pathology and cytology. We also thank Erin Moshier for her help with statistical analysis.

REFERENCES

1. Chin-Hong PV, Palefsky JM. Natural history and clinical management of anal human papillomavirus disease in men and women infected with human immunodeficiency virus. *Clin Infect Dis*. 2002;35:1127–1134.
2. D'Souza G, Wiley DJ, Li X, et al. Incidence and epidemiology of anal cancer in the multicenter AIDS cohort study. *J Acquir Immune Defic Syndr*. 2008;48:491–499.
3. Schiffman M, Kjaer SK. Chapter 2: Natural history of anogenital human papillomavirus infection and neoplasia. *J Natl Cancer Inst Monogr*. 2003;14–19.
4. Zbar AP, Fenger C, Efron J, Beer-Gabel M, Wexner SD. The pathology and molecular biology of anal intraepithelial neoplasia: comparisons with cervical and vulvar intraepithelial carcinoma. *Int J Colorectal Dis*. 2002;17:203–215.
5. Palefsky JM, Holly EA, Hogeboom CJ, Berry JM, Jay N, Darragh TM. Anal cytology as a screening tool for anal squamous intraepithelial lesions. *J Acquir Immune Defic Syndr Hum Retrovirol*. 1997;14:415–422.
6. Palefsky JM, Holly EA, Efron JT, et al. Anal intraepithelial neoplasia in the highly active antiretroviral therapy era among HIV-positive men who have sex with men. *AIDS*. 2005;19:1407–1414.
7. Gervaz P, Hahnloser D, Wolff BG, et al. Molecular biology of squamous cell carcinoma of the anus: a comparison of HIV-positive and HIV-negative patients. *J Gastrointest Surg*. 2004;8:1024–1031.
8. Apgar BS, Kittendorf AL, Bettcher CM, et al. Update on ASCCP consensus guidelines for abnormal cervical screening tests and cervical histology. *Am Fam Physician*. 2009;80:147–155.
9. Devaraj B, Cosman BC. Expectant management of anal squamous dysplasia in patients with HIV. *Dis Colon Rectum*. 2006;49:36–40.
10. Pineda CE, Berry JM, Jay N, Palefsky JM, Welton ML. High-resolution anoscopy targeted surgical destruction of anal high-grade squamous intraepithelial lesions: a ten-year experience. *Dis Colon Rectum*. 2008;51:829–837.
11. Goldstone SE, Kawalek AZ, Huyett JW. Infrared coagulator: a useful tool for treating anal squamous intraepithelial lesions. *Dis Colon Rectum*. 2005;48:1042–1054.

12. Tate DR, Anderson RJ. Recrudescence of cervical dysplasia among women who are infected with the human immunodeficiency virus: a case-control analysis. *Am J Obstet Gynecol.* 2002;186:880–882.
13. Litle VR, Leavenworth JD, Darragh TM, et al. Angiogenesis, proliferation, and apoptosis in anal high-grade squamous intraepithelial lesions. *Dis Colon Rectum.* 2000;43:346–352.
14. Stier EA, Goldstone SE, Berry JM, et al. Infrared coagulator treatment of high-grade anal dysplasia in HIV-infected individuals: an AIDS malignancy consortium pilot study. *J Acquir Immune Defic Syndr.* 2008;47:56–61.
15. Scholefield JH, Ogunbiyi OA, Smith JH, Rogers K, Sharp F. Treatment of anal intraepithelial neoplasia. *Br J Surg.* 1994;81:1238–1240.
16. Lyons M, Francis N, Allen-Mersh TG. Treatment of grade 3 anal intraepithelial neoplasia by complete anal mucosal excision without fecal diversion: report of a case. *Dis Colon Rectum.* 1999;42:1342–1344.
17. Pehoushek J, Smith KJ. Imiquimod and 5% fluorouracil therapy for anal and perianal squamous cell carcinoma in situ in an HIV-1-positive man. *Arch Dermatol.* 2001;137:14–16.
18. Hamdan KA, Tait IS, Nadeau V, Padgett M, Carey F, Steele RJ. Treatment of grade III anal intraepithelial neoplasia with photodynamic therapy: report of a case. *Dis Colon Rectum.* 2003;46:1555–1559.
19. Lacey CJ. Therapy for genital human papillomavirus-related disease. *J Clin Virol.* 2005;32(suppl 1):S82–S90.
20. Chang GJ, Berry JM, Jay N, Palefsky JM, Welton ML. Surgical treatment of high-grade anal squamous intraepithelial lesions: a prospective study. *Dis Colon Rectum.* 2002;45:453–458.
21. Goldstone SE, Hundert JS, Huyett JW. Infrared coagulator ablation of high-grade anal squamous intraepithelial lesions in HIV-negative males who have sex with males. *Dis Colon Rectum.* 2007;50:565–575.
22. Goldstone SE, Winkler B, Ufford LJ, Alt E, Palefsky JM. High prevalence of anal squamous intraepithelial lesions and squamous-cell carcinoma in men who have sex with men as seen in a surgical practice. *Dis Colon Rectum.* 2001;44:690–698.
23. Jay N, Berry JM, Hogeboom CJ, Holly EA, Darragh TM, Palefsky JM. Colposcopic appearance of anal squamous intraepithelial lesions: relationship to histopathology. *Dis Colon Rectum.* 1997;40:919–928.
24. Darragh TM, Birdsong GG, Luff RD, Davey DD. Anal-rectal cytology. In: Solomon D, Nayar R, eds. *The Bethesda System for Reporting Cervical Cytology: Definitions, Criteria, and Explanatory Notes.* 2nd ed. New York, NY: Springer-Verlag; 2004:169–175.
25. Cranston RD, Hirschowitz SL, Cortina G, Moe AA. A retrospective clinical study of the treatment of high-grade anal dysplasia by infrared coagulation in a population of HIV-positive men who have sex with men. *Int J STD AIDS.* 2008;19:118–120.
26. Scholefield JH, Castle MT, Watson NF. Malignant transformation of high-grade anal intraepithelial neoplasia. *Br J Surg.* 2005;92:1133–1136.
27. Watson AJ, Smith BB, Whitehead MR, Sykes PH, Frizelle FA. Malignant progression of anal intra-epithelial neoplasia. *ANZ J Surg.* 2006;76:715–717.
28. Shah S, Montgomery H, Crow JC, et al. Cervical intraepithelial neoplasia treatment in HIV-positive women. *J Obstet Gynaecol.* 2008;28:327–332.
29. Goldstone SE, Moshier E. Detection of oncogenic human papillomavirus impacts anal screening guidelines in men who have sex with men. *Dis Colon Rectum* 2010;53:1135–1142.