

# Long-term Treatment of Primary Sclerosing Cholangitis in Children With Oral Vancomycin: An Immunomodulating Antibiotic

\*Yinka K. Davies, \*Kathleen M. Cox, †Bisher A. Abdullah, §Anca Safta, ‡Annie B. Terry, and \*Kenneth L. Cox

Departments of Pediatrics, \*Lucile Packard Children's Hospital, Stanford University, Palo Alto, CA, †Mary Bridge Children's Hospital, Tacoma, WA, ‡Oregon Health Sciences University, Portland, and §Division of Pediatric Gastroenterology and Hepatology, University of Maryland Hospital for Children, Baltimore

## ABSTRACT

**Background:** Primary sclerosing cholangitis is a rare chronic cholestatic condition of unknown etiology, frequently associated with inflammatory bowel disease and characterized by diffuse fibrosing and inflammatory destruction of the intra- and/or extrahepatic biliary duct system.

**Patients and Methods:** The study involved 14 children with primary sclerosing cholangitis confirmed by either liver biopsy, endoscopic retrograde cholangiopancreatography, and/or magnetic resonance cholangiogram. In each of the 14 cases, liver histology showed characteristic features consistent with primary sclerosing cholangitis. Eleven children had intrahepatic biliary beading and strictures (6 by endoscopic retrograde cholangiopancreatography; 5 by magnetic resonance cholangiogram). Biochemical tests of liver function including alanine aminotransferase, aspartate aminotransferase, and  $\gamma$ -glutamyl transpeptidase and the erythrocyte sedimentation rate were elevated for a mean  $17 \pm 22$  months before vancomycin treatment was initiated. All of the patients were shown to have inflammatory bowel disease histologically; 13 of those patients had clinical

evidence of colitis. Oral vancomycin was given to all 14 patients.

**Results:** All 14 patients showed improvement in their alanine aminotransferase ( $P=0.007$ ),  $\gamma$ -glutamyl transpeptidase ( $P=0.005$ ), erythrocyte sedimentation rate ( $P=0.008$ ), and clinical symptoms with oral vancomycin treatment. There was less improvement noted in the patients with cirrhosis when compared with the patients without cirrhosis.

**Conclusions:** Before this study, there has not been an effective long-term treatment for sclerosing cholangitis to prevent the usual progression of this disease to cirrhosis. This study showed that oral vancomycin could be an effective long-term treatment of sclerosing cholangitis in children, especially those without cirrhosis. *JPGN* 47:61–67, 2008. **Key Words:** Primary sclerosing cholangitis—Inflammatory bowel disease—Colitis—Vancomycin—Autoantibodies—Fibrosis—Tumor necrosis factor. © 2008 by European Society for Pediatric Gastroenterology, Hepatology, and Nutrition and North American Society for Pediatric Gastroenterology, Hepatology, and Nutrition

Primary sclerosing cholangitis is a chronic disease of unknown cause characterized by patchy progressive inflammation of the biliary tree resulting in destruction and fibrosis (1,2). Disease progression, although variable, is almost universal in all patients, resulting in a loss of intrahepatic bile ducts leading to biliary cirrhosis and eventually liver failure (3,4).

Previously considered rare, the prevalence of primary sclerosing cholangitis has increased as a result of screen-

ing patients with inflammatory bowel disease for abnormal liver function tests (5). The close association between primary sclerosing cholangitis and inflammatory bowel disease has been well established (6). Fifty percent to 75% of patients with primary sclerosing cholangitis have inflammatory bowel disease, particularly ulcerative colitis (5). The course of the biliary disease is unrelated to the clinical course of the colitis.

There is increasing evidence that immune mechanisms play an essential role in the pathogenesis of primary sclerosing cholangitis. It has yet to be established whether the immune cascade is the cause or consequence of the bile duct injury (7). There are potential nonimmune mechanisms that play a role in the pathogenesis of the sclerosing disease (8–10). These include a toxic

Received January 14, 2007; accepted January 5, 2008.

Address correspondence and reprint requests to Kenneth L. Cox, MD, Department of Pediatrics, Stanford University, 750 Welch Rd, Suite 116, Palo Alto, CA 94304.

The authors report no conflicts of interest.

agent, possibly liberated by gut bacteria or ischemic injury. There have been many trials of pharmacological agents, of which none have shown resolution in the effects of primary sclerosing cholangitis. Successful treatment likely has been limited by the uncertainty of the cause of the disease (11).

Cox and Cox (12) previously reported treatment with oral vancomycin in 3 children with primary sclerosing cholangitis and inflammatory bowel disease. This initial report demonstrated normalization of liver tests and resolution of symptoms in these children while taking oral vancomycin. However, all 3 children had recurrence of symptoms and abnormal laboratory findings after vancomycin was discontinued (12).

This article reviews our experience treating 14 children with primary sclerosing cholangitis and inflammatory bowel disease with oral vancomycin, demonstrating the short- and long-term clinical and laboratory responses. One case, which provided evidence of a more systemic immunomodulating effect of oral vancomycin on the liver, lungs, and gastrointestinal tract, is reviewed in more detail.

## PATIENTS AND METHODS

### Clinical Features

This was a prospective study of 14 consecutive children who were diagnosed with primary sclerosing cholangitis and inflammatory bowel disease. The mean age of our patients was  $12 \pm 4$  years ranging from 2 to 17 years. The male:female ratio in the present series was 2.3:1, which is comparable to the 2:1 male predominance that is observed in the adult population (5).

Fourteen patients with primary sclerosing cholangitis are described, in whom the diagnosis was confirmed by liver biopsy, endoscopic retrograde cholangiopancreatography (ERCP) and/or magnetic resonance cholangiogram. Liver for histological examination was obtained by percutaneous needle biopsy in all 14 patients. In each of the 14 cases, liver histology showed characteristic features of primary sclerosing cholangitis. There were no histological features suggestive of autoimmune hepatitis. Four patients (cases 2, 6, 8, and 9) had cirrhosis seen on biopsy before initiating oral vancomycin therapy. Eleven children had intrahepatic biliary beading and strictures on ERCP (cases 1, 2, 5, 9, 14, and 12) or magnetic resonance cholangiogram (cases 4, 7, 8, 10, 12, and 14). Biochemical tests of liver function (including alanine aminotransferase, aspartate aminotransferase, and  $\gamma$ -glutamyl transpeptidase) and the erythrocyte sedimentation rate (ESR) were elevated for a mean of  $17 \pm 22$  months, ranging from 1 to 69 months, before initiating vancomycin treatment.

All of the patients were shown to have inflammatory bowel disease histologically; 13 of the 14 patients (case 7 was the exception) had clinical evidence of colitis. Three patients (cases 2, 3, and 10) had Crohn disease involving the small bowel and colon. The other 11 patients had ulcerative colitis. Stool cultures for enteric pathogens and *Clostridium difficile* toxin were negative in 13 patients except case 1.

The index case (case 1) was an ulcerative colitis patient taking maintenance sulfasalazine who presented with colitis and abnormal laboratory tests (elevated alanine aminotransferase,

$\gamma$ -glutamyl transpeptidase, and ESR) associated with stool positive for *C difficile* toxin. The *C difficile* was treated with oral vancomycin and the symptoms of colitis resolved with normalization of laboratory tests. After the vancomycin was discontinued and the *C difficile* was no longer detectable by polymerase chain reaction, the colitis and abnormal liver test including elevation of the ESR recurred. The patient had a liver biopsy and ERCP that were both consistent with primary sclerosing cholangitis. As reported, retreating with oral vancomycin resulted in normal laboratory test and ERCP and improvement in liver histology. Because of this case, the subsequent 13 children with primary sclerosing cholangitis have been treated with oral vancomycin.

Twelve of our patients (2,4–14) had multiple serological immune markers measured before and while receiving oral vancomycin. These included antinuclear antibody (ANA), anti-smooth muscle antibody, anti-liver kidney antibody, anti-mitochondrial antibody, anti-neutrophilic cytoplasmic antibody (p-ANCA), and anti-*Saccharomyces cerevisiae* antibody.

One of the most recent patients (case 10) treated in our series was a 12-year-old male who presented with a 3-month history of symptoms that included weight loss, diffuse abdominal pain, and a 2-week history of cough. He had been on a 10-day course of amoxicillin at the onset of his cough. His chest radiograph revealed bilateral pleural and cardiac effusions. His CT scan demonstrated bilateral micronodular infiltrates with clumped appearance in the subpleural locations and along the fissures. There were also signs of mediastinal and hilar adenopathy. He had a normal bronchoscopy with negative bronchial lavage cultures. Clinically, he was lethargic and hypoxic requiring oxygen via nasal cannula. Serum studies revealed an ESR 130 mm/hour, aspartate aminotransferase 114 IU/L, alanine aminotransferase 77 IU/L, alkaline phosphatase 1147 U/L,  $\gamma$ -glutamyl transpeptidase 418 IU/L, and albumin 2.9 g/dL. His liver biopsy demonstrated severe changes most consistent with biliary tract outflow obstruction and chronic active inflammation involving the biliary tree. His magnetic resonance cholangiogram demonstrated beading of his left intrahepatic duct. His immunological markers demonstrated a positive ANA, anti-smooth muscle antibody, ANCA, and anti-*S cerevisiae* antibody.

### Treatment

Oral vancomycin was instituted to all 14 patients at an initial dose of  $50 \text{ mg} \cdot \text{kg}^{-1} \cdot \text{day}^{-1}$ . Vancomycin was the only treatment given except for sulfasalazine, which was given to case 1 for his colitis, and amoxicillin, which was given to case 12 for his presenting cough. Initially, patients were treated until there was normalization or no further improvement of the liver enzymes and ESR. The 4 patients (cases 2, 6, 8, and 9) whose laboratory tests did not normalize and who had cirrhosis on liver biopsy were not retreated. The other 10 patients (cases 1, 3, 4, 5, 7, 10, 11, 12, 13, and 14) who had normalization of the laboratory tests on oral vancomycin and did not have cirrhosis on liver biopsies were retreated with oral vancomycin; 4 patients (cases 1, 3, 4, and 5) received intermittent short courses of treatment over  $4\frac{1}{2}$  years, with 4 patients (cases 3, 7, 10, and 14) remaining on long-term treatment for a mean of  $54 \pm 43$  months ranging from 30 to 118 months. Because of recurrence of abnormal liver function tests after vancomycin was discontinued, case 3 was placed on long-term therapy. Before, during, and after completion

of oral vancomycin, liver function and ESR were measured with biochemical tests.

### Statistical Analysis

All of the results were reported as mean  $\pm$  standard deviation. *P* values were derived using Wilcoxon signed rank test.

## RESULTS

All 14 of our patients showed improvement of selected liver function tests and ESR (Fig. 1). There was no significant change in the total bilirubin, complete blood count, or any laboratory values other than those listed in Figure 1.

There was less of an improvement demonstrated in the patients with cirrhosis (cases 2, 6, 8, and 9) than the patients without cirrhosis (cases 1, 3, 4, 5, 7, 10, 11, 12, 13, and 14) (Fig. 2). Because there was less significant

response observed in the patients with cirrhosis, they were not retreated with vancomycin.

When the vancomycin treatment was discontinued, there was recurrence of clinical symptoms and an increase in liver enzymes in those who did not have cirrhosis (cases 1, 3, 4, and 5) (Fig. 3). Those who were retreated following their relapse again had normalization of liver enzymes. One patient (case 4) was retreated only once, with 3 (cases 1, 3, and 5) receiving 2 treatments. Seven patients (cases 3, 7, 10, 11, 12, 13, and 14) without cirrhosis were left on treatment for a mean of  $19 \pm 24$  months ranging from 4 to 56 months. Their laboratory values have remained normal and they are clinically asymptomatic. Cases 7 and 10 underwent liver biopsies while on vancomycin, and case 10 also had a repeat colonoscopy with biopsy. All of the biopsies on vancomycin were normal.

Twelve (cases 2, 4, 5, 6, 7, 8, 9, 10, 11, 12, 13, and 14) of the 14 patients had immune markers tested. All

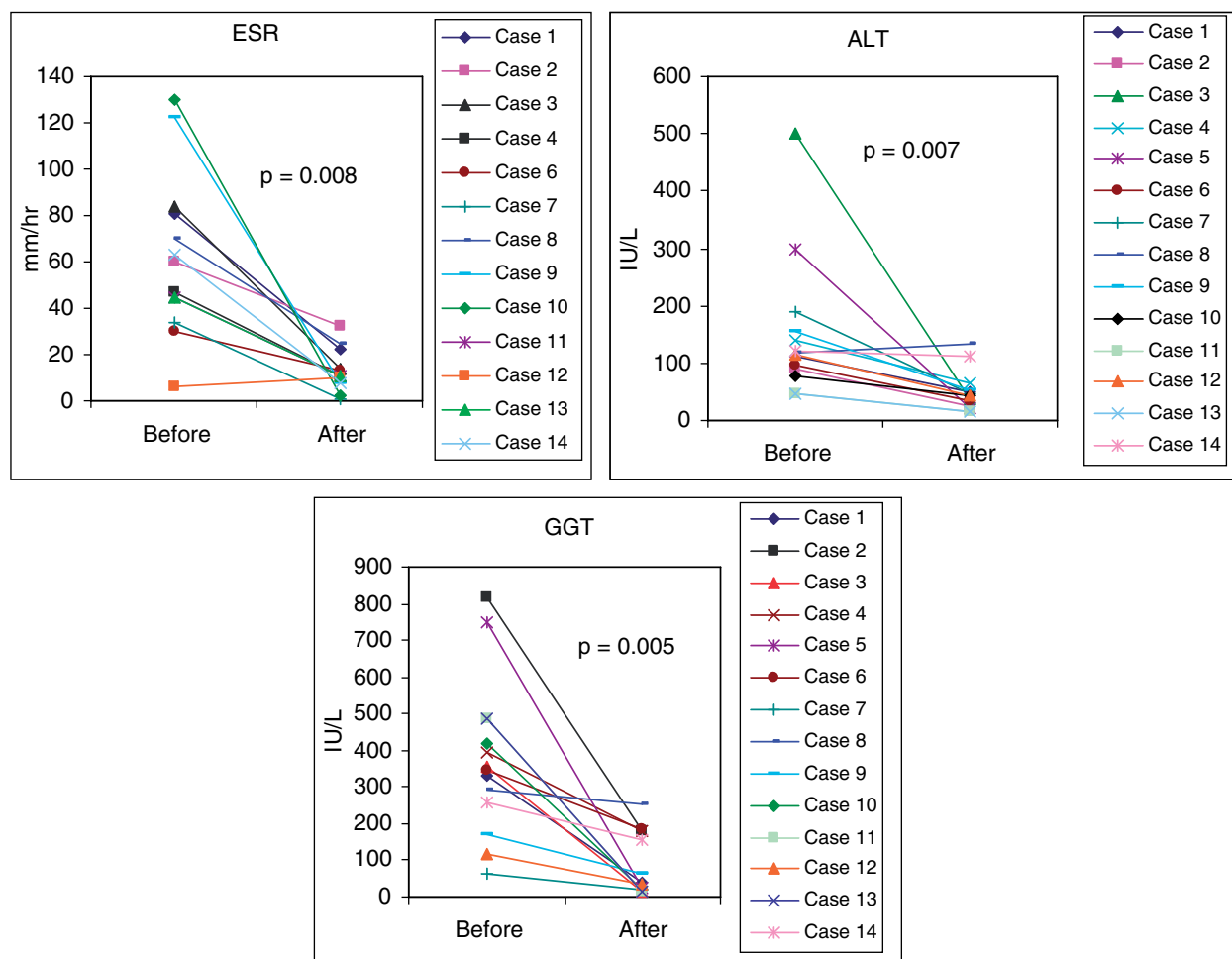
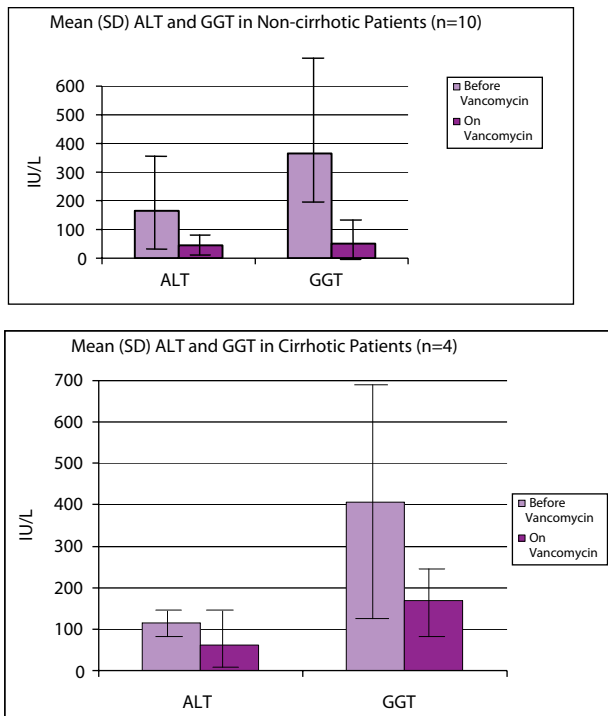


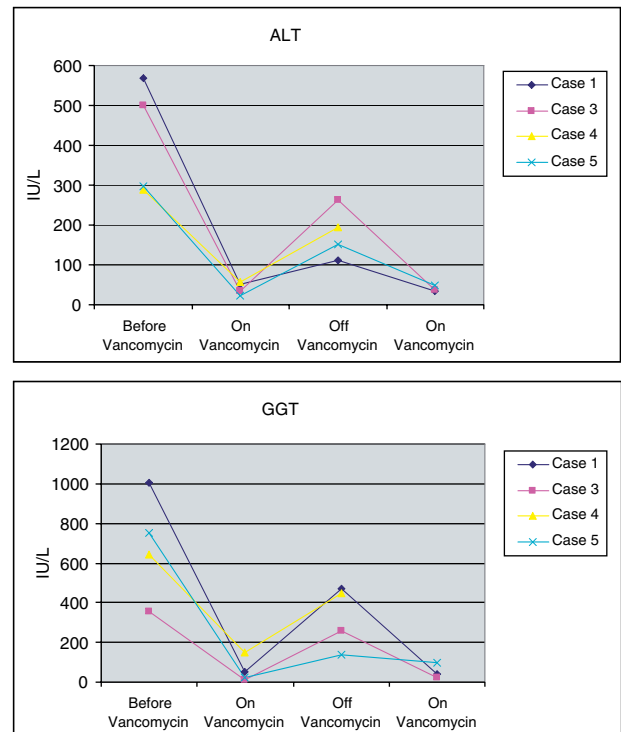
FIG. 1. Blood alanine aminotransferase (ALT),  $\gamma$ -glutamyl transpeptidase (GGT), and erythrocyte sedimentation rate (ESR) levels in 14 children before and after 1–2 months of treatment with oral vancomycin ( $50 \text{ mg} \cdot \text{kg}^{-1} \cdot \text{day}^{-1}$ ).



**FIG. 2.** Cirrhotic ( $n=4$ ) vs noncirrhotic ( $n=10$ ) blood alanine aminotransferase (ALT) and erythrocyte sedimentation rate (ESR) levels before and after 1–2 months of treatment with oral vancomycin ( $50 \text{ mg} \cdot \text{kg}^{-1} \cdot \text{day}^{-1}$ ).

12 patients had 1 or more positive serum autoantibody tests before treatment, with an overall decrease in positive antibodies after 3.5 months taking vancomycin. Of those 12 patients, 5 patients (cases 2, 6, 7, 8, and 12) had a positive ANA. The most frequent ANA pattern was the speckled pattern. Three patients (cases 5, 7, and 10) had a positive smooth muscle antibody; all of the patients were negative for anti-liver kidney and antimitochondrial antibodies. There was 1 patient (case 10) who was both anti-*S cerevisiae* antibody and p-ANCA positive; the remaining patients were positive for p-ANCA. In 4 patients (cases 6, 7, 9, and 10), ANA, smooth muscle antibody, and p-ANCA were positive before treatment and became negative after an average of 3 months of vancomycin treatment. The other 8 patients presented at an earlier stage of our evaluation and did not have repeat serologies or are awaiting repeat serologies.

In case 10, the liver biopsy before beginning vancomycin demonstrated severe changes, including acute inflammation involving the biliary tree, bile ductular proliferation, and periductal fibrosis in an onion skin pattern, suggesting sclerosing cholangitis (Fig. 4E and G). There was chronic active inflammation with granuloma formation in the duodenum (Fig. 4A). Sections of the colon demonstrated cryptitis and crypt abscess formation (4C). Giant cells were present in biopsies of duodenum and



**FIG. 3.** Relapse of liver disease as indicated by changes in blood alanine aminotransferase (ALT) and  $\gamma$ -glutamyl transpeptidase (GGT) levels in 4 patients who received a total of 7 intermittent treatments ( $<3 \text{ mo}$  each) of oral vancomycin ( $50 \text{ mg} \cdot \text{kg}^{-1} \cdot \text{day}^{-1}$ ).

ileum, although no organisms were identified by Giemsa stain or acid-fast bacillus staining. After 2 months of vancomycin treatment, the repeat liver biopsy demonstrated only mild ductular proliferation without acute inflammation; significant periductal fibrosis was absent in this core (Fig. 4F and H). The gastrointestinal biopsies showed a normal duodenum and resolution of acute inflammation and granulomas (Fig. 4B and D). The patient's diffuse abdominal pain resolved after 3 days on vancomycin with an increase in appetite. The patient required oxygen during his hospitalization, which was discontinued after 2 days on vancomycin. The nodularity of the lungs on CT scan before treatment resolved completely on vancomycin.

## DISCUSSION

In this study, oral vancomycin was an effective treatment of sclerosing cholangitis in children. Blood liver enzyme levels and sedimentation rates normalized on oral vancomycin in 10 children who did not have cirrhosis, and improved in the 4 children with cirrhosis. When the vancomycin was stopped after 2 to 3 months of therapy, abnormalities of blood liver enzymes and sedimentation rate recurred. When children without

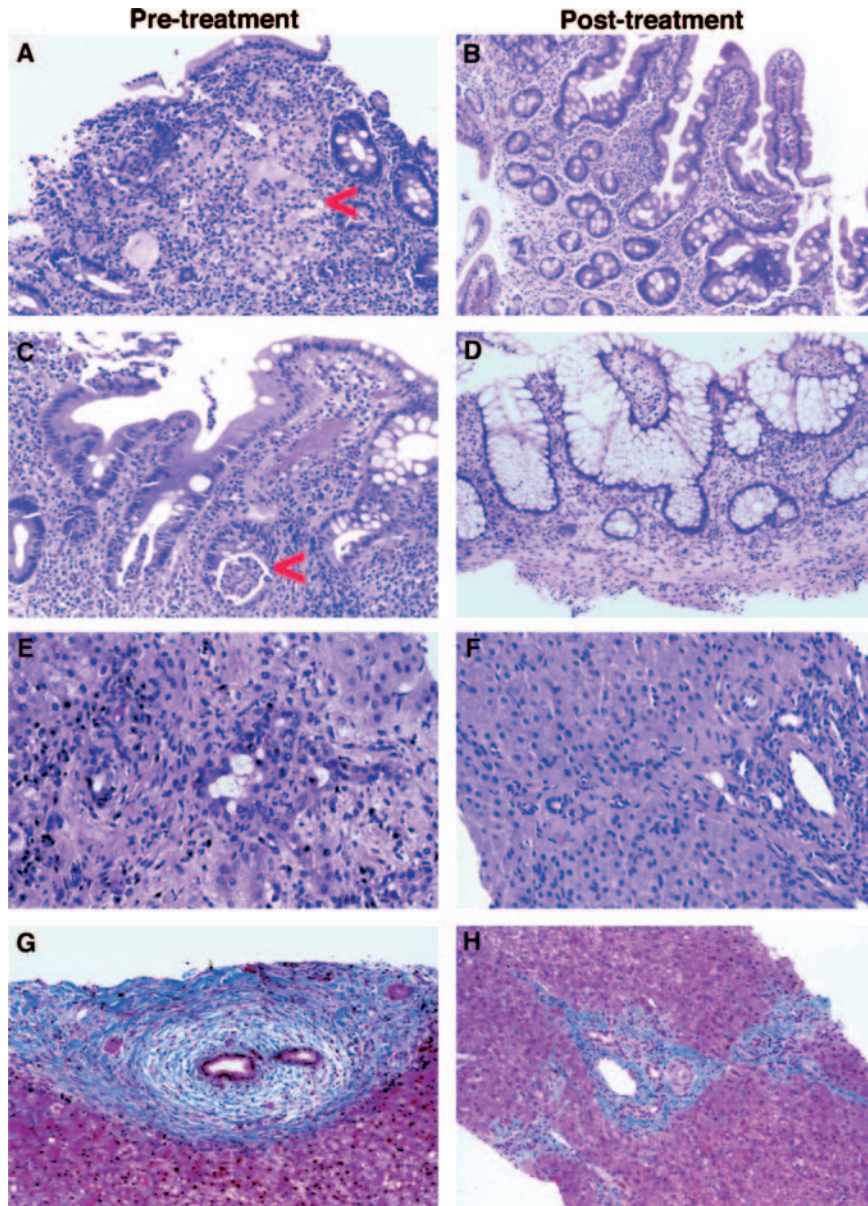


FIG. 4. Pathology of primary sclerosing cholangitis. A-H.

cirrhosis were retreated and maintained on long-term therapy, the liver enzymes and sedimentation rates remained normal. Oral vancomycin is poorly absorbed from the gastrointestinal tract. From these observations, we postulate that the efficacy of oral vancomycin is due to its antimicrobial effects on as yet unidentified gastrointestinal organisms, or from absorbed vancomycin metabolites or bacteria degradation products, such as cell walls or glycoproteins, which may alter the innate and adaptive immune response to components of the hepatobiliary tract.

Vancomycin, a bactericidal antibiotic, is effective against gram-positive organisms. It actively suppresses methicillin-resistant *Staphylococcus aureus*, staphylococcal epidermis, streptococcal pyogenes, *Streptococcus pneumoniae*, *Enterococcus faecalis*, species of *Clostridium*, diphtheroids, *Listeria monocytogenes*, and *Lactobacillus* (13). It exerts its effects by binding to the precursor units of bacterial cell walls, inhibiting their synthesis (13). The net result is alteration in bacterial cell wall permeability. Gram-negative organisms are not sensitive to vancomycin, perhaps because of the porin channels in the

cell walls of gram-negative organisms, which do not accommodate the large, bulky vancomycin molecule. No enteric pathogens have been identified as causing sclerosing cholangitis (14,15). Thirteen of our patients had stool cultures and *C difficile* toxin assays, which were negative for pathogens. This would suggest that the response to oral vancomycin was due to its antimicrobial effects on unknown pathogens or normal flora that were causing abnormal immunological reactions in the liver.

The association of Crohn disease with a lung disorder is a rare finding. Although often overlooked, granulomatous pulmonary disease has been reported as an extraintestinal manifestation in patients with Crohn disease (16,17). Our patient with respiratory distress associated with pulmonary nodules seen on CT scan and without pathogens identified at bronchoscopy may have had toxic or immunoreactive pulmonary disease that responded to the oral vancomycin.

Cellular and humoral abnormalities observed in patients with primary sclerosing cholangitis include abnormalities in the complement system, hyperglobulinemia, elevated circulating immune complexes, and the presence of serum autoantibodies (18–21). An overlapping syndrome between autoimmune hepatitis and primary sclerosing cholangitis has been described previously in the literature (22). In both conditions, there is an increase in immune markers observed (23,24). In 12 patients (cases 2, 4, 5, 6, 7, 8, 9, 10, 11, 12, 13, and 14), several immune markers were measured, and these patients had 1 or more positive antibodies. In 4 patients, who had several autoantibodies measured before and during treatment, ANA, anti-smooth muscle antibody, and p-ANCA were positive before treatment and decreased significantly or became negative on treatment. Although the liver function tests and ESR normalized within 1 month of treatment, the antibodies became negative after taking vancomycin for an average of 3 months. The disappearance of the positive autoantibodies on oral vancomycin suggested that it had an effect on the immunoreactivity in sclerosing cholangitis (25).

Cytokines have an important role in the inflammatory cascade events. Tumor necrosis factor- $\alpha$  (TNF- $\alpha$ ), a cytokine produced by monocytes/macrophages, can be stimulated by bacterial products, such as lipopolysaccharide, in the setting of gram-negative sepsis (13,26). The cell walls of gram-positive organisms contain teichoic acid and peptidoglycan, which are also able to trigger the release of TNF- $\alpha$  (13,26). Vancomycin has been shown to downregulate the TNF- $\alpha$  mRNA accumulation in blood monocytes and lipopolysaccharide-induced TNF- $\alpha$  (27). The downregulation of TNF- $\alpha$  production by monocytes may be one of the therapeutic effects observed with vancomycin in these patients.

In conclusion, before this study, there has not been an effective treatment for sclerosing cholangitis resulting in the usual progression of this disease to cirrhosis. This

study has shown that oral vancomycin could be an effective therapy for long-term treatment of sclerosing cholangitis in children, especially those without cirrhosis. Because those without cirrhosis had normal liver studies while taking oral vancomycin and relapsed when vancomycin was discontinued after 3 months, longer term therapy is indicated. However, whether longer term therapy will allow eventual withdrawal of therapy without relapse has yet to be determined. Although none of our patients had side effects or infectious complications from the oral vancomycin, there is concern that use of this antibiotic will lead to vancomycin-resistant organisms (eg, *Enterococcus*). As a result, future studies should attempt to identify the mechanisms by which vancomycin produces its effect, then develop more specific antimicrobial or immunological treatments that will not have the risk for creating resistant antimicrobial organisms.

**Acknowledgments:** We appreciate the assistance of Megan Troxell, MD, PhD, in the Department of Pathology at Stanford University for reviewing the pathology of case 10 and selecting the most appropriate photographs of the histology for this publication. We also appreciate the generous donations of the Cronholm, Sanders, and Wadsworth families to the Shoenberg Foundation, which were used to support these studies.

## REFERENCES

1. El-Shabrawi M, Wilkinson ML, Portmann B, et al. Primary sclerosing cholangitis in childhood. *Gastroenterology* 1987;92:1226–35.
2. Roberts EA. Primary sclerosing cholangitis in children. *J Gastroenterol Hepatol* 1999;14:588–93.
3. Ponsioen CY, Vrouenraets SM, Prawirodirdjo W, et al. Natural history of primary sclerosing cholangitis and prognostic value of cholangiography in a Dutch population. *Gut* 2002;51:562–6.
4. Lee YM, Kaplan MM. Primary sclerosing cholangitis. *N Engl J Med* 1995;332:924–33.
5. Narayanan Menon KV, Wiesner RH. Etiology and natural history of primary sclerosing cholangitis. *J Hepatobiliary Pancreat Surg* 1999;6:343–51.
6. Angulo P, Lindor KD. Primary sclerosing cholangitis. *Hepatology* 1999;30:325–32.
7. Dienes HP, Lohse AW, Gerken G, et al. Bile duct epithelia as target cells in primary biliary cirrhosis and primary sclerosing cholangitis. *Virchows Arch* 1997;431:119–24.
8. Kozaiwa K, Tajiri H, Sawada A, et al. Three pediatric cases of primary sclerosing cholangitis treated with ursodeoxycholic acid and sulphasalazine. *J Gastroenterol Hepatol* 1998;13:825–9.
9. Lindor KD. Mayo Primary Sclerosing Cholangitis-Ursodeoxycholic Acid Study Group. Ursodiol for primary sclerosing cholangitis. *N Engl J Med* 1997;336:691–5.
10. Olsson R, Broome U, Danielsson A, et al. Colchicine treatment of primary sclerosing cholangitis. *Gastroenterology* 1995;108:1199–203.
11. Kugelmas M, Spiegelman P, Osgood MJ, et al. Different immunosuppressive regimens and recurrence of primary sclerosing cholangitis after liver transplantation. *Liver Transpl* 2003;9:727–32.
12. Cox KL, Cox KM. Oral vancomycin: treatment of primary sclerosing cholangitis in children with inflammatory bowel disease. *J Pediatr Gastroenterol Nutr* 1998;27:580–3.

13. Siedlar M, Szczepanik A, Wieckiewicz J, et al. Vancomycin down-regulates lipopolysaccharide-induced tumour necrosis factor  $\alpha$  (TNF  $\alpha$ ) production and TNF  $\alpha$ -mRNA accumulation in human blood monocytes. *Immunopharmacology* 1997;35:265–71.
14. Olsson R, Bjornsson E, Backman L, et al. Bile duct bacterial isolates in primary sclerosing cholangitis: a study of explanted livers. *J Hepatol* 1998;28:426–32.
15. Bjornsson ES, Kilander AF, Olsson RG. Bile duct bacterial isolates in primary sclerosing cholangitis and certain other forms of cholestasis—a study of bile cultures from ERCP. *Hepato-gastroenterology* 2000;47:1504–8.
16. Bentur L, Lachter J, Koren I, et al. Severe pulmonary disease in association with Crohn's disease in a 13-year-old girl. *Pediatr Pulmonol* 2000;29:151–4.
17. Mahadeva R, Walsh G, Flower CD, et al. Clinical and radiological characteristics of lung disease in inflammatory bowel disease. *Eur Respir J* 2000;15:41–8.
18. Gohlke F, Lohse AW, Dienes HP, et al. Evidence for an overlap syndrome of autoimmune hepatitis and primary sclerosing cholangitis. *J Hepatol* 1996;24:699–705.
19. Ben-Ari Z, Panagou M, Patch D, et al. Hypercoagulability in patients with primary biliary cirrhosis and primary sclerosing cholangitis evaluated by thrombelastography. *J Hepatol* 1997;26:554–9.
20. Cambridge G, Rampton DS, Stevens TR, et al. Anti-neutrophil antibodies in inflammatory bowel disease: prevalence and diagnostic role. *Gut* 1992;33:668–74.
21. Chapman RW, Cottone M, Selby WS, et al. Serum autoantibodies, ulcerative colitis, and primary sclerosing cholangitis. *Gut* 1986;27:86–91.
22. Angulo P, Peter JB, Gershwin ME, et al. Serum autoantibodies in patients with primary sclerosing cholangitis. *J Hepatol* 2000;32:182–7.
23. Claise C, Johanet C, Bouhnik Y, et al. Antineutrophil cytoplasmic autoantibodies in autoimmune liver and inflammatory bowel diseases. *Liver* 1996;16:28–34.
24. Van Milligen de Wit AW, van Deventer SJ, Tytgat GN. Immunogenetic aspects of primary sclerosing cholangitis: implications for therapeutic strategies. *Am J Gastroenterol* 1995;90:893–900.
25. Schattner A, Kozak N, Lassry Y, et al. Primary intestinal T-cell lymphoma and sclerosing cholangitis: a cytokine-mediated association? *J Intern Med* 1998;244:537–41.
26. Bernal W, Moloney M, Underhill J, et al. Association of tumor necrosis factor polymorphism with primary sclerosing cholangitis. *J Hepatol* 1999;30:237–41.
27. Bo X, Broome U, Remberger M, et al. Tumour necrosis factor  $\alpha$  impairs function of liver derived T lymphocytes and natural killer cells in patients with primary sclerosing cholangitis. *Gut* 2001;49:131–41.