Soonchunhyang Medical Science 21(2):201-204, December 2015 pISSN: 2233-4289 | eISSN: 2233-4297 SMS

CASE REPORT

Late Recurrence of Ovarian Cancer Mimicking a Primary Lung Malignancy after Curative Resection

Yoon Chae Lee[1], So Yeon Jeon[1,2], Seung Yong Park[1,2], Yeong Hun Choe[1,2], Yong Chul Lee[1,2,*], So Ri Kim[1,2,*]

[1]Department of Internal Medicine and Research Center for Pulmonary Disorders, Chonbuk National University Medical School; [2]Research Institute of Clinical Medicine of Chonbuk National University-Biomedical Research Institute of Chonbuk National University Hospital, Jeonju, Korea

The majority of patients with an advanced-stage ovarian cancer relapse within approximately 18 months after completion of the first-line therapy. Recurrent ovarian cancer commonly presents as peritoneal seeding, while other distant sites are anywhere including the pleura, liver, lung, central nervous system, spleen, skin, bone, and breast. As pulmonary metastases usually occur through hematogenous or lymphangitic routes, the pattern of the metastases of ovarian cancer is multiple and scattered diffusely. The solitary pulmonary metastasis of ovarian cancer is an extremely rare condition, thus it can be misdiagnosed as a primary lung cancer, unless physician has a clinical suspicion. Herein, we introduce a case of solitary pulmonary metastasis of ovarian cancer which occurred 9 years after the curative surgery and chemotherapy.

Keywords: Recurrence; Ovarian neoplasms; Metastatic; Thoracic surgical procedure

INTRODUCTION

Ovarian cancer is the most lethal gynecological malignancy in the United States [1]. Unfortunately, most women with advanced-stage ovarian cancer experience disease relapse after primary adjuvant chemotherapy and develop symptomatic recurrent disease [2]. The incidence of pulmonary metastases and pleural metastases of ovarian cancer is from 25% to 35% and from 0% to 28%, respectively [3]. Generally pulmonary metastases are hematogenous or lymphangitic [4] and solitary pulmonary metastases of ovarian cancer are extremely rare. In addition, the majority of recurrence of ovarian cancer occurs within few years after the complete remission (CR) through curative treatment. Therefore, the late solitary pulmonary metastasis from ovarian cancer can be difficult to differentiate it from a primary lung cancer.

This report describes a rare case of solitary pulmonary metastasis from ovarian cancer occurred long after the achievement of CR state with mimicking the typical radiologic features of primary lung cancer.

CASE REPORT

A 58-year-old woman visited Chonbuk National University Hospital with chief complaint of cough and chest discomfort on the left thorax for two months. There was no history of weight loss, hemoptysis, smoking behavior, and environmental and/or drug exposure. Physical and laboratory examination did not reveal any relevant abnormality except anemia. Nine years ago, she had total hysterectomy and bilateral salpingo-oophorectomy for ovarian clear cell carcinoma and serous cystadenocarcinoma. She was also diagnosed as pulmonary tuberculosis and was treated at that time. Until this lung mass was detected, she had been regular check-ups at obstetrics and gynecology for seven years and no evidence of recurrence for ovarian cancer including cancer antigen 125 (CA 125) and computed tomography (CT) images of abdominal and pelvis.

Chest X-ray showed an approximately 6-cm-sized huge mass in the left lung field (Fig. 1A). On contrast enhanced chest CT images, the mass had well demarcated smooth margin with eccentric focal calcification, obstructed the airway, and was enhanced very poorly (Fig. 1B, C). Bronchoscopic examination revealed that the

Correspondence to: So Ri Kim
Department of Internal Medicine, Chonbuk National University Medical School, 567 Baekje-daero, Deokjin-gu, Jeonju 54896, Korea
Tel: +82-63-250-2475, Fax: +82-63-259-3212, E-mail: sori@jbnu.ac.kr
*These authors contributed equally to this work as a senior author.
Received: Oct. 22, 2015 / Accepted after revision: Nov. 4, 2015

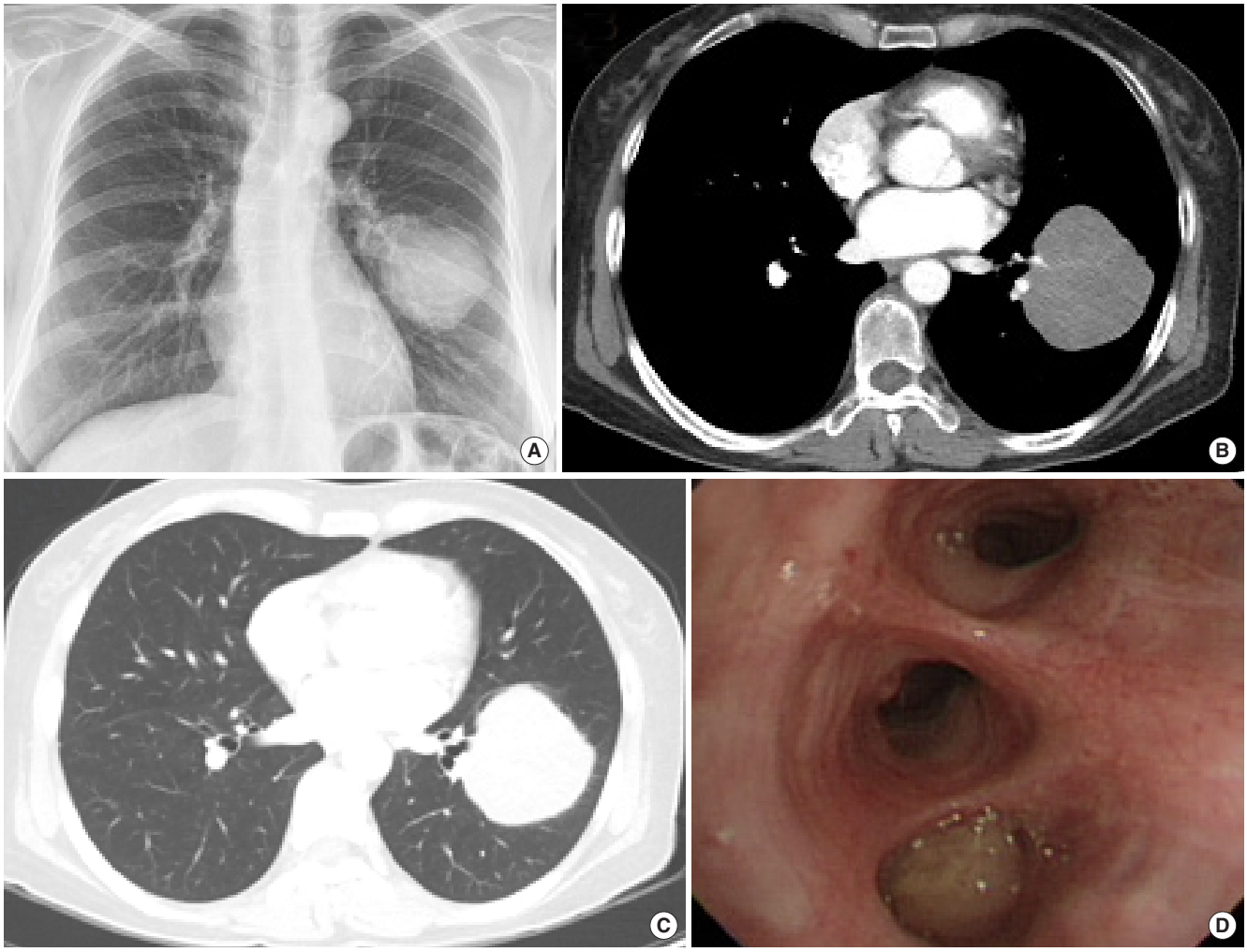

Fig. 1. (A) Chest X-ray showed an approximately 6-cm-sized mass in the left lung field. (B, C) Chest computed tomography revealed a mass with well demarcated smooth margin and poor enhancement in the left lower lobe. (D) Fiberoptic bronchoscopy showed a mass obstructing the lumen of left lower basal segment.

round mass occupied the lumen of the left lower basal segments (Fig. 1D), and the tissues obtained by bronchoscopic biopsy showed that the mass was consisted of several gray irregular and friable fragments of soft tissues, suggesting adenocarcinoma. Under the impression of primary lung malignancy, non-small cell lung cancer suggestive of adenocarcinoma, we decided to perform left lower lobectomy for the mass aiming to confirm the diagnosis of the mass and to remove the mass surgically. The surgical specimen was approximately 6×5-cm-sized yellowish firm mass which was well demarcated from surrounding tissues. On microscopic findings, the lining epithelium was composed of tall columnar epithelium with apical mucin. They showed solid growth with conspicuous epithelia cell atypia and stratification. Immunohistochemically, the tumor cells were positively stained for C-kit, high molecular weight cytokeratin, p53, and Ki 67. But they were negative for CD34, p63, estrogen receptor, progesterone receptor, and thyroid transcription factor-1 (Fig. 2A-H). As we reviewed the previous pathologic slides of the ovarian cancer resected surgically nine years ago, the histologic features of ovarian mass appeared to be similar to those of lung mass, showing that irregular glandular spaces were lined with a layer of tall columnar cells exhibiting abundant mucinous cytoplasm and fibrous stroma (Fig. 2I).

Based on these findings, the pulmonary mass was verified as metastatic recurred adenocarcinoma from previous ovarian cancer. She had taken the adjuvant chemotherapy with platinum based regimen.

DISCUSSION

Ovarian cancer ranks fifth among the leading causes of cancer-

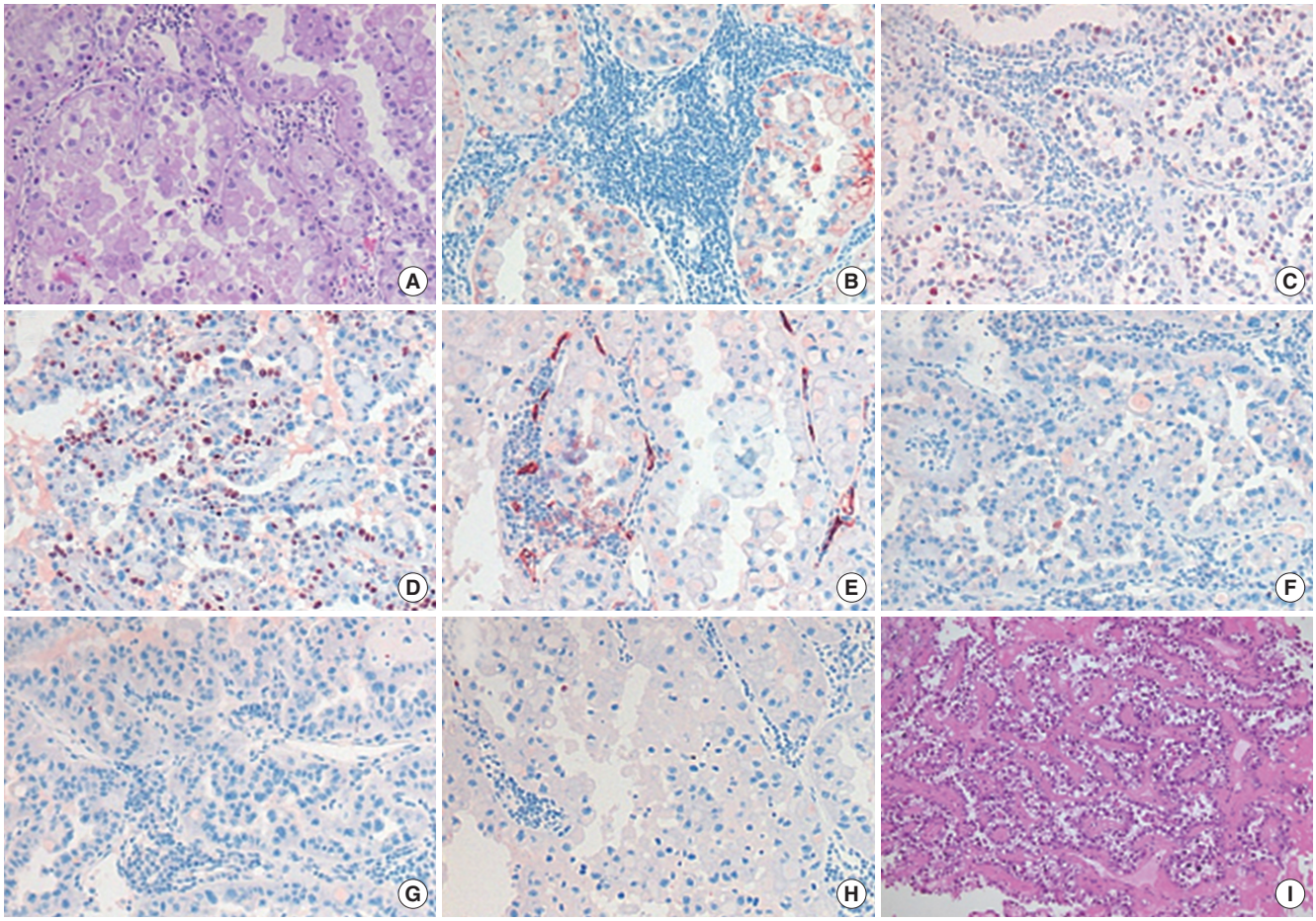

Fig. 2. (A) Representative hematoxylin & eosin (H&E)-stained section of the lung mass showed that the lining epithelium was composed of tall columnar epithelium with apical mucin. They showed solid growth with conspicuous epithelia cell atypia and stratification (×100). (B-H) Immunohistochemical analyses for (B) high molecular weight cytokeratin (HMW-CK) (B), (C) p53, (D) Ki 67, (E) CD34, (F) estrogen receptor (ER), (G) progesterone receptor (PR), and (H) thyroid transcription factor (TTF)-1. The tumor cells were positively stained for C-kit, HMW-CK, p53, and Ki 67. But they were negative for CD34, p63, ER, PR, and TTF-1 (×100). (I) Representative H&E-stained section of the ovarian mass resected 9 years ago. It appears to be similar to histologic findings of lung mass, showing that irregular glandular spaces were lined with a layer of tall columnar cells exhibiting abundant mucinous cytoplasm and fibrous stroma (×100).

related deaths in women [1]. Overall rate of tumor response for the standard chemotherapy is relatively high and ranges from approximately 70% to 80% [5]. However, most of responders relapse within approximately 18 months after completion of the first-line therapy [5].

Recurrent ovarian cancer commonly presents as peritoneal seeding, retroperitoneal and/or mesenteric lymphadenopathy, and a local surgical bed mass [6]. Distant metastases theoretically may occur anywhere [7], including the pleura, liver, lungs, central nervous system, spleen, skin, bone, and breast. The pulmonary metastases of ovarian cancer are manifested variously such as pleural effusions, parenchymal or solid metastases, lymphangitic metastatic disease, hilar or nodal metastases, solid pleural metastases, and rib, pericardial, and pulmonary intravascular metastases. Typical radiologic findings of pulmonary metastases include multiple peripherally located round variable-sized nodules (i.e., hematogenous metastasis) and diffuse thickening of the interstitium (i.e., lymphangitic carcinomatosis) [4].

Some solitary metastasis of ovarian cancer has been reported uncommonly in spleen, liver, and central nervous system including cerebrum, cerebella, and spinal cord [8]. As for solitary pulmonary metastasis of ovarian cancer, a case of simultaneous single pulmonary metastasis of ovarian cancer has been reported [9]. Interestingly, in our current case, a solitary metastatic mass was occurred in the lung, was very large up to 6 cm, and was well demarcated from the surrounding parenchyme of the lung, exhibiting smooth margin and eccentric focal calcification. Moreover, the mass obstructed the laterobasal subsegmental bronchi.

Recurrence-free survival rates for all patients with ovarian cancer are 75% at 2 years, 55% at 5 years, and 52% at 10 years after the first line therapy [10]. Specifically, patients with stage III or IV disease have recurrence-free survival rates of 72%, 44%, and 40% at 2, 5, and 10 years, respectively [10]. Therefore, the late recurrence is relatively uncommon. In this case, our patient had been in CR state until a solitary pulmonary mass was detected at 9 years after the surgical resection of the ovarian cancer, adenocarcinoma, with adjuvant chemotherapy. The initial radiologic diagnosis was a primary lung malignancy, presenting as a single huge mass with obstructing bronchial lumen of the left lower lobe, however, we finally confirmed the diagnosis as a metastatic ovarian cancer in the lung, through comparison of histologic features of previous ovarian cancer with the current lung mass.

This interesting case of the late recurrence of ovarian cancer mimicking a primary lung malignancy suggests that although the clinical presentation of our patient is atypical, the possibility of solitary pulmonary metastasis should be considered, specifically in patients previously treated for ovarian cancer, even in patients kept in CR state for long time.

This case shows that distant metastasis is possible even though normal abdominal-pelvis CT scan and CA 125 level in ovarian cancer. Therefore, regular chest CT follow-up should be considered for distant metastasis of ovarian cancer as well as abdominal-pelvis CT scan and CA 125.

In conclusion, we introduce a very rare case of late recurrence of ovarian cancer presenting as a solitary pulmonary huge mass which was initially misdiagnosed as primary lung malignancy. This case report provides the physicians the lessons that correct diagnosis for a lung mass is based on the meticulous history taking, clinical suspicion, and pathologic analyses, even though the radiologic diagnostic modalities are developing and images are getting more correct.

ACKNOWLEDGMENTS

We thank Professor Mie-Jae Im for critical readings of the manuscript.

REFERENCES

1. Jemal A, Siegel R, Ward E, Murray T, Xu J, Smigal C, et al. Cancer statistics, 2006. CA Cancer J Clin 2006;56:106-30.
2. Ozols RF. Treatment goals in ovarian cancer. Int J Gynecol Cancer 2005; 15 Suppl 1:3-11.
3. Rose PG, Piver MS, Tsukada Y, Lau TS. Metastatic patterns in histologic variants of ovarian cancer. An autopsy study. Cancer 1989;64:1508-13.
4. Libshitz HI, North LB. Pulmonary metastases. Radiol Clin North Am 1982;20:437-51.
5. McGuire WP, Hoskins WJ, Brady MF, Kucera PR, Partridge EE, Look KY, et al. Cyclophosphamide and cisplatin compared with paclitaxel and cisplatin in patients with stage III and stage IV ovarian cancer. N Engl J Med 1996;334:1-6.
6. Park CM, Kim SH, Kim SH, Moon MH, Kim KW, Choi HJ. Recurrent ovarian malignancy: patterns and spectrum of imaging findings. Abdom Imaging 2003;28:404-15.
7. Dauplat J, Hacker NF, Nieberg RK, Berek JS, Rose TP, Sagae S. Distant metastases in epithelial ovarian carcinoma. Cancer 1987;60:1561-6.
8. Khan O, Savage P, Gopeesingh T, Fernando DC. Splenic metastases in ovarian carcinoma. West Indian Med J 1987;36:251-5.
9. Lauenstein TC, Goehde SC, Herborn CU, Goyen M, Oberhoff C, Debatin JF, et al. Whole-body MR imaging: evaluation of patients for metastases. Radiology 2004;233:139-48.
10. Rubin SC, Randall TC, Armstrong KA, Chi DS, Hoskins WJ. Ten-year follow-up of ovarian cancer patients after second-look laparotomy with negative findings. Obstet Gynecol 1999;93:21-4.