

Association between abnormal kinematics and degenerative change in knees of people with chronic anterior cruciate ligament deficiency: A magnetic resonance imaging study

Jennifer M Scarvell^{acf}, Paul N Smith^{ab}, Kathryn M Refshauge^c, Howard R Galloway^{bd}
and Kevin R Woods^e

^aTrauma and Orthopaedic Research Unit, The Canberra Hospital ^bANU Medical School, The Canberra Hospital ^cSchool of Physiotherapy, University of Sydney, ^dThe Canberra Hospital ^eCanberra Orthopaedic Group ^fSchool of Health Sciences, University of Canberra

Progressive degeneration of the anterior cruciate ligament (ACL) deficient knee may be partly due to chondral trauma at the time of ACL rupture and repeat episodes of subluxation, but also due to aberrant kinematics altering the wear pattern at the tibiofemoral interface. The hypothesis that altered kinematics, represented by the tibiofemoral contact pattern, would be associated with articular cartilage degeneration in ACL-deficient knees was tested in a cross-sectional study of 23 subjects with a history of > 10 years ACL-deficiency without knee reconstruction. Subjects were aged 31 to 67 years. Eleven were male, 12 were female. Sagittal magnetic resonance imaging (MRI) scans enabled tibiofemoral contact mapping as subjects performed a closed-chain leg-press. Images were acquired at 15 degree intervals from 0 degrees to 90 degrees knee flexion. Articular cartilage degeneration was assessed by diagnostic MRI and where possible, arthroscopy. The ACL-deficient knees had a posterior tibiofemoral contact pattern on the tibial plateau compared to the healthy knees ($F_{(1,171)} = 9.2, p = 0.003$). The difference appeared to be seen in the medial compartment ($F_{(1,171)} = 3.2, p = 0.07$), though this failed to reach significance. Articular cartilage degeneration in the medial compartment was related to the variation of the tibiofemoral contact pattern ($r = -0.53, p = 0.01$). Articular cartilage degeneration was not related to time since injury ($r = -0.16, p = 0.65$). The association between aberrant kinematics and degenerative change may stimulate thinking on the role of dynamic stability and neuromuscular co-ordination in joint protection. [Scarvell JM, Smith PN, Refshauge KM, Galloway HR and Woods KR (2005): Association between abnormal kinematics and degenerative change in knees of people with chronic anterior cruciate ligament deficiency: A magnetic resonance imaging study. *Australian Journal of Physiotherapy* 51: 233–240]

Key words: Anterior Cruciate Ligament, Chronic Anterior Ligament Injury, Knee Kinematics, Magnetic Resonance Imaging

Introduction

It has long been recognised that anterior cruciate ligament (ACL) injury initiates a cascade of events frequently terminating in osteoarthritis of the injured knee (Clatworthy and Amendola 1999, McDaniel and Dameron 1980). Factors responsible for degeneration of the knee include events at the time of the original injury such as chondral and bone trauma and meniscal tears (Wu et al 2002). While the past cannot be changed, physiotherapists involved in the long term care of the chronic ACL-deficient patient seek to understand the factors influencing future degenerative changes in order to give sound advice and make informed rehabilitation decisions. Future degenerative changes may be the consequence of repeated episodes of trauma due to instability (Fetto and Marshall 1980) as well as changes to the kinematics of the knee during routine activities (Allen et al 2000). However, while several studies have examined the kinematics of the acute ACL-deficient knee (Beard et al 1996, Beynnon et al 2003, Brandsson et al 2001, Georgoulis et al 2003, Hollman et al 2002), there is little known regarding the kinematics of chronic ACL-deficient knees (Wexler et al 1998), despite the role of the physiotherapist in improving kinematics by neuromuscular re-education in ACL-deficiency (Ellenbecker 2000).

The cause of articular cartilage degeneration may be indicated by its nature and location. For example, the anterior and internal rotation subluxation of the tibia that ruptures the ACL also frequently causes chondral and bone trauma seen as a kissing lesion in the lateral compartment (Myers et al 2001). Bone bruises visible on magnetic resonance imaging (MRI) scan are evidence that impact injuries in conjunction with ACL injuries may occur with sufficient force to cause bleeding in the subchondral bone (Johnson et al 2000, Lahm et al 1998). In the medial compartment of chronic ACL-deficient knees, degeneration of the menisci has been described as a major risk factor for osteoarthritis (Segawa et al 2001). The medial meniscus is a secondary stabiliser of the knee during application of an anterior tibial force, resulting in additional load and shear forces on the meniscus (Allen et al 2000, Butler et al 1980). These increased loads may lead to degenerative failure and render the meniscus incapable of fulfilling the roles of shock absorption, cartilage nutrition, and load distribution which protect the chondral surface (Allen et al 2000, Bellabarba et al 1997). A chronic ACL-deficient knee with medial meniscus incompetency has an 80% risk of medial compartment osteoarthritis (Dejour et al 1994). It may be that lateral compartment degeneration is due to chondral injury at the time of the original injury (Myers et al 2001), but that medial compartment degeneration is the result of other factors such as aberrant kinematics or

subsequent knee injury (Finsterbush et al 1990).

Evidence of altered kinematics in ACL-deficient knees is seen even in routine daily activities such as stepping up, walking, and lunging as changes in the sagittal translation and longitudinal rotation of the ACL-deficient knee during flexion (Brandsson et al 2001, Friden et al 1993, Georgoulis et al 2003, Vergis and Gillquist 1998). Altered kinematic patterns may change the area of loading and magnitude of shear forces at the tibiofemoral contact interface, enough to produce a repetitive micro trauma to the articular cartilage (Allen et al 2000, Sakane et al 1999). While ACL-deficiency has been linked to patterns of tibial articular cartilage degeneration (Frankel et al 1971, Harman et al 1998), it has not been shown specifically that tibiofemoral contact patterns are related to areas of wear at the articular surface. Measurement of knee kinematics by tibiofemoral contact mapping is particularly suitable in the case of chronic ACL-deficiency, as events at the tibiofemoral contact surface have relevance to cartilage wear patterns and shearing.

The aim of this study was to compare the kinematics of chronic ACL-deficient knees with healthy contralateral knees, using MRI. The relationship between kinematic changes, as reflected by the tibiofemoral contact pattern, time since injury, and articular cartilage degeneration were explored using a cross-sectional design.

Method

Patients Twenty-five subjects were recruited with a history of ACL injury at least 10 years previously. Two subjects were excluded following diagnostic MRI, one because an ACL tear was not visible, and one with a concomitant posterior cruciate ligament tear. The remaining 23 subjects were aged between 31 and 67 years (45 ± 9.8 years); 11 were male, 12 were female. The injury was sustained between 10 and 35 years previously, (17.8 ± 1.5 years). Twenty-one subjects were injured during sports, and two in low level falls. Four were injured while skiing, six while playing various codes of football, two during netball, three during basketball, and one each while dancing, wrestling, tobogganing, playing tennis, gymnastics, and hockey. Six injuries were classified as contact injuries, in that the knee had been struck by an object or another person. The remaining 17 were non-contact injuries. Twelve subjects had arthroscopic reconstruction of the ACL following participation in the study. ACL tear was confirmed by MRI scan for every subject.

Subjects were excluded if there were any contraindications to MRI, including suspicion of pregnancy, ferrous metal implants, or claustrophobia, and also if they were over 180 cm tall (to permit knee flexion in the MRI tunnel). Subjects were also excluded if history of injury or symptoms were present in the contralateral knee, so that the uninjured knee could act as a matched control. All subjects provided informed consent according to conditions of ethics approval from university and health department committees.

Imaging MRI was used to record the kinematics of the ACL-deficient knee and contralateral knee for each subject by taking an MRI of both knees simultaneously while the subject performed a supine leg-press within the MRI field. Elastic straps at the ankles and thighs maintained thigh adduction and foot position. Still images were generated at 15 degree intervals, from 0 degrees to 90 degrees flexion. A series of images was acquired with the legs relaxed (unloaded), and

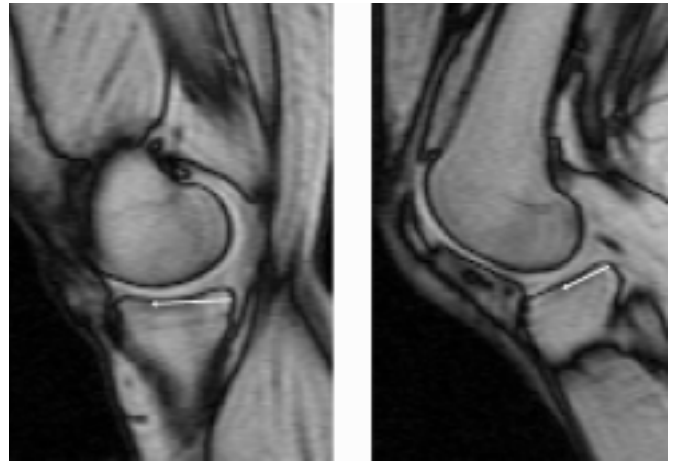

Figure 1: Measurement reference points for tibiofemoral contact mapping. Sagittal MRI images through the medial compartment at 0° and the lateral compartment of the knee at 45°, demonstrating the posterior edge of the tibial cortex and the contact point of the femoral condyle (arrows).

another series resisting a 150N load. Imaging was performed using a 1.5T Siemens Magnetom Vision^a. T1 weighted spoiled gradient echo sequences were used to generate eight sagittal images through each knee, for each condition, and position of flexion. This MRI sequence provides good differentiation of cortical bone and articular cartilage. Slices were arranged to be perpendicular to the tibial plateau, and concentrated on the centre of the medial and lateral compartment of each knee. This sequence was chosen following testing of several suitable sequences, because of image clarity for measurement reliability, and speed. Acquisition speed was 35 seconds. MRI requires subjects to remain absolutely still. The commonly used diagnostic T1 weighted fast spin echo sequence acquired in 4 minutes 30 seconds, produced a fatigue tremor, even in the healthy subjects used for testing the method (Scarvell et al 2004). The load was limited to 150N, as a 300N load tested caused the MRI sled to pull through the machine. Consequently, the load and scanning time were optimum for this method.

The position of tibiofemoral contact on the tibial plateau was defined as the distance from the posterior tibial cortex to the point of contact of the tibia with the femur on the medial and lateral condyles respectively (Figure 1) (Scarvell et al 2004). Where contact occurred over a wider area, the area centroid was used. To account for variation in the size of subjects, the distance measurements were scaled to a tibial plateau of standard dimensions (being the mean tibial plateau dimensions). The reliability of this method of MR imaging of was previously tested in control subjects, including sources of error from choice of image slices to represent the centre of the medial or lateral compartment, and measurement error. With these sources of error both included tibiofemoral contact points were mapped reliably with both fast spin echo and gradient echo sequences with intraclass correlation (2,1) 0.96 (99% CI = 0.94 to 0.97) and 0.94 (99% CI = 0.91 to 0.97) respectively. With good reliability of both sequences, gradient echo was chosen for the kinematic study for its faster scanning time (Scarvell et al 2004).

Clinical variables recorded for each subject included

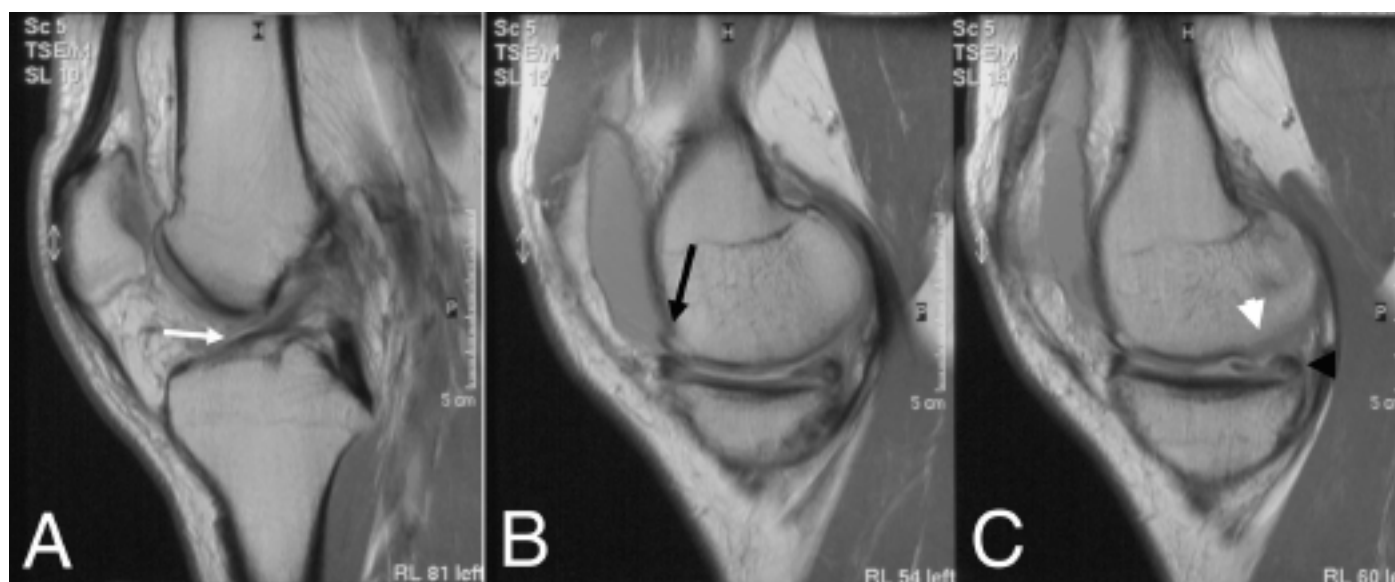


Figure 2: This sagittal T1 weighted MRI scan shows degenerative changes present in the medial compartment of the knee in a male subject with 12-year history of chronic ACL-deficiency. In the left image (A) can be seen a chronic ACL tear with attrition of remaining strands (white arrow), in the centre (B) and right images (C), medial compartment degenerative changes including osteophytes (black arrow), chronic tear of the posterior horn of the medial meniscus (black arrowhead), and damage to the articular surface of the femoral condyle (white arrowhead). There is also an effusion medial to the patella.

measurement of the passive anterior laxity of both knees, and the subjects' functional level. The KT 1000 arthrometer was used to measure passive anterior laxity, by quantifying the anterior displacement produced by the Lachman's manoeuvre (Daniel et al 1985). Anterior tibial displacement was measured in both knees five times: at 15 lb, 20 lb, 30 lb of force during anterior drawer, with a maximum manual force during anterior drawer and on active quadriceps muscle contraction.

The Cincinnati Knee Rating System (Barber-Westin et al 1999) was used to measure the symptoms, functional level and details of the physical examination. The maximum Cincinnati knee score is 100 for normal knees with full function (Barber-Westin et al 1999).

Articular cartilage degeneration in the ACL-deficient knees was measured from diagnostic MRI scans for all 23 subjects and also at arthroscopy for 12 subjects (Figure 2). 12 subjects had knee surgery following participation in the study, enabling the area and depth of articular cartilage lesions to be visualised at arthroscopy. For these 12 subjects the arthroscopy was within 4 weeks of the kinematic and diagnostic MRI scans. Meniscal and ligament damage was also recorded. Damage was recorded using Noyes' system for recording articular cartilage damage out of 100, where 100 is no articular cartilage damage, and 0 is full thickness lesions of at least 1.5 cm diameter in all three compartments, i.e. eburnated bone (Noyes and Stabler 1989).

The diagnostic MRI scans employed standard diagnostic sequences, including sagittal T1 and T2 weighted fast spin echo sequences, proton density, STIR, axial T2 and coronal T2 sequences. The images were reported by radiologists with particular expertise in musculoskeletal MRI. Arthroscopy is considered the gold standard for assessment of chondral and meniscal integrity whereas MRI may underestimate partial thickness chondral damage, particularly of degenerative

rather than acute focal lesions (Lundberg et al 1997, McCauley and Disler 2001, Spiers et al 1993). Therefore, for the 12 subjects who had both arthroscopic and MRI assessment of joint damage, the scores from the MRI and arthroscopic examinations were combined to give the worst case. For example, a partial depth lesion of 1.5 cm diameter on the MRI scan, but 2.0 cm at arthroscopy, was recorded as 2.0 cm in the combined score.

Statistical analysis Differences in the tibiofemoral contact pattern between the loaded and unloaded conditions, the ACL-deficient and healthy knee, and between medial and lateral compartments of the knees were tested using repeated measures ANOVA, for knee flexion at 0, 15, 30, 45, 60, 75, and 90 degrees.

Multivariate analysis was used to explore associations between tibiofemoral contact patterns in the healthy contralateral and ACL-deficient knees, and the articular cartilage degeneration evident in the ACL-deficient knees, and to control for age, sex and time since injury.

Results

Clinical variables The side-to-side difference measured by the KT 1000 arthrometer under an anterior drawer of 30 lb ranged from -1 to 10.5 mm (3.3 ± 2.9 , mean \pm SD), on activation of quadriceps ranged from -1 to 5.6 mm (2.2 ± 2.2 mm) and under a maximal manual anterior load ranged from 0 to 11 mm (4.6 ± 2.8 mm). Four subjects had a side-to-side difference of less than 3 mm, but all subjects had ACL tear confirmed by MRI. It is recognised that subjects with chronic ACL-deficiency may guard the knee from displacement during testing by contraction of the hamstrings, despite careful application by the examiner (Daniel et al 1985).

Cincinnati scores ranged from 44 to 81 (60.2 ± 11). The symptoms component of the score ranged from 7 to 34 out of

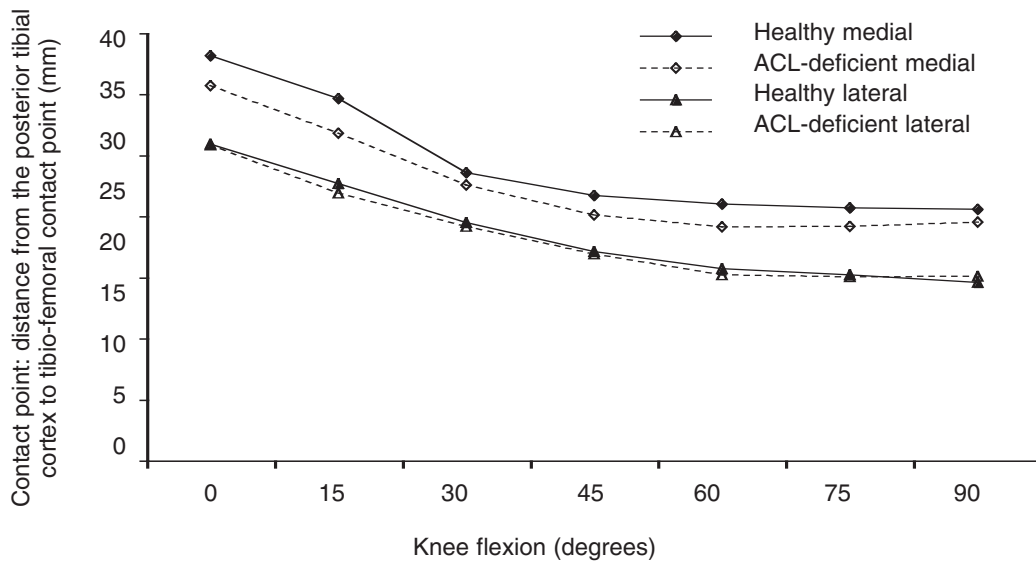


Figure 3: Tibiofemoral contact pattern for the loaded condition, comparing the healthy contralateral knees (solid line) and chronic ACL-deficient knees (broken line) (mean ± SE). The difference between healthy contralateral and chronic ACL-deficient knees was more pronounced in the medial compartment, with a more posterior position of contact on the tibial plateau.

40 (23 ± 8). At this functional level a subject would be able to do light work or sports without symptoms, but no running, twisting, or jumping. The subjects also rated the perceived condition of their knee on a visual analogue scale from 0 to 10, where 0 is extremely poor, 5 is fair, and 10 is normal. Subject self-rated scores ranged widely from 2 to 9 (5 ± 2).

Passive anterior laxity was not correlated with total Cincinnati knee scores ($r = -0.22, p = 0.54$), subjects' self-reported scores ($r = 0.07, p = 0.67$), or with the component of the Cincinnati score that indicates severity of symptoms (pain, giving-way etc, $r = 0.22, p = 0.22$).

Kinematics of chronic ACL-deficient knees Performing a leg press against a 150N load did not affect the tibiofemoral contact pattern. The contact pattern of the injured or the healthy knees while pressing was no different to the contact pattern while relaxed ($F_{(1,171)} = 1.23, p = 0.25$). The medial tibiofemoral contact pattern was different from the lateral contact pattern ($F_{(1,171)} = 196.36, p < 0.001$) for both the healthy and ACL-deficient knees.

The ACL-deficient knees showed a tibiofemoral contact pattern occurring posteriorly on the tibial plateau to the healthy contralateral knees ($F_{(1,171)} = 9.2, p = 0.003$) (Figure 3). The difference appeared more pronounced in the medial compartment ($F_{(1,171)} = 3.2, p = 0.07$), though this failed to reach significance. In the medial compartment with the knee loaded, the contact points of the ACL-deficient knees were a mean of 1.8 mm (± 3.2 mm) posterior on the tibial plateau compared to the contralateral healthy knees. This difference was largest at 0 degrees and 15 degrees knee flexion with mean contact points of 2.9 mm and 2.8 mm respectively, posterior. In the lateral compartment, the mean difference between the healthy and injured knees was negligible at 0.24 ± 3.1 mm at 0 degrees and remained negligible throughout knee flexion to 90 degrees (Figure 4).

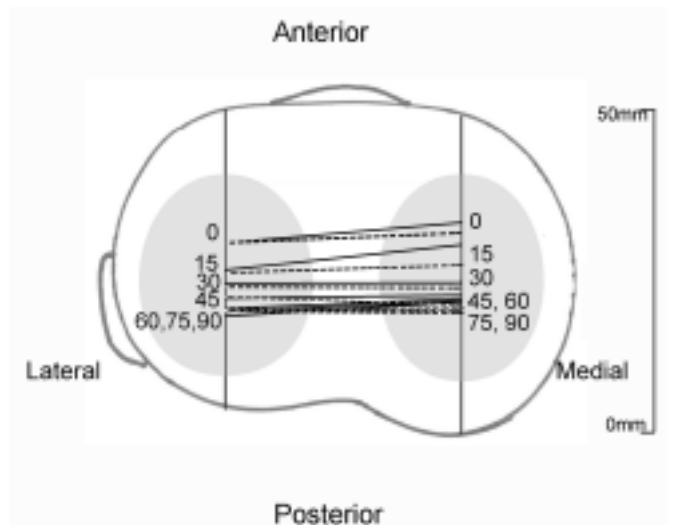


Figure 4: Diagram of the tibial plateau mapping tibiofemoral contact points between 0° and 90° of knee flexion for the loaded condition. The chronic ACL-deficient knees (broken line) showed a more posterior pattern of contact in the medial compartment than the healthy knees (solid line).

Degeneration of the articular cartilage in the chronic ACL-deficient knees reported on MRI and arthroscopy ranged widely from 20 to 100 out of 100 (72 ± 26). Five subjects had no evidence of degeneration, i.e. score of 100. Sixteen subjects had degeneration in the medial compartment and 12 had degeneration in the lateral compartment. Medial meniscal damage was identified in 16 subjects and lateral meniscal damage in 15 subjects (including tears, previous meniscectomy, and degenerative tears).

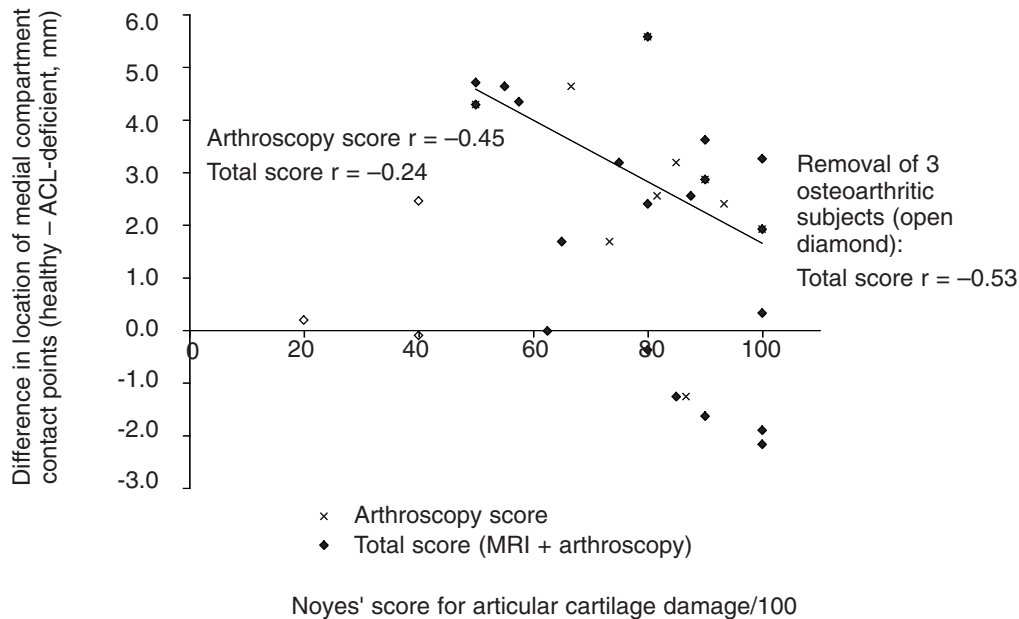


Figure 5: Correlation of altered knee kinematics in the medial compartment with articular cartilage damage in chronic ACL-deficient knees. The correlation between articular cartilage damage and altered kinematics was stronger for arthroscopy ($r = -0.45$), than when arthroscopic and MRI scores were used ($r = -0.24$). Three subjects (open diamond) had Noyes scores of 20 to 40/100, indicating extensive osteoarthritis. With these subjects removed the relationship between altered kinematics and degenerative change is strengthened ($r = -0.53$) suggesting osteoarthritis has a different influence on knee kinematics.

Articular cartilage degeneration recorded from examination of diagnostic MRI scans and arthroscopic assessment was weakly correlated with alteration in tibiofemoral contact pattern ($r = -0.24$, $p = 0.26$) (Figure 5). However, there were three outliers in this group of subjects. Three subjects had Noyes' scores of $\leq 40/100$, indicating advanced tricompartmental osteoarthritis. One subject with a Noyes score of 20 had a total knee replacement within three months of the study. The three subjects with advanced osteoarthritis had a smaller side-to-side difference in tibiofemoral contact patterns than the other chronic ACL-deficient subjects. With these three outliers excluded, there was a stronger and statistically significant correlation between kinematic changes and articular cartilage degeneration ($r = -0.54$, $p = 0.01$).

Age of subjects, sex of subjects, or time since injury was not associated with scores for articular cartilage degeneration. With all subjects included, time since injury was not correlated with articular cartilage degeneration in the knee ($r = -0.16$, $p = 0.65$). The length of time since injury did not correlate with subjects' symptoms ($r = -0.26$, $p = 0.46$), self-reported score ($r = 0.11$, $p = 0.77$) or total Cincinnati score ($r = -0.23$, $p = 0.52$). With three subjects with advanced osteoarthritis excluded, there was still no association seen between time since injury and articular cartilage degeneration ($r = 0.00$, $p = 0.99$). Age of subjects was poorly correlated with medial compartment contact pattern changes ($r = -0.25$, $p = 0.28$), and with articular cartilage degeneration ($r = -0.08$, $p = 0.74$). Sex of subjects was poorly correlated with changes to the contact pattern of the medial compartment ($r = -0.21$, $p = 0.37$), or articular cartilage degeneration ($r = -0.25$, $p =$

0.28). Consequently, the dominant relationship evident was that as contact pattern in the medial compartment changed, articular cartilage degeneration worsened.

Five subjects (four female and one male) had no evidence of articular cartilage degeneration or meniscal damage. They had sustained the original injury between 10 and 35 years earlier (19 ± 10 years). They had all ceased sports requiring cutting, pivoting, and running after the original ACL injury, but continued to keep fit in non-pivoting sports, such as running or swimming, once or twice per week. The Cincinnati knee scores for this group ranged from 61 to 74/100. Their symptom levels ranged from 24 to 30/40, i.e. moderate work or sports involving running with twisting or turning produced swelling, pain, or giving way. Self-reported knee condition ranged from 4 'fair' to 9 'almost normal' out of 10. Three subjects who were happy to continue with conservative management for the long term were health professionals. Two subjects who were not happy with the repeated episodes of instability and pain on activity subsequently had knee reconstruction surgery.

Discussion

Chronic ACL-deficient knees had an altered tibiofemoral contact pattern compared to healthy contralateral knees, particularly in the medial compartment of the knee. This contrasts with recently ACL-injured knees, in which the tibiofemoral contact pattern appears to be more posterior on the tibial plateau of the lateral compartment (Scarvell et al 2005). This suggests increased internal rotation of the tibia during flexion. Instability of the ACL-injured knee is seen as

anterior translation of the tibia during movement (Beard et al 2001, Vergis and Gillquist 1998). However, depending on the techniques used for kinematic analysis, this anterior translation is contributed to by more lateral compartment than medial translation and can be described as a rotational instability causing increased internal rotation of the tibia. A study of open-field MRI described increased translation of the lateral compartment in ACL-injured knees performing an active Lachman's test (Logan et al 2004). Internal rotation of the ACL-injured knee compared to the contralateral healthy knee was also noticed in subjects stepping up onto a box, using the highly invasive but accurate roentgen stereophotogrammetric analysis (RSA) (Brandsson et al 2001). However, there are no other published studies of contact pattern analysis chronic ACL-deficient knees *in vivo* with which to compare these findings of altered medial compartment contact patterns.

Differences in contact pattern between the recent and chronic injuries could reflect long-term damage to the knee resulting from chronic ACL-deficiency. In the absence of the ACL, the MCL becomes the primary restraint to both anterior motion and rotation of the tibia (Butler et al 1980), together with a contribution from the medial meniscus. In recently ACL-injured knees the rotational instability of the lateral compartment may cause a shift in the axis of rotation towards the medial side of the knee. Thus, in the absence of the ACL, the long axis of rotation of the knee appears to shift towards the MCL. In chronic ACL-deficient knees the secondary restraints to anterior and rotary tibial movement, the MCL and the medial meniscus, have probably assumed this role for many years (Allen et al 2000, Butler et al 1980) and it is possible that they have become attenuated. The tibiofemoral contact pattern might have been more altered in the medial compartment than the lateral compartment, because the attenuation of the secondary restraints has reduced the structural stability of the medial compartment.

The kinematic changes seen in the medial compartment contact pattern may produce more wear in the medial compartment of both articular cartilage and medial meniscus. In this study, the extent of joint damage was associated with changes to tibiofemoral contact pattern in the medial compartment. This cross-sectional study cannot, however, show causality. The pattern of damage in the medial compartment of the knee could be the result of increased load on secondary restraints in the ACL-deficient knee, causing shearing of the articular cartilage and trauma to the medial meniscus (Allen et al 2000). A meta-analysis found that the ratio of medial to lateral meniscal damage in chronic ACL-deficient knees was 70:30 (Bellabarba et al 1997). When the menisci are incompetent for load distribution, shock absorption or cartilage nutrition, the articular cartilage surface is subject to damage and the consequent degeneration is very well described (Casscells 1978, Kurosawa et al 1980). Thus, it appears that the degenerative changes occurring in the medial compartment are associated with altered medial compartment kinematics.

The role of shear forces in degeneration is controversial. Some researchers deny that instability causes osteoarthritic changes (Burr and Radin 1990). They argue that ACL-deficient knees will not develop osteoarthritic changes unless the menisci are damaged (Burr and Radin 1990). Other researchers, using dogs to study ACL-deficiency, found osteoarthritic changes in all dogs at 34 weeks (Lopez and Markel 2003). In humans, osteophytes and superficial

destruction of the cartilage are likely at 10 years after ACL injury and significant osteoarthritis is likely by 20 to 30 years (Dejour et al 1994). These rates are influenced by the damage to the menisci, so that if both the ACL and medial meniscus are damaged, the rate of degeneration is higher than if only one structure is damaged.

We did not find a correlation between time since injury and changes in knee kinematics. In the gait analysis study of Wexler et al (1998), increased anterior translation of the tibia in stance phase of walking, and the magnitude of translation were associated with time since injury. It was suggested that increased anterior translation indicated the attenuation of the secondary restraint structures of the joint. In our study, time since injury was not a factor in the association of kinematics with articular cartilage degeneration.

Nor did we find a correlation between time since injury and articular cartilage degeneration. Myers et al (2001) found in a retrospective study of 541 subjects that medial compartment changes, either to chondral cartilage or menisci, were proportional to time since injury, but chondral impact trauma at the time of injury accounted for lateral compartment damage. Bellabarba et al (1997) also related medial compartment changes to time since injury. These retrospective studies support the association between chronicity of ACL-deficiency and medial compartment degeneration and appear to give credence to the concept of disturbance in tibiofemoral contact influencing degenerative change. The present study suggests that it is not time that influences degenerative change, but rather it is altered kinematics.

This study is a cross sectional design and consequently cannot demonstrate whether articular cartilage degeneration was the result of altered contact patterns, or vice versa. A prospective cohort study of patients with discrete ACL-injury and no meniscal or chondral damage may contribute to this. Nor can this study inform the physiotherapy community whether retraining the neuromuscular dynamic stability of the lower limb will reduce the risk of osteoarthritis for the patient, though it is possible, based on the relationship between aberrant kinematics and degenerative change. Those studies remain to be done.

A further limitation to this study is that a supine leg-press is not an activity that fully represents the dynamic demands of a weight bearing joint. A landing jump or standing squat would be more representative of the kinds of loads and forces experienced by the knee. The load of 150N was limited by the sled of the MRI, which was pulled through the machine by greater loads applied to the rope and pulley (Scarvell et al 2004). However, within the limitations of a conventional MRI machine, a closed-chain leg-press against 150N load provides a context for the activation of the lower limb musculature in an environment not unlike that of knee rehabilitation protocol.

The tibiofemoral contact pattern of chronic ACL-deficient knees was different from healthy knees. This difference was particularly evident in the medial compartment of the knee, and particularly at 0 degrees and 15 degrees of knee flexion. These kinematic consequences of chronic ACL-deficiency may in part be responsible for the pattern of degenerative change, but could be the result of degenerative change, particularly in the medial compartment of the knees.

Footnote ^aSiemens AG, Munich, Federal Republic of Germany.

Acknowledgements The MRI imaging in this paper owes much to the skill of Dianne Lane, radiographer. Dr Bruce Shadbolt assisted with research design and statistics. Thank you to the subjects for their generosity of time and their knees.

Correspondence Dr JM Scarvell, Physiotherapy, School of Health Sciences, University of Canberra, ACT 2601. Email: jennie.scarvell@canberra.edu.au

References

- Allen C, Wong E, Livesay G, Sakane M, Fu F and Woo S (2000): Importance of the medial meniscus in the anterior cruciate ligament-deficient knee. *Journal of Orthopaedic Research* 18: 109–115.
- Barber-Westin S, Noyes F and McCloskey J (1999): Rigorous statistical reliability, validity, and responsiveness testing of the Cincinnati knee rating system in 350 subjects with uninjured, injured, or anterior cruciate ligament reconstructed knees. *American Journal of Sports Medicine* 27: 402–416.
- Beard D, Murray D, Gill H, Price A, Rees J, Alfaro-Adrian J and Dodd C (2001): Reconstruction does not reduce tibial translation in the cruciate-deficient knee. An in vivo study. *Journal of Bone and Joint Surgery (Br)* 83: 1098–1103.
- Beard D, Soundarapandian R, O'Connor J and Dodd C (1996): Gait and electromyographic analysis of anterior cruciate ligament deficient subjects. *Gait and Posture* 4: 83–88.
- Bellarbarba C, Bush-Joseph C and Bach B (1997): Patterns of meniscal injury in the anterior cruciate-deficient knee: a review of the literature. *American Journal of Orthopedics* 26: 18–23.
- Beynon B, Fleming B, Churchill D and Brown D (2003): The effect of anterior cruciate ligament deficiency and functional bracing on translation of the tibia relative to the femur during non weightbearing and weightbearing. *American Journal of Sports Medicine* 31: 99–105.
- Brandsson S, Karlsson J, Eriksson B and Karrholm J (2001): Kinematics after tear in the anterior cruciate ligament: dynamic bilateral radiostereometric studies in 11 patients. *Acta Orthopaedica Scandinavica* 72: 372–378.
- Burr D and Radin E (1990): Trauma as a factor in the initiation of osteoarthritis. In Brandt K (Ed.): *Changes in Osteoarthritis*. Indiana: Indiana University School of Medicine, pp. 73–80.
- Butler D, Noyes F and Grood E (1980): Ligament restraints to anterior drawer in the human knee. *Journal of Bone and Joint Surgery (Am)* 62-A: 259–270.
- Casscells S (1978): The torn or degenerated meniscus and its relationship to degeneration of the weight bearing areas of the femur and tibia. *Clinical Orthopaedics and Related Research* 132: 196–200.
- Clatworthy M and Amendola A (1999): The anterior cruciate ligament and osteoarthritis. *Clinics in Sports Medicine* 18: 173–198.
- Daniel D, Malcolm L and Losse G (1985): Instrumented measurement of anterior laxity of the knee. *Journal of Bone and Joint Surgery (Am)* 67-A: 720–726.
- Dejour H, Neyret P and Bonnin M (1994): Instability and osteoarthritis. In Fu F, Harner C and Vince K (Eds): *Knee Surgery*. Baltimore: Williams and Wilkins.
- Ellenbecker TS (2000): *Knee Ligament Rehabilitation*. New York: Churchill Livingstone.
- Fetto J and Marshall J (1980): The natural history of diagnosis of anterior cruciate ligament insufficiency. *Clinical Orthopaedics and Related Research* 147: 29–37.
- Finsterbush A, Frankl U, Matan Y and Mann G (1990): Secondary damage to the knee after isolated injury of the anterior cruciate ligament. *American Journal of Sports Medicine* 18: 475–479.
- Frankel V, Burstein A and Brooks D (1971): Biomechanics of internal derangement of the knee. *Journal of Bone and Joint Surgery (Am)* 53-A: 945–962.
- Friden T, Egund N and Lindstrand A (1993): A comparison of symptomatic versus non symptomatic patients with chronic anterior cruciate ligament insufficiency. Radiographic sagittal displacement during weight-bearing. *American Journal of Sports Medicine* 21: 389–393.
- Georgoulis A, Papadonikolakis A, Papageorgiou C, Mitsou A and Stergiou N (2003): Three-dimensional tibiofemoral kinematics of the anterior cruciate ligament deficient and reconstructed knee during walking. *American Journal of Sports Medicine* 31: 75–79.
- Harman M, Markovich G, Banks S and Hodge W (1998): Wear patterns on tibial plateaus from varus and valgus osteoarthritic knees. *Clinical Orthopaedics and Related Research* 352: 149–158.
- Hollman J, Deusinger R, Van Dillen L and Matava M (2002): Knee joint movements in subjects without knee pathology and subjects with injured anterior cruciate ligaments. *Physical Therapy* 82: 960–972.
- Johnson D, Bealle D, Brand J, Nyland J and Caborn D (2000): The effect of a geographic lateral bone bruise on knee inflammation after acute anterior cruciate ligament rupture. *American Journal of Sports Medicine* 28: 152–155.
- Kurosawa H, Fukubayashi T and Nakajima H (1980): Load-bearing model of the knee joint: Physical behaviour of the knee joint with or without menisci. *Clinical Orthopaedics and Related Research* 149: 283–290.
- Lahm A, Erggelet C, Steinwachs and Reichelt A (1998): Articular and osseous lesions in recent ligament tears: Arthroscopic changes compared with magnetic resonance imaging findings. *Arthroscopy* 14: 597–604.
- Logan M, Willimas A, Lavelle J, Gedroyc W and Freeman M (2004): What really happens during the Lachman test? A dynamic MRI analysis of tibiofemoral motion. *American Journal of Sports Medicine* 32: 369–375.
- Lopez M and Markel M (2003): Anterior cruciate ligament rupture after thermal treatment in a canine model. *American Journal of Sports Medicine* 31: 164–167.
- Lundberg M, Thuomas K and Messner K (1997): Evaluation of knee joint cartilage and menisci ten years after isolated and combined ruptures of the medial collateral ligament. Investigation by weight-bearing radiography, MRI and analysis of proteoglycan fragments in the joint fluid. *Acta Radiologica* 38: 151–157.
- McCauley T and Disler D (2001): Magnetic resonance imaging of articular cartilage of the knee. *Journal of the American Academy of Orthopaedic Surgeons* 9: 2–8.
- McDaniel W and Dameron T (1980): Untreated rupture of the anterior cruciate ligament. *Journal of Bone and Joint Surgery (Am)* 62-A: 696.
- Myers P, Fox H and Swanson C (2001): Chondral and meniscal lesions in the ACL deficient knee: Time from injury vs extent of damage. *Journal of Bone and Joint Surgery (Br)* 83: 321.
- Noyes F and Stabler C (1989): A system for grading articular cartilage lesions at arthroscopy. *American Journal of Sports Medicine* 17: 505–508.
- Sakane M, Livesay G, Fox R, Rudy T, Runco T and Woo S (1999): Relative contribution of the anterior cruciate ligament, medial collateral ligament and bony contact to the anterior stability of the knee. *Knee Surgery, Sports Traumatology and Arthroscopy* 7: 93–97.
- Scarvell J, Smith P, Refshauge K, Galloway H and Woods K (2004): Evaluation of a method to map tibiofemoral contact points using MRI. *Journal of Orthopaedic Research* 22: 788–793.

- Scarvell J, Smith P, Refshauge K, Galloway H and Woods K (2005): Comparison of kinematics in the healthy and ACL injured knee using MRI. *Journal of Biomechanics* 38: 255–262.
- Segawa H, Omori G and Koga Y (2001): Long-term results of non-operative treatment of anterior cruciate ligament injury. *Knee* 8: 5–11.
- Snyder-Mackler L, Fitzgerald G, Bartolozzi A and Cicotti M (1997): The relationship between passive joint laxity and functional outcome after anterior cruciate ligament injury. *American Journal of Sports Medicine* 25: 191–195.
- Spiers A, Meagher T, Ostlere S, Wilson D and Dodd C (1993): Can MRI of the knee affect arthroscopic practice? *Journal of Bone and Joint Surgery (Br)* 75: 49–52.
- Vergis A and Gillquist J (1998): Sagittal plane translation of the knee during stair walking. Comparison of healthy subjects with anterior cruciate ligament deficient subjects. *American Journal of Sports Medicine* 26: 841–846.
- Wexler G, Hurwitz D, Bush-Joseph C, Andriacchi T and Bach B (1998): Functional gait adaptations in patients with anterior cruciate ligament deficiency over time. *Clinical Orthopaedics and Related Research* 348: 166–175.