



## Transthyretin levels in the vitreous correlate with change in visual acuity after vitrectomy

E Van Aken, E A De Letter, M Veckeneer, et al.

*Br J Ophthalmol* 2009 93: 1539-1545 originally published online August 18, 2009

doi: 10.1136/bjo.2009.158048

---

Updated information and services can be found at:

<http://bjo.bmj.com/content/93/11/1539.full.html>

---

*These include:*

**References**

This article cites 25 articles, 8 of which can be accessed free at:

<http://bjo.bmj.com/content/93/11/1539.full.html#ref-list-1>

**Email alerting service**

Receive free email alerts when new articles cite this article. Sign up in the box at the top right corner of the online article.

---

**Notes**

---

To order reprints of this article go to:

<http://bjo.bmj.com/cgi/reprintform>

To subscribe to *British Journal of Ophthalmology* go to:

<http://bjo.bmj.com/subscriptions>

# Transthyretin levels in the vitreous correlate with change in visual acuity after vitrectomy

E Van Aken,<sup>1</sup> E A De Letter,<sup>2</sup> M Veckeneer,<sup>3</sup> L Derycke,<sup>4</sup> T van Enschot,<sup>5</sup> I Geers,<sup>5</sup> S Delanghe,<sup>5</sup> J R Delanghe<sup>5</sup>

<sup>1</sup> Department of Ophthalmology, University Hospital Ghent, Ghent, Belgium; <sup>2</sup> Department of Forensic Medicine, University Hospital Ghent, Ghent, Belgium; <sup>3</sup> Rotterdam Eye Hospital, Rotterdam, The Netherlands; <sup>4</sup> Upper Airway Research Laboratory, University Hospital Ghent, Ghent, Belgium; <sup>5</sup> Department of Clinical Chemistry, University Hospital Ghent, Ghent, Belgium

Correspondence to:  
Dr E Van Aken, Department of Ophthalmology, University Hospital Ghent, De Pintelaan 185, B-9000 Ghent, Belgium; [elisabeth.vanaken@ugent.be](mailto:elisabeth.vanaken@ugent.be)

Accepted 3 July 2009  
Published Online First  
18 August 2009

## ABSTRACT

**Background/aim:** Little is known about biochemical markers related to change in visual acuity after vitrectomy. The potential use of transthyretin (TTR), a carrier of the retinol/retinol-binding protein, as a biochemical marker protein, was investigated.

**Methods:** TTR was measured using immunonephelometry in a group of patients (n = 77) in longstanding (>1 week) retinal detachment (n = 29), fresh (<1 week) retinal detachment (n = 17), macular holes (n = 20) or diabetic retinopathy (n = 11). Vitreous samples were taken at the start of every vitrectomy procedure. For reference values, cadaver specimens (n = 73) were used.

**Results:** Reference values for vitreous TTR (median 18 mg/l; IQR 4 to 24 mg/l) comprised 2.2% of reference values for vitreous protein levels (median 538 mg/l; IQR 269 to 987 mg/l). Vitreous TTR values of patients were comparable in all disorders. Vitreous TTR values were higher in phakic (median 22.5 mg/l; IQR 10 to 27 mg/l) than in pseudophakic patients (median 12 mg/l; IQR 8 to 19 mg/l; p = 0.06). Postoperative change in visual acuity correlated well with vitreous TTR values found preoperatively (r<sub>s</sub> = 0.408; p = 0.012). Both change in visual acuity and lens status were the only variables which proved to explain the variance of TTR (multiple correlation coefficient: 0.494; phakic status: t = 2.767; p = 0.0084; and change in visual acuity t = 2.924; p = 0.0056).

**Conclusion:** Vitreous fluid concentrations of TTR can be regarded as a biochemical marker for retinal function.

Transthyretin (TTR) is a 55 kDa homotetrameric protein with a dimer configuration that is synthesised in the liver, choroid plexus, visceral yolk sac and retinal pigment epithelium. Each monomer is a 127-residue polypeptide rich in beta sheet structure. Association of two monomers forms an extended beta sandwich. Further association of another identical set of monomers produces the homotetrameric structure. In serum, it functions as a carrier for thyroxine and retinol-binding protein (RBP). It has two thyroxine-binding sites per tetramer at the interface between the latter set of dimers, and two binding sites for RBP on the outer surface. As a carrier protein for thyroxine in serum, it acts in concert with thyroxine-binding globulin and albumin. Retinol is transported bound to RBP, which itself is bound to TTR.<sup>1</sup> RBP has a higher affinity for TTR when it is bound to a retinol ester.<sup>2</sup> The transport of protein-bound ligands across lipid-water interfaces, such as cell membrane surfaces, is thought to involve obligatory dissociation of protein-bound ligand into the free state before transmembrane transport.<sup>3</sup> The retinol-RBP-TTR complex cannot pass freely through

cell membranes. STRA6 is a multitransmembrane domain protein functioning as the high-affinity tissue receptor for plasma RBP and mediating cellular uptake of vitamin A from the vitamin A-RBP complex.<sup>4</sup> It has been suggested that formation of the complex between TTR and single, or multiple, RBP molecules prevents renal clearance of the retinol/RBP complex.<sup>5</sup>

In the eye, TTR is bound to retinol and RBP in various ocular tissues. In contrast to retinol, which is derived solely from the serum, TTR is synthesised locally. Plasma TTR does not cross the Bruch membrane into the retina. Ocular TTR is synthesised in the retinal pigment epithelium (RPE) and in the pigmented epithelium of the ciliary body, the corneal endothelium and the optic nerve fibre layer of the retina, and is transported to specific locations within the eye.<sup>6-8</sup> Although the physiological role of TTR in the eye is unknown, it is possible that it participates in retinol cycling.

TTR can be deposited as amyloid fibrils in senile systemic amyloidosis (SSA) and familial amyloid polyneuropathy (FAP). At least 20 TTR mutations are associated with amyloidosis.<sup>9</sup> Vitreous amyloid fibrils are the result of local synthesis of mutated TTR. Nuclear cataract is associated with low protein intake and low serum levels of TTR.<sup>10</sup> Immunohistochemical analysis of drusen in patients with age-related macular degeneration showed the presence of TTR.<sup>11</sup> Comparison of aqueous humour between myopic and non-myopic patients showed a higher TTR level in the former.<sup>12</sup>

There exist no biochemical markers to differentiate between patients with excellent and poorer visual acuity after vitrectomy. Little is known about the TTR concentrations in normal and pathological human vitreous fluid. As there are no known reports of humans lacking TTR, the importance of TTR to vision has not been described. In view of the presumed key role of TTR in the vitamin A cycle, we wanted to explore the use of TTR in human vitreous fluid as a biochemical marker protein for retinal function.

## MATERIALS AND METHODS

### Subjects

Vitreous samples obtained from human cadavers (n = 73), obtained through a vitreous tap 4 mm from the limbus in the temporal upper or lower quadrant, were used for establishing reference values for TTR. In table 1, the age, sex, post-mortem interval and possible pre-existing diseases are provided. The median postmortem interval was 1.5 days (IQR 0.9 to 2.4 days). In addition, the cause, mechanism and manner of death of each

## Laboratory science

**Table 1** Overview of the postmortem reference group: control cases; n = 73; age (years)

Case no	Age (years)	Sex	Postmortem interval (days)	Cause of death	Mechanism of death	Manner of death	Important pre-existing disease(s)
1	62	Female	± 2.50	Gunshot cal 9 mm	Internal bleeding, HV shock	Criminal	Coronary bypass, generalised ATH, diabetes not excluded
2	82	Female	± 1.00	Parathion intoxication	Letal ACH inhibition	Suicide	Depression
3	47	Male	± 1.00	Gastrointestinal bleeding	Internal bleeding, HV shock	Natural	Alcohol abuse
4	21	Male	3.13	Drowning	Mechanical asphyxia	Accidental	None
5	39	Male	± 1.5	Gunshot pistol cal 7.65	Craniocerebral trauma	Criminal	Liver steatosis
6	40	Male	3.13	Fall from stairs	Subdural bleeding	Accidental	Slight CH (muscular)
7	31	Male	2.65	MDMA intoxication	CP failure	Accidental	Chronic pyelonephritis
8	14	Female	3.52	Diving trauma	Drowning	Accidental	None
9	38	Male	2.49	Stab wound	Internal bleeding, HV shock	Criminal	None
10	26	Female	± 7 to 8	Intoxication	Hypoxic encephalopathy; pulmonary infection	Accidental	Cachexia; survival following intoxication (± 1 month)
11	60	Male	1.42	Multiple blunt trauma	Craniocerebral trauma	Criminal	Alcohol abuse; liver steatosis; ATH aorta (third degree)
12	68	Female	1.80	Traffic accident	Polytrauma	Accidental	ATH aorta (third degree)
13	58	Female	4.51	Polydrug intoxication	CP failure	Accidental	CH (muscular); pulmonary HT; generalised ATH
14	42	Female	0.83	Shotgun cal 12	Internal bleeding, HV shock	Criminal	None
15	53	Male	1.83	Shotgun cal 12	Internal bleeding, HV shock	Criminal	ATH aorta abdominalis (third degree); pulmonary HT
16	33	Female	2.01	Strangulation	Mechanical asphyxia	Criminal	None
17	83	Female	0.83	Multiple blunt trauma	CP failure; HV shock	Criminal?	ATH aorta (third degree); non-recent pyelonephritis
18	55	Male	1.40	Multiple blunt trauma on head	Cerebral death	Criminal	CH (muscular); ATH aorta (third degree)
19	56	Male	0.88	High GI bleeding	Internal bleeding, HV shock	Natural	Alcohol abuse
20	73	Male	1.77	Entrapment in lift shaft	Craniocerebral trauma	Accidental	Liver steatosis; generalised ATH (eg, 2-branch coronary)
21	45	Female	1.39	Strangulation	Mechanical asphyxia	Criminal	benign nephrosclerosis Liver steatosis; chronic thyroiditis
22	42	Female	1.83	Fall from height	Polytrauma, HV shock	Suicide	Psychiatric patient
23	54	Male	± 1.50	Disordered DM type I	Diabetic ketoacidosis	Natural	DM type I
24	65	Male	3.56	Traffic accident	Craniocerebral trauma	Accidental	CH (three-branch coronary sclerosis; ischaemic cardiomyopathy) liver steatosis; generalised ATH
25	80	Male	1.25	Hammer blows on head and stab wounds to neck	Craniocerebral trauma; HV shock	Criminal	DM type II, CH (1-branch coronary sclerosis); benign nephroangiosclerosis; generalised ATH (aorta, cerebral vessels)
26	59	Male	0.25	Undetermined	Cardiopulmonary failure	Natural	Unspecified cardiac complaints
27	42	Female	1.15	Multiple stab wounds (knife)	External and internal bleeding; HV shock Cardiac tamponade	Criminal	Chronic pulmonary emphysema and pulmonary HT
28	52	Male	0.83	Polydrug intoxication	CP failure	Accidental	Alcohol and drug abuse
29	34	Male	0.85	Multiple stab wounds (knife)	Internal bleeding; HV shock	Criminal	Alcohol abuse; liver steatosis; non-recent cerebral contusions
30	39	Female	1.27	Multiple stab wounds (knife) and fall from height	Polytrauma and cardiac tamponade	Criminal	Drepanocytosis; subacute pyelonephritis
31	21	Male	2.04	Polydrug intoxication	CP failure	Accidental?	Chronic intravenous drug abuse (cf, foreign-body granulomata lungs; hypertrophy LN); CH (muscular)
32	66	Male	1.50	Gastrointestinal bleeding	HV shock	Natural	DM type II; alcohol abuse; arterial HT
33	58	Male	0.84	Shotgun cal 20	Brain stem laceration	Criminal	Liver steatosis; CH (muscular); ATH; pulmonary HT
34	35	Male	0.66	Polydrug intoxication	CP failure	Accidental	Alcohol and drug abuse
35	39	Male	3.27	Cardiac pathology	CP failure	Natural	CH (three-branch coronary sclerosis; ischaemic cardiomyopathy)
36	62	Female	1.00	Fall from stairs and hypothermia	Craniocerebral trauma	Accidental	None
37	53	Female	1.66	Fall from height	Polytrauma	Suicide	Pulmonary HT; non-specific chronic hepatitis (medication-related?); depression
38	49	Male	± 3.00	Hypothermia	HV shock	Accidental	Alcohol abuse
39	29	Male	0.50	Hanging	Mechanical asphyxia	Suicide	None

Continued

Table 1 Continued

Case no	Age (years)	Sex	Postmortem interval (days)	Cause of death	Mechanism of death	Manner of death	Important pre-existing disease(s)
40	53	Male	0.42	Polydrug intoxication	CP failure	Accidental	DM type II; alcohol abuse; arterial HT
41	84	Female	±0.56	Cachexia: extreme negligence	Bronchiolitis, Hypoglycaemia, dehydration	Undetermined	Chronic peptic oesophagitis; chronic pyelonephritis; generalised ATH
42	46	Male	±2.00	Alcohol intoxication and fall	HV shock	Undetermined	Chronic pulmonary emphysema and HT; alcohol abuse (liver steatosis and pancreas fibrosis); ATH aorta
43	20	Female	1.66	Manual strangulation and blunt trauma	Mechanical asphyxia	Criminal	None
44	19	Male	±2.70	Disorder DM type I	Diabetic ketoacidosis	Natural	DM type I
45	43	Male	±3.50	Polydrug intoxication	CP failure	Accidental	CH (muscular); liver steatosis
46	47	Female	1.29	Cardiac pathology	CP failure (cf, anteroseptal infarction)	Natural	CH (three-branch coronary sclerosis); angor pectoris
47	25	Female	3.83	Arthroscopy	Multiple lung embolism	Accidental	None
48	37	Female	1.27	Hammerblows on head	Cranio-cerebral trauma	Criminal	None
49	66	Male	0.50	Hanging over iron wire	Mechanical asphyxia (positional)	Accidental	Epilepsy; alcohol abuse
50	28	Male	±0.20	DM type I: hypoglycaemia	CP failure	Natural	DM type I
51	38	Male	1.29	Thoracic stab wound	HV shock	Suicide	CH (one-branch coronary sclerosis); liver steatosis
52	62	Male	2.74	Fall from height	Polytrauma; HV shock	Accidental	Alcohol abuse; liver steatosis; psychiatric problems
53	35	Female	±2.35	Stab wounds knife and manual strangulation	Mechanical asphyxia and HV shock	Criminal	Slight CH; non-specific portitis; localised pancreatitis; chronic intravenous drug abuse
54	26	Male	±0.50	Gunshot pistol cal .45	Cranio-cerebral trauma	Suicide	Depression
55	51	Male	±0.50	Ethanol intoxication	(Sub)acute CP failure	Accidental	DM type I; chronic alcohol abuse; NB: no hypoglycaemia at the time of death
56	92	Female	±2.73	Sudden cardiac death	(Sub)acute CP failure	Natural	Non-recent nephrectomy right and stenting right carotid artery; arterial HT; benign nephrosclerosis left kidney
57	46	Female	±1.25	Hanging	Mechanical asphyxia	Suicide	Slight pulmonary HT; liver steatosis; depression
58	8	Male	±1.66	Strangulation	Mechanical asphyxia	Murder	Slight CH (muscular)
59	44	Male	±0.75	Fall from stairs	Cranio-cerebral trauma	Accidental	Alcohol and drug abuse
60	27	Male	7.79	Hanging	MOF; hypoxic encephalopathy	Suicide	CH (muscular); chronic active hepatitis C
61	24	Male	±0.50	Polydrug intoxication	CP failure	Suicide	Depression
62	26	Female	±1.00	CO intoxication and disordered DM type I	CP failure (CO and ketoacidosis)	Accidental	DM type I (including diabetic feet); spina bifida
63	46	Male	±3.00	Multiple blunt trauma	Cranio-cerebral trauma	Criminal	CH (muscular); liver steatosis; old trauma capitis and non-recent subdural haematoma
64	77	Male	±2.50	Hypothermia	CP failure	Accidental	Cachexia; ATH (LAD, cerebral vessels) benign nephrosclerosis; pulmonary HT
65	11	Female	0.94	Anaphylactic shock (during anaesthesia)	HV shock	Natural	Strabismus
66	51	Male	1.25	Stab wounds abdomen	Internal bleeding; HV shock	Criminal	Alcohol abuse; generalised ATH; CH (three-branch coronary atherosclerosis)
67	46	Male	±0.50	Polydrug intoxication	(Sub)acute CP failure	Suicide	Alcohol abuse; psychiatric patient
68	61	Male	±0.20	Undetermined	CP failure	Natural	DM type II, chronic obstructive pulmonary disease, arterial HT; alcohol abuse
69	36	Male	±1.66	Undetermined	CP failure	Natural	DM type I
70	59	Male	±1.25	Gastrointestinal bleeding	CP failure and HV shock	Natural	Chronic non-steroid anti-inflammatory drug use for lower-back pain; arterial HT
71	33	Male	4.27	Intoxication (cocaine, ethanol)	CP failure due to VF	Accidental	CH (muscular and two-branch atherosclerotic coronary disease)
72	46	Male	0.25	Undetermined	CP failure	Natural	Hypercholesterolaemia
73	71	Female	±1.00	Positional asphyxia	Mechanical asphyxia	Accidental	Chronic venous ulcers both legs

ACH, acetylcholinesterase; ATH, atherosclerosis; cal, calibre; DM, diabetes mellitus; CH, cardiac hypertrophy; CP, cardiopulmonary failure; HT, hypertension; HV, hypovolaemic shock.

**Table 2** Characteristics of patients

	Retinal detachment >1 week	Retinal detachment <1 week	Advanced proliferative diabetic retinopathy	Macular hole stage 3
No	29	17	11	20
Age (range)	71 (61 to 79)	57 (51 to 69)	56 (50 to 59)	71 (61 to 74)
Phakic	15 (52%)	6 (35%)	6 (55%)	14 (70%)
Men	13 (45%)	8 (47%)	7 (64%)	7 (35%)

individual are specified. Furthermore, we analysed 77 freshly collected vitreous fluid samples submitted to our laboratory. Samples were collected by two vitreoretinal surgeons (MV in the Rotterdam Eye Hospital, The Netherlands, and EVA in Ghent University Hospital, Belgium). A vitreous tap of 0.5 ml was performed at the start of every vitrectomy procedure via a syringe connected to the collecting cannula of the vitreous cutter. All samples were immediately stored at 4°C. Informed consent was obtained from each patient. According to diagnosis, the patient could be divided in longstanding retinal detachment (n = 29), fresh retinal detachment (n = 17), macular holes (n = 20) or advanced proliferative diabetic retinopathy (n = 11). As definitions, we used: "longstanding retinal detachment" for retinal detachments of patients with typical symptoms for a retinal detachment for at least 1 week before surgical intervention, "fresh retinal detachment" for retinal detachments of patients with typical symptoms for a retinal detachment for less than 1 week before surgical intervention, "macular hole" for stage 3 (>400 µm) macular holes characterised by OCT existing more than 6 months and "advanced proliferative diabetic retinopathy" for patients with a fundus partially obscured by vitreous haemorrhage according to ETDRS standards.<sup>13</sup> Pre- and postoperative visual acuity are measured using Snellen charts at 6 m.

### Biochemical investigations

TTR was measured immunonephelometrically on undiluted vitreous fluid samples using commercially available Behring antibodies on a Behring Nephelometer II analyser (Dade Behring) standardised against the widely accepted WHO/

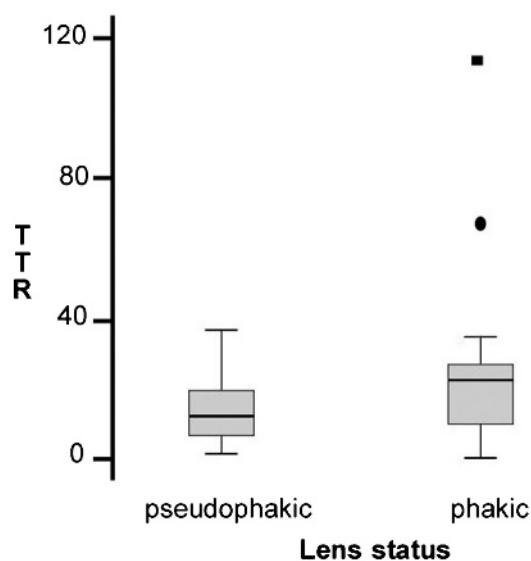
College of American Pathologists Certified Reference Material 470. Total protein in vitreous fluid was measured by the Pyrogallol Red method (n = 129) with Standard Reference Material 917a as a standard and commercially available reagents (Instruchemie, Delfzijl, The Netherlands) on a Modular P system (Roche).<sup>14</sup> The 2.5 and 97.5 percentiles of the human cadaver specimens were used for calculating the reference interval. All samples were kept frozen at -20°C until analysis. The between-run coefficient of variation was 5.86%, and the detection limit was 3.35 mg/l.

### Clinical investigations

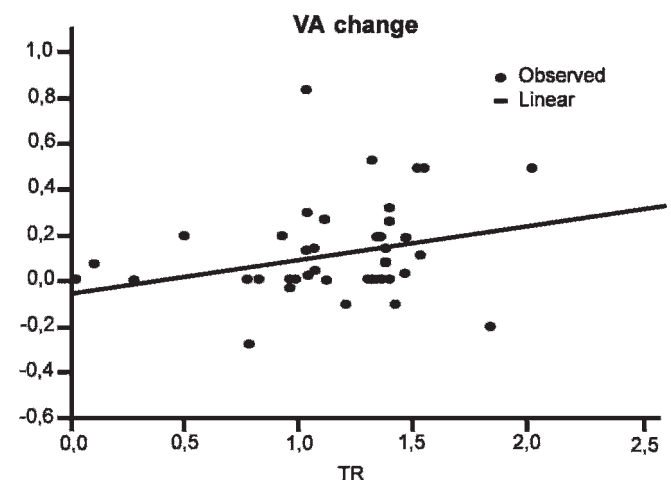
In the patient group, best-corrected visual acuity (Snellen) was evaluated before and 3–4 months after vitrectomy. The diagnosis of all preoperative conditions was made by funduscopy by a trained vitreoretinal surgeon. Additionally, optical coherence tomography (OCT) was performed for patients presenting with a macular hole. Patients who had undergone cataract surgery before were defined as "pseudophakic." Patients who had not yet undergone cataract surgery or had cataract surgery simultaneously with the vitrectomy were defined as "phakic." Characteristics of patients are found in table 2.

### Statistics

All p values <0.05 were considered significant. Agreement between data was evaluated using the Spearman rank analysis. The lower limit of detection was calculated as the mean value -3 SD for a blank sample. Diagnostic accuracy was assessed by ROC analysis using commercially available statistical software



**Figure 1** Box-whisker plots for transthyretin (TTR) values in vitreous samples of patients. Comparison between TTR values of pseudophakic and phakic patients. p = 0.064; Mann-Whitney U test.



**Figure 2** Correlation between vitreous transthyretin (TTR) concentration in patients and change in visual acuity (VA) postoperatively. Agreement was fair between the TTR concentration (x) and the sight measurements (y). The following regression equation was obtained:  $y$  (Snellen) =  $0.0462 + 0.0042 \log X$  (mg/l); Spearman rho = 0.408; p = 0.012; 95% confidence interval 0.106 to 0.641.

**Table 3** Preoperative visual acuity (VA), postoperative VA and change in VA for all patients individually in Snellen (6 m)

	VA preoperatively	VA postoperatively	Change in VA
Retinal detachment	0.1	0.9	0.8
>1 week (n = 29)	0.7	1.0	0.3
	0.2	0.7	0.5
	0.003	0.017	0.014
	0.16	0.3	0.14
	0.1	0.1	0
	0.05	0.9	0.85
	0.05	0.7	0.65
	0.003	0.4	0.397
	0.02	0.6	0.58
	0.003	0.02	0.017
	0.003	0.2	0.197
	0.7	0.7	0
	0.003	0.2	0.197
	0.1	0.16	0.06
	1.0	0.7	-0.3
	0.05	0.2	0.15
	0.003	0.017	0.004
	0.017	0.3	0.283
	0.9	0.8	-0.1
	0.1	0.16	0.06
	0.4	0.4	0
	0.2	0.16	-0.04
	0.02	0.02	0
	0.003	0.2	0.197
	0.003	0.15	0.147
	0.003	0.6	0.597
	0.017	0.16	0.143
	0.2	0.16	-0.04
Mean (SD)	0.2 (0.28)	0.4 (0.3)	0.2 (0.3)
Retinal detachment	0.003	0.4	0.397
<1 week (n = 17)	0.8	1	0.2
	1.0	0.7	-0.3
	0.003	0.6	0.597
	0.003	0.9	0.897
	0.017	0.9	0.883
	0.003	0.5	0.497
	1.0	0.8	-0.2
	0.003	0.5	0.497
	0.7	0.6	-0.1
	0.8	0.8	0
	0.017	0.3	0.283
	0.6	0.6	0
	0.003	0.5	0.497
	0.003	0.5	0.497
	0.3	0.3	0
	0.003	0.2	0.197
Mean (SD)	0.3 (0.4)	0.6 (0.2)	0.3 (0.3)
Advanced proliferative	0.1	0.3	0.2
diabetic retinopathy (n = 11)	0.017	0.2	0.183
	0.2	0.3	0.1
	0.4	0.4	0
	0.4	0.4	0
	0.003	0.003	0
	0.6	0.6	0
	0.2	0.3	0.1
	0.3	0.3	0
	0.6	0.5	-0.1
	0.16	0.4	0.24
Mean (SD)	0.3 (0.2)	0.3 (0.2)	0.1 (0.1)
Macular hole stage 3	0.2	0.2	0
(n = 20)	0.3	0.3	0

Continued

**Table 3** Continued

	VA preoperatively	VA postoperatively	Change in VA
	0.16	0.2	0.04
	0.1	0.4	0.3
	0.3	0.3	0
	0.4	0.5	0.1
	0.15	0.4	0.25
	0.2	0.2	0
	0.3	0.3	0
	0.3	0.3	0
	0.3	0.3	0
	0.2	0.4	0.2
	0.02	0.02	0
	0.1	0.3	0.2
	0.4	0.7	0.3
	0.2	0.2	0
	0.3	0.3	0
	0.2	0.3	0.1
	0.5	0.7	0.2
	0.6	0.6	0
Mean (SD)	0.3 (0.1)	0.3 (0.2)	0.1 (0.1)

Visual acuity of 0.017 (1/60) equals fingers counting at 1 m, visual acuity of 0.003 (1/300) equals hand movement at 1 m. The mean (SD) values for each patient group are given below. The Kruskal-Wallis one-way analysis of variance by ranks did not show any statistically significant difference between the patient groups ( $p > 0.05$ ).

(MedCalc, SPSS, Chicago). The variance of TTR was studied using a stepwise backward elimination logistic regression model, starting with all covariates in the model followed by a stepwise removal of the term associated with the highest  $p$  value.

## RESULTS

### Reference values

In the reference group ( $n = 73$ , median age: 46 years; IQR 35 to 58 years), the median total protein concentration was 538 mg/l (IQR 269 to 987 mg/l). Considering the causes of death and the pre-existing pathologies, our control cases were a varied group and thus represent the normal population, including a few diabetics ( $n = 10$ ; see table 1). The distribution of total protein was skewed. The median TTR concentration was 18 mg/l (IQR 4 to 24 mg/l) (table 2). The concentration of TTR was correlated with the total protein concentration of the vitreous fluid (correlation coefficient: 0.459;  $p < 0.01$ ). TTR concentrations were not significantly affected by the postmortem interval.

### Values in various pathological conditions

The preoperative and postoperative visual acuities are list in table 3. The total protein levels in patients with fresh or longstanding retinal detachment and in patients with proliferative diabetic retinopathy were higher than total protein reference levels. Among the patient groups, the highest TTR values were recorded in the patients presenting with proliferative diabetic retinopathy and lowest in patients presenting with macular hole stage 3 (table 4). The median TTR values in any pathological condition did not differ statistically with reference TTR values. TTR values in patients who were phakic prior to the vitrectomy procedure (median 22.5 mg/l) were higher than in pseudophakic patients (median 12 mg/l) (fig 1). TTR/total protein ratios were calculated, as this ratio corrects for the vascular permeability changes. TTR/total protein ratios in any disease did not differ with reference TTR/total protein values. Preoperative vitreous TTR values correlated well with the visual outcome following treatment (fig 2). In a logistic regression model, both change in

**Table 4** Reference values and values for total protein and transthyretin (TTR) in vitreous fluid of the various patient groups

Retinal condition	Total protein (mg/l)	TTR (mg/l)	TTR/total protein (%)
	Median (IQR)	Median (IQR)	Median (IQR)
Reference	538 (269 to 987)	18 (4 to 24)	2.2 (0.9 to 3.9)
RRD>1 week old	781* (460 to 1881)	19 (12 to 24)	1.6 (0.6 to 3.3)
RRD<1 week old	816* (427 to 1527)	14 (7 to 25)	1.8 (1.7 to 3.1)
Diabetes mellitus	2326* (1880 to 2818)	20 (10 to 24)	1.3 (1.2 to 1.4)
Macular hole	701 (241 to 1456)	13 (9 to 25)	1.5 (1.1 to 3.2)

The within- and between-run values for total protein and TTR are summarised.

\* $p < 0.05$  versus reference values; Mann-Whitney U test.

IQR, interquartile ratio; RRD, rhegmatogenous retinal detachment.

visual acuity and lens status were the only variables which proved to explain the variance of TTR (multiple correlation coefficient: 0.494; phakic status:  $t = 2.767$ ;  $p = 0.0084$ ; and change in visual acuity  $t = 2.924$ ;  $p = 0.0056$ ).

## DISCUSSION

This is the first report to the authors' knowledge about a biochemical marker related to change in visual acuity after vitrectomy and for measuring TTR in vitreous samples by immunonephelometry. In the present study, high concentrations of TTR (mean: 19 mg/l) were found in vitreous fluid of cadaver eyes. The observed values are comparable with those observed in cerebrospinal fluid (mean: 17 mg/l). The median serum TTR levels are 300 mg/l (IQR 250 to 350 mg/l). The total protein levels in vitreous fluid are 538 mg/l and are comparable with total protein levels in serum and in CSF (150 to 500 mg/l). Total protein levels in serum are much higher ( $64 \times 10^3$  to  $83 \times 10^5$  mg/l). The reference TTR/total protein ratios in the vitreous (2.2%) greatly exceed the TTR/total protein levels in serum (0.4% to 0.5%). The reference TTR values correlated with total protein levels in the vitreous. The origin of vitreous proteins includes the tissues surrounding the vitreous, the hyalocytes of the vitreous or the surrounding vasculature. The much higher TTR/total protein ratios found in the vitreous as compared with serum values suggest that simple diffusion from the serum cannot be the source of vitreous TTR. We conclude that the physiological level of TTR found in the vitreous of cadaver eyes is derived from surrounding tissues as RPE cells.

We found a significant correlation between postoperative change in visual acuity and high TTR concentrations in the vitreous preoperatively. Ramakrishnan *et al* found low TTR levels in the vitreous of patients with diabetes.<sup>15</sup> TTR levels in the former study, however, were not measured by immunonephelometry but calculated semiquantitatively by densitometry after electrophoresis. Our results show that TTR levels in the vitreous are related not to diagnosis but to RPE function. TTR expression is a marker of differentiation of RPE cells *in vitro*.<sup>8</sup> We presume a higher metabolic state of RPE cells in patients with high TTR expression, and thus a better regeneration after a vitrectomy procedure.

The function of TTR in the vitreous remains to be elucidated. RPE of the eye and choroid plexus of the brain are developmental and functional homologues, sharing many of the characteristics of transporting epithelia: the cells are joined by tight apical membrane junctions, and they regulate the transport of fluids and serum proteins into their respective humours. The secretion of TTR by the choroid plexus of the brain provides the mechanism for the regulation of T4 (thyroxine) levels in the brain. TTR in the CSF is involved in the delivery of T4 to stem cells and progenitor cells within the

brain, which require T4 for regulation of the cell cycle.<sup>16 17</sup> The abundance of TTR mRNA in RPE is, except for the choroid plexus in the brain, unmatched by any other tissue of the body.<sup>8</sup> TTR protein is secreted predominantly in an apical direction by RPE cells *in vitro*.<sup>18</sup> The fact that the retinol metabolism is altered in TTR-null mice suggests that TTR plays a major role in the retinol metabolism in the interphotoreceptor matrix (IPM).<sup>19</sup> Interphotoreceptor retinoid-binding protein (IRBP), a non-selective scavenger and stabiliser of retinoids released from photoreceptors and pigment epithelial cells, is the most abundant soluble protein component of the IPM. IRBP plays a direct role in the release of all-*trans* retinol from the rods.<sup>20</sup> All-*trans* retinol generated in rod photoreceptors upon the bleaching of rhodopsin is known to move from the rods to the RPE, where it is enzymatically converted to 11-*cis* retinal in the retinoid visual cycle. Experiments conducted on toad RPE-eyecups, mammalian RPE cells and isolated RPE membranes indicate that IRBP specifically promotes the release of 11-*cis* retinal from the RPE apical surface, a step necessary for the movement of 11-*cis* retinal to the rods.<sup>21</sup> IRBP thereby directly supports the regeneration of rhodopsin in the visual cycle.<sup>22</sup> An emerging concept is that the central role of retinoid-binding proteins in the visual cycle is to achieve tight control of retinoid concentration while protecting the retinal cells from the toxicity of free retinoids. In analogy with the CSF where thyroxine concentrations are titrated by binding to TTR, a spatial gradient of free IRBP molecules and IRBP/retinoid complexes might as well be regulated by TTR in the IPM.

We found higher TTR concentrations in phakic patients than in pseudophakic patients. The vitreous proteome is found to be different in pseudophakic patients.<sup>23</sup> Lens cortical fibre debris, for example, leaks into the vitreous during cataract extraction. Cataract surgery might thus account for the easier passage of TTR from the posterior chamber to the anterior chamber, resulting in a higher outflow via the trabecular meshwork.

The total protein levels in the vitreous of patients with diabetes were 4.3-fold higher than the reference total protein levels. Electrophoresis of vitreous fluid proteins in diabetics revealed a plasma-like protein pattern, suggesting that the increased protein concentration is due to a major diffusion from the pathological vessels. Increased vascular permeability and pathological neovascularisation are major aspects of diabetic retinopathy. Reduced integrity of adherens junctions and tight junctions of human diabetic retina have been reported.<sup>24 25</sup> TTR values in the vitreous of patients with diabetes were fairly similar to reference TTR values, as can be deduced from the following example. A vitreous cavity with a 4 ml content filled with blood corresponds to an influx of only 12  $\mu$ g TTR from the serum into the vitreous cavity (3 mg/l TTR  $\times$  4 ml). The amount of TTR that has originated from the serum into the vitreous cavity cannot cause a significant rise in the TTR concentration already present in the vitreous.

In conclusion, vitreous TTR concentrations strongly exceed the values obtained in serum. Therefore, their concentrations in vitreous fluid reflect local production by the RPE. The present study suggests that TTR can be used as a biochemical marker for assessing retinal function.

**Competing interests:** None.

**Ethics approval:** Ethics approval was provided by the Ethics Committee of University Ghent Hospital, Belgium.

**Patient consent:** Obtained.

**Provenance and peer review:** Not commissioned; externally peer reviewed.

## REFERENCES

1. **Monaco HL**, Rizzi M, Coda A. Structure of a complex of two plasma proteins: transthyretin and retinol-binding protein. *Science* 1995;**268**:1039–41.
2. **Noy N**, Slosberg E, Scarlata S. Interactions of retinol with binding proteins: studies with retinolbinding protein and with transthyretin. *Biochemistry* 1992;**31**:1118–24.
3. **Mendel CM**. The free hormone hypothesis: a physiologically based mathematical model. *Endocr Rev* 1989;**10**:232–74.
4. **Kawaguchi R**, Yu J, Honda J, *et al*. A membrane receptor for retinol binding protein mediates cellular uptake of vitamin A. *Science* 2007;**315**:820–5.
5. **Kanai M**, Raz A, Goodman DS. Retinolbinding protein: the transport protein for vitamin A in human plasma. *J Clin Invest* 1968;**47**:2025–44.
6. **Getz RK**, Kennedy BG, Mangini NJ. Transthyretin localization in cultured and native human retinal pigment epithelium. *Exp Eye Res* 1999;**68**:629–36.
7. **Dwork AJ**, Cavallaro T, Martone RL, *et al*. Distribution of transthyretin in the rat eye. *Invest Ophthalmol Vis Sci* 1990;**31**:489–96.
8. **Pfeffer BA**, Becerra SP, Borst DE, *et al*. Expression of transthyretin and retinol binding protein mRNAs and secretion of transthyretin by cultured monkey retinal pigment epithelium. *Mol Vis* 2004;**10**:23–30.
9. **Sandgren O**. Ocular amyloidosis, with special reference to the hereditary forms with vitreous involvement. *Surv Ophthalmol* 1995;**40**:173–96.
10. **Delcourt C**, Dupuy AM, Carriere I, *et al*. Pathologies Oculaires Liées à l'Age study group. Albumin and transthyretin as risk factors for cataract: the POLA study. *Arch Ophthalmol* 2005;**123**:225–32.
11. **Mullins RF**, Russell SR, Anderson DH, *et al*. Drusen associated with aging and age-related macular degeneration contain proteins common to extracellular deposits associated with atherosclerosis, elastosis, amyloidosis, and dense deposit disease. *FASEB J* 2000;**14**:835–46.
12. **Duan X**, Lu Q, Xue P, *et al*. Proteomic analysis of aqueous humor from patients with myopia. *Mol Vis* 2008;**14**:370–7.
13. **Davis MD**, Fisher MR, Gangnon RE, *et al*. Risk factors for high-risk proliferative diabetic retinopathy and severe visual loss: Early Treatment Diabetic Retinopathy Study Report #18. *Invest Ophthalmol Vis Sci* 1998;**39**:233–52.
14. **Orsonneau JL**, Douet P, Massoubre C, *et al*. An improved pyrogallol red-molybdate method for determining total urinary protein. *Clin Chem* 1989;**35**:2233–6.
15. **Ramakrishnan S**, Sulochana KN, Parikh S, *et al*. Transthyretin (prealbumin) in eye structures and variation of vitreous-transthyretin in diseases. *Indian J Ophthalmol* 1999;**47**:31–4.
16. **Richardson SJ**. Cell and molecular biology of transthyretin and thyroid hormones. *Int Rev Cytol* 2007;**258**:137–93.
17. **Lemkine GF**, Raj A, Alfama G, *et al*. Adult neural stem cell cycling in vivo requires thyroid hormone and its alpha receptor. *FASEB J* 2005;**18**:863–5.
18. **Ong DE**, Davis JT, O'Day WT, *et al*. Synthesis and secretion of retinol-binding protein and transthyretin by cultured retinal pigment epithelium. *Biochemistry* 1994;**33**:1835–42.
19. **Palha JA**, Nissanos J, Fernandes R, *et al*. Thyroid hormone distribution in the mouse brain: the role of transthyretin. *Neuroscience* 2002;**113**:837–47.
20. **Qtaishat NM**, Wiggert B, Pepperberg DR. Interphotoreceptor retinoid-binding protein (IRBP) promotes the release of all-trans retinol from the isolated retina following rhodopsin bleaching illumination. *Exp Eye Res* 2005;**81**:455–63.
21. **Edwards RB**, Adler AJ. IRBP enhances removal of 11-cis-retinaldehyde from isolated RPE membranes. *Exp Eye Res* 2000;**70**:235–45.
22. **Pepperberg DR**, Okajima TL, Wiggert B, *et al*. Interphotoreceptor retinoid-binding protein (IRBP). Molecular biology and physiological role in the visual cycle of rhodopsin. *Mol Neurobiol* 1993;**7**:61–85.
23. **Neal RE**, Bettelheim FA, Lin C, *et al*. Alterations in human vitreous humour following cataract extraction. *Exp Eye Res* 2005;**80**:337–47.
24. **Davidson MK**, Russ PK, Glick GG, *et al*. Reduced expression of the adherens junction protein cadherin-5 in a diabetic retina. *Am J Ophthalmol* 2000;**129**:267–9.
25. **Peters S**, Cree IA, Alexander R, *et al*. Angiotensin modulation of vascular endothelial growth factor: Effects on retinal endothelial cell permeability. *Cytokine* 2007;**40**:144–50.



medical therapy (by Norbert Pfeiffer, Mainz) to the different laser techniques and the numerous surgical options. Trabeculectomy might still be the gold standard, but it increasingly has its competitors: shunts may be relatively safe and effective even as primary surgery for primary glaucomas, as Keith Barton (London) points out, while for Robert Stegmann, "Schlemm's canal surgery will continue to play an increasing role in the management of glaucoma as it is the most physiologic way to approach it."

Glaucoma therapy will remain one of the most challenging tasks for the ophthalmologist—and at the same time promises new developments like those that have propelled glaucoma diagnostics forward, for the benefit of our patients, so impressively. The annual Basel meeting and the book series of which *Glaucoma Therapy: State of the Art* is the latest (it is not available in bookstores but is now on sale online at <http://www.glaucoma-meeting.ch>) help to keep the audience and the readers in touch with a dynamic field of ophthalmology.

**Competing interests:** None.

**R D Gerste**

14801 Soft Wind Drive, Galtherburg, MD 20878, USA;  
[info@glaucoma-meeting.ch](mailto:info@glaucoma-meeting.ch)

## Diabetic retinopathy for the comprehensive ophthalmologist

By Jonathan Walker. Published by Deluma Medical, Fort Wayne, 2009, pp 280, \$39.99. ISBN-13 978-0-9821472-0-7

*Diabetic Retinopathy for the Comprehensive Ophthalmologist* delivers exactly what it promises: an appropriately balanced, straightforward guide to the management

of diabetic retinopathy geared toward the general ophthalmologist. This book is not your traditional didactic reference. Informal and light-hearted, even self-deprecating at times, the author's tone allows this book to be read like a novel rather than a medical textbook. He elegantly balances humour and information, using anecdotes and mnemonics to reinforce key points.

The author assumes his readership has basic understanding of the ophthalmological exam and ancillary tests, and foregoes a primer on this subject. A thorough discussion of the principles and use of lasers, however, is included and is a must-read for retina fellows or any ophthalmologist interested in adding laser procedures to their armamentarium. Residents as well as practising ophthalmologists will likely find useful the chapter on pain control for patients undergoing panretinal photocoagulation. An additional pearl is a chapter on cataract surgery in patients with diabetes, covering specific details regarding preoperative evaluation, intraocular lens selection, anaesthesia and management of postoperative complications.

The chapters are concise and intuitively organised with images from ancient and historical ophthalmology texts adorning the title pages. A reader can easily open this book for 10 min and take away three or four clinical pearls. Colour photographs underscore key principles, particularly in the chapter entitled "You Should Not Do Magic You Do Not Understand: Complications of Laser Treatment." The images of complications and "near-complications" serve admirably as reminders of the potential dangers of ophthalmic lasers.

Large, straightforward figures are found throughout the text, including useful tables

for the appropriate timing of follow-up and figures detailing key information from the landmark papers on diabetic retinopathy. Also interspersed in the chapters are "boxes" containing practical advice that cannot be found in many desk references. These include tips on counselling patients prior to procedures and preparing them for the inevitable pitfalls they are likely to encounter due to their diabetic eye disease. By adopting these techniques, ophthalmologists will better garner the trust and confidence of their patients and reduce time spent explaining during future visits.

*Diabetic Retinopathy for The Comprehensive Ophthalmologist* is available for purchase at Amazon.com for \$39.99. If you cannot afford the purchase price, the author has generously made the entire textbook available as a free download at <http://www.drcobook.com>

**Competing interests:** None.

**J M Goshe**

Cleveland Clinic Main Campus, Mail Code i13, 9500 Euclid Avenue, Cleveland, OH 44195, USA; [goshej@ccf.org](mailto:goshej@ccf.org)

## CORRECTION

doi:10.1136/bjo.2009.158048corr1

Van Aken E, De Letter EA, Veckeneer M, et al. Transthyretin levels in the vitreous correlate with change in visual acuity after vitrectomy (*Br J Ophthalmol* 2009;**93**:1539–45). Line 8 of the Discussion should read "Total protein levels in vitreous fluid are 538 mg/l and are comparable with total protein levels in CSF (150–500 mg/l); ie, "in serum and" should have been omitted.