REVERSIBLE COLLAPSE OF RABBIT EARS AFTER INTRAVENOUS PAPAIN, AND PREVENTION OF RECOVERY BY CORTISONE*

By LEWIS THOMAS, M.D.

(*From the Department of Pathology, New York University-Bellevue Medical Center, New York*)

PLATES 19 TO 23

(Received for publication, April 13, 1956)

For reasons not relevant to the present discussion rabbits were injected intravenously with a solution of crude papain, and the following reactions occurred with unfailing regularity: Within 4 hours after injection, both ears were observed to be curled over at their tips. After 18 hours they had lost all of their normal rigidity and were collapsed limply at either side of the head, rather like the ears of spaniels. After 3 or 4 days, the ears became straightened and erect again. If, at this time, a new injection of papain were given, the same bizarre events recurred. Apart from the unusual cosmetic effect, the animals exhibited no evidences of systemic illness or discomfiture, and continued to feed and move about after the fashion of normal animals of the species.

It has been learned that the phenomenon is associated with a rapid profound depletion of the intercellular matrix of the ear cartilage, and the simultaneous disappearance of all of the material, presumably chondroitin sulfate, which endows cartilage with its usual basophilic staining properties. As the ears regain their shape, both matrix and basophilia reappear. These changes occur not only in ear cartilage but in all other cartilaginous tissues, including the bones, joints, larynx, trachea, and bronchi.

It has also been learned that the ear-collapsing effect of papain is much prolonged by the administration of cortisone, and the replacement of cartilage matrix is delayed for as long as cortisone treatment is continued.

The present report is concerned with these and other aspects of the phenomenon.

Materials and Methods

Papain was obtained as the crude powder derived from dried latex, from several commercial sources. For most experiments, 1 per cent solutions were prepared. The material was dissolved in distilled water, with stirring, and the insoluble residue removed by paper filtration. Bacteria-free solutions were obtained by filtration through Coors porcelain or Seitz

* This work was done under sponsorship of the Commission on Acute Respiratory Disease, Armed Forces Epidemiological Board, and supported in part by the Office of the Surgeon General, Department of the Army, and by a grant from the National Institutes of Health, United States Public Health Service (H-2022).

filters. It was early established that the phenomenon of ear collapse was not influenced by the site of injection and occurred with the same regularity whether papain was injected into the femoral vein, intracardially, or into an ear vein. In the experiments to be described, all injections were made by ear vein.

The rabbits were young, hybrid albino animals obtained from several breeders. Approximately 250 rabbits were used in the experiments to follow. It is important to note that the average weight of all animals was between 800 and 1000 gm., and the average age 7 to 8 weeks. In one experiment, large, mature rabbits were found to be refractory to the phenomenon under investigation.

Cortisone (cortone, Merck) was injected intramuscularly in doses described below.

EXPERIMENTAL

The gross appearance of rabbit's ears at various intervals after the intravenous injection of papain is illustrated in Fig. 1.

The reaction was produced in all of over 150 rabbits given 1 cc. of a 1 per cent solution of crude papain. Similar reactions, but with less complete collapse of the ears, were observed after 1 cc. of a 0.5 per cent solution, and, less constantly, after a 0.1 per cent solution. The earliest visible change in the gross began to occur 3 hours after papain, and consisted of drooping and increased flexibility of the ear tips. During subsequent hours, the loss of normal texture gradually progressed downward toward the base, until the ears lay flaccidly back along the neck, or hung down on either side of the head. By the end of 24 hours the collapse reached its maximal extent, and no further change in appearance took place during the 2nd day. Toward the end of the 3rd day, the ears usually began to regain tone. The process of reversal first became evident at the base, and on the 4th day the ears were partially upright, but still showed curling of the tips. By the 5th day, in the majority of instances, the gross appearance of the ears was again normal.

The Effect of Repeated Injections of Papain; The Appearance of Immunity.—A group of ten rabbits received injections of 1 cc. of a 1 per cent solution of papain every 3 days for a period of 3 weeks. During the first 12 days the ears remained completely collapsed, and then gradually over a period of 3 or 4 days resumed the normal shape. On the 15th day and thereafter, the injections no longer caused collapse of the ears. Evidences of mild anaphylaxis were observed in some of the animals immediately following injections given during the 3rd week. Precipitating antibodies which reacted with the papain solution were demonstrable in serum drawn at this time. It is presumed that the animals had become immune to the factor responsible for ear collapse. Further studies on this line are currently in progress.

Protection of One Ear by Temporary Arterial Occlusion.—In order to learn whether the factor responsible for ear collapse produced its effect by circulating in the blood for a long period, or was promptly absorbed from the blood into the involved tissues, the following experiment was performed. In six rabbits the circulation to the right ear was occluded by winding a length

of rubber tubing tightly around the base. Papain, 1 cc. of a 1 per cent solution, was then injected into the marginal vein of the opposite ear. 15 minutes later the circulation to the right ear was released, and the animals were observed for 3 days. The results are illustrated in Fig. 2. In each instance, the left ear collapsed in the usual manner, while the right ear remained erect and showed no loss of tone. This outcome indicates that the final effect of the papain factor is determined within 15 minutes after injection, and after this time there is no longer a sufficient amount in the blood to cause the reaction.

Histopathologic Changes in Cartilage after Papain Injection.—Sixteen rabbits received an intravenous injection of 1 cc. of 1 per cent papain, and were sacrificed in groups of four after intervals of 4, 24, 48, and 72 hours. Histologic sections of the ears, ribs, femoral epiphyses, knee joints, larynx, trachea, and bronchi were examined with hematoxylin and eosin stains and by the Hotchkiss-McManus modification of the periodic acid–Schiff reaction. In addition, several special stains for delineation of elastic tissues and collagen were employed. Similar histologic preparations were made from the corresponding tissues of four normal rabbits.

The results were uniform and striking. In the sections taken 4 hours after injection, the ear cartilage showed loss of a major portion of the intercellular matrix, and complete absence of basophilia from the small amount of remaining matrix. The cartilage cells appeared somewhat larger, and rounder than normal, and lay in close contact with each other. The contrast between normal ear cartilage and tissue obtained 4 hours after injection is illustrated in Figs. 3 A and 3 B.

In other tissues containing cartilage similar changes were encountered. In the larynx, trachea, and bronchi the disappearance of basophilic material in the matrix was a conspicuous feature, but the matrix itself showed less diminution in total volume than was seen in ear cartilage (Fig. 4).

The sections taken 24 and 48 hours after administration of papain showed substantially the same changes. There were no lesions indicating cell destruction, and no inflammatory or vascular lesions in the areas of altered cartilage. By the end of the 3rd day, the matrix appeared to have become normal in volume, and basophilia was again demonstrable in many areas.

Periodic acid–Schiff preparations showed the presence of granular Schiff-positive material in the cytoplasm of normal ear cartilage cells. In the sections of ear cartilage obtained 4, 24, and 48 hours after injection of papain, the cells did not contain this substance. After 72 hours, the Schiff-positive material was again demonstrable in the cartilage cells.

Attempts to Determine the Identity of the Active Factor in Papain.—There are known to be at least two crystallizable proteases in crude papain, designated as papain protease and chymopapain (1, 2). Smith and coworkers have also isolated and crystallized a papain lysozyme (3). The three enzymes are be-

lieved to account for a major proportion of the weight of crude, dry papain (3).

Samples of crystalline papain protease (Worthington Biochemical Co., Freehold, New Jersey) and crystalline papain lysozyme (courtesy of Dr. Emil Smith) were tested by intravenous injection into rabbits in doses of 5 mg. per rabbit. Neither produced any change in the normal shape or tone of the ears, nor any histologic alteration of cartilage matrix. A combination of crystalline papain and lysozyme was also without effect. An incompletely purified papain extract (fraction 3-A(2)) containing both chymopapain and lysozyme, as well as other unidentified materials, caused collapse of ears.

It is concluded, tentatively, that the ear collapse phenomenon is not due to the crystalline papain protease or lysozyme. The possibility that chymopapain may be responsible cannot be excluded. Further attempts to identify the active factor by fractionation procedures are in progress. It has been found most abundantly in a fraction corresponding to that designated 3A-1 in the procedure described by Kimmel and Smith (2). This material, prepared by precipitation of a crude papain solution with 0.4 saturation by ammonium sulfate, followed by precipitation of the supernatant with 0.8 saturation, followed by dialysis of the precipitate, produced the most severe reactions thus far observed. An injection of 0.5 cc. of this fraction caused complete collapse of the ears within 3 to 4 hours, with death of some of the rabbits, evidently caused by respiratory obstruction. At autopsy, the trachea of these animals was of a soft, easily compressible consistency similar to that of the esophagus.

Fractions prepared by precipitation with mercuric chloride, by the method used by Smith *et al.* to produce lysozyme (3), proved to be inactive. This may have been due to inactivation of the material by mercury, since it was observed that mercuric chloride, in a final concentration of 0.01 M, caused loss of the ear-collapsing property of crude papain solutions.

Unlike the chymopapain described by Jansen and Balls (1), the material became ineffective after exposure to pH 1.9 overnight. Moreover, precipitates obtained by sodium chloride saturation of papain solutions at pH 2, which contain chymopapain (1), did not cause the ear reaction in rabbits.

Heating of active preparations of 1 per cent crude papain at 60°C. for 15 minutes resulted in disappearance of activity.

The Effects of Cortisone.—The disappearance of basophilic material from the matrix of cartilage suggests the possibility that chondroitin sulfate may have been lost from this tissue, and preliminary chemical assays of the altered cartilage support this view. Since it has been suggested by Asboe-Hansen (4) that cortisone prevents the synthesis and/or deposition of this type of sulfated acid polysaccharide in tissues, it seemed appropriate to test the effect of cortisone on the reaction to papain, and particularly on the reconstitution of cartilage matrix after collapse of the ears. To this end, the following experiment was undertaken: Groups of rabbits were injected with 1 cc. of 1 per cent

papain, and treated at various times with cortisone. A typical result is summarized in Table I. When given at the same time as papain, or within 24 hours or less thereafter, cortisone prevented or greatly delayed the return to normal. For example, the daily administration of cortisone, in a dose of 5 mg. per kilo, prevented the reformation of cartilage during a treatment period of 4 weeks, in contrast to untreated animals in which the ears became normal on the 4th or 5th day after papain. The observation is illustrated in Fig. 4.

TABLE I

Prevention by Cortisone of the Return of Papain-Collapsed Ears to Normal

Treatment	Days After Papain Injection				
	1	3	5	9	14
5 mg. cortisone on day of papain injection, and daily thereafter	4/4*	4/4	4/4	4/4	4/4
10 mg. cortisone on day of papain. None thereafter	3/3	3/3	2/3	0/3	0/3
10 mg. cortisone 24 hrs. after papain, and daily thereafter	4/4	4/4	4/4	4/4	4/4
10 mg. cortisone 48 hrs. after papain, and daily thereafter	4/4	4/4	4/4	4/4	4/4
No cortisone	4/4	4/4	0/4	0/4	0/4

* Numerator refers to number of rabbits with collapsed ears on indicated day; denominator refers to number in group.

When cortisone was begun 48 hours after papain the return of the ears to normal was similarly prevented for 4 weeks, but the degree of ear collapse was less than in the animals in which cortisone was begun on the day of papain. As is shown in Table I, continuing treatment was needed in order to prevent restoration; a single injection at the time of injection of papain had little or no delaying effect.

It should be mentioned that cortisone did not have the property of enhancing susceptibility to the ear-collapsing action of papain, nor was the rate at which the lesion developed accelerated by cortisone.

DISCUSSION

The existence in crude papain of a factor which causes collapse of rabbits' ears and lysis of cartilage matrix in all tissues when injected by vein raises several interesting points for further inquiry. The first two are biochemical problems concerning the nature of the papain factor and the nature of the

change in cartilage. Although the factor has not been identified, it seems to be distinct from crystalline papain and lysozyme; its possible relationship to chymopapain remains to be clarified. Whatever its nature, it must possess a remarkable degree of biological activity, in view of the fact that 5 mg. of crude papain is effective in 1 kilo rabbits, and a major part of this amount consists of crystallizable papain protease and lysozyme, which do not cause the phenomenon, plus a considerable amount of insoluble residue which is lost when the solution of crude papain is filtered. It is a conservative estimate that less than 1 mg. of the active principle of papain is probably sufficient to remove the basophilic constituent of cartilage in all parts of the animal's body.

As to the nature of the change induced in cartilage, little can be said at this time. It is generally assumed that the basophilia of cartilage matrix is largely due to chondroitin sulfate. Preliminary assays of affected cartilage have indicated a substantial loss of this component. Whether this occurs directly as the result of an action on chondroitin sulfate itself, or indirectly as an effect on another constituent to which the former is bound, remains to be determined. The significance of the disappearance of intracellular periodic acid–Schiff-positive material from the cartilage cells is also a matter for further study.

The rapidity of the reaction, the extensive area of cartilage tissue involved, and the small doses of crude papain which suffice to cause the reaction are points which, taken together, suggest that an enzyme is at work. Consideration must be given not only to possible enzymes contained in papain, but also to the possibility that a kinase in papain is capable of activating a lytic enzyme in the rabbit's own tissues.

There is indirect evidence suggesting that the active principle is rapidly cleared from the blood and taken up by the tissues which it affects. When the arterial circulation to one ear was occluded for a period of 15 minutes at the time of injection, this ear was protected against collapse. A possibly analogous situation was demonstrated by Karnovsky (5) with nitrogen mustard: occlusion of the arterial supply to the marrow of one femur for 5 minutes after injection spared this organ from the action of HN_2, owing to rapid fixation of the drug in other tissues.

The question as to whether the papain factor is concentrated in cartilage may become answerable when the identity of the agent is known. It was observed that rabbits become immune after 2 weeks of injection, indicating the formation of a specific antibody, and it may therefore be possible to locate the factor by immunohistochemical techniques such as that of Coons. It is known that various antibodies against constituents of papain appear after immunization with the crude material (6), but the identification of antibody directed against the active principle which affects cartilage must await isolation of the latter in purified form.

Cortisone has the property of preventing, or greatly delaying, the restora-

tion of cartilage to its normal state. If it should prove that the process of recovery requires the synthesis and deposition of chondroitin sulfate, this affect of cortisone may become of practical usefulness for studies of the postulated (4) role of cortisone in the metabolism of sulfated mucopolysaccharides.

It is remarkable that so drastic a physical and chemical alteration in cartilage can be brought about without any obvious indication of functional impairment or tissue damage to the joints. It will be necessary to observe animals for much longer periods after papain injection before assuming that no irreversible changes have occurred. In particular, the effect of papain on subsequent skeletal development in very young animals is to be investigated.

SUMMARY AND CONCLUSIONS

A substance has been demonstrated in solutions of crude papain, which, when injected intravenously into 1 kilo rabbits, in amounts less than 5 mg., results in complete collapse of both ears. The phenomenon becomes visible 4 hours after injection, and is complete within 24 hours. 3 or 4 days after papain, the ears gradually reassume their normal form.

Ear collapse is associated with depletion of the ear cartilage matrix, and the disappearance of basophilia from the matrix. Similar changes occur in all other cartilage tissues, including bones, joints, larynx, trachea, and bronchi. At the time when the ears are restored to normal shape, the basophilic matrix reappears in cartilage.

Repeated injections of papain, over a period of 2 or 3 weeks, bring about immunity to the phenomenon of ear collapse.

When the arterial circulation to one ear is occluded for 15 minutes at the time of injection of papain, this ear is protected against collapse.

The effect of crude papain could not be reproduced by crystalline papain protease or crystalline papain lysozyme, which together comprise a considerable portion of the dry weight of papain. The nature of the responsible factor has not been determined, and the possibility that chymopapain may be implicated is currently under study.

Cortisone prevents the return of papain-collapsed ears to their normal shape and rigidity. Possibly this reflects a capacity of cortisone to impede the synthesis or deposition of sulfated mucopolysaccharides in tissues.

BIBLIOGRAPHY

1. Jansen, E. F., and Balls, A. K., *J. Biol. Chem.*, **137,** 1941, 459.
2. Kimmel, J. R., and Smith, E. L., *J. Biol. Chem.*, **207,** 1954, 515.
3. Smith, E. L., Kimmel, J. R., Brown, D. M., and Thompson, E. O. P., *J. Biol. Chem.*, **215,** 1955, 65.
4. Asboe-Hansen, G., Tr. 5th Conf. Connective Tissues, Josiah Macy Jr. Foundation, New York, 1954, 123.
5. Karnovsky, D. A., Graef, I., and Smith, H. W., *Am. J. Path.*, **24,** 1948, 275.
6. Hwang, K., and Ivy, A. C., *Ann. New York Acad. Sc.*, **54,** 1951, 161.

EXPLANATION OF PLATES

PLATE 19

FIGS. 1 A to D. The appearance of rabbit ears after an intravenous injection of papain. A, before injection. B, 4 hours after. C, 24 hours after. D, 5 days after. × ⅔.

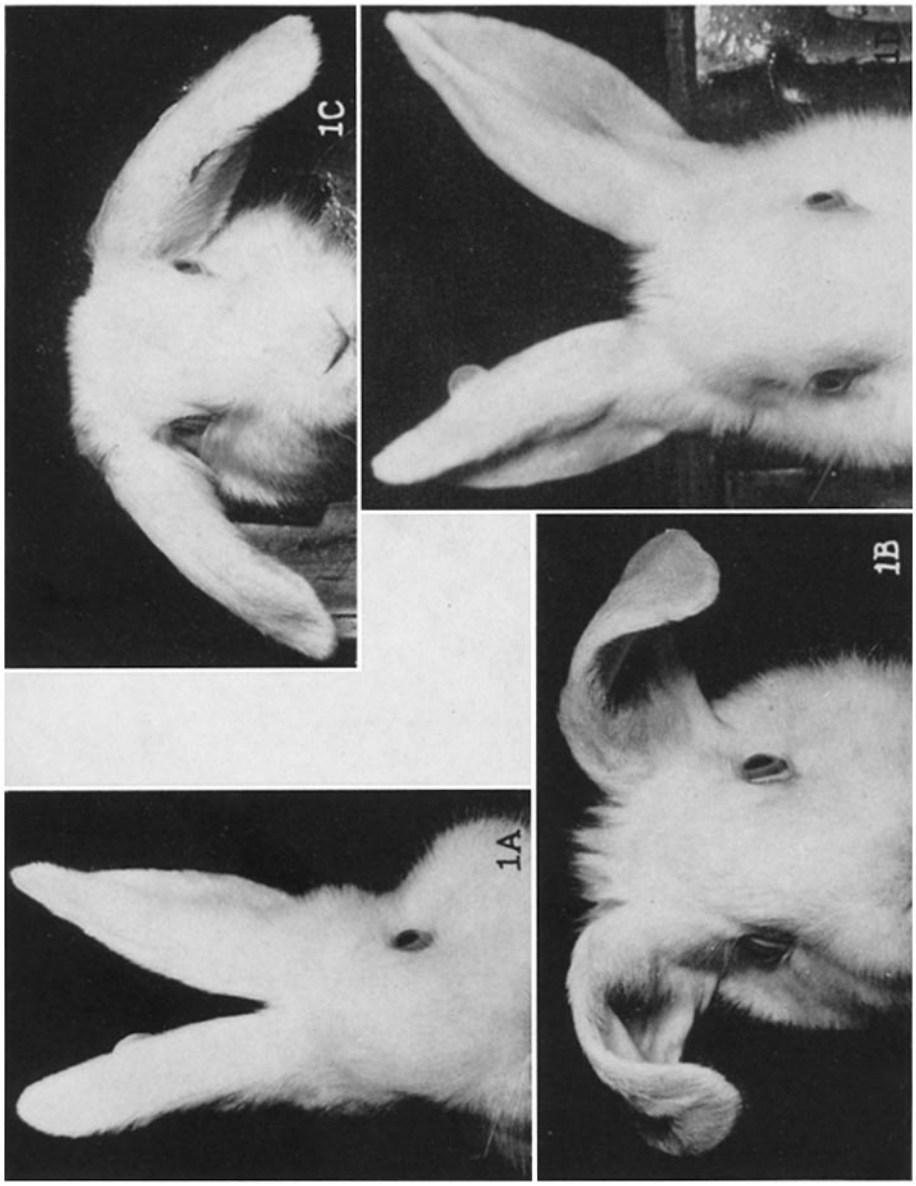

(Thomas: Collapse of rabbit ears after intravenous papain)

PLATE 20

FIG. 2. Protection against ear collapse by excluding arterial circulation to one ear at time of papain injection. The right ear was clamped for 15 minutes at time of injection of papain. Photograph taken 2 days after injection. Note partial collapse of left ear, normal right ear.



(Thomas: Collapse of rabbit ears after intravenous papain)

PLATE 21

FIGS. 3 A and B. Histologic changes in cartilage following papain injection. A, normal rabbit ear cartilage. Note diffuse basophilia, most marked immediately around each cartilage cell. Cells are well spaced apart and separated by matrix. B, ear cartilage 4 hours after intravenous papain. Loss of basophilia and reduction in amount of matrix. Cartilage cells are large, round and close together. × 70.

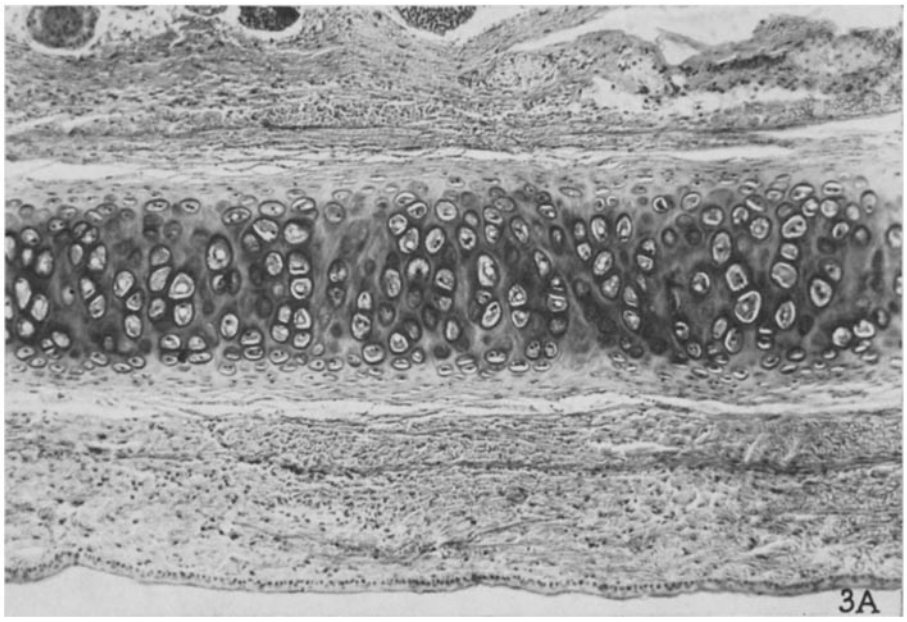

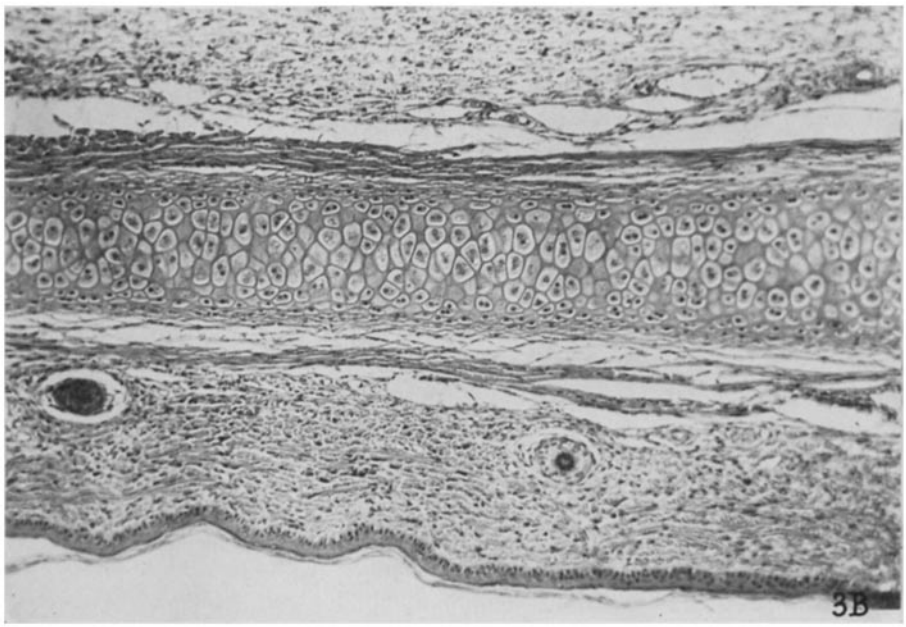

(Thomas: Collapse of rabbit ears after intravenous papain)

PLATE 22

FIGS. 4 A and B. Histologic changes in cartilage following papain injection. A, normal tracheal cartilage. B, tracheal cartilage 24 hours after papain. Note loss of basophilia in matrix. × 70.

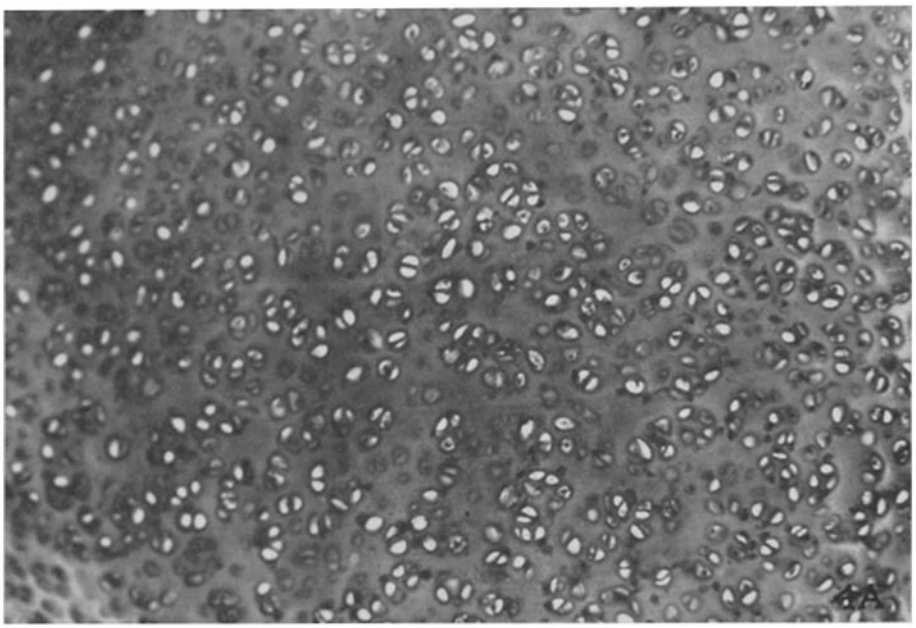



(Thomas: Collapse of rabbit ears after intravenous papain)

PLATE 23

FIGS. 5 A to C. Maintenance of ear collapse by cortisone. A, rabbits injected with papain and photographed on 5th day. Ears have nearly returned to normal. B, treated with 5 mg. cortisone daily for 3 weeks after papain. Ears partially collapsed. C, treated with 10 mg. cortisone daily for 3 weeks after papain. Ears remain completely collapsed. × 4/5.

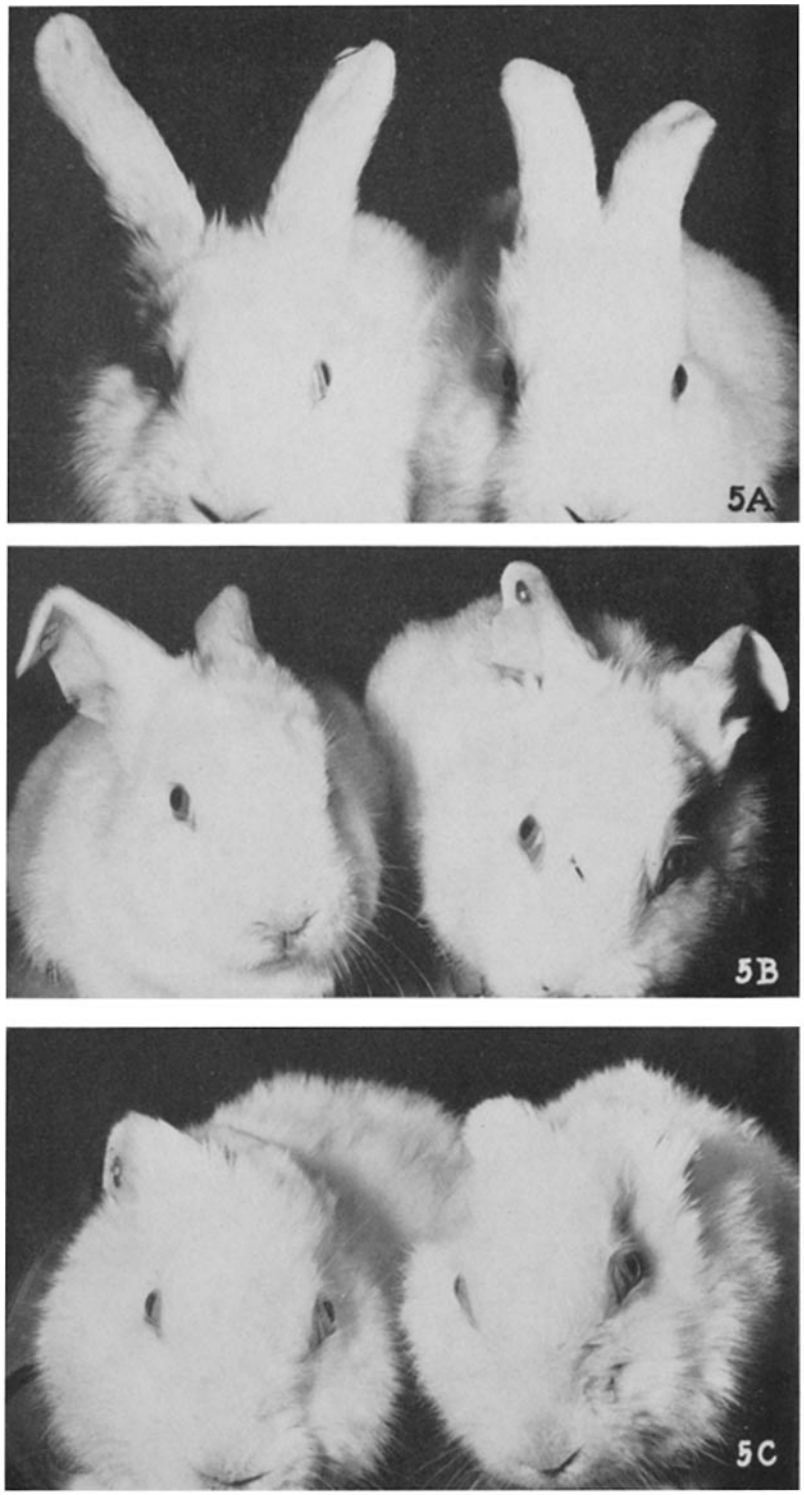

(Thomas: Collapse of rabbit ears after intravenous papain)