

# Efficacy and Safety of Gefitinib Plus Anlotinib for Patients with EGFR Positive Advanced Non-Small-Cell Lung Cancer: A Retrospective Exploratory Study

Wen-Xia Hu, Jing-Cui Peng, Yun Wang, Hao Jin, Nan Geng 

Department of Respiratory Medicine, The Fourth Hospital of Hebei Medical University, Shijiazhuang, 050012, People's Republic of China

Correspondence: Nan Geng, Department of Respiratory Medicine, The Fourth Hospital of Hebei Medical University, 12 Jian-Kang Road, Shijiazhuang, 050012, People's Republic of China, Tel +86 13933852787, Email [anbuchao2021@163.com](mailto:anbuchao2021@163.com)

**Objective:** This study was to investigate the efficacy and safety of gefitinib plus anlotinib for patients with EGFR positive advanced non-small cell lung cancer (NSCLC) in a first-line setting.

**Methods:** A total of 36 patients with previously-untreated EGFR positive advanced NSCLC were included in this study retrospectively. All patients were administered with gefitinib plus anlotinib combination therapy. The efficacy of the patients was evaluated with the change of target lesion using imaging evidence according to RECIST 1.1 criteria and all the patients were followed up regularly. Adverse reactions were collected and documented during the combination administration. Univariate analysis according to the baseline characteristic subgroup was implemented using Log rank test and multivariate analysis was adjusted by Cox regression analysis.

**Results:** All the 36 patients included in our study were available for efficacy and safety analysis. Best overall response of the patients during gefitinib plus anlotinib administration suggested that partial response was observed in 30 patients, stable disease was noted in five patients, and progressive disease was found in one patient, which yielded an objective response rate (ORR) of 83.3% (95% CI=67.2–93.6%) and a disease control rate (DCR) of 97.2% (95% CI=85.5–99.9%). Prognostic data indicated that the median progression-free survival (PFS) of the 36 patients with NSCLC was 15.2 months (95% CI=8.15–22.26). Furthermore, the median overall survival (OS) of the 36 patients was 35.9 months (95% CI=22.77–49.03). Additionally, the most common adverse reactions of the patients with NSCLC were diarrhea (63.9%), fatigue (58.3%), hypertension (50.0%), rash (44.4%), and nausea and vomiting (41.7%). Furthermore, ECOG performance status was associated with PFS of gefitinib plus anlotinib combination therapy in baseline characteristic subgroup analysis.

**Conclusion:** Gefitinib plus anlotinib regimen demonstrated encouraging efficacy and an acceptable safety profile for patients with previously untreated EGFR positive NSCLC preliminarily. The conclusion should be validated in prospective clinical trials subsequently.

**Keywords:** non-small cell lung cancer, EGFR mutation, anlotinib, gefitinib, efficacy, safety

## Introduction

As the second most common solid tumor and the leading cause of cancer-related death all over the world, lung cancer was observed of approximately 815,000 new cases and 715,000 deaths in China each year.<sup>1</sup> Non-small cell lung cancer (NSCLC) accounts for approximately 85% of lung cancer.<sup>2</sup> Patients with epidermal growth factor receptor (EGFR) positive mutation were reported to be of almost 40% among all NSCLC in China.<sup>3</sup> As a result, it is estimated that there are approximately 277,000 new cases of NSCLC with EGFR positive mutation in China annually. To our knowledge, pivotal trials established EGFR tyrosine kinase inhibitor (TKI) therapy as the standard of care for patients with EGFR positive NSCLC since 2004.<sup>4</sup> Amazingly, recent years had witnessed remarkable achievements regarding the targeted drugs for patients with EGFR mutation, thus rendering NSCLC with a positive EGFR mutation the most successful

cancer in precision medicine.<sup>5</sup> Gefitinib, erlotinib, afatinib, dacomitinib, and Osimertinib were efficacious in clinical practice as the first-line therapy for patients with EGFR mutation NSCLC currently.<sup>6</sup> Unfortunately, with regard to the first-generation EGFR TKIs (gefitinib, erlotinib, and Icotinib) in China, although 60–80% of the patients with EGFR positive mutation had responses following the administration with these drugs, the median progression-free survival (PFS) was still dismal (approximately 1 year) owing to the acquired therapeutic resistance.<sup>7</sup> Additionally, it should be noted that a third-generation EGFR TKI (Osimertinib) was a superior first-line treatment according to the FLAURA study.<sup>8</sup> However, there was no standard targeted drug therapy after Osimertinib progression and the optimized therapy strategy across multiple treatment lines remained unknown.<sup>9</sup> Consequently, it was necessary to investigate the efficacious first-generation EGFR TKI-based regimens for delaying the progression in the first-line setting urgently.

Resistance to EGFR TKIs was always associated with elevated vascular endothelial growth factor (VEGF) levels. And inhibition of the VEGFR and EGFR signal pathway exhibited the possibility to overcome gefitinib resistance.<sup>10</sup> Therefore, the combination of EGFR inhibitors and VEGFR inhibitors might be of potential feasibility for cancer treatment clinically.<sup>11</sup> To our knowledge, angiogenesis was of utmost importance in the development of numerous malignancies and was identified to be an important therapeutic strategy for solid tumors according to the theory of professor Folkman<sup>12</sup> since 1971. As a result, recent years had witnessed that antiangiogenic targeted drugs were developed and exhibited potential anticancer activity in advanced NSCLC.<sup>13</sup> The previous preclinical study suggested that bevacizumab could counteract VEGF-dependent resistance to erlotinib in an EGFR-mutated NSCLC xenograft model.<sup>14</sup> Therefore, we noticed that bevacizumab plus erlotinib combination therapy demonstrated improved PFS compared with erlotinib alone for patients with EGFR positive NSCLC according to the NEJ026 trial.<sup>7</sup> Furthermore, EGFR-TKI combined with anti-VEGF inhibitor demonstrated synergistic action in an EGFR T790M xenograft model.<sup>15</sup> EGFR-TKI combined with antiangiogenic targeted drugs might play a promising role to reverse the gefitinib resistance and prolong the PFS of patients with EGFR positive mutation. An interesting study investigated the combination therapy of cabozantinib (a multitargeted TKI targeting VEGFR2) plus erlotinib as second- or subsequent-line treatment for both EGFR-mutant and wild-type NSCLC.<sup>16</sup> The results indicated that the combination regimen was efficacious, thus indicating VEGFR and EGFR dual blockade might serve as a new option for NSCLC.<sup>17</sup>

As an orally antiangiogenic multi-targeted TKI, anlotinib became a new standard of care for patients with NSCLC, regardless of the EGFR status in third-line treatment in China since 2018 according to the ALTER0303 Phase III clinical trial.<sup>18</sup> And anlotinib played the anticancer activity with the inhibition of VEGFR1-3, FDGFR1-4, PDGFR $\alpha$ - $\beta$ , c-Kit, and Ret.<sup>19</sup> Amazingly, a recent study explored the efficacy of anlotinib combined with gefitinib among patients with EGFR positive mutation NSCLC who had acquired resistance to EGFR-TKIs.<sup>20</sup> And the results suggested that this combination was a promising administration for patients with EGFR-TKI resistant and potentially secondary drug-resistant advanced NSCLC *in vitro* and *in vivo*. However, the feasibility of anlotinib plus gefitinib regimen as first-line treatment for patients with EGFR positive NSCLC was still unknown currently.

Consequently, the present study was to investigate the efficacy and safety of gefitinib plus anlotinib as first-line therapy for patients with EGFR positive advanced NSCLC in the real world.

## Patients and Methods

### Study Design and Eligibility Criteria

Gefitinib and anlotinib were both approved for patients with advanced NSCLC in China. And a certain number of patients with EGFR positive NSCLC had been treated with gefitinib plus anlotinib administration in clinical practice. Therefore, this study was designed as a retrospective analysis. Patients with previously-untreated advanced NSCLC who were in the presence of positive EGFR mutation from June 2018 to June 2021 in the Department of Respiratory Medicine of the Fourth Hospital of Hebei Medical University were included in this study consecutively. The inclusion criteria included: 1) pathologically confirmed diagnosis of advanced NSCLC; 2) activate positive EGFR mutation without T790M mutation; 3) pathological staging of IIIb or IV; 4) aged  $\geq 18$  years; 5) Eastern Cooperative Oncology Group (ECOG) performance status (PS) of 0–2 score; 6) patients were treated with gefitinib plus anlotinib combination administration in first-line setting; 7) at least one measurable target lesion according to response evaluation criteria in solid tumors (RECIST 1.1). The exclusion criteria were:

1) previous exposure to gefitinib or anlotinib administration; 2) presence of symptomatic brain metastases (patients with stable brain metastases were eligible); 3) concomitant with another tumor or serious disease that might compromise the survival of the patients; and 4) data of efficacy assessment was not available. However, patients who were lost to follow-up were appropriate for survival analysis. A flow chart of this retrospective study is illustrated in Figure 1. A total of 36 patients with EGFR positive advanced NSCLC were enrolled in this study ultimately.

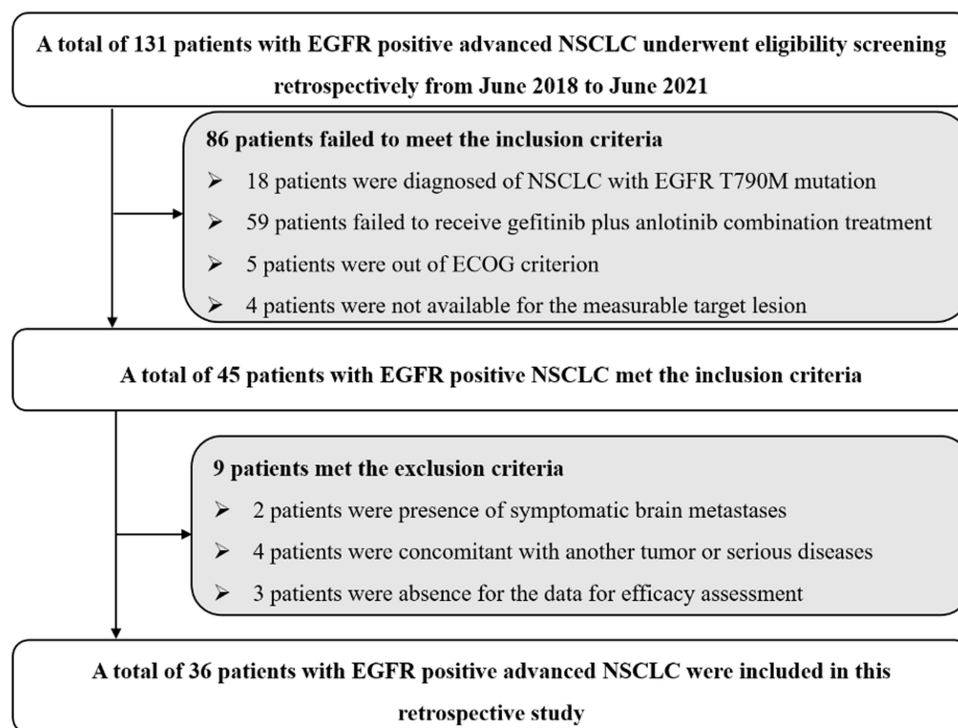
The primary endpoint of the present study was progression-free survival (PFS), the secondary endpoints were objective response rate (ORR), disease control rate (DCR), overall survival (OS), and safety of gefitinib plus anlotinib administration. The protocol of the present study was approved by the ethics committee of the fourth hospital of Hebei medical university (approved number: 2020 MEC056), which was conducted in accordance with the Declaration of Helsinki. Informed consent was provided by each enrolled patient and the medical data of the patients was confidential at the highest level.

## Administration of Gefitinib Plus Anlotinib Regimen

All the patients included in this study were treated with gefitinib combined with anlotinib therapy. Gefitinib was administered orally at 250 mg once daily (every 28 days as one cycle) until disease progression or intolerable adverse reactions. Anlotinib was administered orally once daily for day 1–14, discontinued for 7 days (every 21 days as one cycle) with an initial dosage of 12 mg or 10 mg until disease progression or intolerable adverse reactions. Additionally, intolerant patients were permitted to receive a single agent until disease progression. Furthermore, dosage adjustment of anlotinib to either 10 mg or 8 mg once daily was permitted according to the adverse reactions during the treatment.

## Response Assessment and Document of Adverse Reactions

Drug response was evaluated by the investigator assessment using chest computed tomography (CT) scans or nuclear magnetic resonance imaging (MRI) before and after gefitinib plus anlotinib administration. The change of target lesions was assessed every 8 weeks or it was necessary (clinical symptoms of the patients were getting worse). Results of each imaging assessment were recorded and analyzed to document the best overall response of the patients. Subsequently,



**Figure 1** Flow chart of the retrospective study of gefitinib plus anlotinib in the treatment for patients with EGFR positive advanced non-small cell lung cancer.

follow-up was performed over the phone every 3 months, and death status of the patients was mainly obtained. The data cut-off date of this study was October 30, 2021.

Adverse reactions during the combination treatment of gefitinib plus anlotinib were performed using Common Terminology Criteria for Adverse Events (CTCAE) version 4.03 criteria to record the toxicity profile of gefitinib plus anlotinib combination therapy. And the maximum toxicity of the 36 patients with NSCLC which occurred during the combination therapy were collected and analyzed in this study.

## Statistical Analysis

Data presented in this study was analyzed using SPSS software version 25.0 (IBM, USA). ORR was the percentage of complete response (CR) and partial response (PR) among the 36 patients with NSCLC. DCR was the percentage of CR and PR and stable disease (SD) among the 36 patients with NSCLC. PFS was defined as the interval from the date of the onset of gefitinib plus anlotinib administration to the date of disease progression or death, whichever occurred first. OS was defined as the interval from the date of the onset of gefitinib plus anlotinib administration to the date of death of the patients from any cause.<sup>9</sup> When no progression or death events were observed, survival end points were censored at the date of data cut-off. Kaplan-Meier survival curves were drawn using Stata version 14.0 to generate the PFS and OS survival curves. Survival difference according to the baseline characteristic subgroup was calculated using Log rank test.  $P < 0.05$  was accepted as statistically significant.

## Results

### Baseline Characteristics of the 36 Patients with EGFR Positive NSCLC

The baseline characteristics of the 36 patients with EGFR positive advanced NSCLC are shown in Table 1. The median age of the 36 patients was 59 years (age range=35–81 years). A total of 19 patients were female and 17 patients were male. Pathological stage with IIIb or IV was observed in three and 33 patients, respectively. ECOG performance status of 0–1 score and 2 score was noted in 25 and 11 patients, respectively. Nonsmokers and smokers/former smokers were found in nine and 27 patients, respectively. Most of the patients had adenocarcinoma (94.4%). Brain metastasis was observed in five patients (13.9%). Regarding the EGFR genomic aberration, EGFR Exon 19 delete and 21 L858A mutation were reported in 19 patients and 17 patients, respectively. Besides, number of metastatic sites of  $\leq 2$  and  $> 2$  were found in 11 and 25 patients, respectively. Interestingly, the initial dosage of anlotinib with 12 mg and 10 mg was observed in 30 and six patients, respectively.

### Efficacy of the 36 Patients with EGFR Positive Advanced NSCLC Who Received Gefitinib Plus Anlotinib Administration

All the 36 patients with EGFR positive advanced NSCLC were available for efficacy assessment. The best overall response of each enrolled patient during gefitinib plus anlotinib administration indicated that partial response (PR) was observed in 30 patients, stable disease (SD) was noted in five patients, and progressive disease (PD) was found in one patient according to RECIST version 1.1. As a result, ORR of the 36 patients was 83.3% [95% confidence interval (CI) =67.2–93.6%], DCR was 97.2% (95% CI=85.5–99.9%). Specifically, waterfall plot for the best percentage change in target lesion size of the 36 patients who received gefitinib plus anlotinib administration was exhibited in Figure 2. Most of the target lesions among the 36 patients with EGFR positive advanced NSCLC shrank significantly. Furthermore, the chest CT scan of the target lesion in the lymph node of a PR patient before and after the administration of gefitinib plus anlotinib is illustrated in Figure 3. The target lesion changed dramatically after the combination therapy of gefitinib plus anlotinib. Additionally, all the non-target lesions almost disappeared completely, which suggested that this patient benefited significantly from the combination administration of gefitinib plus anlotinib.

**Table 1** Baseline Characteristics of the 36 Patients with EGFR Positive Advanced NSCLC

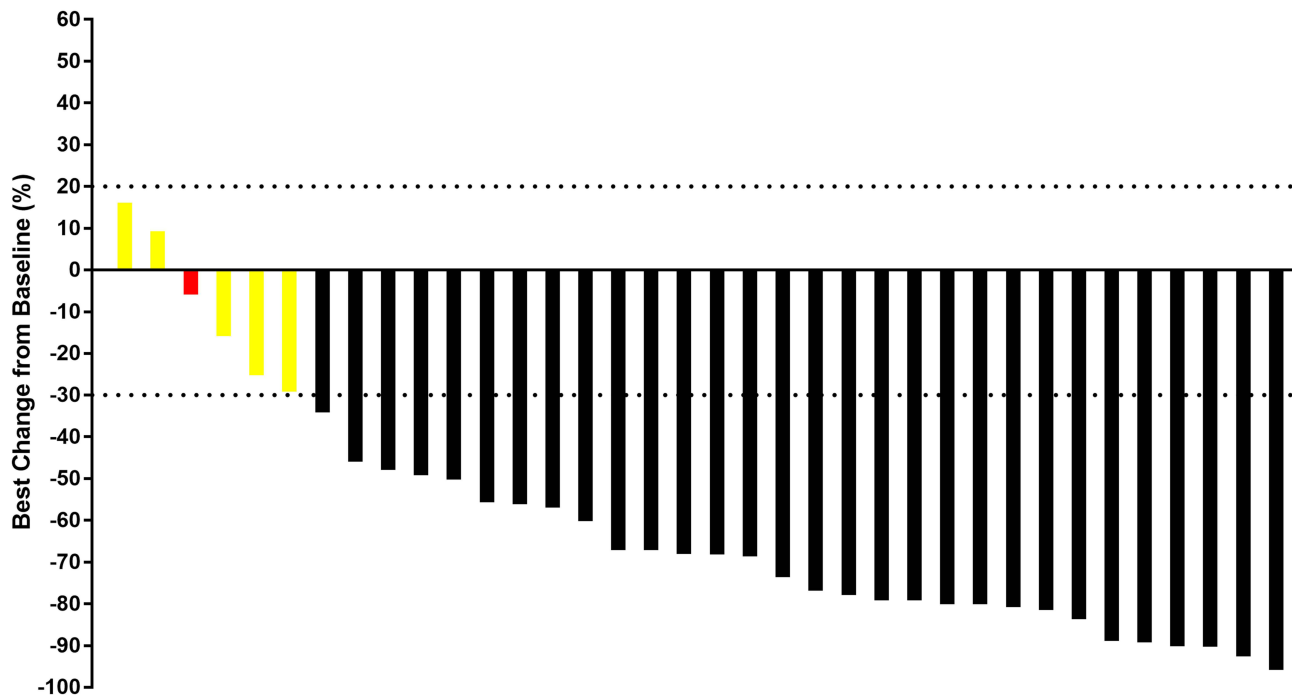
Characteristics	Total Patients (N=36)	Percentage
<b>Age (years)</b>		
Median (range)	59 (35–81)	
≥59	20	55.6%
<59	16	44.4%
<b>Gender</b>		
Male	17	47.2%
Female	19	52.8%
<b>Pathological stage</b>		
IIIb	3	8.3%
IV	33	91.7%
<b>ECOG PS score</b>		
0–1	25	69.4%
2	11	30.6%
<b>Smoking status</b>		
Nonsmoker	9	25.0%
Smoker/former smoker	27	75.0%
<b>Histology</b>		
Adenocarcinoma	34	94.4%
Other type	2	5.6%
<b>Brain metastasis</b>		
Yes	5	13.9%
No	31	86.1%
<b>EGFR genomic aberration</b>		
Exon 19 del	19	52.8%
Exon 21 L858A	17	47.2%
<b>Number of metastatic sites</b>		
≤2	11	30.6%
>2	25	69.4%
<b>Initial dosage of anlotinib (mg)</b>		
12	30	83.3%
10	6	16.7%

**Abbreviations:** EGFR, epidermal growth factor receptor; NSCLC, non-small cell lung cancer; ECOG, Eastern Cooperative Oncology Group; PS, performance status.

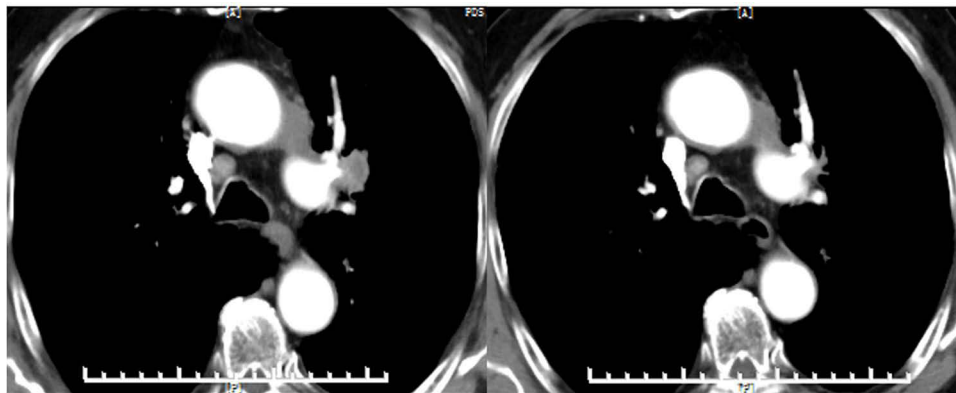
## Prognosis of the 36 Patients with EGFR Positive Advanced NSCLC Who Received Gefitinib Plus Anlotinib Administration

The median follow-up duration for all the patients from the onset of the combination therapy to the date of data cut-off was 29.5 months (follow-up range=1.8–40.5 months). Regarding the PFS data, a total of 23 progression or death events were observed at the date of data cut-off, which yielded a maturity of PFS data of 63.9%. As illustrated in Figure 4, the median PFS of the 36 patients with EGFR positive NSCLC who received gefitinib plus anlotinib administration was 15.2 months (95% CI=8.15–22.26). And the 12-month PFS and 24-month PFS rates were 66.3% (95% CI=48.3–79.3%) and 34.0% (95% CI=17.1–51.7%), respectively.

Furthermore, the prognostic significance according to baseline characteristic subgroup was also performed for the potential relevance to PFS in univariate analysis. And the median PFS and 95% CI on the basis of baseline characteristic subgroups were presented. As shown in Table 2, it seemed that patients benefited from the combination administration of gefitinib plus anlotinib similarly, regardless of the baseline characteristic subgroups. However, ECOG PS score was significantly associated with PFS in univariate analysis. And the median PFS of patients with PS 0–1 score and 2 score



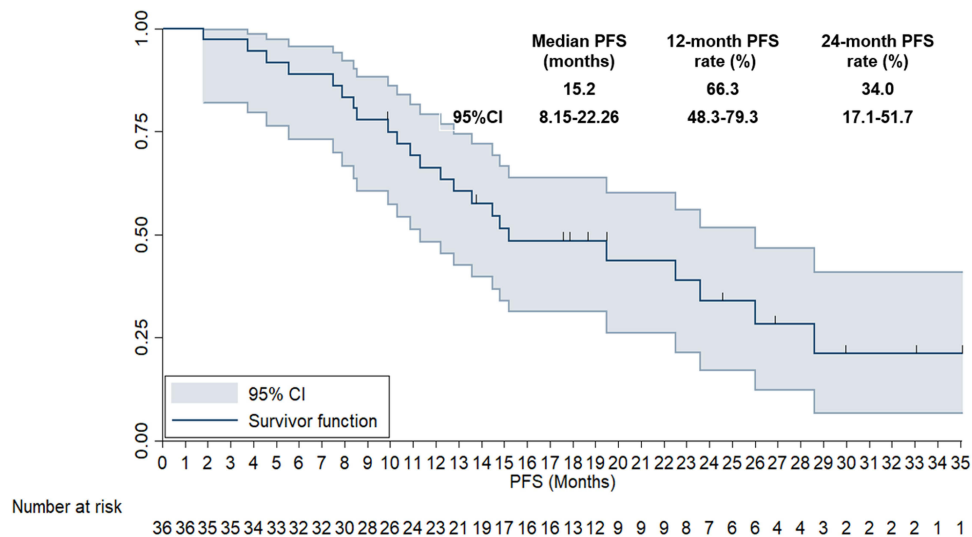
**Figure 2** Waterfall plot for the best percentage change in target lesion of the 36 patients with EGFR positive advanced non-small cell lung cancer who received gefitinib plus anlotinib administration [black columns represent PR, yellow columns represent SD and red column represents PD in the best overall response (although the target lesion shrank 5.5% compared with the target lesion in baseline of this patient who was presented in red column, new target lesion was detected during the efficacy assessment. Therefore, this patient was deemed as PD)].



**Figure 3** The CT scan results of the changes for target lesions in lymph node of one patient with non-small cell lung cancer before and after the administration of gefitinib plus anlotinib.

was 19.5 months and 13.6 months, respectively ( $P=0.019$ ). Interestingly, it should be noticed that patients with 12 mg initial dosage of anlotinib had a trend for better PFS than those with a 10 mg initial dosage of anlotinib, even the difference was not statistically significant (median PFS: 15.2 vs 12.8 months,  $P=0.218$ ). The other baseline characteristics conferred balanced PFS of the combination administration and no significant statistical difference was observed ( $P>0.05$ ).

Furthermore, the long follow-up duration yielded a relatively mature OS data in this study. And a total of 16 death events were observed at the date of data cut-off, and the maturity of OS data was 44.4%. As illustrated in Figure 5, the median overall survival (OS) of the 36 patients with EGFR positive NSCLC who received gefitinib plus anlotinib administration was 35.9 months (95% CI= 22.77–49.03). And the 24-month and 36-month OS rates were 67.4% (95% CI=48.6–80.6%) and 44.4% (95% CI=22.0–64.7%), respectively.



**Figure 4** The progression-free survival curve of the 36 patients with EGFR positive advanced non-small cell lung cancer who received gefitinib plus anlotinib administration.

## Safety Profile of the 36 Patients with EGFR Positive Advanced NSCLC Who Received Gefitinib Plus Anlotinib Administration

Maximum toxicity of the 36 patients with EGFR positive NSCLC occurring during the administration of gefitinib plus anlotinib was analyzed in this study. Totally, adverse events regardless of attribution were observed in all the 36 patients (100%). Nonetheless, adverse reactions were noted in 32 patients among the 36 patients (88.9%). And the adverse reactions of grade 3–4 were found in 15 patients among the 36 patients (41.7%). No grade 5 adverse reactions were found during the combination administration.

Specifically, as exhibited in Table 3, the common adverse reactions were diarrhea (63.9%), fatigue (58.3%), hypertension (50.0%), rash (44.4%), nausea and vomiting (41.7%), hand–foot syndrome (30.6%), abnormal liver function (25.0%), proteinuria (16.7%), stomatitis (13.9%), and constipation (8.3%). Furthermore, adverse reactions of grade 3–4 were hypertension (16.7%), diarrhea (8.3%), nausea and vomiting (8.3%), fatigue (5.6%), rash (5.6%), hand–foot syndrome (5.6%), abnormal liver function (5.6%), and proteinuria (2.8%). The overall safety profile was tolerable and manageable among the 36 patients with NSCLC who received the administration of gefitinib plus anlotinib.

## Discussion

This study highlighted the feasibility regarding the clinical outcome and safety of gefitinib plus anlotinib in a first-line setting for patients with EGFR positive advanced NSCLC in the real-world retrospectively. Collectively, the regimen of gefitinib plus anlotinib might be a potentially efficacious and safe treatment for patients with previously-untreated EGFR positive advanced NSCLC clinically.

Recent years had witnessed significant development of targeted drugs, immunotherapy, and antiangiogenic targeted drugs that dramatically improved the PFS of patients with advanced NSCLC in a first-line setting.<sup>21</sup> Especially in the therapeutic area for patients with EGFR positive NSCLC, gefitinib was the first EGFR-TKI that exhibited a promising response that was used over 10 years clinically.<sup>22</sup> Although gefitinib exhibited an extremely high ORR and could achieve longer PFS among patients with EGFR positive advanced NSCLC, most of EGFR positive patients would develop drug resistance in approximately 10 months after gefitinib treatment.<sup>23</sup> Amazingly, the third-generation EGFR-TKI (Osimertinib) was an irreversible EGFR-TKI for both sensitizing mutation and the T790M resistance mutation.<sup>24</sup> Therefore, it was initially approved for the treatment of EGFR positive patients exhibiting T790M positive mutation as the second-line setting and was now established as the new standard of care for all EGFR positive patients in first-line treatment.<sup>25</sup> It seemed that gefitinib plus anti-angiogenic therapy might be of low priority and clinical applicability. However, it should be noted that the FLAURA Asian subgroup analysis indicated that no OS benefit was observed

**Table 2** Univariate Analysis for PFS of the 36 Patients with EGFR Positive NSCLC According to Baseline Characteristics

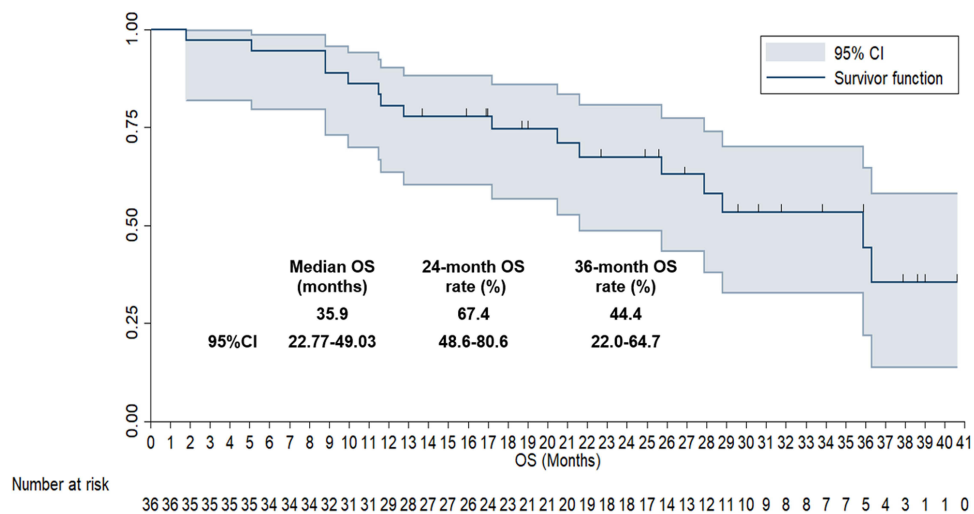
Characteristics	N	Median PFS (Months)	95% CI	P
<b>Age (years)</b>				
≥59	20	15.2	9.15–21.25	0.511
<59	16	14.8	7.74–21.86	
<b>Gender</b>				
Male	17	15.2	10.11–20.29	0.319
Female	19	19.5	14.37–24.63	
<b>Pathological stage</b>				
IIIb	3	14.5	7.19–21.81	0.443
IV	33	15.2	7.96–22.44	
<b>ECOG PS score</b>				
0–1	25	19.5	12.21–26.79	0.019
2	11	13.6	6.08–21.12	
<b>Smoking status</b>				
Nonsmoker	9	15.2	8.16–22.24	0.419
Smoker/former smoker	27	14.5	7.57–21.43	
<b>Brain metastasis</b>				
Yes	5	14.8	6.82–22.78	0.314
No	31	15.2	8.54–21.86	
<b>EGFR genomic aberration</b>				
Exon 19 del	19	19.5	10.66–28.34	0.435
Exon 21 L858A	17	15.2	6.05–24.35	
<b>Number of metastatic sites</b>				
≤2	11	15.2	7.33–23.07	0.631
>2	25	14.8	8.65–20.95	
<b>Initial dosage of anlotinib (mg)</b>				
12	30	15.2	9.71–20.69	0.218
10	6	12.8	7.22–18.38	

**Abbreviations:** EGFR, epidermal growth factor receptor; NSCLC, non-small cell lung cancer; ECOG, Eastern Cooperative Oncology Group; PS, performance status.

among patients in an Asian population,<sup>8</sup> which suggested that there was still an urgent need to investigate a combination therapeutic strategy to overcome EGFR-TKI resistance and to prolong the outcomes of patients with EGFR positive advanced NSCLC. Interestingly, the recent studies reported that first-generation EGFR TKI (gefitinib and erlotinib) plus bevacizumab regimen showed promising efficacy for patients with EGFR positive NSCLC in a first-line setting.<sup>7,9,26</sup> Therefore, exploring efficacious regimens of gefitinib plus anti-angiogenic agent was still a meaningful clinical practice. From the objective view, bevacizumab was an intravenous injection formulation and it was inconvenient for the patients when combined with oral gefitinib. As a result, it was necessary to investigate the preliminary clinical outcomes of gefitinib plus oral multi-target antiangiogenic tyrosine kinase inhibitors (anlotinib) clinically.

To our knowledge, the ORR and DCR of gefitinib monotherapy for patients with EGFR positive NSCLC in a first-line setting was approximately 72% and 84%, respectively.<sup>27</sup> And the ORR and DCR of anlotinib monotherapy for patients with NSCLC as third-line treatment was 9.2% and 81.0%, respectively.<sup>18</sup> In the present study, with the addition of anlotinib to gefitinib, the ORR and DCR improved to 83.3% and 97.2%, respectively. It seemed that combination of anlotinib plus gefitinib played a synergistic action potentially. Furthermore, the median PFS in this study was 15.2 months, which was dramatically longer than that of gefitinib monotherapy for patients with EGFR positive NSCLC in real-world practice (median PFS=11.9 months).<sup>28</sup> Furthermore, the PFS data in our study was consistent with that observed in the combination regimen of erlotinib (another EGFR TKI) plus bevacizumab numerically (median PFS ranged from 16.0 months to 17.9 months).<sup>26,29</sup> As a result, our study preliminarily suggested





**Figure 5** The overall survival curve of the 36 patients with EGFR positive advanced non-small cell lung cancer who received gefitinib plus anlotinib administration.

that gefitinib plus antiangiogenic TKI-anlotinib might be of valuable clinical significance for patients with EGFR positive NSCLC to prevent the progression of the disease. And the results in our study were consistent with another exploratory retrospective study initiated by Li et al.<sup>20</sup> They included a total of 20 patients with EGFR positive NSCLC and investigated the efficacy of combination treatment with anlotinib plus gefitinib in vitro and in vivo, which yielded a DCR of 100% and median PFS of 15.7 months. Besides, a recent phase III clinical trial initiated by Zhao et al<sup>9</sup> investigated the efficacy and safety of apatinib (another antiangiogenic TKI) plus gefitinib as first-line treatment in EGFR positive advanced NSCLC. A total of 313 patients were assigned to the apatinib plus gefitinib or placebo plus gefitinib group, and the ORR and median PFS of apatinib plus gefitinib group was 77.1% and 13.7 months. The efficacy of apatinib plus gefitinib was in concert with that in our study to some extent. The conclusion indicated that anlotinib plus gefitinib might play a synergistic action and improved the PFS for patients with gefitinib refractory EGFR positive NSCLC. Unfortunately, owing to the insufficient follow-up duration, both of the two above studies failed to evaluate the OS of the combination regimen. Therefore, given that the follow-up duration of our study was long enough (median follow-up duration: 29.5 months), OS analysis was also carried out ultimately. And the median OS of the 36 patients who received gefitinib plus anlotinib was 35.9 months, which was close to the final median OS reported in the FLAURA clinical trial (median OS was 38.6 months and 31.8 months of Osimertinib and gefitinib group, respectively).<sup>30</sup> And it should be noted that the median OS in our study was longer than that of gefitinib for

**Table 3** Adverse Reactions of the 36 Patients with EGFR Positive NSCLC Who Received Gefitinib Plus Anlotinib Administration

Adverse Reactions	Total (N, %)	Grade 1–2 (N, %)	Grade 3–4 (N, %)
Diarrhea	23 (63.9)	20 (87.0)	3 (8.3)
Fatigue	21 (58.3)	19 (52.8)	2 (5.6)
Hypertension	18 (50.0)	12 (33.3)	6 (16.7)
Rash	16 (44.4)	14 (38.9)	2 (5.6)
Nausea and vomiting	15 (41.7)	12 (33.3)	3 (8.3)
Hand-foot syndrome	11 (30.6)	9 (25.0)	2 (5.6)
Abnormal liver function	9 (25.0)	7 (19.4)	2 (5.6)
Proteinuria	6 (16.7)	5 (13.9)	1 (2.8)
Stomatitis	5 (13.9)	5 (13.9)	0 (0.0)
Constipation	3 (8.3)	3 (8.3)	0 (0.0)

**Abbreviations:** EGFR, epidermal growth factor receptor; NSCLC, non-small cell lung cancer.

patients with EGFR positive NSCLC in real-world practice (median OS: 35.9 months vs 26.9 months).<sup>28</sup> We speculated that the superior OS of patients with EGFR positive NSCLC who received anlotinib plus gefitinib could be attributed to the fact that considerable targeted drugs (EGFR-TKIs) and immunotherapy drugs (PD-1 or PD-L1 inhibitors) were approved in China since 2018, which might contribute to the survival benefit for the patients with EGFR positive NSCLC in subsequent line therapy consecutively.

Interestingly, the univariate analysis according to baseline characteristic subgroup was also performed to identify the potential factors that might contribute to the PFS of gefitinib plus anlotinib. Results suggested that patients might benefit from the combination administration of gefitinib plus anlotinib similarly, regardless of the baseline characteristic subgroups. However, ECOG performance status was significantly associated with PFS in univariate analysis, which indicated that patients with ECOG performance status of 2 score might suffer a worse PFS compared with those of 0–1 score. This finding was consistent with the previous study that ECOG performance status was confirmed to be an independent prognostic factor to predict the survival among patients with NSCLC.<sup>31</sup> Besides, it should be noted that patients with 10 mg anlotinib dosage had a trend for worse PFS compared with those with 12 mg anlotinib dosage (median PFS: 15.2 vs 12.8 months), even the difference was not statistically significant in the univariate analysis ( $P=0.218$ ). We speculated this could be attributed to the fact that a cohort of patients with poor performance status stood a good chance to choose 10 mg anlotinib rather than 12 mg, thus resulting in a worse PFS to some extent. And the conclusion should be validated in large-scale prospective trials. Furthermore, owing to the retrospective design of our study and the conventional EGFR detection technology, no next-generation sequencing (NGS) results regarding the gene mutation profile of the 36 patients were available currently. And we should perform the association analysis to identify the clinical significance of co-mutation and mutation load among patients with EGFR-positive NSCLC who received gefitinib plus anlotinib treatment in the future.

The overall adverse reactions of the combination administration of anlotinib plus gefitinib were tolerable and manageable, which was consistent with the previous reports regarding the combination therapy of antiangiogenic TKI (apatinib) plus gefitinib in EGFR positive NSCLC.<sup>9</sup> Interestingly, the incidence of grade 3–4 adverse reactions was 41.7%, which was higher than that observed in the treatment of gefitinib monotherapy (grade  $\geq 3$  adverse reactions: 37.7%) and lower than that found in the regimen of apatinib plus gefitinib (grade  $\geq 3$  adverse reactions: 84.1%) numerically. It seemed that anlotinib plus gefitinib was safer for the patients with EGFR positive NSCLC. Specifically, the most common adverse actions of anlotinib plus gefitinib were fatigue, hypertension, and hand–foot syndrome, which might be attributed to the treatment of anlotinib and were consistent with the safety profile of the previous study regarding anlotinib in patients with NSCLC in real-world practice.<sup>32</sup> Other adverse reactions such as rash and stomatitis were also observed, which might have resulted from the administration of gefitinib therapy.<sup>9</sup> Interestingly, the overall incidence of the adverse reactions in our study was relatively lower than that observed in the phase III clinical trial.<sup>7</sup> We speculated that this discrepancy might be attributed to the retrospective design of our study and the previous retrospective study suggested that adverse reactions of the retrospective study were documented poorly and insufficiently compared to well-designed prospective clinical trials.<sup>33</sup> However, the finding should be validated in prospective clinical trials subsequently. In a word, the overall safety profile of the anlotinib plus gefitinib regimen was acceptable and manageable in real-world practice.

From the objective view, limitations existed in the present study inevitably. Firstly, the sample size was small for a real-world study, only 36 patients were enrolled. Clinical outcomes of gefitinib plus anlotinib still need to be confirmed in a larger sample size. Secondly, the present study was designed as a retrospective analysis and some bias could not be avoided, and the patient management was not sufficient when compared with the prospective clinical trial. Furthermore, the maturity of PFS and OS data was still needed to be improved in the subsequent follow-up. We believe our study is of potentially clinical significance to provide real-world evidence for patients with EGFR positive NSCLC who receive gefitinib plus anlotinib administration.

## Conclusion

This study provided real-world evidence that a gefitinib plus anlotinib regimen demonstrated encouraging efficacy and an acceptable safety profile for patients with previously-untreated EGFR positive NSCLC preliminarily. And the conclusion should be validated in prospective clinical trials subsequently.

## Disclosure

The authors declare that there are no conflicts of interest in this work.

## References

1. Wu F, Wang L, Zhou C. Lung cancer in China: current and prospect. *Curr Opin Oncol.* 2021;33(1):40–46. doi:10.1097/cco.0000000000000703
2. Zhang J, Mao W, Chen Z, Gu H, Lian C. Clinical significance of Has\_circ\_0060937 in bone metastasis of NSCLC. *Int J Gen Med.* 2020;13:1115–1121. doi:10.2147/ijgm.s279023
3. Hu W, Li B, Geng N, et al. Association between PDL1 genetic variation and efficacy of apatinib monotherapy in patients with previously treated advanced NSCLC: a real-world retrospective study. *Int J Gen Med.* 2021;14:2703–2714. doi:10.2147/ijgm.s303717
4. Maemondo M, Inoue A, Kobayashi K, et al. Gefitinib or chemotherapy for non-small-cell lung cancer with mutated EGFR. *N Engl J Med.* 2010;362(25):2380–2388. doi:10.1056/NEJMoa0909530
5. Jahanzeb M, Lin HM, Pan X, et al. Immunotherapy treatment patterns and outcomes among ALK-positive patients with non-small-cell lung cancer. *Clin Lung Cancer.* 2021;22(1):49–57. doi:10.1016/j.clcc.2020.08.003
6. Passaro A, Mok T, Peters S, et al. Recent advances on the role of EGFR tyrosine kinase inhibitors in the management of NSCLC with uncommon, non exon 20 insertions, EGFR mutations. *J Thorac Oncol.* 2021;16(5):764–773. doi:10.1016/j.jtho.2020.12.002
7. Saito H, Fukuhara T, Furuya N, et al. Erlotinib plus bevacizumab versus erlotinib alone in patients with EGFR-positive advanced non-squamous non-small-cell lung cancer (NEJ026): interim analysis of an open-label, randomised, multicentre, Phase 3 trial. *Lancet Oncol.* 2019;20(5):625–635. doi:10.1016/s1470-2045(19)30035-x
8. Soria JC, Ohe Y, Vansteenkiste J, et al. Osimertinib in untreated EGFR-mutated advanced non-small-cell lung cancer. *N Engl J Med.* 2018;378(2):113–125. doi:10.1056/NEJMoa1713137
9. Zhao H, Yao W, Min X, et al. Apatinib plus gefitinib as first-line treatment in advanced EGFR-mutant NSCLC: the phase III ACTIVE study (CTONG1706). *J Thorac Oncol.* 2021;16(9):1533–1546. doi:10.1016/j.jtho.2021.05.006
10. Larsen AK, Ouaret D, El Oudrani K, Petitprez A. Targeting EGFR and VEGF (R) pathway cross-talk in tumor survival and angiogenesis. *Pharmacol Ther.* 2011;131(1):80–90. doi:10.1016/j.pharmthera.2011.03.012
11. Le X, Nilsson M, Goldman J, et al. Dual EGFR-VEGF pathway inhibition: a promising strategy for patients with EGFR-mutant NSCLC. *J Thorac Oncol.* 2021;16(2):205–215. doi:10.1016/j.jtho.2020.10.006
12. Folkman J. Tumor angiogenesis: therapeutic implications. *N Engl J Med.* 1971;285(21):1182–1186. doi:10.1056/nejm197111182852108
13. Manzo A, Montanino A, Carillio G, et al. Angiogenesis inhibitors in NSCLC. *Int J Mol Sci.* 2017;18(10):2021. doi:10.3390/ijms18102021
14. Masuda C, Yanagisawa M, Yorozu K, et al. Bevacizumab counteracts VEGF-dependent resistance to erlotinib in an EGFR-mutated NSCLC xenograft model. *Int J Oncol.* 2017;51(2):425–434. doi:10.3892/ijo.2017.4036
15. Naumov GN, Nilsson MB, Cascone T, et al. Combined vascular endothelial growth factor receptor and epidermal growth factor receptor (EGFR) blockade inhibits tumor growth in xenograft models of EGFR inhibitor resistance. *Clin Cancer Res.* 2009;15(10):3484–3494. doi:10.1158/1078-0432.ccr-08-2904
16. Neal JW, Dahlberg SE, Wakelee HA, et al. Erlotinib, cabozantinib, or erlotinib plus cabozantinib as second-line or third-line treatment of patients with EGFR wild-type advanced non-small-cell lung cancer (ECOG-ACRIN 1512): a randomised, controlled, open-label, multicentre, Phase 2 trial. *Lancet Oncol.* 2016;17(12):1661–1671. doi:10.1016/s1470-2045(16)30561-7
17. Reckamp KL, Frankel PH, Ruel N, et al. Phase II trial of cabozantinib plus erlotinib in patients with advanced epidermal growth factor receptor (EGFR)-mutant non-small cell lung cancer with progressive disease on epidermal growth factor receptor tyrosine kinase inhibitor therapy: a California cancer consortium phase II trial (NCI 9303). *Front Oncol.* 2019;9:132. doi:10.3389/fonc.2019.00132
18. Han B, Li K, Wang Q, et al. Effect of anlotinib as a third-line or further treatment on overall survival of patients with advanced non-small cell lung cancer: the ALTER 0303 phase 3 randomized clinical trial. *JAMA Oncol.* 2018;4(11):1569–1575. doi:10.1001/jamaoncol.2018.3039
19. Cheng Y, Wang Q, Li K, et al. Anlotinib vs placebo as third- or further-line treatment for patients with small cell lung cancer: a randomised, double-blind, placebo-controlled phase 2 study. *Br J Cancer.* 2021;125(3):366–371. doi:10.1038/s41416-021-01356-3
20. Li T, Qian Y, Zhang C, et al. Anlotinib combined with gefitinib can significantly improve the proliferation of epidermal growth factor receptor-mutant advanced non-small cell lung cancer in vitro and in vivo. *Transl Lung Cancer Res.* 2021;10(4):1873–1888. doi:10.21037/tlcr-21-192
21. Brozos-Vázquez EM, Díaz-Peña R, García-González J, et al. Immunotherapy in nonsmall-cell lung cancer: current status and future prospects for liquid biopsy. *Cancer Immunol Immunother.* 2021;70(5):1177–1188. doi:10.1007/s00262-020-02752-z
22. Noronha V, Patil VM, Joshi A, et al. Gefitinib versus gefitinib plus pemetrexed and carboplatin chemotherapy in EGFR-mutated lung cancer. *J Clin Oncol.* 2020;38(2):124–136. doi:10.1200/jco.19.01154
23. Wu SG, Shih JY. Management of acquired resistance to EGFR TKI-targeted therapy in advanced non-small cell lung cancer. *Mol Cancer.* 2018;17(1):38. doi:10.1186/s12943-018-0777-1
24. Nagasaka M, Zhu VW, Lim SM, et al. Beyond osimertinib: the development of third-generation EGFR tyrosine kinase inhibitors for advanced EGFR+ NSCLC. *J Thorac Oncol.* 2021;16(5):740–763. doi:10.1016/j.jtho.2020.11.028
25. Papadimitrakopoulou VA, Mok TS, Han JY, et al. Osimertinib versus platinum-pemetrexed for patients with EGFR T790M advanced NSCLC and progression on a prior EGFR-tyrosine kinase inhibitor: AURA3 overall survival analysis. *Ann Oncol.* 2020;31(11):1536–1544. doi:10.1016/j.annonc.2020.08.2100
26. Stinchcombe TE, Jänne PA, Wang X, et al. Effect of erlotinib plus bevacizumab vs erlotinib alone on progression-free survival in patients with advanced EGFR-mutant non-small cell lung cancer: a phase 2 randomized clinical trial. *JAMA Oncol.* 2019;5(10):1448–1455. doi:10.1001/jamaoncol.2019.1847
27. Wu YL, Cheng Y, Zhou X, et al. Dacomitinib versus gefitinib as first-line treatment for patients with EGFR-mutation-positive non-small-cell lung cancer (ARCHER 1050): a randomised, open-label, phase 3 trial. *Lancet Oncol.* 2017;18(11):1454–1466. doi:10.1016/s1470-2045(17)30608-3
28. Yao ZH, Liao WY, Ho CC, et al. Real-world data on prognostic factors for overall survival in EGFR mutation-positive advanced non-small cell lung cancer patients treated with first-line gefitinib. *Oncologist.* 2017;22(9):1075–1083. doi:10.1634/theoncologist.2016-0331

29. Seto T, Kato T, Nishio M, et al. Erlotinib alone or with bevacizumab as first-line therapy in patients with advanced non-squamous non-small-cell lung cancer harbouring EGFR mutations (JO25567): an open-label, randomised, multicentre, phase 2 study. *Lancet Oncol.* 2014;15(11):1236–1244. doi:10.1016/s1470-2045(14)70381-x
30. Ramalingam SS, Vansteenkiste J, Planchard D, et al. Overall survival with osimertinib in untreated, EGFR-mutated advanced NSCLC. *N Engl J Med.* 2020;382(1):41–50. doi:10.1056/NEJMoa1913662
31. Geng N, Su J, Liu Z, et al. The influence of KDR genetic variation on the efficacy and safety of patients with advanced NSCLC receiving first-line bevacizumab plus chemotherapy regimen. *Technol Cancer Res Treat.* 2021;20:15330338211019433. doi:10.1177/15330338211019433
32. Cheng JD, Chai LX, Zhao ZP, Hao YY, Li S. Efficacy and safety of anlotinib for patients with advanced NSCLC who progressed after standard regimens and the preliminary analysis of an efficacy predictor. *Cancer Manag Res.* 2020;12:5641–5650. doi:10.2147/cmar.s253366
33. Wang RT, Zhao Y, Wang AL, et al. Efficacy and safety of regorafenib monotherapy among patients with previously treated metastatic colorectal cancer in a Chinese population: a real-world exploratory study. *Int J Gen Med.* 2021;14:5363–5373. doi:10.2147/ijgm.s325545

International Journal of General Medicine

Dovepress

## Publish your work in this journal

The International Journal of General Medicine is an international, peer-reviewed open-access journal that focuses on general and internal medicine, pathogenesis, epidemiology, diagnosis, monitoring and treatment protocols. The journal is characterized by the rapid reporting of reviews, original research and clinical studies across all disease areas. The manuscript management system is completely online and includes a very quick and fair peer-review system, which is all easy to use. Visit <http://www.dovepress.com/testimonials.php> to read real quotes from published authors.

Submit your manuscript here: <https://www.dovepress.com/international-journal-of-general-medicine-journal>