

# 轉移子宮頸癌病人合併牛胃掌、黑棘皮症及 密集性皮膚乳突瘤

蔡侑儒 蔡宜政 全鳴鐸 胡淑玲  
國泰綜合醫院 皮膚科

## The Combination of Tripe Palms, Acanthosis Nigricans and Florid Cutaneous Papillomatosis in a Patient with Metastatic Cervical Cancer

Yu-Ju Tsai Yi-Jeng Tsai Ming-Tuo Chuan Shu-Ling Hu

Tripe palms, which described the thickening of pamar skin with increase of normal dermatoglyphics and a peculiar velvety texture, is a specific cutaneous paraneoplastic syndrome especially related to cancers of upper aerodigestive tract. Acanthosis nigricans, and florid cutaneous papillomatosis (sudden appearance of many warty skin lesions) are the most commonly associated paraneoplastic dermatosis. All three may be part of a continuum, caused by factors produced by the underlying malignancy. A thorough investigation for an underlying malignancy is warranted for all patients with tripe palms and/or florid cutaneous papillomatosis. We reported a 55-year-old female initially presented with tripe palms. After detailed cutaneous survey, acanthosis nigricans and florid cutaneous papillomatosis were also found. Thorough examinations revealed recurrence and metastasis of her cervical cancer. (Dermatol Sinica 22 : 142-147, 2004)

*Key words:* Tripe palms, Cutaneous paraneoplastic syndrome, Acanthosis nigricans, Florid cutaneous papillomatosis, Cervical cancer

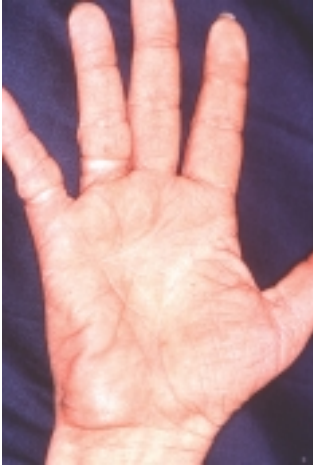牛胃掌(tripe palms)意指手掌處的皮膚變厚、掌紋變深並顯現天鵝絨般的質感。大多數典型牛胃掌都是伴腫瘤性的皮膚變化，尤其源於上消化呼吸道的癌症。黑棘皮症及密集性皮膚乳突瘤是最常伴隨的皮膚病變，它們可能代表者同一個病因在不同部位的皮膚的表現。因此對所有牛胃掌或密集性皮膚乳突瘤的病人，都需要有完整的癌症篩檢。我們報告一例五十五歲女性，因手腳皮膚變厚就診，經診斷為牛胃掌，伴隨黑棘皮症及密集性皮膚乳突瘤等皮膚病變，我們進一步發現患者體內的子宮頸癌已呈現復發及廣泛性的轉移。(中華皮誌22 : 142-147, 2004)

*From the Department of Dermatology, Cathay General Hospital*

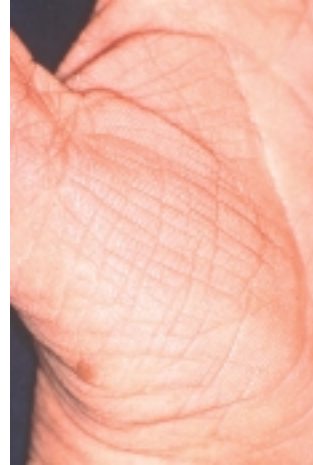
*Accepted for publication: December 18, 2003*

*Reprint requests: Ming-Tuo Chuan, M.D., Department of Dermatology, Cathay General Hospital, No 280, Section 4, Jen-Ai Road, Taipei, Taiwan, R.O.C.*

*TEL: 886-2-27082121 ext. 5078 FAX: 886-2-27074949*



**Fig. 1**  
Exaggeration of normal dermatoglyphics of the palm.



**Fig. 2**  
Close view showing velvety rugose appearance of thenar skin with accentuation of normal skin markings.

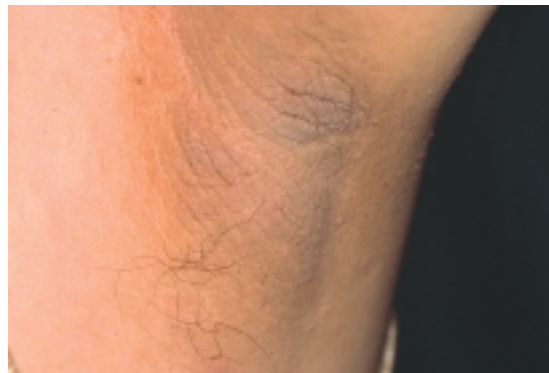## INTRODUCTION

The first appearance in medical literature of the term 'tripe' in association with internal malignancy was in 1971, when Dr. Roy Summerly recalled a patient describing his own palms as "tripe hands" due to its resemblance to the bovine foregut prepared for edible consumption.<sup>1</sup> The term was further popularized to describe the peculiar thickened appearance of palmar skin, characterized by increase in the normal dermatoglyphic pattern and a peculiar velvety texture.<sup>2,3</sup> Cohen *et al.*, in 1993<sup>1</sup>, reviewed the literature about this peculiar cutaneous condition and found 91% (79 out of 87 patients) were associated with internal malignancy. Pulmonary and gastric carcinomas were the most common neoplasm in their review. Other associated paraneoplastic dermatosis are acanthosis nigricans, florid cutaneous papillomatosis, Leser-Trelat sign and pruritus.<sup>1</sup> The skin changes may precede, accompany or follow the diagnosis of the underlying neoplasm, and often heralding an aggressive course.<sup>4</sup>

We reported a patient having the combination of tripe palms, acanthosis nigricans and florid cutaneous papillomatosis lesions, which disclosed the recurrence and metastasis of her cervical cancer.

## CASE REPORT

A 55-year-old woman with cervical cancer underwent surgical excision in July 1999. She received 6 courses of chemotherapy due to one positive sentinel lymph node (total 16 lymph nodes). No recurrence of cervical cancer during irregular follows up. In Aug 2002, she visited our hospital for checking the thickening changes of her palmoplantar skin. Besides, some flesh-colored papules on bilateral thighs and dorsal hands appeared simultaneously in the past 6 months. These lesions persisted despite of liquid nitrogen therapy at another hospital.



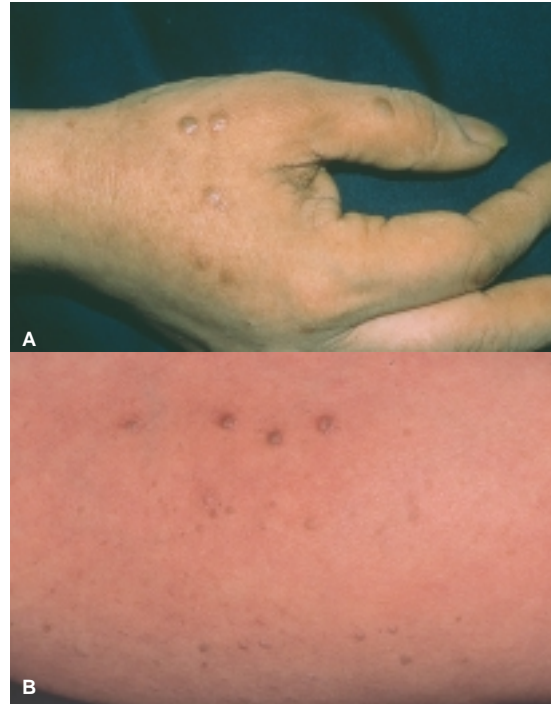
**Fig. 3**  
Acanthosis nigricans of axilla. Similar changes were found at waist and nape.

Physical examination revealed brownish-yellow thickening of palmoplantar skin (Fig. 1, 2). After detailed examination, gray-brown, velvety cutaneous changes were disclosed over her neck, axillae, and waist (Fig. 3), so were many flesh-colored hyperkeratotic papules scattering over her dorsal hands (Fig. 4a) and thighs (Fig. 4b). Besides, a pigeon-egg sized, hard, fixed subcutaneous nodule over right inguinal area was also found. Histological examination of her

**Fig. 4a**

palmar skin biopsy revealed epidermal acanthosis with compact hyperkeratosis (Fig. 5). One of the flesh-colored papules over her thigh disclosed acanthosis, papillomatosis and hyperkeratosis (Fig. 6).

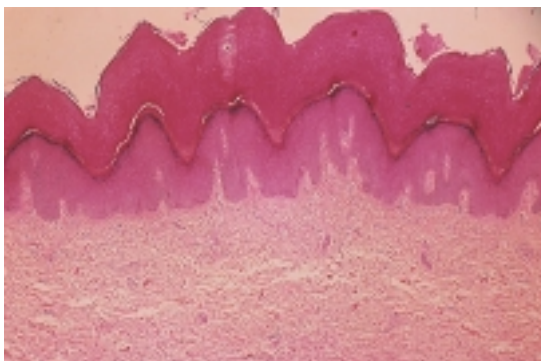
Blood sampling for tumor markers revealed elevated SCC (51.6 ng/ml (0-2.5)) and CA 125 (107.7 $\mu$ /ml (<35)). Transvaginal sonography found a virginal stump mass (4.4 x 2.9 x 2.6cm) and a right inguinal mass (2.9 x 2.3cm). Squamous cell carcinoma was confirmed by biopsy of the stump. CT scan of abdomen and pelvis detected a 3 x 3 x 6 cm tumor in the Douglas pouch, multiple lymph nodes at bilateral para-aortic, bilateral common iliac, and right internal iliac region, bony destruction of the 4th lumbar vertebral spine and a splenic mass 3.5 cm in diameter mass. She



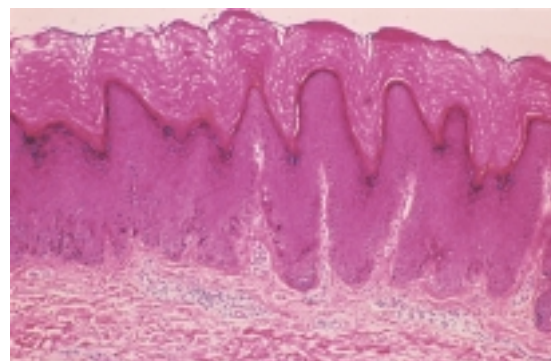
**Fig. 4**

Some flesh-colored papules over the patient's dorsal hand (Fig 4a) and thigh (Fig 4b) that has similar appearance with viral warts. Some of them had been treated by liquid nitrogen before.

was then transferred to Koo Foundation Sun Yat-Sen Cancer Center. Her skin changes improved after chemotherapy there.



**Fig. 5**  
Marked hyperkeratosis and acanthosis of palmar skin. (H & E, 40x)



**Fig. 6**  
One of the flesh-colored papules on thigh showing marked hyperkeratosis, acanthosis and papillomatosis. (H & E, 100x)

## DISCUSSION

Tripe palms are an uncommon clinical condition. To our knowledge, only 94 patients have been reported in the English literature before and about 90% were malignancy associated.<sup>1,4-10</sup> The peculiar thickening change may also involve soles in addition to palms, as in our patient.<sup>9</sup> Tripe palms is usually asymptomatic, though cases associated with hyperhidrosis of palms have been reported.<sup>3,11</sup> The clinical appearances of tripe palms are similar in patients with or without underlying malignancy. The palms are thickened and have a moss like or velvety texture. The dermatoglyphics are often pronounced and exaggerated. Occasionally, the palmar surface of the hands and fingers are cobbled or honeycombed. Published synonyms include acanthosis nigricans of the palms, acanthosis palmaris, pachydermatoglyphy, palmar hyperkeratosis, and palmar keratoderma. Histological findings of tripe palms are similar to those described in acanthosis nigricans, with all biopsies showing acanthosis and hyperkeratosis. In addition, papillomatosis, dermal mucin deposition and increased dermal mast cells may occasionally be found.<sup>1</sup>

Tripe palms fulfill the criteria for paraneoplastic dermatosis. 85 patients (89%) of the 95 reported tripe palms, including our case, occurred in patients with cancer.<sup>1,4-10</sup> Neoplasms most commonly associated are of pulmonary and gastric origin, accounting for more than half of the malignancies. Nearly one fifth of the associated cancers were of genitourinary tract origin. Cervical cancer has been reported previously only in 3 patients.<sup>12-14</sup> Other associated cancers include breast carcinoma, tumor of the head and neck, sarcoma, carcinoma of colon or gallbladder, astrocytoma, melanoma, non-Hodgkin's lymphoma, and pancreatic carcinoma.<sup>1,15</sup> Diagnosis of tripe palms most often precedes, but may be simultaneous, or follow the diagnosis of malignancy. Successful treatment of the underlying malignancy accompany regression of skin changes, as in our patient.<sup>1,6</sup> In some of the patients with malignancy-associated tripe palms, the appearance of tripe palms

occurred in association with the recurrence or metastasis of their malignancy.<sup>1,10</sup> Idiopathic tripe palms has been described in association with endocrinopathies, such as diabetes mellitus or thyroid goiter, hyperproliferative dermatosis include psoriasis, exfoliative dermatitis, or other conditions such as congestive heart failure, chronic bronchitis, bullous pemphigoid, systemic mastocytosis, etc.<sup>1,8</sup>

Other cutaneous paraneoplastic syndromes may coexist with malignancy-associated tripe palms. Acanthosis nigricans was the most frequently coexistent paraneoplastic sign, occurring in 72% of malignant tripe palms. Therefore, tripe palms has been postulated to represent a special palmar variant of acanthosis nigricans.<sup>9</sup> When acanthosis nigricans is associated with tripe palms, gastric carcinoma is the most common underlying neoplasm followed by pulmonary carcinoma. If tripe palms occurred without acanthosis nigricans, pulmonary carcinoma is the more frequently encountered conditions.<sup>1</sup> Other commonly associated cutaneous manifestations included florid cutaneous papillomatosis, pruritus, and the sign of Lesser-Trélat, occurring in 30%, 25%, and 20% respectively.<sup>1</sup>

The flesh-colored warty papules over extremities of our patient may be the initial presentation of florid cutaneous papillomatosis. This term refers to the rapid onset of numerous skin lesions indistinguishable from common viral warts. They usually begin on extremities, especially on the backs of hands and wrists, but may disseminate to the entire body and face. All previously reported cases were associated with cancers; with gastric carcinoma being the most commonly identified malignancy.<sup>16</sup> Clinical associations include pruritus, acanthosis nigricans and other cutaneous paraneoplastic syndromes. The histological features include pronounced hyperkeratosis, acanthosis and papillomatosis without evidence of viral infection. The combination of florid cutaneous papillomatosis with tripe palms and acanthosis nigricans was rare.

The pathogenesis of these paraneoplastic dermatoses remains unknown. It is possible that

the cutaneous lesions represent a response of the epidermis to a stimulating factors released by the associated tumor. Epidermal growth factor (EGF)<sup>6</sup> and transforming growth factor- $\alpha$  (TGF- $\alpha$ )<sup>15, 18</sup> were the most commonly mentioned. Both factors act through binding to the epidermal growth factor receptor (EGFR), and may be responsible for several cutaneous paraneoplastic syndromes, including tripe palms, acanthosis nigricans, the sign of Leser-Trélat and florid cutaneous papillomatosis.<sup>6, 15-18</sup> There was also one report of elevated TNF- $\alpha$  in a case of tripe palms associated with systemic mastocytosis.<sup>8</sup> Further evidence is the decreased serum levels of EGF or TGF- $\alpha$  accompanied by improvement of skin lesions after treatment of underlying disease.<sup>6, 8, 18</sup> The EGFR signal transduction pathway is important in the growth, invasiveness and metastatic potential of many human tumors, and over expression of EGFR is common in a variety of human epithelial malignancies.<sup>17, 18</sup> Therefore, malignant acanthosis nigricans, tripe palms, and florid cutaneous papillomatosis may be part of a continuum.<sup>16</sup> They may be caused by EGF, TGF- $\alpha$  or other unknown factors produced by the underlying disease acting through the EGFR pathway. When confronted with a patient of malignant acanthosis nigricans, tripe palms, or florid cutaneous papillomatosis, EGF or TGF- $\alpha$  level may be another tumor marker for monitoring effectiveness of treatment and early recognition of cancer recurrence.

The clinical differential diagnosis of tripe palms includes pachydermia of pachydermoperiostosis, hypertrophic pulmonary osteoarthropathy, acromegaly, thyroid acropachy, palmo-plantar keratoderma of Bazex syndrome, keratosis palmaris et plantaris and even in some manual labor workers. From clinical features, laboratory abnormalities and radiological changes of bony structure, one can readily differentiate tripe palms from most of them. Bazex syndrome is characterized by erythematous scaling psoriasiform lesions on ears, nose besides fingers and toes, which is absent in tripe palms. In either the hereditary or the acquired form of

keratosis palmaris et plantaris, the palmar ridges, furrows and dermatoglyphics are diminished secondary to the generalized thickening of ventral hands, which are different from tripe palms. The hands of manual labor worker may also present as thickened palmar skin. However, it is not as homogenous and symmetrical as tripe palms, which involves bilateral ventral sides of hands and sides of fingers.

In conclusion, tripe palms is one of the most significant paraneoplastic cutaneous manifestation, with about 90% of patients associated with internal malignancy. We should be alert to such sign and evaluate all presented cases for underlying malignancy thoroughly. Because this cutaneous sign may precede malignancy for years, regular follow up is recommended if the initial survey had negative finding. Herein, we report a case presented with tripe palms, acanthosis nigricans, and florid cutaneous papillomatosis as an indicator of the recurrence and metastasis of her cervical cancer.

## REFERENCES

1. Cohen PR, Grossman ME, Silvers DN L, *et al.*: Tripe palms and malignancy. *Clin Dermatol* 11: 165-173, 1993.
2. Clarke J: Malignant acanthosis nigricans. *Clin Exp Dermatol* 2: 167-170, 1977.
3. Breathnach SM, Wells GC: Acanthosis palmaris: Tripe palms. A distinctive pattern of palmar keratoderma frequently associated with internal malignancy. *Clin Exp Dermatol* 5: 181-189, 1980.
4. Ravnbrong L, Thomsen K: Acanthosis nigricans and bile duct malignancy. *Acta Derm Venereol (Stockh)* 73: 378-379, 1993
5. Requena L, Aguilar A, Renedo G, *et al.*: Tripe palms: A cutaneous marker of internal malignancy. *J Dermatol* 22: 492-495, 1995.
6. Douglas F, McHenry PM, Dagg JH, *et al.*: Elevated levels of epidermal growth factor in a patient with tripe palms. *Br J Dermatol* 130: 686-687, 1994.
7. Siragusa M, Batolo D, Schepis C: A new patient with idiopathic tripe palms. *Acta Derm Venereol (Stockh)* 77: 397, 1997.
8. Chosidow O, Becherel PA, Piettr JC, *et al.*: Tripe palms associated with systemic mastocytosis: the role of transforming growth factor- $\alpha$  and efficacy

- of interferon- $\alpha$ . *Br J Dermatol* 138: 698-703, 1998.
9. Stavrianeas NG, Katoulis AC, Neofotistou O, *et al.*: Tripe palms preceding squamous cell carcinoma of the lung by 11 months. *Dermatology* 198: 173-174, 1999.
  10. Mohrenschlager M, Vocks E, Wessner DB, *et al.*: Tripe palms and malignant acanthosis nigricans: cutaneous signs of imminent metastasis in bladder cancer? *J Urol* 165: 1629-1630, 2001.
  11. Cohen PR, Kurzrock R: Malignancy-associated tripe palms. *J Am Acad Dermatol* 27: 271-272, 1992.
  12. Mikhail GR, Fachnie AM, Drukker BH, *et al.*: Generalized malignant acanthosis nigricans. *Arch Dermatol* 115: 201-202, 1979.
  13. Liddell K, Jensen NE: Malignant acanthosis nigricans and its unusual association carcinoma of the colon and carcinoma of the cervix. *Br J Surg* 63: 248-250, 1976
  14. Hare RJ. Acanthosis nigricans. *Proc R Soc Med* 50: 276, 1957.
  15. Ellis DL, Kafka SP, Chow JC, *et al.*: Melanoma, growth factors, acanthosis nigricans, the sign of Lesser-Trelat, and multiple acrochordons: A possible role for alpha-transforming growth factor in cutaneous paraneoplastic syndromes. *N Engl J Med* 317: 1582-1587, 1987.
  16. Gheeraert P, Goens J, Schwartz RA, *et al.*: Florid cutaneous papillomatosis, malignant acanthosis nigricans, and pulmonary squamous cell carcinoma. *Inter J Dermatol* 30: 193-197, 1991.
  17. Yoneda T, Alsina MM, Watatani K, *et al.*: Dependence of a human carcinoma and associated paraneoplastic syndromes on the epidermal growth factor receptor pathway in nude mice. *Cancer Res* 51: 2438-2443, 1991.
  18. Koyama S, Ikeda K, Sato M, *et al.*: Transforming growth factor-alpha (TGF- $\alpha$ )-producing gastric carcinoma with acanthosis nigricans: An endocrine effect of TGF- $\alpha$  in the pathogenesis of cutaneous paraneoplastic syndrome and epithelial hyperplasia of the esophagus. *J Gastroenterol* 32: 71-77, 1997.