

Original Article

Angio negative spontaneous subarachnoid hemorrhage: Is repeat angiogram required in all cases?

Rajan Kumar, Kuntal Kanti Das, Rajni K. Sahu, Pradeep Sharma, Anant Mehrotra, Arun K. Srivastava, Rabi N. Sahu, Awadhesh K. Jaiswal, Sanjay Behari

Department of Neurosurgery, Sanjay Gandhi Post Graduate Institute of Medical Science, Lucknow, Uttar Pradesh, India

E-mail: Rajan Kumar - kumar.rajn62@gmail.com; Kuntal Kanti Das - drkuntalkantidas@gmail.com; Rajni K. Sahu - dr.rajnikants@gmail.com; Pradeep Sharma - dr.pradd@gmail.com; Anant Mehrotra - dranantmehrotra@gmail.com; Arun K. Srivastava - doctorarunsrivastava@gmail.com; Rabi N. Sahu - drnsahu@gmail.com; *Awadhesh K. Jaiswal - jaiswal_dr_2002@yahoo.co.in; Sanjay Behari - sbehari27@yahoo.com

*Corresponding author

Received: 28 February 14 Accepted: 18 June 14 Published: 07 August 14

This article may be cited as:

Kumar R, Das KK, Sahu RK, Sharma P, Mehrotra A, Srivastava AK, et al. Angio negative spontaneous subarachnoid hemorrhage: Is repeat angiogram required in all cases?. *Surg Neurol Int* 2014;5:125.

Available FREE in open access from: <http://www.surgicalneurologyint.com/text.asp?2014/5/1/125/138367>

Copyright: © 2014 Kumar R. This is an open-access article distributed under the terms of the Creative Commons Attribution License, which permits unrestricted use, distribution, and reproduction in any medium, provided the original author and source are credited.

Abstract

Background: In some cases of spontaneous subarachnoid hemorrhage (SAH), the cause of bleed remains obscure on initial evaluation. These patients may harbor structural lesions. We aim to determine the utility of repeat angiogram in these subsets of patients.

Methods: In this prospective study, patients with SAH with a negative computed tomographic angiogram (CTA) and digital subtraction angiogram (DSA) were included. A repeat angiogram was done after 6 weeks of initial angiogram. Patients were divided into perimesencephalic SAH (PM-SAH) and diffuse classic SAH (Classic-SAH) groups. Outcome was determined by modified Rankin score (mRS).

Results: A total of 22% (39/178) of all SAH were angio-negative. A total of 90% ($n = 35$) of these were in Hunt and Hess grade 1-3. A total of 22 patients had PM-SAH and 17 had a Classic-SAH. Repeat angiogram did not reveal any pathology in the PM-SAH group, whereas two patients with Classic-SAH were found to have aneurysms. At 6 months follow-up, 95% patients of PM-SAH and 83.3% of Classic-SAH had mRS of 0.

Conclusion: Repeat angiogram is probably not necessary in patients of PM-SAH and they tend to have better outcome. Classic-SAH pattern of bleed is associated with fair chances of an underlying pathology and a repeat angiogram is recommended and these cases and they have poorer outcome.

Key Words: Computed tomographic angiography, digital subtraction angiography, perimesencephalic, repeat angiogram, spontaneous subarachnoid hemorrhage

Access this article online**Website:**

www.surgicalneurologyint.com

DOI:

10.4103/2152-7806.138367

Quick Response Code:

INTRODUCTION

Spontaneous subarachnoid hemorrhage (SAH) is an acute and potentially fatal neurosurgical emergency. The incidence of SAH is variable and ranges from

6.5 to 23.9 per 100,000 populations (including all age groups).^[14,22] As far as the etiology of spontaneous SAH is concerned, around 75% of them are due to ruptured intracranial aneurysms, 5% are caused by arteriovenous malformations (AVMs), and, in remaining cases,

no vascular abnormality is evident on angiographic studies.^[22] One of the first and most important step in the management of spontaneous SAH is determining the cause of bleed. Initial angio negative spontaneous SAH group of patients thus pose a difficult management proposition. This is so because these patients run the risk of re-bleed and its consequences if a structural lesion had been missed on the initial angiogram. That is why many authors have advocated a repeat angiogram after a defined time period to detect these missed cases.^[6,11,24] However, the repeat angiogram (digital subtraction angiogram [DSA]) has got its own set of complications (SAH-specific mortality in 0.17% of patients, focal neurological deficit in 3.2% of patients, with permanent disability in 0.04%)^[12] and one needs to balance the risks of a repeat angiogram against the possible benefits. Our centre is a tertiary care teaching hospital and sizeable populations of spontaneous SAH patients are treated at this centre. This study aimed to prospectively analyze the utility of repeat angiographic study in initial angio negative spontaneous SAH patients.

MATERIALS AND METHODS

This prospective study was conducted between December 2011 and June 2013. We analyzed 40 consecutive cases of clinico-radiologically proven cases of spontaneous SAH who had a negative initial angiogram (both computed tomographic angiogram [CTA] and DSA). Out of these 40 patients, 1 patient was excluded as the patient died before the repeat angiogram. These patients were admitted in intensive care unit or wards depending on their clinical status and the patients were thoroughly evaluated. We graded their clinical status as per the modified Hunt and Hess score.^[8]

We have a departmental protocol for management of SAH patients. Every noncontrast computed tomography (CT)-proven SAH patient undergoes an initial CTA to find out cause of SAH. If CTA demonstrates a structural lesion (e.g. aneurysm or AVM), then patient undergoes definitive management of the same. In case CTA does not reveal any structural cause of the bleed, the patient undergoes four vessel intraarterial DSA. If DSA also fails to depict any pathological substrate, we label these cases as angio negative SAH. In such cases, a repeat DSA is performed after 6 weeks. In radiological evaluation, we specifically looked for location/distribution of bleed, Fisher grade, any evidence of infarction secondary to vasospasm, hydrocephalus, cerebral edema, etc., On the basis of pattern of bleed on CT scan, we divided the patients into two groups, one group with perimesencephalic SAH (PM-SAH) and another having with Classic-SAH. We followed the criteria given by Van Gijn^[23] in this

regard, PM-SAH comprises (i) a central hemorrhage located immediately in front of the midbrain or within perimesencephalic, prepontine, or medullary cisterns; (ii) absence of intraparenchymal bleeding; (iii) extension of blood into the proximal sylvian fissure with no more than a minute amount of blood in the lateral sylvian fissure; (iv) extension of blood without complete filling of the anterior interhemispheric fissure; (v) absence of a frank intraventricular hemorrhage (sedimentation of a small amount of intraventricular blood is allowed). The pattern of hemorrhages that did not meet all of these criteria was classified as Classic-SAH. Classic-SAH bleed was diffuse pattern of subarachnoid blood and there were no patients with either sulcal bleed only or purely intraventricular bleed. As angiograms were negative, these patients were managed conservatively according to the standard SAH management protocols, which included adequate hydration, calcium channel blockers (Nimodipine), stool softeners, steroids, and anticonvulsants during the acute stage till resolution of their symptoms (mainly headache) and are discharged with a advise of a follow up angiogram after 6 weeks. Repeat DSA was performed in all the patients of angio negative SAH. Complications arising out of angiogram were recorded and managed accordingly. The outcome of these patients were evaluated in terms of mRS score^[2,17] and a score of 1-2 was considered favorable and 3 or more as unfavorable. The SPSS statistical package version 17.0 (Chicago, IL, USA) was used for data management and analysis.

RESULTS

A total of 178 spontaneous SAH patients were treated at our centre during the period of the present study. A total of 39 patients were having negative CTA and DSA and were included in the study. Hence, incidence of angio negative SAH was 22% ($n = 39$) in our series. Table 1 summarizes the demographic profile and SAH grades (Hunt and Hess) of the patients. All patients presented with headache of sudden onset with or without

Table 1: Demographic summary and patient characteristics by hemorrhagic pattern

Demographics	PM-SAH (n=22)	Classic-SAH (n=17)	Total (%)
Age (range) in years	52.45 (32-72)	48.56 (25-51)	
Sex (M: F)	15:7	12:5	
H and H grade			
1	11	05	16 (41)
2	08	06	14 (36)
3	01	04	05 (13)
4	02	02	04 (10)
5	0	0	0

PM-SAH: Perimesencephalic subarachnoid hemorrhage, Classic-SAH: Diffuse classic subarachnoid hemorrhage, n: Number, M: Male, F: Female; H and H: Hunt and Hess grade

vomiting and/or nuchal rigidity. Radiologically, the bleed pattern (Fisher grade)^[4] of 39 patients of angio negative SAH is summarized in Table 2.

Twelve (30%) patients had evidence of hydrocephalus, and none of them showed infarction CT scan. Initial CT scans showed PM-SAH patterns in 22 (56.4%) patients and Classic-SAH patterns in 17 (43.6%) patients. All patients underwent a CT head with CT angiogram irrespective of whether an angiogram was done outside (even in those cases in whom angiograms were available, the quality was suboptimal for any inference). As CTA turned out to be negative, all patients underwent four vessels DSA. The complications from these angiographic studies were noted in two (5%) patients. Following repeat DSA, one patient in PM-SAH group developed bilateral posterior cerebral artery territory infarct leading to visual loss and another patient in Classic-SAH group had motor aphasia. Both of them were treated medically and improved. The modified Rankin score (mRS) was used for analysis of clinical outcomes [Table 3]. All patients except for 1 (95%) in the PM-SAH group and 14 (83.33%) patients in the Classic-SAH group showed recovery to mRS score of 0 [Table 4]. Twenty-two (56.4%) PM-SAH patients underwent a repeat DSA; however, no aneurysm was found in any of them. In contrast, 17 (43.6%) Classic-SAH patients underwent repeat DSA and aneurysm was detected in 2 of them, yielding an overall false-negative rate of 5.1% of the initial DSA. These two patient's cases are illustrated.

Illustrative cases

Case 1

A 50-year-old female complaining of headache, vomiting with mild neck pain from 2 days was brought to our emergency. Neurological examination revealed no focal neurological deficits except for neck stiffness. Findings on noncontrast CT head revealed moderate SAH, predominantly in left cerebellopontine angle (CPA) cistern; however, no aneurysm was detected on CTA done at our institute. DSA was also negative [Figure 1a-d]. The patient received conservative treatment and recovered without any complications. Repeat DSA after 6 weeks revealed a small aneurysm measuring 2.0 × 1.5 mm arising from left anterior inferior cerebellar artery (AICA) [Figure 1e]. Surgical clipping of aneurysm was done.

Case 2

A 76-year-old female presented with sudden, severe headache with multiple bouts of vomiting and altered sensorium from 10 days. She was opening eyes on pain and appeared confused though she was responding to simple commands. There were no focal neurological deficits. CT scan head revealed Fisher grade 4 bleed in the anterior interhemispheric fissure, right sylvian fissure, suprasellar, pre-pontine, interpeduncular SAH with

Table 2: Pattern of bleed as per fisher grade

Distribution of bleed (fisher grade)	Number of patients	Percentage
1	0	0
2	15	38
3	17	44
4	7	18

Table 3: Modified rankin scale

Score	Description
0	No symptoms at all
1	No significant disability despite symptoms; able to carry out all usual duties and activities
2	Slight disability; unable to carry out all previous activities, but able to look after own affairs without assistance
3	Moderate disability; requiring some help, but able to walk without assistance
4	Moderately severe disability; unable to walk without assistance and unable to attend to own bodily needs without assistance
5	Severe disability; bedridden, incontinent and requiring constant nursing care and attention
6	Dead

Table 4: Clinical outcomes and false negative rate of baseline DSA

	PM-SAH (%) n=22	Classic-SAH (%) n=17
mRS*		
0	21 (95)	14 (83.3)
1	01 (5)	03 (16.7)
2	0	0
3	0	0
4	0	0
5	0	0
6	0	0
False negative DSA	0	02 (11.7%)

*P = 0.236, mRS: Modified rankin scale, DSA: Digital subtraction angiography

PM-SAH: Perimesencephalic subarachnoid hemorrhage, Classic-SAH: Diffuse classic subarachnoid hemorrhage

intraventricular bleed with moderate hydrocephalus. CTA did not reveal aneurysm or vascular malformation. She was submitted for DSA, which was also negative [Figure 2a-c]. She underwent right sided ventriculo-peritoneal shunt for cerebrospinal fluid (CSF) diversion following which she had improvement in neurological condition. The patient improved and was discharged in stable condition. After 6 weeks she underwent repeat DSA that revealed a small bilobed posterior communicating artery aneurysm on right side [Figure 2d], which was treated with endovascular coiling.

DISCUSSION

The leading cause of SAH is aneurysmal rupture, and misdiagnosis can result in substantial morbidity and

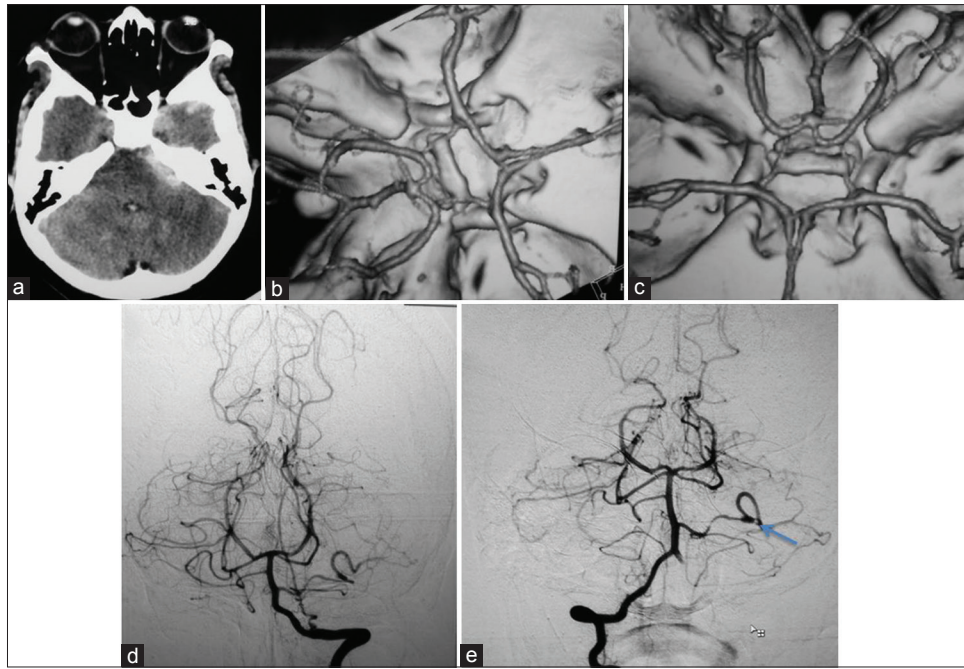


Figure 1: NCCT head showing moderate SAH in left cerebellopontine angle cistern (a), 3D-CTA brain showing no structural abnormality (b,c); Initial DSA Brain showing no aneurysm (d); Repeat DSA brain revealed a small AICA aneurysm (arrow) (e)

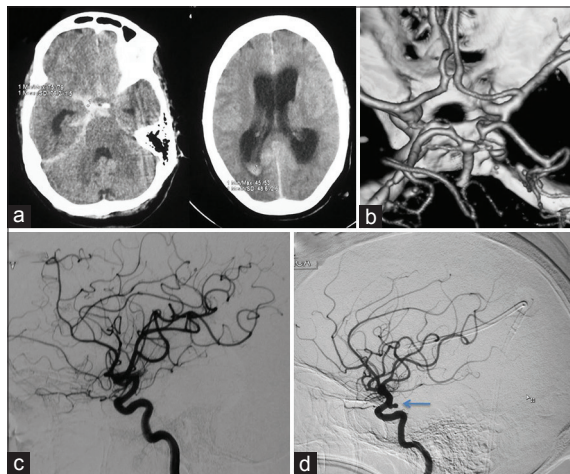


Figure 2: NCCT head showing bleed in anterior interhemispheric fissure, right sylvian fissure, suprasellar, prepontine and intrapeduncular cistern with intraventricular extension with moderate hydrocephalus (a); 3D-CTA brain appeared normal (b); Initial DSA brain failed to reveal any structural abnormality (c); Repeat DSA brain revealed a small bilobed posterior communicating artery aneurysm on right side (arrow) (d)

mortality primarily from a re-bleed. The incidence of angiogram negative SAH has been reported to be variable ranging from 2% to 24% in various studies. Gintautas *et al.*^[21] reported 15-20% cases, Fontanella *et al.*^[5] reported 2-24% and Jung *et al.*^[10] reported 8-23% cases of total spontaneous SAH. Our study indicates that the incidence of angio negative SAH probably lies at the higher end of the range mentioned in the literature.

Although DSA is still considered the gold standard, technical advances have made CTA a very useful

imaging modality in elucidating the cause of SAH. Even then, false negativity remains a significant limitation.^[9] A number of possible factors leading to nonvisualization of a structural lesion, when it is actually present, have been mentioned in the literature. These include blood in cistern obscuring the aneurysm, vasospasm proximal and distal to aneurysm leading to nonfilling of aneurysm, vascular thrombosis, thrombus inside the aneurysmal sac, small micro aneurysm, very close proximity to skull bone and hemorrhage from a venous system or simply a technically inadequate examination.^[3,15] The risks of undetected aneurysm are re-bleeding and vasospasm, which can lead to severe morbidity, however, there are studies that reported the incidence of re-bleeding, which ranged from 0% to 5%, and in a study by Fontanella *et al.*,^[5] it is reported that the incidence of re-bleed was 5.1% and all the episodes occurred within 17 days after the initial ictus. Gintautas *et al.*^[21] reported that the chance of re-bleeding is 4-5% in the first 24 h, 20% in 2 weeks, and even 50% in 6 months. To detect these undetected structural pathologies, a repeat angiogram has been advocated by many authors. Repeat angiogram can be in the form of either 3D-CTA, DSA, or magnetic resonance angiogram (MRA). CTA has many advantages as the initial investigation in emergency setting of SAH such as high speed, noninvasive nature, and less risk of complication. It gives accurate measurement of aneurysm and is able to show the aneurysm in multiple projections. It also shows the mural calcification and thrombus. It also gives bony landmark for the surgery. CTA is also helpful in triaging patients with ruptured aneurysms to either endovascular coiling or surgical

clipping.^[1] CTA is less costly for the patient and involves less radiation dose. In CTA, complications like extravasation of contrast and allergic reaction and repeat CTA due to extravasation of contrast can occur. However, in our study, none of the patients had allergic reaction or contrast extravasation.

Magnetic resonance angiography is another modality to see the intracranial vessels and the peculiarity of this is that it does not require contrast agent to visualize the vessels. Also it has no risk of radiation, so the risks related to artery cannulation and contrast has been eliminated. But, the role of MRI or MRA is very limited in the cases of SAH as these techniques provided little diagnostic yield and did not give additional information particularly if performed in addition to DSA. In the study by Fontanella *et al.*,^[5] they also reported that MRA is not necessary in these cases.

DSA remains the gold standard investigation for SAH. The advantages with DSA are (i) it provides the ability to intervene, (ii) Time-resolved blood flow dynamics (arterial, capillary, venous phases), (iii) High spatial and temporal resolution, and (iv) it provides a subtracted digital image, which can be intensified to see the vessels properly. With technical advancements, such as three dimensional rotational DSA (3-D rDSA), the recent incidence of DSA-negative SAH has shown a significant reduction. This technique is better than conventional two dimensional (2D) angiogram in detecting aneurysm. Ishihara *et al.*^[9] reported that the incidence of DSA-negative SAH was 8.6% in the DSA group and 4.2% in the 3-D rDSA group. Although DSA is the gold standard for detection of aneurysms, it is invasive and may be associated with neurological complications.^[13] The overall incidence of neurological deficits due to procedural complications during DSA has been reported to be around 1-2.6%, with an incidence of persistent deficits following cerebral angiography of about 0.1-0.5%.^[3,7,12] The nonneurologic complications include renal failure (0-0.15%), arterial occlusion requiring surgical thrombectomy or thrombolysis (0-0.4%), pseudo aneurysm formation (0.01-0.22%) and hematoma formation requiring transfusion or surgical evacuation (0.26-1.5%).^[16] The complications were noted in two patients in our study. One patient in PM-SAH group had developed bilateral PCA territory infarct leading to visual loss and another patient in Classic-SAH group had developed motor aphasia following repeat DSA. Both of them were treated medically and improved subsequently.

Different authors have described various patterns of bleed in SAH. Agid *et al.*^[1] divided these patients into four groups as per the distribution of subarachnoid blood on plain CT of head at the presentation: (i) Perimesencephalic hemorrhage (PMH), (ii) Diffuse

aneurysmal pattern, (iii) Xanthochromic CSF on lumbar puncture with no blood demonstrated on CT, and (iv) Peripheral sulcal pattern (with absence of basal cisternal blood). They concluded that those patients who had evidence of perimesencephalic hemorrhage presented in good clinical grade (Hunt and Hess scale 1) with headaches, no neurological deficits, no loss of consciousness, and have a good prognosis. Agid *et al.*^[1] suggested that these patients do not need any investigations except an initial CTA. The second group of patients were those with diffuse aneurysmal pattern of blood on CT. These patients have a potential risk for re-bleeding and have more significant symptoms at onset, and relatively poor prognosis and the possible causes include an extremely small aneurysm, dissection of arterial wall not detected on DSA, or rupture of an atherosclerotic wall. The third group with no evidence of SAH on plain CT but diagnosed on lumbar puncture were negative for both CTA and/or DSA, which were clinically similar to first group with a low re-bleed risk. The fourth group with peripheral sulcal blood were suggestive of vasculitis. Rinkel *et al.*^[18,19] mentioned in their report that the cause of perimesencephalic hemorrhage is likely to be venous in origin and unlikely to be due to aneurysm and these patients have no risk of re-bleed; that is why, they stated that these patients do not need a repeat DSA in further course. In another study by Sung-yong *et al.*,^[20] the pattern of bleed was described according to Fisher grade and the location of blood was classified into (i) Diffuse, with or without local dominance, (ii) Perimesencephalic cistern, (iii) Sylvian fissure, (iv) Interhemispheric fissure, and (v) Ventricle or other locations. They concluded that thick or diffuse SAH on initial CT scan was suggestive of an aneurysmal bleed and a repeat angiogram is mandatory if initial angio was negative. They also found CTA useful in the detection of occult aneurysm early in the course of SAH. Other authors like Jung *et al.*^[10] divided these patients into three groups: Group 1, with no SAH on CT scan, but confirmed by CSF analysis, group 2, with a perimesencephalic pattern of SAH, and group 3, with a nonperimesencephalic pattern of bleed. Overall false negative rate of first angiography was 17.5% (0% in group 1, 1.5% in group 2, and 45.9% in group 3). So the authors strongly recommended repeat angiography in patients with nonperimesencephalic pattern of bleed. Other authors have also advocated repeat angiogram in nonperimesencephalic pattern of SAH and advised against the same in perimesencephalic bleeds. The nonperimesencephalic pattern of blood in our study was exclusively diffuse subarachnoid bleed and no patients with pure intraventricular bleed or pure sulcal bleed was seen in our study. Moreover, similar to these studies, we also found that yield of a repeat angiogram in PM-SAH was 0% while 2 out of 17 (11.76%) patients

with Classic-SAH were found to be positive for aneurysm on repeat DSA. The overall false negative rate in our series was 5.1%.

The timing of repeat angiogram is somewhat controversial. In the current study, at the time of initial presentation, all patients had both CTA and DSA done; and if the results of both were negative, a repeat DSA was done at 6 weeks after the first angiography. Gintautas *et al.*^[21] advocate that repeat angiogram should be done within 10-14 days of initial angiogram and should be performed while patient remains admitted in the hospital. Early repeat angiogram, if positive, can potentially prevent a rebleed which occurs most frequently within first few days of ictus. Also, as the investigation is done during same hospital admission, the relatives and the patient remain motivated for the same which may be an issue after admission. On the contrary, some authors^[6] advocate that repeat angiogram should be performed after 4-6 weeks of initial ictus. The arguments in favour of delayed repeat angiogram are that by this time radiologic vasospasm recovers, hematoma around the vessel and any thrombus inside proximal vessel or aneurysm sac also resolves, thus making visualization of the aneurysm easier.

Two patients in Classic-SAH group had an aneurysm on repeat DSA. In the first case, there was bleed in left CPA and ambient cistern, which was, possibly, obscuring the aneurysm. The aneurysm was small and arising from left AICA and interestingly, AICA was dominant and also supplying the posterior inferior cerebellar artery (PICA) territory (AICA-PICA variant). Second case had diffuse SAH involving anterior interhemispheric fissure, right sylvian fissure, suprasellar, prepontine, interpeduncular SAH with intraventricular extension with moderate hydrocephalus. On repeat DSA, a small bilobed right posterior communicating aneurysm was detected. The hydrocephalus was addressed with CSF diversion procedure later and aneurysm was coiled. Possible cause of nondetection of this aneurysm on initial angiogram could be proximity to skull base with bony artifact and possibly technically inadequate study wherein proper rotational angiographic views were probably not taken. Based on the results of our study, because structural anomalies, such as aneurysms, can be obscured in the first angiogram, repeat DSA is always indicated in patients with bleed consistent with Classic-SAH patterns upon CT scan and negative initial angiogram (CTA and DSA).

CONCLUSION

Angio negative spontaneous SAH is a very important clinical entity accounting for nearly one-fifth of all cases (22%). The primary aim in management of these patients is to ensure that there is no structural lesion underlying the bleed, primarily aneurysms. Classification

of the bleed on CT scan into perimesencephalic and nonperimesencephalic patterns is very helpful. Patients with PM-SAH usually do not have any underlying aneurysms and tend to have good outcome. As our results suggest, a repeat angiogram in these patients is probably not necessary once an initial angiogram is negative. In contrast, Classic-SAH pattern of SAH is usually associated with fair chances of an underlying missed pathology and also a relatively poorer outcome. We recommend a repeat angiogram in all these patients with rotational angiogram in order to exclude aneurysms, which is important for reducing morbidity and mortality due to misdiagnosis.

REFERENCES

1. Agid R, Andersson T, Almqvist H, Willinsky RA, Lee SK, terBrugge KG, *et al.* Negative CT angiography findings in patients with spontaneous subarachnoid hemorrhage: When is digital subtraction angiography still needed? *AJNR Am J Neuroradiol* 2010;31:696-705.
2. Bonita R, Beaglehole R. Recovery of motor function after stroke. *Stroke* 1998;19:1497-500.
3. Broderick JP, Brott TG, Duldner JE, Tomsick T, Leach A. Initial and recurrent bleeding are the major causes of death following subarachnoid hemorrhage. *Stroke* 1994;25:1342-7.
4. Fisher CM, Kistler JP, Davis JM. Relation of cerebral vasospasm to subarachnoid hemorrhage visualized by computerized tomographic scanning. *Neurosurgery* 1980;6:1-9.
5. Fontanella M, Rainero I, Panciani PP, Schatlo B, Benevello C, Garbossa D, *et al.* Subarachnoid hemorrhage and negative angiography: Clinical course and long-term follow-up. *Neurosurg Rev* 2011;34:477-84.
6. Gupta SK, Gupta R, Khosla VK, Mohindra S, Chhabra R, Khandelwal N, *et al.* Nonaneurysmal nonperimesencephalic subarachnoid hemorrhage: Is it a benign entity? *Surg Neurol* 2009;71:566-71.
7. Heiserman JE, Dean BL, Hodak JA, Flom RA, Bird CR, Drayer BP, *et al.* Neurologic complications of cerebral angiography. *AJNR Am J Neuroradiol* 1994;15:1401-17.
8. Hunt WE, Hess RM. Surgical risk as related to time of intervention in the repair of intracranial aneurysms. *J Neurosurg* 1968;28:14-20.
9. Ishihara H, Kato S, Akimura T, Suehiro E, Oku T, Suzuki M. Angiogram-negative subarachnoid hemorrhage in the era of three dimensional rotational angiography. *J Clin Neurosci* 2007;14:252-5.
10. Jung JY, Kim YB, Lee JW, Huh SK, Lee KC. Spontaneous subarachnoid haemorrhage with negative initial angiography: A review of 143 cases. *J Clin Neurosci* 2006;13:1011-7.
11. Kaim A, Proske M, Kirsch E, von Weyarn A, Radü EW, Steinbrich W. Value of repeat-angiography in cases of unexplained subarachnoid hemorrhage (SAH). *Acta Neurol Scand* 1996;93:366-73.
12. Kaufmann TJ, Huston J 3rd, Mandrekar JN, Schleck CD, Thielen KR, Kallmes DF. Complications of diagnostic cerebral angiography: Evaluation of 19,826 consecutive patients. *Radiology* 2007;243:812-9.
13. Leffers AM, Wagner A. Neurologic complications of cerebral angiography. A retrospective study of complication rate and patient risk factors. *Acta Radiol* 2000;41:204-10.
14. Linn FH, Rinkel GJ, Algra A, van Gijn J. Incidence of subarachnoid hemorrhage: Role of region, year, and rate of computed tomography: A meta-analysis. *Stroke* 1996;27:625-9.
15. McMahon J, Dorsch N. Subarachnoid haemorrhage of unknown aetiology: What next? *Crit Rev Neurosurg* 1999;25;9:147-55.
16. Olivecrona H. Complications of cerebral angiography. *Neuroradiology* 1977;14:175-81.
17. Rankin J. Cerebral vascular accidents in patients over the age of 60. II. Prognosis. *Scott Med J* 1957;2:200-15.
18. Rinkel GJ, van Gijn J, Wijdicks EF. Subarachnoid hemorrhage without detectable aneurysm. A review of the causes. *Stroke* 1993;24:1403-9.
19. Rinkel GJ, Wijdicks EF, Vermeulen M, Ramos LM, Tanghe HL, Hasan D, *et al.*

- Nonaneurysmal perimesencephalic subarachnoid hemorrhage: CT and MR patterns that differ from aneurysmal rupture. *AJNR Am J Neuroradiol* 1991;12:829-34.
20. Ahn SY, Lim DJ, Kim SH, Kim SD, Hong KS, Ha SK, Clinical analysis of patients with spontaneous subarachnoid hemorrhage of initial negative angiography. *Korean J Cerebrovasc Surg* 2011;13:230-4.
 21. Vaitkevicius G, Gvzdaitis AR, Lukosevicius S. Spontaneous subarachnoid hemorrhage: Patients' examination after aneurysm-negative initial angiograms. *Medicina (Kaunas)* 2002;38:976-81.
 22. Van Gijn J, Kerr RS, Rinkel GJ. Subarachnoid haemorrhage. *Lancet* 2007;369:306-18.
 23. Van Gijn J, Van Dongen KJ, Vermeulen M, Hijdra A. Perimesencephalic hemorrhage: A nonaneurysmal and benign form of subarachnoid hemorrhage. *Neurology* 1985;35:493-7.
 24. Yu DW, Jung YJ, Choi BY, Chang CH. Subarachnoid hemorrhage with negative baseline digital subtraction angiography: Is repeat digital subtraction angiography necessary? *J Cerebrovasc Endovasc Neurosurg* 2012;14:210-5.