J Rural Med 2010; **5**(2): 194–197

Case report

Treatment for Lateral Flexion Fracture Dislocation of the Cervical Spine: Report of Two Cases

Itsuo Shiina[1, 2], Shigeru Hioki[1], Hiroshi Kamada[1, 2], Kuniaki Amano[1, 2] and Hiroshi Noguchi[1]

[1]*Department of Orthopedic Surgery, Ibaraki Seinan Medical Center Hospital, Japan*
[2]*Department of Orthopedic Surgery, Graduate School of Comprehensive Human Sciences, University of Tsukuba, Japan*

Abstract

The injury mechanism of traumatic cervical spine injury varies, and Allen *et al.* divide cervical spine injuries into 6 types based on the direction of external force at the time of injury. In this report, we present 2 cases as Lateral Flexion Stage 2. A 51-year-old male (Case 1) was injured in a traffic accident. His conscious level was JCS III-200, and he was found to have a Frankel Grade of B. X-ray revealed a C5/6 fracture dislocation injury of Lateral Flexion Stage 2. We were unable to obtain good reduction. We planned to perform posterior fusion using a cervical spine pedicle screw but could not perform the procedure due to the patient's poor general condition. A 32-year-old male (Case 2) was injured as a result of being hit by a steel sheet. He had Frankel Grade D paralysis. X-ray revealed a C5/6 fracture dislocation injury of Lateral Flexion Stage 2. We did not perform manual reduction. We performed posterior fixation, anterior decompression and anterior fixation. Bone union was confirmed, and the patient was able to return to work. In cases of this type of fracture dislocation of the cervical spine, the supporting structures of the spinal column circumferentially rupture and induce high instability. Since closed reduction is sometimes difficult and involves risk, strong internal fixation might be recommended.

Key words: fracture dislocation injury, cervical spine, lateral flexion

*(J Rural Med 2010; **5**(2): 194–197)*

Introduction

The injury mechanism of traumatic cervical spine injury varies, and Allen *et al.* divided cervical spine injuries in 165 cases into the following 6 types based on the direction of external force at the time of injury: Compressive Flexion, Distractive Flexion, Compressive Extension, Distractive Extension, Vertical Compression and Lateral Flexion. Furthermore, they subdivided the injuries into stages based on the morphology of the bone symptoms (Figure 1). Among the above types, the frequency of Lateral Flexion (LF) was lowest, and frontal view X-ray revealed only 3 cases of Stage 1 without dislocation and only 2 cases of Stage 2 with dislocation[1)]. In this report, we presented 2 cases of the injury classified as LF Stage 2 according to Allen *et al.*

Case Report

Case 1

The subject was a 51-year-old male. He was the driver of a car involved in a collision in which his car was hit from the left side and overturned. He was not wearing his seatbelt, and his left parietal region was the first area of impact. His car was overturned upside down, and he might receive injury with his own weight being as an external strength. On admission, his conscious level was JCS III-200, and he inflected the right elbow in response to pain stimulation. Since he was in shock and was experiencing respiratory failure, he was intubated and treated with a ventilator. We diagnosed his injury as Grade B according to the Frankel classification. An anteroposterior plain radiograph showed dilation of the left facet joint at the level of C5/6 and dislocation of the C5 vertebral body to the right side. A lateral plain radiograph showed interspinous dilation (Figure 2). We diagnosed a C5/6 fracture dislocation injury of LF Stage 2. Computed tomography (CT) revealed dilation of the C5/6 facet joint and fracture of the right lateral mass of C6 (Figure 3).

We attempted manual reduction but failed. Therefore, while monitoring by X-ray, the loaded weight was gradually

Correspondence to: Itsuo Shiina
Department of Orthopaedic Surgery, Graduate School of Comprehensive Human Sciences, University of Tsukuba, 1-1-1 Tennodai, Tsukuba, Ibaraki 305-8575, Japan
E-mail: c0730179@md.tsukuba.ac.jp

©2010 The Japanese Association of Rural Medicine

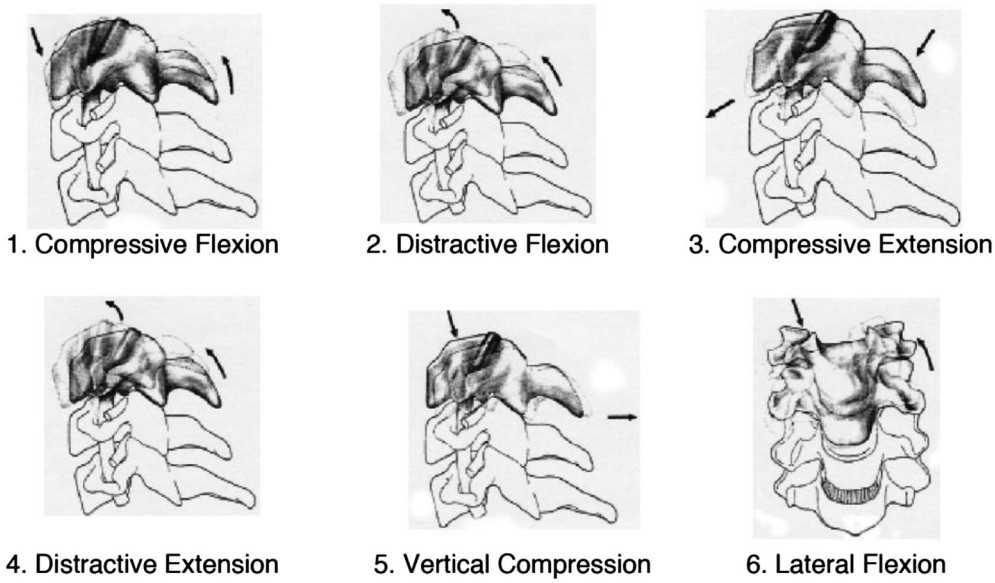

Figure 1. Allen *et al.* divide cervical spine injuries into the following 6 types based on the direction of external force at the time of injury: 1. Compressive Flexion, 2. Distractive Flexion, 3. Compressive Extension, 4. Distractive Extension, 5. Vertical Compression, and 6. Lateral Flexion.

Figure 2. Cervical spine X-ray images of case 1. On the frontal view (left), dilation of the left facet joint at the level of C5/6 and dislocation of the C5 vertebral body to the right side were revealed. From the lateral view (right), interspinous dilation was observed.

Figure 3. Reconstructed computer tomography image of case 1 (coronal view). Dilation of the C5/6 facet joint and fracture of right lateral mass of C6 were clearly revealed.

increased to be 10 kg; however only intervertebral dilation was observed, and reduction was not achieved. Further traction was considered to be dangerous, and immobilization in a halo vest was performed at the position where reduction could be performed. Due to deterioration of respiratory function, tracheotomy was performed approximately 1 month after the injury. We confirmed the patency of the vertebral and posterior communicating arteries by 3D CT angiography, and posterior fusion using a cervical spine pedicle screw was considered. However, we could not perform the procedure due to the patient's poor general condition. Approximately two months after the injury, we observed callus formation on plain radiographs and changed

Figure 4. Cervical spine X-ray images of case 2. On the frontal view (left), dilation of the left facet joint at the level of C5/6 and dislocation of the C5 vertebral body into the right side were revealed.

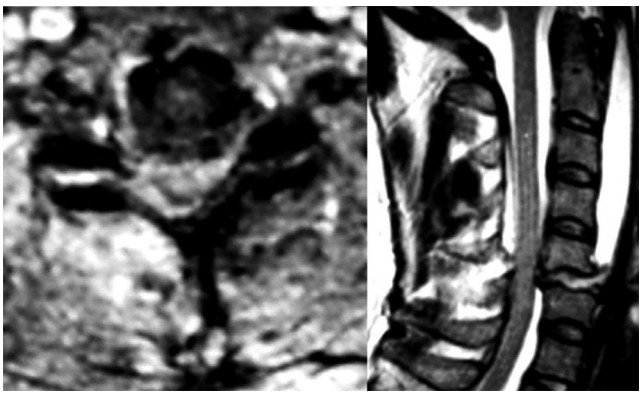

Figure 5. MR images of case 2 (left and right: sagittal view and axial view at the C5/6 level, respectively). Injury of the C5/6 intervertebral disk, tear of the anterior longitudinal ligament, and injury of the posterior supporting structure were revealed.

the halo vest to a Philadelphia collar. During the follow-up period, improvement of paralysis was not observed. He died of pneumonia at another hospital approximately 3 months after injury.

Case 2

A 32-year-old male had his left mandible smashed into a hanging steel sheet while working at a construction site (8 m × 1 m). On admission, he had a clear sensorium and normal vital signs. Muscle weakness at level 4 of Manual Muscle Test (MMT) was observed in the regions below the right and left brachial biceps. He was aware of numbness of both upper limbs. He was diagnosed as Grade D according to the Frankel classification. Contusion, which reached the muscle layer, expanded from the left edge of the mouth to the inframandibular region, but important organs such as the carotid sheath were not injured. A cervical spine X-ray (frontal view) showed dilation of the left facet joint at the level of C5/6 and dislocation of the C5 vertebral body into the right side (Figure 4). CT showed fractures of the C6 vertebral body and lateral mass. We diagnosed a C5/6 fracture dislocation injury of LF Stage 2. MRI revealed injury of the C5/6 intervertebral disk, protrusion into the vertebral canal, tear of the anterior longitudinal ligament and injury of the posterior supporting structure (Figure 5).

Reduction by traction was not performed, and immobilization in a halo vest was applied on the day after injury. The mandible contusion was cured without deep infection, and fusion was performed 2 weeks after the injury. With the patient wearing the halo vest in a prone position, the posterior approach was performed. Among the posterior supporting structures, the supraspinous and interspinal ligaments and left C5/6 facet joint capsule were ruptured and remarkably unstable. After reduction, an autologous bone was grafted between spinous processes and was fastened with polyethylene tape. We performed anterior decompression and fixation with the patient in the supine position (Figure 6). Favorable fixation was obtained, but immobilization in a halo vest was continued postoperatively because the patient was young and active. Gait training was initiated 4 days after the operation, and immobilization with a halo vest was changed to immobilization with a Philadelphia collar 2 weeks after the operation. The patient was able to walk and was discharged from the hospital 4

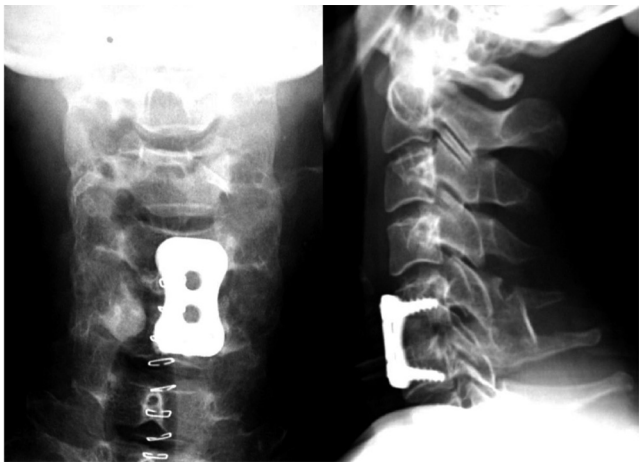

Figure 6. Post-operative cervical spine X-ray images of case 2. Anterior and posterior fixation with autologous bone grafts were performed.

weeks after the operation. Both the degree and range of numbness lessened over time, and muscle strength in both upper limbs gradually increased. Bone union was confirmed 6 months after the operation. Paralysis at the level of MMT4 remained in the fingers of both hands, but he was able to return to work.

Discussion

Only a few investigators have focused on lateral flexion fracture dislocation among fracture dislocation injuries of the cervical spine. Parent *et al.* reported 5 cases and performed autopsies in 2 cases of death. They found tears of the facet joint capsule, posterior longitudinal ligament and interspinal ligament[2]. In our cases, injuries of the anterior longitudinal ligament, intervertebral disk, facet joint capsule and supraspinous and interspinal ligaments were observed, and both the anterior and posterior supporting structures were ruptured. High instability might be induced by circumferential spread of rapture of the supporting structures, including fractures of the lateral mass and coronoid process.

Closed reduction is sometimes difficult and involves risk, since it disrupts the continuity of spinal columns. Although attention should be paid to complicating injuries and general conditions, early and strong internal fixation might be recommended in terms of promoting rehabilitation and preventing complications by shortening the bed rest period and simplifying external fixation. Rechtine II reported that in patients with facet dislocation, up to 40% of patients will remain unstable after reduction even after 3 months of immobilization in a halo, and that surgical stabilization is usually indicated in these cases[3]. Among the techniques of internal fixation, the combined use of anterior and posterior fixation is relatively easy and makes secure decompression from the anterior region possible[4–6]. However, deep infection of the region around the tracheotomy site and injuries of the esophagus and respiratory tract are concerned. On the other hand, fixation using a cervical spine pedicle screw provides good fixation strength and makes it possible to perform both reduction and fixation through a single approach from the posterior region. However, it is difficult to insert a screw since there is a risk of damaging the vertebral artery, spinal cord and nerve root[7, 8]. It might be necessary to carefully choose the fixation method for each patient.

Conclusions

We presented 2 cases of lateral fracture dislocation of the cervical spine. The supporting structures of the spinal column circumferentially ruptured and induced high instability. Since closed reduction is sometimes difficult and involves risk, strong internal fixation might be recommended in lateral fracture dislocation of the cervical spine.

References

1. Allen BL, Ferguson RL, Lehmann TR, *et al.* A mechanistic classification of closed, indirect fractures and dislocations of the lower cervical spine. Spine 1982; 7: 1–27.
2. Parent AD, Harkey HL, Touchstone DA, *et al.* Lateral cervical spine dislocation and vertebral artery injury. Neurosurgery 1992; 31: 501–509.
3. Rechtine II GR. Nonopperative management and treatment of spinal injuries. Spine 2006; 31: S22–S27.
4. Bozkus H, Ames CP, Chamberlain RH, *et al.* Biomechanical analysis of rigid stabilization techniques for three-column injury in the lower cervical spine. Spine 2005; 30: 915–922.
5. Koh YD, Lim TH, You JW, *et al.* A biomechanical comparison of modern anterior and posterior plate fixation of the cervical spine. Spine 2001; 26: 15–21.
6. Jones EL, Heller JG, Silcox DH, *et al.* Cervical pedicle screws versus lateral mass screws: Anatomic feasibility and biomechanical comparison. Spine 1997; 22: 977–982.
7. Abumi K, Kaneda K, Shono Y, *et al.* One-stage posterior decompression and reconstruction of the cervical spine by using pedicle screw fixation system. J Neurosurgery 1999; 90: 19–26.
8. Kotani Y, Cunningham BW, Abumi K, *et al.* Biomechanical analysis of the stabilization systems. An assessment of transpedicular screw fixation in the cervical spine. Spine 1994; 19: 2529–2539.