

Human parietal cortex lesions impact the precision of spatial working memory

Wayne E. Mackey,¹ Orrin Devinsky,² Werner K. Doyle,³ John G. Golfinos,³ and Clayton E. Curtis^{1,4}

¹Department of Psychology, New York University, New York, New York; ²Department of Neurology, New York University School of Medicine, New York, New York; ³Department of Neurosurgery, New York University School of Medicine, New York, New York; and ⁴Center for Neural Science, New York University, New York, New York

Submitted 17 May 2016; accepted in final form 9 June 2016

Mackey WE, Devinsky O, Doyle WK, Golfinos JG, Curtis CE. Human parietal cortex lesions impact the precision of spatial working memory. *J Neurophysiol* 116: 1049–1054, 2016. First published June 15, 2016; doi:10.1152/jn.00380.2016.—The neural mechanisms that support working memory (WM) depend on persistent neural activity. Within topographically organized maps of space in dorsal parietal cortex, spatially selective neural activity persists during WM for location. However, to date, the necessity of these topographic subregions of human parietal cortex for WM remains unknown. To test the causal relationship of these areas to WM, we compared the performance of patients with lesions to topographically organized parietal cortex with those of controls on a memory-guided saccade (MGS) task as well as a visually guided saccade (VGS) task. The MGS task allowed us to measure WM precision continuously with great sensitivity, whereas the VGS task allowed us to control for any deficits in general spatial or visuomotor processing. Compared with controls, patients generated memory-guided saccades that were significantly slower and less accurate, whereas visually guided saccades were unaffected. These results provide key missing evidence for the causal role of topographic areas in human parietal cortex for WM, as well as the neural mechanisms supporting WM.

posterior parietal cortex; intraparietal sulcus; topography; lesion; saccade; working memory

NEW & NOTEWORTHY

Working memory (WM) is a critical building block for nearly all high-level cognitive functions. Although it is widely acknowledged that WM involves distributed processing throughout the brain, precisely which brain areas are critical for supporting WM remains unknown. In this study, we find that lesions to human posterior parietal cortex (PPC) impair the precision of spatial WM, but not visuomotor control. Therefore, human PPC is essential for spatial WM.

WORKING MEMORY (WM) is the system that integrates perception and action over brief periods of time. It is strongly related to general intelligence (Engle et al. 1999) and is critical for nearly all high-level cognitive functions (Daneman and Carpenter 1980; Süss et al. 2002). Despite its importance, we still have a poor understanding of how the brain supports WM, or even which brain areas critically support WM.

Address for reprint requests and other correspondence: C. E. Curtis, New York Univ., 6 Washington Pl., New York, NY 10003 (e-mail: clayton.curtis@nyu.edu).

For over 40 years, researchers have posited that persistent neural activity is the mechanism by which primates maintain information in WM (Fuster and Alexander 1971; Goldman-Rakic 1995). In the monkey, neuronal populations in lateral prefrontal cortex and lateral intraparietal area (LIP) sustain their firing rates after a relevant external cue has vanished until the animal makes a behavioral response (Funahashi et al. 1989; Fuster and Alexander 1971; Gnadt and Andersen 1988; Kubota and Niki 1971). Lesions to these areas in the monkey impair spatial WM (Funahashi et al. 1993; Li et al. 1999).

In humans, neuroimaging studies routinely find persistent neural activity in the precentral sulcus (PCS) in frontal cortex and the intraparietal sulcus (IPS) in parietal cortex (Courtney et al. 1998; Schluppeck et al. 2006; Srimal and Curtis 2008). These regions are also organized into topographic maps of gaze-centered contralateral space (Jerde et al. 2012; Schluppeck et al. 2006; Sheremata et al. 2010; Silver and Kastner 2009). Although we recently demonstrated spatial WM impairments in humans after PCS lesions (Mackey et al. 2016), no study to date has investigated the necessity of topographically organized IPS subregions in spatial WM. This missing data are critical for understanding the role of these topographic areas of parietal cortex in cognition, as well as the neural mechanisms supporting WM.

To test the necessity of topographic areas of IPS in spatial WM, we recruited patients with parietal lesions that overlapped topographically organized IPS and had them perform both memory-guided (MGS) and visually guided saccade (VGS) tasks. Using an atlas to topographic visual areas (Wang et al. 2015), we compared the extent of parietal damage with the probabilistic locations of topographic IPS maps. Whereas the MGS task assessed spatial WM with great precision, the VGS task served as a control to eliminate confounds of visual acuity and general spatial or oculomotor deficits. We measured both accuracy and response time for each task and compared patient performance with that of healthy controls.

Patients were significantly less accurate and slower to respond during the MGS task compared with controls. However, patient performance on the VGS task was identical to that of controls. Therefore, our results demonstrate for the first time that lesions to topographic subregions of parietal cortex impair spatial WM, rather than general visuomotor processing.

MATERIALS AND METHODS

Subjects. We recruited three patients (mean age 46.7 yr, age range 26–61 yr; all female) with surgical resections of cortical tissue from

posterior parietal cortex (PPC) from New York University's Patient Registry for the Study of Perception, Emotion & Cognition (PROSPEC). One patient had a lesion of the left PPC, whereas the others had lesions of the right PPC (see Fig. 1C). All resections were treatments for cortical tumors or focal epilepsy (Table 1). Because a significant amount of time had passed since their surgery (mean 6.53 yr, range 1.5–12 yr), any potentially acute oculomotor deficits would have been resolved. Twelve neurologically healthy individuals (mean age 31.1 yr, age range 20–45 yr; 5 female) served as age-matched experimental controls. All subjects gave informed written consent before participating and were compensated monetarily. All procedures were approved by the human subjects Institutional Review Board at New York University.

Lesion localization. By the nature of patients having lesions to topographic areas in parietal cortex, we were unable to use typical topographic mapping methods to identify these regions in individual subjects. Instead, to identify which subregions of the IPS were damaged in each patient, we transformed all lesion masks to MNI space and compared each patient's lesion to a probabilistic atlas used to identify topographic areas (Wang et al. 2014). All three patients had lesions that overlapped probabilistically with IPS1 through IPS5, with one patient's lesion also overlapping IPS0 and the remaining two patients having lesions that also encroached on the superior parietal lobule (Table 1).

Oculomotor procedures. We collected monocular eye movement data at 1,000 Hz using an SR Research EyeLink 1000+ eye tracker. Subjects sat in a darkened room with their head stabilized using a chin rest to eliminate head movement and help them remain comfortable throughout the task. We performed nine-point calibrations at the beginning of each session and between runs whenever necessary. Experimental stimuli were displayed against a gray background (CIE $xyz = 0.031920, 0.033105, 0.027318$), and experimental tasks were programmed in MATLAB (The Math Works, Natick, MA) using the MGL toolbox.

Experimental procedures. Subjects performed blocks of two different saccade tasks. Each block consisted of a visually guided saccade (VGS) task followed by a memory-guided saccade (MGS) task. Subjects took breaks as necessary to remain comfortable and alert throughout the duration of the experiment. We instructed subjects to complete as many blocks as possible up to a limit of 10 total blocks (mean blocks completed = 9.1, range = 4–10).

Memory-guided saccade task. At the beginning of each trial, subjects fixated their gaze on a preparation cue (black cross over white dot, size = 1°) at the center of the screen (Fig. 1A). A random target location (yellow dot, size = 1°) was then briefly flashed (200 ms) at a random location of 10° of eccentricity from the central fixation point. No target locations were presented within 15° of the cardinal axes to prevent verbalization of locations (e.g., up, down). We instructed subjects to remember the location of the target throughout a variable delay period (3, 3.5, 4, 4.5, or 5 s). At the end of the delay period, the preparation cue disappeared coupled with a sound, signaling the subject to respond by making an eye movement to the target location they were holding in memory. After 800 ms, the target location reappeared as feedback (green dot, size = 1°) to which the subjects were instructed to make a corrective saccade (700 ms). Afterward, an intertrial interval cue (blue square, size = 1°, 1,500 ms) appeared at the center of the screen to notify subjects that the current

trial was over and a new one would begin. Subjects completed 30 trials per run.

Visually guided saccade task. To control for confounds of visual acuity and saccade preparation, subjects also performed a VGS task (Fig. 1B). This task was identical to the MGS task, except that it did not include a memory component. Instead of the target location disappearing after 200 ms, it remained on the screen throughout the variable delay period until the intertrial interval.

Analysis. We transformed eye movement data into degrees of visual angle using a third-order polynomial algorithm that fit eye positions to known spatial locations and then scored data offline with an in-house MATLAB function-graphing toolbox (iEye). Eye movements were defined as saccades when velocity exceeded 30°/s or, when velocity failed to reach 30°/s, were confirmed by visual inspection. Error was defined as the Euclidean distance between the saccade endpoint and the target location, expressed in degrees of visual angle. Saccadic gain was defined as the ratio of saccade amplitude to target eccentricity. Saccadic response time (SRT) represents the amount of time (in ms) between the onset of the response cue and when the subject made the saccade. Error and gain were calculated for the initial saccade after central fixation offset (primary saccade) as well as the final corrective saccade before target feedback was presented (final saccade). Trials where SRT exceeded 900 ms or were below 100 ms, or where subjects prematurely broke fixation, were discarded from analysis.

We grouped patient results by the visual field where the target location appeared (contralesional or ipsilesional). Because no significant differences were found in the control group between targets presented in the left or right visual field (Wilcoxon rank-sum test), we averaged the results together as a representation of control group performance. This resulted in a total of three performance groups: control, patient contralesional, and patient ipsilesional. Additionally, we found that performance did not differ between the narrow range of delays used (Wilcoxon rank-sum test) and therefore collapsed our analyses across delays. We performed statistical analysis of performance results across groups (Kruskal-Wallis ANOVA) for all metrics. When results were statistically significant, we compared ipsilesional and contralesional patient performance with controls (Wilcoxon rank-sum test).

Neuropsychological exam. Patients completed a battery of neuropsychological tests with a licensed neuropsychologist. The Wechsler Adult Intelligence Scales, 4th edition (WAIS-IV; Wechsler 2008) were used to measure general intellectual functions, yielding four primary indexes: verbal comprehension, perceptual reasoning, working memory, and processing speed, as well as a full-scale intelligence quotient, a composite of the four indexes. We report the scores (standard scores) relative to the age-matched normative sample of the WAIS-IV, with a mean of 100 (SD 15).

RESULTS

Task performance across groups is shown in Fig. 2. Compared with controls, patients performed significantly worse on the MGS task. With regard to the primary saccades, patients had longer SRT (control mean 269.91 ms, SE 7.89 ms, Wilcoxon rank-sum test; contralesional mean 348 ms, SE 31.21 ms, $P = 0.017$; ipsilesional mean 332 ms, SE 14.57, $P =$

Table 1. Demographic data and lesion information for patients with parietal lesions

	Age, yr	Sex	Handedness	Lesion Size, ml	Chronicity	Hemisphere	Etiology	Regions
PPC1	61	Female	Right	8.48	12	Left	Glioma (low grade)	IPS0-IPS5
PPC2	26	Female	Right	22.36	6	Right	Focal cortical dysplasia	IPS0-SPL1
PPC3	53	Female	Right	45.18	1.5	Right	Glioma (low grade)	IPS1-SPL1

PPC1–PPC3, patients with PPC lesions. IPS, intraparietal sulcus; SPL, superior parietal lobule.

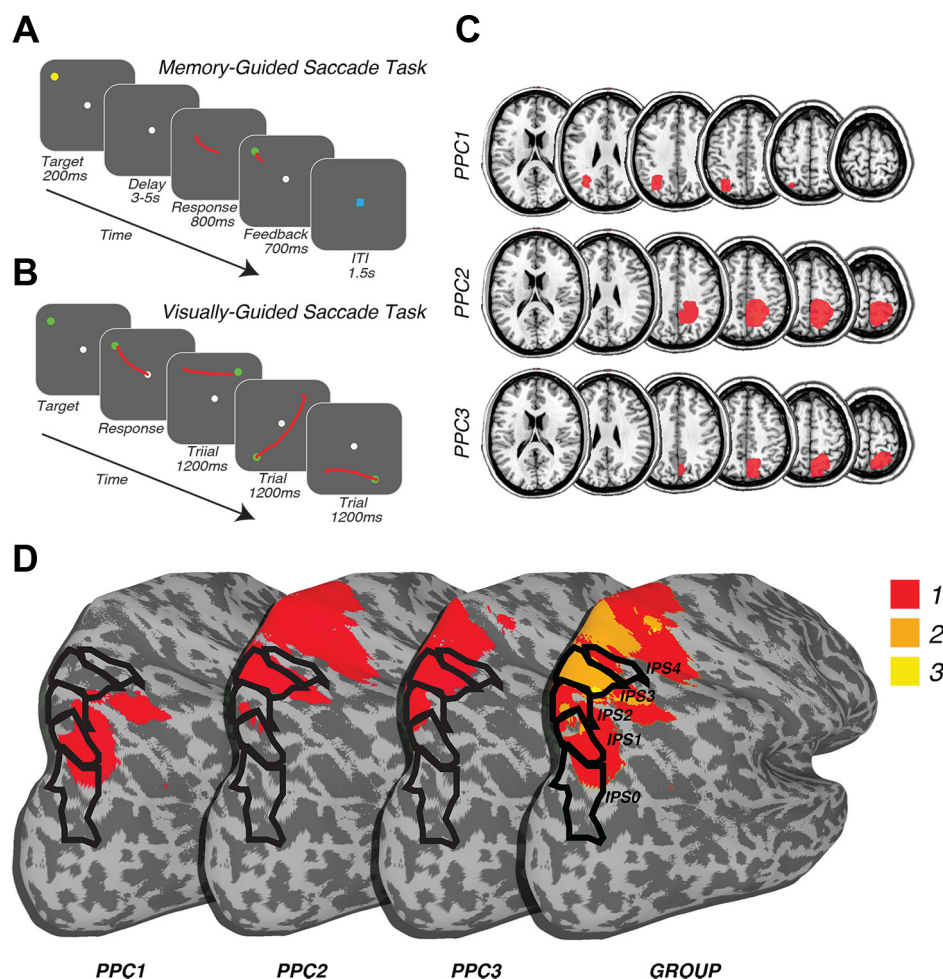


Fig. 1. Experimental tasks and patient lesion masks. *A*: memory-guided saccade (MGS) task used to measure spatial WM ability. ITI, inter-trial interval. *B*: visually guided saccade (VGS) task used to control for general visual, spatial, or oculomotor deficits caused by PPC lesions. *C*: individual lesion reconstructions for each patient with PPC lesions (PPC1–PPC3). Red areas indicate lesion locations. *D*: surface reconstructions of lesions and probabilistic IPS areas. Individual patient lesions are at left, where the surface at far right represents the sum of lesion overlap.

0.008) and were less accurate (control mean 1.29, SE 0.06, Wilcoxon rank-sum test; contralesional mean 2.21, SE 0.23, $P = 0.004$; ipsilesional mean 1.96, SE 0.29, $P = 0.008$) than controls. Although not statistically significant at the group level, these impairments were worse in the contralesional than ipsilesional visual field in all three patients. The final saccades of PPC patients were also significantly impaired compared with controls (mean 1.02, SE 0.06), but only in the contralesional visual field (Wilcoxon rank-sum test; contralesional mean 1.4, SE 0.16, $P = 0.030$; ipsilesional mean 1.21, SE 0.08, $P = 0.136$). Additionally, IPS lesions did not cause significant impairments in gain on either the primary (control mean 0.95, SE 0.008, Wilcoxon rank-sum test; contralesional mean 0.88, SE 0.05, $P = 0.10$; ipsilesional mean 0.9, SE 0.05, $P = 0.18$) or final saccade (control mean 0.98, SE 0.005, Wilcoxon rank-sum test; contralesional mean 0.97, SE 0.006, $P = 0.22$; ipsilesional mean 0.96, SE 0.002, $P = 0.24$).

Performance was completely unimpaired in the VGS task (Fig. 2), ruling out a general visual, spatial, or oculomotor deficit (error: control mean 0.46, SE 0.04; contralesional mean 0.62, SE 0.09, $P = 0.13$; ipsilesional mean 0.64, SE 0.11, $P = 0.21$; SRT: control mean 187.8 ms, SE 6.75 ms; contralesional mean 203.6 ms, SE 23.8 ms, $P = 0.6$; ipsilesional mean 195.3 ms, SE 15.7 ms, $P = 0.72$; gain: control mean 0.97, SE 0.009; contralesional mean 0.93, SE 0.03, $P = 0.31$; ipsilesional mean 0.95, SE 0.05, $P = 0.51$). The patients only performed worse (longer SRT and less accuracy) on the MGS task. Their

performance on neuropsychological tests of intelligence and memory were also within the normal range, indicating that the observed impaired MGS performance could not be due to general cognitive dysfunction (Table 2).

DISCUSSION

In the present work, we show for the first time that lesions to topographic areas of parietal cortex, specifically IPS, impair spatial WM and that this impairment cannot be attributed to any general visuomotor deficit. Compared with controls, patients generated memory-guided saccades that were significantly slower and less accurate, whereas visually guided saccades were unaffected. Although our sample size is small, the observed impairments are remarkably consistent. Therefore, we conclude that the topographic areas in parietal cortex are causally involved in the precision of spatial WM. These results are consistent with the effects of reversible lesions to homologous areas of parietal cortex in nonhuman primates, specifically LIP. Li et al. (1999) injected muscimol into LIP, temporally inactivating the region, and subsequently measured monkey WM performance on MGS and VGS tasks nearly identical to the ones used in the current study. Similarly to our patients, monkeys with LIP inactivations responded significantly slower and were less accurate on the MGS task, yet unimpaired during the VGS task. Again paralleling our patient results, these impairments in the monkey were greater in the contralesional visual field.

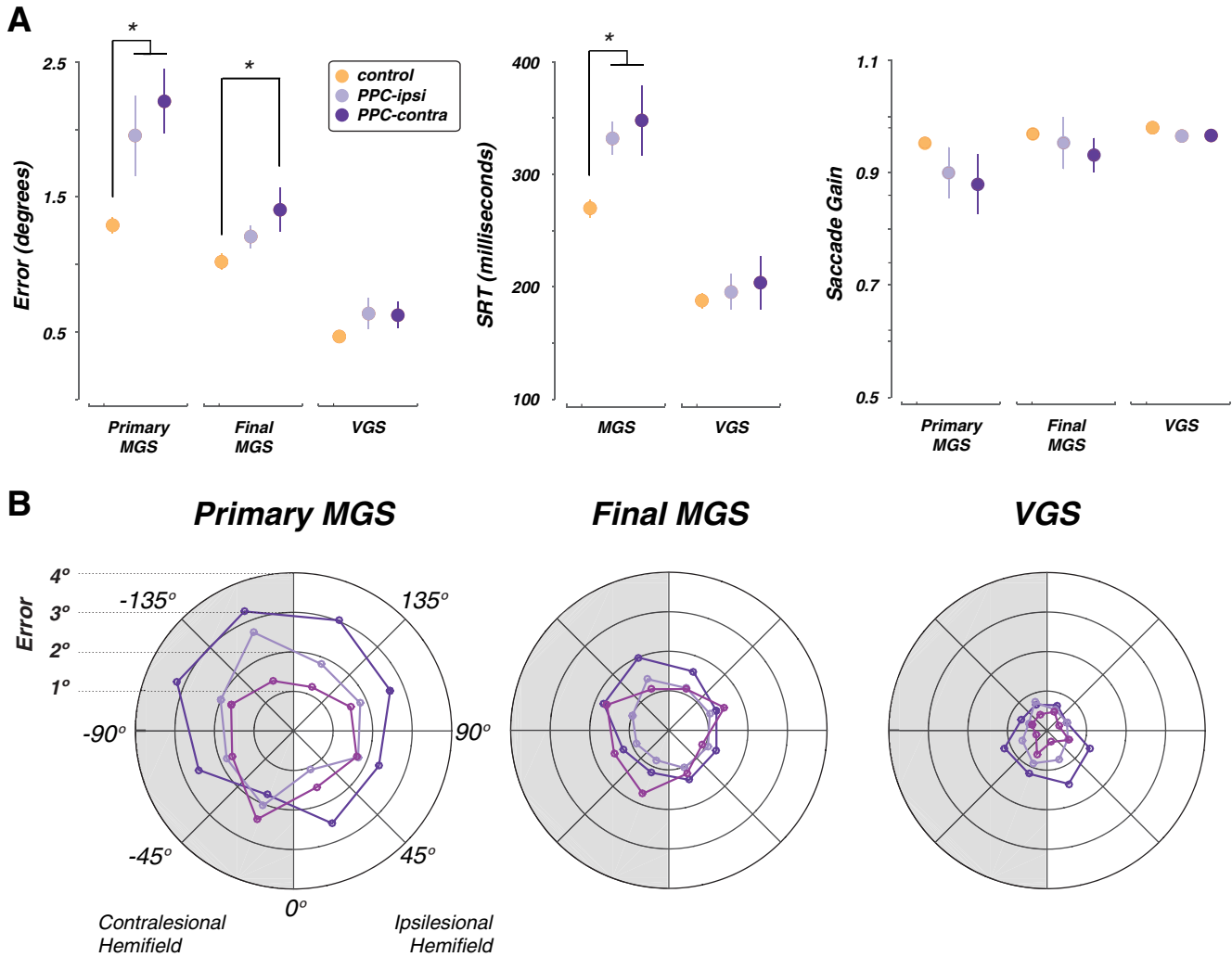


Fig. 2. Performance on working memory (MGS) and control (VGS) tasks. *A*: mean error, response time, and saccadic gain. Error bars represent SE. Patients with PPC lesions were significantly less accurate and slower compared with controls for both primary and final saccades. Additionally, patient performance was worse in the contralesional visual field. *B*: radial histograms of individual patient error. Each colored line represents an individual patient. Data are collapsed into 8 equal bins of spatial position around the visual field.

Although WM recruits a widespread network of cortical regions to facilitate optimal performance (D’Esposito and Postle 2015), the differential contributions from each area remains uncertain. Whereas topographic areas in both frontal and parietal cortices exhibit persistent neural activity during human neuroimaging experiments (Courtney et al. 1998; Schlupeck et al. 2006; Srimal and Curtis 2008), performance of patients with parietal lesions in the current study differs markedly from the performance of patients with frontal lesions on

identical experimental tasks (Mackey et al. 2016). Thus below we contrast the effects of frontal and parietal lesions on memory-guided saccades.

First, whereas the gain of memory-guided saccades in patients with frontal lesions is impaired (Mackey et al. 2016; Ploner et al. 1999), in patients with parietal lesions we found that gain is normal. To reach the desired target location, frontal patients make a series of hypometric saccades to reach the target (Mackey et al. 2016). We found no such behavior in patients with parietal lesions. This suggests that whereas frontal lesions cause systematic biases and hypometric saccades, parietal lesions cause an increase in variance. Such differences give us clues to the different contributions of the frontal and parietal cortex to WM. Hopefully, theoretical work may leverage these differences to help us constrain our models of the role of frontal and parietal cortices in spatial WM.

Second, although primary saccades made by patients with both frontal and parietal lesions were less accurate, only patients with parietal lesions made significantly less accurate final saccades. Only saccades to the contralesional visual field were impaired by parietal damage. Because the topographic

Table 2. Neuropsychological scores of parietal lesion patients after resection

	FSIQ	VCI	PRI	PSI	WMI
PPC1	115	118	102	114	117
PPC2	126	116	123	125	117
PPC3	109	122	100	92	114

WAIS-IV scores given are verbal comprehension index (VCI), perceptual reasoning index (PRI), processing speed index (PSI), and working memory index (WMI), as well as a composite of the 4 indexes, the full-scale intelligence quotient (FSIQ).

areas in IPS contain maps of the contralateral visual field, such a contralesional effect is predicted. Primary and final saccades have different adaptation profiles (Srimal and Curtis 2010), developmental trajectories (Luna et al. 2004), and patterns of dysfunction in schizophrenia (Krappmann and Everling 1998). Therefore, they likely depend on different mechanisms that support WM. For instance, we might speculate that although the primary saccade is a relatively finer measure of prospective action planning, the accuracy of the final gaze position may additionally index a more general sensory memory for the target location. Because patients with both frontal and parietal lesions have impaired primary saccades, but only patients with parietal lesions have impaired final saccades, the frontal cortex may play a greater role in prospective planning, whereas parietal cortex may play a greater role in maintaining retrospective sensory information. Neuroimaging studies also provide compelling evidence for this dissociation of frontal and parietal cortex in WM (Curtis 2006; Curtis and D'Esposito 2006; Curtis et al. 2004). Our current results, combined with those of Mackey et al. (2016), offer the first causal evidence in support of this dissociation. The current study was not designed to specifically test differences between patients with frontal and parietal lesions, and therefore future studies utilizing patient populations or transcranial magnetic stimulation could formally test these predictions.

Our results appear to contradict a previous lesion study that purportedly demonstrated that PPC was necessary for manipulation, but not storage, of information in WM (Koenigs et al. 2009). These researchers used a battery of neuropsychological tests that measured WM, language production, long-term memory, and visuospatial abilities. They found that although patients were impaired on tests that involved manipulation of information in WM or of a higher difficulty, they performed within the normal range on simple WM tasks that only required maintenance of information. In our current study, patients also completed a battery of neuropsychological tests that included some of the same tests performed by Koenigs et al. In fact, although we found patient performance to be impaired on our MGS task, just like Koenigs et al., we found no impairments on neuropsychological tests of WM. Our simple task requires subjects to remember only a single item over a short delay, making it unlikely that it is more difficult than the tests of WM in the clinical battery. Instead, we suggest that the MGS task is a more sensitive and continuous measure of spatial WM performance, which allowed us to detect WM impairments where standardized neuropsychological tests could not. For example, calculation of the working memory index (WMI) is based on two subsets: digit span and arithmetic. Digit span requires the subject to repeat back a string of numbers in either forward or backward order relative to how they were presented. Although this is indeed a reliable measurement of WM ability, the resolution of this measurement is much lower than that of the MGS task. Whereas a subject can recall an item correctly or incorrectly on the digit span task, the MGS task allows us to observe not just if they are correct or incorrect, but to what degree they are correct or incorrect.

The sensitivity of the observed impairment is a key finding. Errors made during the MGS task were small, even in patients with parietal lesions (primary saccade $\sim 2.5^\circ$, final saccade $\sim 1.5^\circ$). Parietal lesions did not completely abolish the memory for the target location in WM, but instead impaired the preci-

sion for which that memory was represented. This is likely because of two important factors. First, all patients had unilateral, not bilateral lesions, meaning that the topographic areas of parietal cortex in the opposite hemisphere were intact and could possibly compensate or have reorganized over time. Second, spatial WM is likely supported by a distributed network of topographically organized brain regions in cortical and subcortical areas (Koepec et al. 2015; Saber et al. 2015; Schluppeck et al. 2006), including the PCS and IPS. We suggest that these areas partially compensate for the impairments caused by damaged topographic areas of parietal cortex in our patients.

The differences in the observed impairments from lesions to the PCS and IPS may also provide insight into the hierarchy of information communication between these regions and why some compensation exists. The PCS and IPS are structurally connected by the superior longitudinal fasciculus (SLF), a key white matter pathway projecting to areas in both frontal and parietal cortices (Thiebaut de Schotten et al. 2011). The remembered location may be maintained in PPC and fed forward to the PCS, where an oculomotor plan is then constructed and maintained until cued to execute. This would explain why patients with lesions of the PCS have systematically hypometric primary saccades but an intact representation of the remembered location, as well as why patients with lesions of the PPC have impairments in both primary and final saccades.

Whereas the frontal cortex has long been the focus of investigations into the neural mechanisms of WM, much less is understood about the role of parietal cortex in WM. The current study fills an important gap in our understanding of the neural mechanisms supporting WM and the role of parietal cortex in the network of brain regions supporting WM.

ACKNOWLEDGMENTS

We thank Drs. Karen Blackmon, Michael Meager, and Elizabeth Phelps for support and management of New York University's Patient Registry for the Study of Perception, Emotion, and Cognition; and Grace Hallenbeck and Lauren Banker for assistance in data collection and analysis.

GRANTS

This work was supported by National Institutes of Health Grant R01EY016407 (to C. E. Curtis) and the National Science Foundation Graduate Research Fellowship Program (to W. E. Mackey).

DISCLOSURES

No conflicts of interest, financial or otherwise, are declared by the authors.

AUTHOR CONTRIBUTIONS

W.E.M. and C.E.C. conception and design of research; W.E.M., O.D., W.K.D., J.G.G., and C.E.C. performed experiments; W.E.M. and C.E.C. analyzed data; W.E.M. and C.E.C. interpreted results of experiments; W.E.M. and C.E.C. prepared figures; W.E.M. and C.E.C. drafted manuscript; W.E.M., O.D., W.K.D., J.G.G., and C.E.C. edited and revised manuscript; W.E.M., O.D., W.K.D., J.G.G., and C.E.C. approved final version of manuscript.

REFERENCES

- Courtney SM, Petit L, Maisog JM, Ungerleider LG, Haxby JV. An area specialized for spatial working memory in human frontal cortex. *Science* 279: 1347–1351, 1998.
- Curtis CE. Prefrontal and parietal contributions to spatial working memory. *Neuroscience* 139: 173–180, 2006.

- Curtis CE, D'Esposito M.** Selection and maintenance of saccade goals in the human frontal eye fields. *J Neurophysiol* 95: 3923–3927, 2006.
- Curtis CE, Rao VY, D'Esposito M.** Maintenance of spatial and motor codes during oculomotor delayed response tasks. *J Neurosci* 24: 3944–3952, 2004.
- Daneman M, Carpenter PA.** Individual differences in working memory and reading. *J Verbal Learn Verbal Behav* 19: 450–466, 1980.
- D'Esposito M, Postle BR.** The cognitive neuroscience of working memory. *Annu Rev Psychol* 66: 115–142, 2015.
- Engle RW, Tuholski SW, Laughlin JE, Conway AR.** Working memory, short-term memory, and general fluid intelligence: a latent-variable approach. *J Exp Psychol Gen* 128: 309–331, 1999.
- Funahashi S, Bruce CJ, Goldman-Rakic PS.** Dorsolateral prefrontal lesions and oculomotor delayed-response performance: evidence for mnemonic “scotomas”. *J Neurosci* 13: 1479–1497, 1993.
- Funahashi S, Bruce CJ, Goldman-Rakic PS.** Mnemonic coding of visual space in the monkey's dorsolateral prefrontal cortex. *J Neurophysiol* 61: 331–349, 1989.
- Fuster JM, Alexander GE.** Neuron activity related to short-term memory. *Science* 173: 652–654, 1971.
- Gnadt JW, Andersen RA.** Memory related motor planning activity in posterior parietal cortex of macaque. *Exp Brain Res* 70: 216–220, 1988.
- Goldman-Rakic PS.** Cellular basis of working memory. *Neuron* 14: 477–485, 1995.
- Jerde TA, Merriam EP, Riggall AC, Hedges JH, Curtis CE.** Prioritized maps of space in human frontoparietal cortex. *J Neurosci* 32: 17382–17390, 2012.
- Koenigs M, Barbey AK, Postle BR, Grafman J.** Superior parietal cortex is critical for the manipulation of information in working memory. *J Neurosci* 29: 14980–14986, 2009.
- Kopec CD, Erlich JC, Brunton BW, Deisseroth K, Brody CD.** Cortical and subcortical contributions to short-term memory for orienting movements. *Neuron* 88: 367–377, 2015.
- Krappmann P, Everling S.** Spatial accuracy of primary and secondary memory-guided saccades in schizophrenic patients. *Schizophr Res* 30: 183–185, 1998.
- Kubota K, Niki H.** Prefrontal cortical unit activity and delayed alternation performance in monkeys. *J Neurophysiol* 34: 337–347, 1971.
- Li CS, Mazzoni P, Andersen RA.** Effect of reversible inactivation of macaque lateral intraparietal area on visual and memory saccades. *J Neurophysiol* 81: 1827–1838, 1999.
- Luna B, Garver KE, Urban TA, Lazar NA, Sweeney JA.** Maturation of cognitive processes from late childhood to adulthood. *Child Dev* 75: 1357–1372, 2004.
- Mackey WE, Devinsky O, Doyle WK, Meager MR, Curtis CE.** Human dorsolateral prefrontal cortex is not necessary for spatial working memory. *J Neurosci* 36: 2847–2856, 2016.
- Ploner CJ, Rivaud-Pechoux S, Gaymard BM, Agid Y, Pierrot-Deseilligny C.** Errors of memory-guided saccades in humans with lesions of the frontal eye field and the dorsolateral prefrontal cortex. *J Neurophysiol* 82: 1086–1090, 1999.
- Saber GT, Pestilli F, Curtis CE.** Saccade planning evokes topographically specific activity in the dorsal and ventral streams. *J Neurosci* 35: 245–252, 2015.
- Schluppeck D, Curtis CE, Glimcher PW, Heeger DJ.** Sustained activity in topographic areas of human posterior parietal cortex during memory-guided saccades. *J Neurosci* 26: 5098–5108, 2006.
- Sheremata SL, Bettencourt KC, Somers DC.** Hemispheric asymmetry in visuotopic posterior parietal cortex emerges with visual short-term memory load. *J Neurosci* 30: 12581–12588, 2010.
- Silver MA, Kastner S.** Topographic maps in human frontal and parietal cortex. *Trends Cogn Sci* 13: 488–495, 2009.
- Srimal R, Curtis CE.** Persistent neural activity during the maintenance of spatial position in working memory. *Neuroimage* 39: 455–468, 2008.
- Srimal R, Curtis CE.** Secondary adaptation of memory-guided saccades. *Exp Brain Res* 206: 35–46, 2010.
- Süss HM, Oberauer K, Wittmann WW, Wilhelm O, Schulze R.** Working-memory capacity explains reasoning ability—and a little bit more. *Intelligence* 30: 261–288, 2002.
- Thiebaut de Schotten M, Dell'Acqua F, Forkel SJ, Simmons A, Vergani F, Murphy DG, Catani M.** A lateralized brain network for visuospatial attention. *Nat Neurosci* 14: 1245–1246, 2011.
- Wang L, Mruzek RE, Arcaro MJ, Kastner S.** Probabilistic maps of visual topography in human cortex. *Cereb Cortex* 25: 3911–3931, 2015.
- Wechsler D.** *Wechsler Adult Intelligence Scale-Fourth Edition (WAIS-IV)*. San Antonio, TX: Pearson, 2008.