

Non-Syndromal, True Congenital Ankylosis of the Temporomandibular Joint A Case Report

SO Ajike¹, ND Chom², UE Amanyeibe¹, ET Adebayo⁴, CN Ononiwu¹, JO Anyiam³, WN Ogala³

ABSTRACT

A case of a six-week old boy with bilateral congenital fibrous intra-articular ankylosis of the temporomandibular joint is presented. The literature is reviewed and limitations to management are highlighted.

Anquilosis no-sindrómica, Verdaderamente Congénita de la Articulación Temporomandibular

Reporte de un caso

SO Ajike¹, ND Chom², UE Amanyeibe¹, ET Adebayo⁴, CN Ononiwu¹, JO Anyiam³, WN Ogala³

RESUMEN

Se presenta el caso de un niño de seis semanas de edad con anquilosis intra-articular fibrosa, congénita y bilateral, de la articulación temporomandibular. Se revisa la literatura y se señalan las limitaciones del tratamiento.

West Indian Med J 2006; 55 (6): 444

INTRODUCTION

Ankylosis of the temporomandibular joint (TMJ) involves fusion of the mandibular condyle to the base of the skull (1). Occurrence in early childhood usually affects growth and the development of the jaws and teeth. Occasionally, it may lead to upper airway obstruction and cor pulmonale (2). The aetiology of TMJ ankylosis includes infection (1), inflammatory disease, trauma, irradiation, neoplasia and rare congenital causes (3–9).

True congenital ankylosis of the TMJs is rare. In a review of 185 cases of ankylosis of the TMJ, Topazian in 1964 documented only five cases. Other reports of congenital ankylosis are only limited to case reports (2, 4, 10–14). The case presented here, therefore, represents an additional case to the scanty literature.

Case Report

Baby M, a six-week old boy was referred from the Emergency Paediatric Unit to the Oral and Maxillofacial Unit

of Ahmadu Bello University Teaching Hospital, Kaduna, Nigeria, with a history of inability to open the mouth since birth. The baby was a spontaneous vaginal delivery at the maternity unit of the hospital complex in Zaria, Nigeria, after an uneventful full term pregnancy. There was no evidence of obstetric trauma. Parents brought the baby to hospital due to the inability to open his mouth 22 hours post delivery. The birthweight at delivery was 3.4 kg.

The patient was the last of three siblings and there was no history of similar problems in the other siblings.

Examination revealed a healthy looking boy with slight mandibular retrognathism (Fig.1) but no other abnormality.

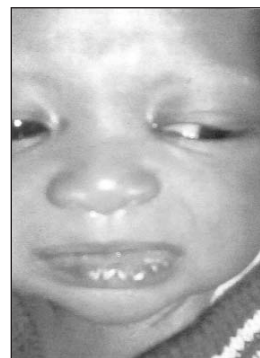

Fig. 1: Full face with slight mandibular retrognathism.

From: Maxillofacial Unit¹, Radiology², and Paediatric³ Departments, Ahmadu Bello University Teaching Hospital and 44 Army Reference Hospital⁴, Kaduna, Nigeria.

Correspondence: Dr SO Ajike, Maxillo-Facial Unit, Ahmadu Bello University Teaching Hospital, Shika-Zaria, Kaduna State, Nigeria. e-mail: mfujiks@yahoo.com.

There were some slight movement at the temporomandibular joints bilaterally when the patient was stimulated to cry. However, inter-alveolar distance was limited to about 2 mm. No other abnormality was detected. Weight at presentation was 3.55 kg.

Laboratory investigations were within normal limits. Full blood count showed packed cell volume was 30%, white blood cell count was 7.4×10^9 per litre, platelets 265×10^9 per litre. The differential white cell count was neutrophils 43% and lymphocytes 57%. The blood picture also showed anisocytosis, poikilocytosis, microcytosis and hypochromia. Electrolyte and urea levels were within normal limits. His genotype was AA.

Plain radiograph of the TMJ was not useful, however CT scan (Fig. 2a and 2b) revealed isodense soft tissue sha-

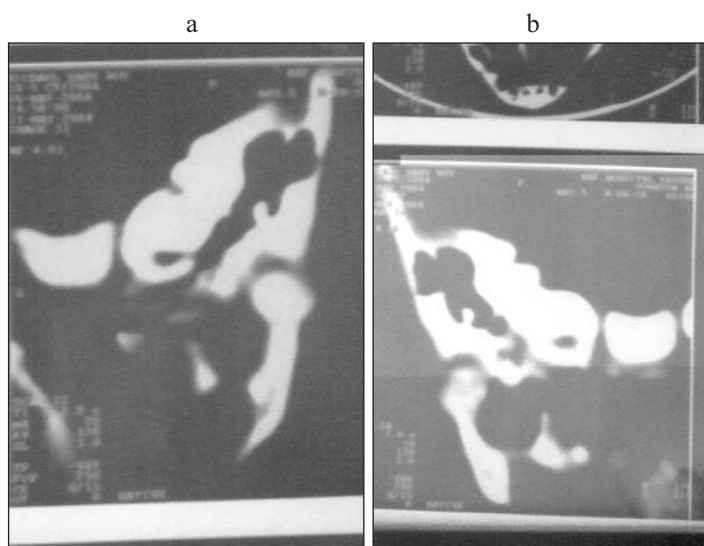


Fig. 2a and 2b: CT scan showing isodense (soft) tissue shadows on both sides of the right joint capsule and on the medial aspect of the left joint capsule with obliteration of the intra-articular cartilage hypodensity.

dows on both sides of the right joint capsule and on the medial aspect of the left joint capsule with obliteration of the intra-articular cartilage hypodensity. Plain radiograph for the chest revealed no abnormality. A clinical and radiographic diagnosis of bilateral congenital fibrous intra-articular ankylosis was made.

Regular follow-up was recommended to the patient's parents pending surgical repair at a later date. However, the patient was subsequently lost to follow-up.

DISCUSSION

True congenital ankylosis of the jaws is shrouded in controversy (15, 16) as some authors have associated it with obstetric trauma (forceps delivery) (14). True congenital ankylosis of the TMJ is immobility of the joint from birth in the absence of other likely causes of ankylosis such as birth trauma (5). There was no history of trauma during obstetrics. Mouth opening (gap between the upper and lower gum pads)

was limited to 2 mm when the patient was stimulated to cry (Fig.1). In cases of post-obstetric trauma ankylosis, mouth opening reduces gradually in the neonatal period due to fibrosis. Such cases on late recognition have been erroneously termed congenital ankylosis.

The exact pathogenesis of congenital ankylosis is unknown. The various proposed hypotheses include anomalous fusion of embryonal mesenchyme in early development during embryogenesis (4), an abnormality of the stapedia artery in the fetus (12), hypervitaminosis A (13) and early loss of neural crest cells (17).

While TMJ ankylosis is noticed with some congenital malformations such as Treacher-Collins syndrome (18) and Pierre Robin's syndrome, this case was asyndromic. Temporomandibular joint ankylosis, especially when it occurs in childhood, causes aesthetic defects in the face, malocclusion, inability to enjoy the culinary acts and malnutrition (19). The index case had nutritional anaemia. Increased upper airway resistance could result in cor pulmonale apart from the risk of asphyxia in transient upper airway obstruction. Hence early recognition and management are necessary.

To the best of the authors' knowledge, this is the second case of true congenital ankylosis of the temporomandibular joint from Nigeria and the first from this centre, which is about 37 years old. Nwoku and Kekere Ekun (4) reported the first case in Nigeria. This was a case of bony fusion between the coronoid process and the maxillary tuberosity in contrast to the case reported here, which is fibrous, bilateral and intra-articular. Hence this could be described as a congenital, bilateral, true, fibrous, intra-articular ankylosis of the temporomandibular joint.

The principal aids to diagnosis of ankylosis are clinical findings and radiology. The case from Lagos, Nigeria (4) had plain radiograph demonstrating the abnormal bony fusion. In the present case, CT scan showed isodense soft tissue shadows on both sides of the right joint capsule and on the medial aspect of the left joint capsule which obliterated the intra-articular cartilage hypodensity (Figs. 2a and 2b). The management of ankylosis has been described but the congenital forms are peculiar in their anaesthetic requirements and possibility of non-compliance to jaw opening exercises. Adekeye *et al* (3) have observed the latter as a major cause of recurrence while the former could be responsible for mortality. The case presented here would have been operated on at the age of six months when anaesthetic difficulties would have been surmounted.

REFERENCES

1. McFadden LR, Rishiraj B. Temporomandibular joint ankylosis: a case report. *J Can Dent Assoc* 2001; **67**: 659-63.
2. Alday LE, Vega PJ, Heller A. Congenital ankylosis of the temporomandibular joint: resultant upper airway obstruction and cor pulmonale. *Chest* 1979; **75**: 384-6.
3. Shamia RI, James JD, Adekeye EO. Ankylosis of the temporomandibular joint. *Nig Med J* 1977; **7**: 305-11.

4. Nwoku AL, Kekere-Ekun TA. Congenital ankylosis of the mandible. Report of a case noted at birth. *J Maxillofac Surg* 1986; **14**: 150–2.
5. El Mofly S. Ankylosis of the temporomandibular joint. *Oral Surg Oral Med Oral Pathol* 1972; **33**: 650–60.
6. Topazian RG. Etiology of ankylosis of temporomandibular joint: analysis of 44 cases. *J Oral Surg Anesth Hosp Dent Serv* 1964; **22**: 227–33.
7. Gridly MS. Abnormal bony connections between the skull and mandibles. *J Oral Surg Oral Med Oral Pathol* 1954; **7**: 954–62.
8. Ugboko VI, Amole AOD, Olasoji HO, Ndukwe KC. Temporomandibular joint ankylosis: a multi-center Nigerian study. *The Online J Dent Oral Med* 2002; **4**: July.
9. Manganello-Souza LC, Mariani PB. Temporomandibular joint ankylosis: report of 14 cases. *Int J Oral Maxillofac Surg* 2003; **32**: 24–9.
10. Komorowska A. Congenital temporomandibular joint ankylosis – a case report. *Eur J Orthod* 1997; **19**: 243–8.
11. Filho MM, Palombo CR, Maccari CIT, D’Oliviano N. Congenital temporomandibular ankylosis – An extreme case. *The Online J Dent Oral Med* 4(2) June, 2004. www.epub.org.br/ojdom/vol.04_no.2/caso24/ancil-e.htm
12. Poswillo D. The pathogenesis of the First and Second branchial arch syndrome. *Oral Surg Oral Med Oral Pathol* 1973; **35**:302–28.
13. Nada R. Maxillomandibular ankylosis and cleft palate in rat embryos. *J Dent Res* 1970; **49**:1086–90.
14. Salleh NBM. Congenital partial fusion of the mandible and maxilla. *Oral Surg* 1965; **20**: 74–6.
15. Burket LW. Congenital bony temporomandibular ankylosis and facial hemiatrophy: review and report of a case. *J Am Med Assoc* 1936; **106**: 1719–22.
16. Beavis JO. Intra-articular bony ankylosis of the TMJ articulation. *J Am Dent Assoc* 1928; **15**: 874.
17. Hegtvedt AK. Diagnosis and management of facial asymmetry. In: Peterson 1st Ed Principles of oral and maxillofacial surgery, Philadelphia:JP Lipincott. 1992; 1400–1.
18. Franceschetti A, Klein D. The mandibulo-facial dysostosis: a new hereditary syndrome. *Acta Ophth* 1949; 27:143. In Nwoku AL, Kekere-Ekun TA. Congenital ankylosis of the mandible. Report of a case at birth. *J Maxillofac Surg* 1986; **14**:150–4.
19. Adekeye EO. Ankylosis of the mandible. analysis of 76 cases. *J Oral Maxillofac Surg* 1983; **41**: 442–9.