

Post Harvest Wound Infection and Patient's Perception: Comparative Study between Radial Artery and Saphenous Vein Harvest Sites

Mitsumasa Hata, MD, Jai Raman, FRACS, George Matalanis, FRACS,
Alexander Rosalion, FRACS, Meg Storer, RN, BN, David Hare, MD,
and Brian F. Buxton, FRACS

Introduction: Despite renewed clinical interest in radial artery grafts (RA) for coronary artery bypass grafting, there is a paucity of controlled prospective data on its efficacy. We report on the rate of harvest related complications from a randomized radial artery study.

Methods: Two hundred eighty nine patients were divided into two groups. Group 1 received RA grafts (n=154 patients) and Group 2 (n=135 patients) received saphenous vein grafts (SVG). Postoperative wound problems were assessed using a questionnaire. Postoperative harvest site infections were also carefully documented.

Results: In group 1, 6 of 154 (3.9%) patients had harvest site wound infections. Five of them improved by antibiotic therapy alone. In group 2, 24 of 135 (17.8%) patients had harvest site wound infections ($p=0.001$ vs. group 1). Fifteen of these patients needed redressing due to discharge from the wound. One hundred forty-nine patients (96.7%) in group 1 answered that their hand function was normal on the questionnaire. Concerns and discomfort about the arm scars in the group 1 were of a similar value of 5.2% (8/154), respectively. In group 2, the incidence of those about the leg were 7.4% (10/135) and 11.9% (16/135), respectively. Although there was no significant difference in concerns about the scar, discomfort was significantly higher in group 2 compared with group 1 ($p=0.0139$).

Conclusions: RA harvest is associated with fewer wound infections and scar discomfort than SVG harvest. Radial artery harvest is almost acceptable in terms of a patient's perception. However, there are still patients who have some symptoms in the forearm after RA harvest. Long-term follow-up is necessary for patient's hand function. (*Ann Thorac Cardiovasc Surg* 2002; 8: 97–101)

Key words: radial artery, harvestsite complication, CABG, hand function

Introduction

Recently, the use of radial arteries (RA) for coronary artery bypass grafting (CABG) has gained renewed clinical interest. The procedure of RA harvesting has been

From the Department of Cardiac Surgery, Austin & Repatriation Medical Centre, University of Melbourne, Melbourne, Australia

Received August 6, 2001; accepted for publication November 16, 2001.

Address reprint requests to Mitsumasa Hata, MD: Second Department of Surgery, Nihon University School of Medicine, 30-1 Ooyaguchi Kamimachi, Itabashi-ku, Tokyo 173-8610, Japan.

reported to be successful, with a low morbidity.¹⁾ However, the potential postoperative complications related to graft harvesting such as injury of the sensory nerves or wound infection may significantly affect the patient's quality of life.²⁾ Although there have been studies evaluating the risk factors for saphenous vein graft (SVG) harvest site complications, the rates of complications for radial artery harvest have not been well described.³⁾ In particular, the patient's perception of hand function postoperatively has not been reported in detail. In this study, we assessed the post graft harvesting complications with questionnaires in order to determine the prevalence of

Table 1. Post harvest hand function questionnaire

Questions relate to how your feels now. Postoperative 3 months results:

Q1. Right now, my hand and arm appear to be fine. Yes/No
 With the following questions from 2 to 11, indicate how strongly you agree or disagree right now with the statements by circling one of the levels (1 to 7).
 Levels; 1: not at all, 2: trivial, 3: mild, 4: moderate, 5: quite severe, 6: severe, 7: extreme

Q2. I feel pain in my arm or hand.
 Q3. I feel numbness in my arm or hand.
 Q4. My arm or hand is swollen.
 Q5. I have limited use of my hand.
 Q7. I have difficulties with daily tasks because of the use of my hand and arm.
 Q9. Overall, my life is affected by the problems with my hand or arm.

Table 2. Questionnaire II for comparative study

Q8. I am concerned about the appearance of my arm scar.
 Q9. My arm has a scar that causes discomfort.
 Q10. I have had coronary surgery using my leg vein and I am concerned about the appearance of the leg scar.
 Q11. My leg has a scar that causes discomfort.

postoperative leg and forearm wound complications. We also assessed the wound infections after RA and SVG harvesting.

Patients and Methods

Our Institute has been undertaking a large randomized trial, namely The Australian Radial Artery Study, since June 1996. In this trial, we have followed up patients who received the RA, right internal thoracic artery (RITA), and SVG, which were anastomosed to the recipient vessels excluding the left anterior descending artery (LAD). These patients were assessed in terms of graft patency, mortality, and morbidity. Between June 1996 and June 2000, 343 patients have been enrolled in this project and discharged from the hospital. Patients with varicose veins, uncontrolled diabetes, peripheral vascular disease, severe obesity (body mass index of over than 35) or a positive Allen's test were omitted from this trial. In the present study, 289 patients were selected as subjects, excluding those patients who had received RITA grafts. These patients were divided into the following 2 groups: i) group 1, consisted of 154 patients who underwent CABG with the RA, and (ii) group 2, consisted of 135 patients who received SVGs instead of RAs. All patients had left internal thoracic artery (LITA) to LAD bypasses as well. We assessed the post-harvest wound experience of patients using a 3-month postoperative questionnaire. This ques-

tionnaire contained 7 statements concerning hand and forearm problems in daily life suffered postoperatively (Table 1). In order to compare scar perceptions between the groups, another questionnaire about scar concern and discomfort for the forearm and leg was also employed (Table 2). Before the operation, we informed the patients about the contents of the questionnaires and asked them to fill them in and send them back by mail 3 months after surgery. An answer of higher than grade 3 (mild symptoms) was regarded as a significant complication. Postoperative harvest site infections were also carefully documented. The presence of a wound infection was determined by the need for intravenous antibiotics for the wound redness, swelling or redressing for the purulent discharge from the wound in the hospital.

Harvesting techniques

On the left side, RA harvesting was usually performed by a surgical assistant at the same time that a median sternotomy was performed. On the right side or both sides, RA harvesting was followed by a median sternotomy. The RA harvest technique was previously described in detail.⁴⁾ In the SVG harvesting procedure, electrocautization was never used. After removal of SVG, the wound was closed using the same technique as for the RA. After the removal of the grafts, both the leg and forearm were kept fixed with bandages until the 2nd day postoperatively.

Age, gender, BMI, diabetic rate, aortic cross clamping

Table 3. Perioperative patients' profiles

	Group 1	Group 2	p value
Age	66±8.7	65.9±10.0	0.9072
Gender	M/F=134/20	M/F=117/18	0.8193
BMI	27.2±4.0	27.4±3.6	0.8784
ACCT	72.6±22.3	81.4±24.9	0.0022
ECCT	98.1±29	107.9±35.9	0.084
No. graft	2.96±0.64	3.02±0.56	0.5528
DM	17/154 (17.5%)	32/135 (23.7%)	0.1532
Hospital stay	7.99±11.7	7.98±11.8	0.3336

time (ACCT), cardiopulmonary bypass time (CPBT), numbers of grafts, postoperative infection rate, and duration of hospital stay were compared between the 2 groups. We assessed postoperative hand and forearm problems with the post harvest hand function questionnaire (Q1-7). Furthermore, we compared the rates of wound concern and discomfort between the RA and SVG harvest sites from another questionnaire (Q8-11).

Statistical analysis

The results were expressed as mean and standard deviation (SD) for the metric data. Statistical differences between the groups tested were analyzed using the chi-square test, Mann-Whitney U-test, and Student t-test. Significance was defined as a p value of less than 0.05.

Results

The patients profiles are shown in Table 2. There were no significant differences between the groups in terms of age,

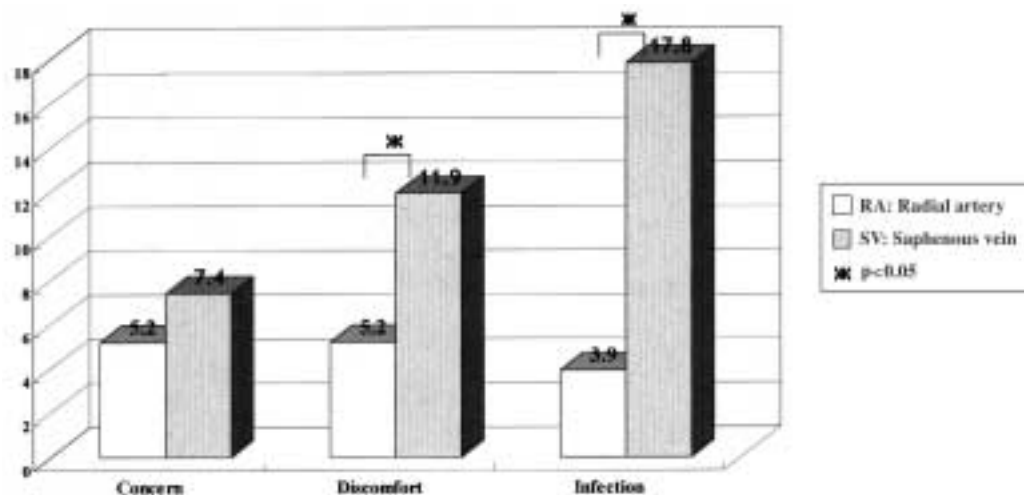
Table 4. Results of hand function questionnaire

Q1	149 of 154 (96.7%) patient with using of RA answered "Yes" in group 1
Q2	21/154 (13.4%)
Q3	28/154 (18.8%)
Q4	3/154 (1.9%)
Q5	5/154 (3.2%)
Q6	7/154 (4.5%)
Q7	4/154 (2.6%)

gender, BMI, CPBT, the numbers of grafts, numbers of diabetics, and postoperative hospital stay (Table 3). The ACCT of group 1 was significantly shorter than that of group 2 (72.6±22.3 min vs. 81.4±24.9 min, p=0.002) (Table 3). In question 1, 149 (96.7%) patients of the group 1 answered "yes" indicating that the hand was fine postoperatively (Table 4). There were no patients complicated by post RA harvest hand ischemia. The prevalence of forearm problems are shown in Table 4. Particularly, in questions 2 and 3, which deal with forearm pain and numbness, 21 (13.4%) and 28 (18.8%) patients in group 1 complained of positive symptoms, respectively (Table 4).

The prevalence of both scar concerns and discomfort for the forearm was similar 5.2% (8/154), respectively. In group 2, the prevalence of these concerns for the leg was 7.4% (10/135) and 11.9% (16/135), respectively (Fig. 1). Although there was no significant difference about the rate of scar concerns, the incidence of scar discomfort was significantly higher in SVG harvest site than RA harvest site (p=0.0139), (Fig. 1).

Six patients (3.9%) in group 1 had forearm wound

**Fig. 1.** Comparative study between the RA and SV harvest sites.

infection. However, all of them suffered from only wound swelling and redness, which promptly improved with oral or intravenous antibiotic therapy. On the other hand, 24 patients (17.8%, $p=0.001$ vs. group 1) in group 2 had leg wound infection, and 15 of these patients needed redressing due to purulent discharge from the wound (Fig. 1).

Discussion

Recently, a number of reports have been published concerning the advantages of using arterial conduits in CABG instead of the SVG.⁵⁻⁷⁾ Several investigators have reported that the biologic characteristics of the vascular wall account for the better patency observed using arterial conduits compared to SVGs.^{8,9)} Furthermore, Weinschelbaum and colleagues have recommended performing a total arterial revascularization using the RA in order to avoid the lower limb complications derived from using the SVG.¹⁰⁾ They argue that this, in turn, may result in earlier ambulation, a shorter hospital stay, and a faster return to daily activities. In Weinschelbaum's paper, however, no comparative study of post harvest complications was carried out between the RA and SVG harvest sites.

In our study, we assessed the post RA harvest hand problems from the questionnaire and also compared the post harvest wound infections and perception of the RA versus SVG of the postoperative recovery. Our study found several positive symptoms in the post-RA harvest hand in terms of arm and hand pain, swelling, hand limitations, difficulties in daily tasks using the hand, and life impact as the results of hand problems. Particularly, the incidences of hand pain and numbness were considerably high, and the other symptoms also might be caused by the pain and numbness. In general, post RA harvest hand pain and numbness are considered to be due to surgical trauma of the superficial branch of the radial nerve, and usually, these symptoms are transient without any functional disturbance.¹¹⁾ In this series, no hand ischemic complications and no motor deficit in the forearm were observed. Interestingly, 96.7% of 154 patients undergoing RA harvest answered that the operated hand was fine on a 3-month postoperative questionnaire despite those symptoms. We consider this is because the majority of patients are still on some pain killers 3 months after surgery. Although those symptoms, which we assessed, were expected to further improve as the rate of pain and numbness decreased, we consider it important to keep following-up the patients about the hand function.

In the questions about concern of appearance of the

wound and discomfort, the complication rates were also rather high. This is probably because the forearm is easily visible and continually used in daily life, and therefore an arm wound is likely to have a significant impact on daily activities. However, when we compared the arm wound and leg wound, the prevalence of scar concern and discomfort in relation to the RA harvest site was less than that of the SVG harvest site. Although there was no significant difference in the rate of scar concerns, the prevalence of scar discomfort of the leg was significantly higher than that of forearm. The forearm scar may have more psychological effect than the leg wound because it is more visible. However, the prevalence of these complications was still higher in the SVG harvest site than that of the RA harvest site.

Several investigators have reported that harvest site infections are another common surgical site infection following CABG. This infection rate may prolong the hospital stay, impact on the wound discomfort, and lead to more severe clinical consequences.^{3,12-14)} The reported prevalence of SVG harvest site infection after CABG is 1 to 18%.¹²⁻¹⁴⁾ Several factors have been identified in previous studies that might predispose patients to SVG harvest site infection, including female gender, increased age, diabetes, peripheral vascular disease, obesity, and wound length and depth.^{12,13)} Meanwhile, Trick and colleagues reported that the incidence of RA harvest site infection was about 3.1 to 12.3%. They found that elevated preoperative blood glucose level (over than 200 mg/dl) and duration of surgery (longer than 5 hrs) were significant risk factors for RA harvest site infection.³⁾ In our trial, patients with risk factors such as uncontrolled diabetes, peripheral vascular disease, and obesity were excluded from this series. Therefore it was possible to compare the incidence of harvest site infections between the RA group and SVG group without the impact of these.

In our study, the incidence of RA and SVG harvest site infections was 3.9% and 17.8%, respectively. Although the rate of harvest site infection was significantly lower in the RA group than in the SVG group, the postoperative hospital stay was similar between the groups. This is because the infected wounds were healed in the out-patient clinic with oral and intravenous antibiotics and wound dressing, unless the patient was febrile or had hemodynamic instability. It is not known why the rate of RA harvest site infection is lower than the SVG harvest site. After RA harvesting, the wound was immediately dressed, bandaged, and fixed beside the patient. In SVG harvesting, however, the wound was exposed until the

end of surgery. This may increase the risk of harvest site infection. The other possibility may be wound edema. The primary cause of edema is regional obstruction of venous or lymphatic circulation. In particular, the leg is more likely to suffer from edema than the forearm because of staging the venous return due to dropping the legs. Normal wound healing requires adequate perfusion of the operated tissue. A wound with severe edema may be compromised by lower perfusion and consequently has an increased risk of impaired wound healing.¹⁵⁾ Therefore, if we take the SVG, it is important to avoid using cauterization as much as possible in order to preserve the blood perfusion in the fatty tissue and to keep bandaged for a slightly longer time to prevent post harvest wound edema.

Conclusion

RA harvest is associated with fewer wound infections and scar discomfort than SVG harvest. Radial artery harvest is almost acceptable in terms of a patient's perception. However, there are still patients who have some symptoms in the forearm after RA harvest. Long-term follow-up is necessary for patient's hand function.

Acknowledgments

We thank Mr Seevanayagam, FRACS in Austin Hospital, Miss Alida Gouwa and Nicky Peters who were medical students from Netherlands for helping in the preparation of this project.

References

1. Lohr JM, Paget DS, Smith JM, Winkler JL, Wladis AR. Upper extremity hemodynamic changes after radial artery grafting for coronary artery bypass. *Ann Vasc Surg* 2000; **14**: 56–62.
2. Arons JA, Collins N, Arons MS. Permanent nerve injury in the forearm following RA harvest: a report of two cases. *Ann Plastic Surg* 1999; **43**: 299–301.
3. Trick WE, Scheckler WE, Tokars JI, et al. Risk factors for radial artery harvest site infection following coronary artery bypass graft surgery. *Clinical Infectious Diseases* 2000; **30**: 270–5.
4. Acar C, Buxton B, Norsworthy C, Eizenberg N, Liu JJ, Taggart D. Radial Artery. In: Buxton B, Frazier OH, Westaby S eds.; *Ischemic Heart Disease Surgical Management*. London, Philadelphia, St Louis, Tokyo: Mosby, 1999: pp 151–7.
5. Calafiore AM, Di Giammarco G, Teodori G, et al. Radial artery and inferior epigastric artery in composite grafts: improved midterm angiographic results. *Ann Thorac Surg* 1995; **60**: 517–24.
6. Borger MA, Cohen G, Buth KJ, et al. Multiple arterial grafts: radial versus right internal thoracic arteries. *Circulation* 1998; **98** (19 suppl): II7–13; discussion II3–4.
7. Barner HB, Standeven JW, Reese J. Twelve-year experience with internal mammary artery for coronary artery bypass. *J Thorac Cardiovasc Surg* 1985; **90**: 668–75.
8. Barner HB. Defining the role of the radial artery. *Semin Thorac Cardiovasc Surg* 1996; **8**: 3–9.
9. van Son JM, Smedts F, Vincent JG, van Lier HJ, Kubat K. Comparative anatomic studies of various arterial conduits for myocardial revascularization. *J Thorac Cardiovasc Surg* 1990; **99**: 703–7.
10. Weinschelbaum EE, Gabe ED, Macchia A, Smimmo R, Suarez LD. Total myocardial revascularization with arterial conduits: radial artery combined with internal thoracic arteries. *J Thorac Cardiovasc Surg* 1997; **114**: 911–6.
11. Acar C, Jebara VA, Portoghese M, et al. Revival of the radial artery for coronary artery bypass grafting. *Ann Thorac Surg* 1992; **54**: 652–60.
12. Mullen JC, Bentley MJ, Mong K, et al. Reduction of leg wound infection following coronary artery bypass surgery. *Can J Cardiol* 1999; **15**: 65–8.
13. Wong SW, Fernando D, Grant P. Leg wound infections associated with coronary revascularization. *Aust NZ J Surg* 1997; **67**: 689–91.
14. Goldsborough MA, Miller MH, Gibson J, et al. Prevalence of leg wound complications after coronary artery bypass grafting: determination of risk factors. *Am J Critical Care* 1999; **8**: 149–53.
15. Wipke-Trevis DD, Stotts NA, Skov Ph, Carrieri-Kohlman V. Frequency, manifestations, and correlates of impaired healing of saphenous vein harvest incisions. *Heart & Lung* 1996; **25**: 108–16.