Solitary Small Hepatic Angiosarcoma: Initial and Follow-up Imaging Findings

Suk Hee Heo, MD[1]
Yong Yeon Jeong, MD[1]
Sang Soo Shin, MD[2]
Tae Woong Chung, MD[1]
Heoung Keun Kang, MD[1]

We report an uncommon case of solitary, small hepatic angiosarcoma that was initially considered as a hemangioma. We present the imaging findings, with an emphasis on the initial and follow-up CT and MR findings, as well as report on the more suggestive findings of angiosarcoma than those of a hemangioma.

Index terms:
Liver neoplasms
Sacoma
Computed tomography (CT)
Magnetic resonance (MR)

Korean J Radiol 2007;8:180-183
Received April 4, 2006; accepted after revision June 15, 2006.

[1]Department of Diagnostic Radiology, Chonnam National University Hwasun Hospital, Hwasun 519-809, Korea;
[2]Department of Diagnostic Radiology, Chonnam National University Hospital, Gwangju 501-757, Korea

Address reprint requests to:
Yong Yeon Jeong, MD, Department of Diagnostic Radiology, Chonnam National University Hwasun Hospital, 160 Ilsim-ri, Hwasun-eup, Hwasun-gun, Jeollanam-do, 519-809, Korea.
Tel. (8261) 379-7112
Fax. (8261) 379-7133
e-mail: yjeong@chonnam.ac.kr

Primary hepatic angiosarcoma is a very rare tumor (1). Koyama et al. (2) classified hepatic angiosarcomas into 4 types: multiple small nodules, a large dominant mass, large focal lesion and diffuse infiltrating lesions. Most reported cases are of the first 2 types and a few areas of each tumor are of the latter 2 types. To our best knowledge, a solitary small ($\leq$ 20 mm) hepatic angiosarcoma has not previously been reported in the radiology literature. We report here on a solitary, small hepatic angiosarcoma, and we include the initial and follow-up CT and MR findings.

CASE REPORT

A 60-year-old man was admitted with a hepatic mass that was incidentally detected during a screening examination. There was a history of treated hypertension and gout. His laboratory values of the liver function were normal. The serum α-fetoprotein and liver enzymes levels were normal. He had no history of extrahepatic malignant neoplasm or exposure to any carcinogens.

Initial contrast-enhanced screening CT demonstrated a 1.1 cm mass in the hepatic dome (Figs. 1A–C). Three phase contrast-enhanced CT demonstrated a low attenuated lesion without definite enhancement on the arterial phase image (Fig. 1A), some peripheral nodular enhancement on the portal-venous phase image (Fig. 1B), and progressive and delayed filling enhancement on the delayed image (Fig. 1C). Although the enhancement pattern of the mass was slightly different from the typical enhancement of hemangiomas, which has a similar density to the contrast-opacified blood in the aorta or hepatic artery during all phases of imaging, the presumptive diagnosis was a hemangioma because of the lesion's small size and the delayed and homogeneous enhancement on three phase contrast-enhanced CT. MR images three months later showed a 2 cm well-circumscribed mass with surface retraction of the hepatic dome (Figs. 1D–H). The T1-weighted MR image (Fig. 1D) revealed a hypointense mass with a hyperintense focus. The T2-weighted MR image (Fig. 1E) showed a heterogeneous hyperintense mass with hypointense areas. The hyperintense focus on the T1-weighted image was considered as hemorrhage within the mass. The gadolinium-enhanced MR images showed heterogeneous enhancement with peripherally rim enhancement on

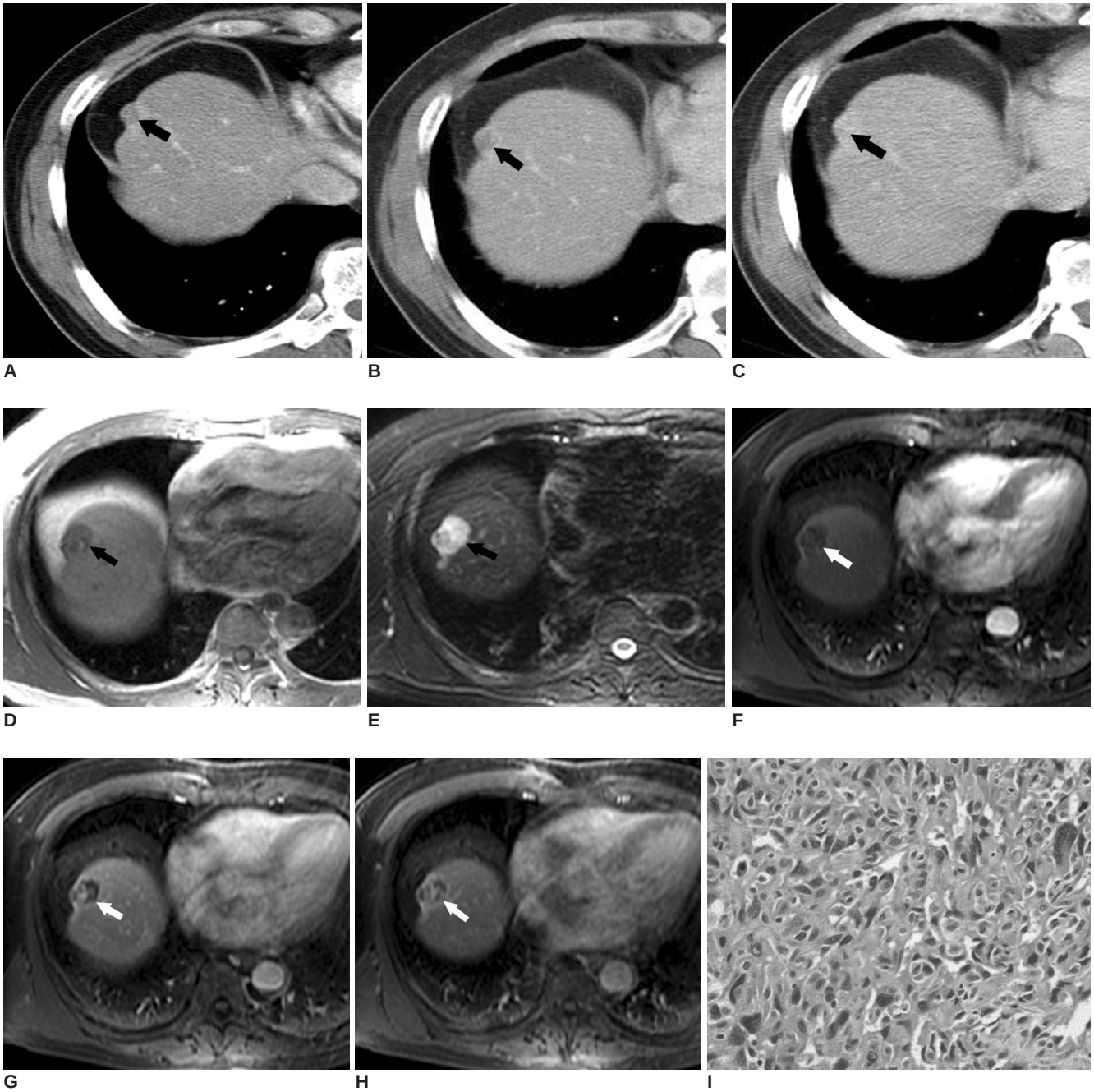

Fig. 1. A 60-year-old man with hepatic angiosarcoma.
A. The arterial phase contrast-enhanced CT image shows a 1.1 cm low attenuated lesion in the hepatic dome (arrow).
B. The portal-venous phase contrast-enhanced CT image shows some peripheral nodular enhancement (arrow).
C. The delayed phase contrast-enhanced CT image shows a persistent, homogeneous enhancing mass (arrow).
D. The T1-weighted gradient-echo (TR/TE = 120/4.2 msec) MR image three months later shows a hypointense mass with focal hyperintense foci that were considered as hemorrhage within the mass in the hepatic dome. Note the increased size of the mass (arrow) compared with the initial CT (**A-C**).
E. The fat-suppressed T2-weighted fast spin-echo (TR/TE = 6666/91 msec) MR image shows a heterogeneous hyperintense mass with areas of low signal intensity (arrow).
F. The arterial phase contrast-enhanced gradient echo (TR/TE = 180/1.5 msec) MR image shows faint peripheral rim enhancement (arrow).
G. The portal-venous phase contrast-enhanced gradient echo (TR/TE = 180/1.5 msec) MR image reveals centrally septal-like enhancement (arrow).
H. The delayed phase contrast-enhanced gradient echo (TR/TE = 180/1.5 msec) MR image shows heterogeneous and persistent enhancement (arrow).
I. Photograph (original magnification, ×400; H & E staining) of the specimen shows the numerous and irregular vascular spaces separated by fibrous septa and lined by pleomorphic and hyperchromatic endothelial tumor cells.

the arterial phase image (Fig. 1F), centrally septal-like enhancement on the portal venous phase image (Fig. 1G), and persistent enhancement on the delayed image (Fig. 1H). The size of the lesion increased on the follow-up MR images. The preoperative diagnosis was that of a malignant mass, and surgical resection was performed.

The gross specimen showed a 2 ×1.5 ×1.5 cm white to red solid mass with an area of hemorrhage. Microscopic examination revealed numerous, irregular and anastomosing vascular spaces separated by fibrous septa, and the spaces were lined by variably pleomorphic and hyperchromatic endothelial cells. Tumor cells grew along the vascular channels, particularly along the sinusoids, with a multilayering and papillary growth pattern (Fig. 1I). The final histopathologic diagnosis was hepatic angiosarcoma.

Twenty-five months after undergoing surgery, there is no evidence of tumor recurrence and metastasis on the follow-up CT.

DISCUSSION

Primary hepatic angiosarcoma accounts for only 2% of primary hepatic tumors, although it is the most common malignant mesenchymal tumor of the liver. It commonly affects patients who are 60 –70 years of age and there is a male preponderance. Angiosarcoma is known to be associated with environmental or occupational exposure to carcinogens (thorium dioxide, vinyl chloride, arsenic and radiation) and it's also associated with hemochromatosis and von Recklinghausen disease. However, most of these tumors occur either in the absence of known risk factors or with cirrhosis of the liver (1).

The radiologic findings of hepatic angiosarcoma have varied in the reports in the literature. The common gross findings of angiosarcoma are multinodular lesions or a large solitary mass (1, 2). When an angiosarcoma appears as a large mass, angiosarcoma may show heterogeneous enhancement on the dynamic contrast-enhanced CT images. At delayed imaging, there is progressive enhancement of the lesion compared with that of the early phase images. This enhancement pattern on dynamic contrast-enhanced images could mimic that of a cavernous hemangioma because the histopathologically multiple vascular channels that are separated by fibrous septa are similar in both tumors (3). However, recent reports performed with faster scanning techniques have described an enhancement pattern of angiosarcoma that differs from that of the typical hemangiomas. Angiosarcoma shows more heterogeneous and persistent enhancement that may be less than that of the aorta or hepatic artery, while hemangioma show progressive centripetal nodular enhancement that is of similar density of the contrast-opacified blood in the aorta or the hepatic artery during all phases of imaging (2, 4).

Angiosarcoma may contain areas of high signal intensity on the T1-weighted images and markedly heterogeneous architecture can be noted on the T2-weighted images. These findings suggest hemorrhage and fibrous septa within the tumor (4). When angiosarcoma appears as multiple masses, it often cannot be readily distinguished from hypervascular metastases and hepatocellular carcinoma. However, the bizarre areas of ring enhancement, the persistent and progressive enhancement, the splenic metastases and the lack of cirrhosis may suggest angiosarcoma (2, 4). Hepatocelluar carcinoma may show early central enhancement and arterioportal shunting on dynamic CT, which distinguishes it from hepatic angiosarcoma and cavernous hemangioma (5).

Previous studies have shown that the small hepatic lesions that are discovered incidentally during the investigation of patients are almost always benign, even in the patients with established malignant neoplasm. These lesions probably need to be followed up with CT or other confirmatory imaging studies rather than by performing invasive diagnostic procedures (6, 7).

A small, hepatic nodule was incidentally detected in our case. On the initial screening contrast-enhanced CT images, it showed progressive centripetal enhancement, which was slightly different from the typical enhancement of hemangiomas. The follow-up MR images three months later showed an increase in the size of the mass and also in the adjacent hepatic surface retraction. The T1-weighted image showed focal high signal intensity and the T2-weighted image showed areas of low signal intensity that may have been related to hemorrhage and the fibrotic septa within the mass. Dynamic contrast-enhanced MR images showed peripherally rim and centrally septal-like progressive enhancement, which are distinguished from that of hemangioma with progressive centripetal nodular enhancement. These findings have been more commonly recognized in malignant hepatic tumors than in benign tumors such as hemangioma (8).

In summary, we report here on a case of a solitary, small hepatic angiosarcoma that was detected on the initial CT and follow-up MRI. If the enhancement pattern of the hepatic mass resembles a hemangioma, but it is slightly different from that of the typical hemangiomas, even if it is small lesion, then follow-up imaging studies should be performed. Heterogeneous signal intensities and centrally septal-like progressive enhancement on the MR images could be findings that are suggestive of hepatic angiosarcoma.

References

1. Buetow PC, Buck JL, Ros PR, Goodman ZD. Malignant vascular tumors of the liver: radiologic-pathologic correlation. *Radiographics* 1994;14:153-166
2. Koyama T, Fletcher JG, Johnson CD, Kuo MS, Notohara K, Burgart LJ. Primary hepatic angiosarcoma: findings at CT and MR imaging. *Radiology* 2002;222:667-673
3. Peterson MS, Baron RL, Rankin SC. Hepatic angiosarcoma: findings on multiphasic contrast-enhanced helical CT do not mimic hepatic hemangioma. *AJR Am J Roentgenol* 2000;175:165-170
4. Itai Y, Teraoka T. Angiosarcoma of the liver mimicking cavernous hemangioma on dynamic CT. *J Comput Assist Tomogr* 1989;13:910-912
5. Ohmoto K, Hirokawa M, Takesue M, Yamamoto S. Hepatic angiosarcoma with early central enhancement and arterioportal shunt on dynamic CT. *Hepatogastroenterology* 2000;47:1717-1718
6. Jones EC, Chezmar JL, Nelson RC, Bernardino ME. The frequency and significance of small (less than or equal to 15 mm) hepatic lesions detected by CT. *AJR Am J Roentgenol* 1992;158:535-539
7. Robinson PJ, Arnold P, Wilson D. Small "indeterminate" lesions on CT of the liver: a follow-up study of stability. *Br J Radiol* 2003;76:866-874
8. Blachar A, Federle MP, Brancatelli G. Hepatic capsular retraction: spectrum of benign and malignant etiologies. *Abdom Imaging* 2002;27:690-699