stances. The well-formed twin died, when about three months old, from bronchitis. The deformed fœtus, a male, showed numerous grave anomalies. The bones of the cranial vault could be felt to be defective, especially the occiput; the nose was flattened out and imperforate; the ears were represented by small apertures without any external ear, and the eyelids of the left eye were imperfect. The skin of the head passed like a cape on to the upper limbs, leaving only the hands free. The thumb and index finger were absent on both sides. There was a ruptured hernia of the umbilical cord. The lower limbs, like the upper, were much deformed. On one foot there were three separate toes, but one of these was evidently three fused together; on the other foot there were three toes. Both the hands and feet were clubbed. The most marked anomaly, however, was shown by the trunk. The whole fœtus was divided into two nearly equal parts: one consisting of head, upper limbs, and chest; the other made up of pelvis and lower limbs, by a deep constriction a little below the level of the umbilicus. The circumference of the body at the level of the constriction was only 12 cms., whilst at the shoulders it was 32 cms. At the constriction no osseous tissue could be felt. The total length of umbilical cord attached to the body was 51 cms. In its first portion it formed a sac for some coils of intestine which were adherent to the sac walls, then its vessels ran in a velamentous fashion in the amnion, and thereafter a true cord was formed.

IV. *Dr J. C. Webster* showed a mounted section of the FEMALE PELVIS AT THE BEGINNING OF LABOUR.

V. *Dr Haultain* exhibited a UTERINE POLYPUS from a patient aged 70. The specimen he thought an interesting one from the history of the case. The patient reached the menopause twenty-five years previously, and had suffered no symptoms of uterine trouble till seven months ago, when she had a large amount of hæmorrhagic vaginal discharge. Since that period the discharge has been almost constant, and five similar growths to that shown had been removed. The uterus is still enlarged, and there are evident signs of polypi yet being present.

VI. THE FEMALE PELVIS IN THE BEGINNING OF THE FIFTH MONTH OF PREGNANCY.

By J. C. WEBSTER, M.D., M.R.C.P. Ed.

CLINICAL NOTE.

The patient suffered from a dermoid tumour of the left ovary, enlarged to about the size of a man's brain by recent hæmorrhage, resulting from a twisted pedicle.

It was removed by Dr Berry Hart.[1] The patient made good progress for a week, but on the ninth day died of cardiac failure.

Method of Study.

The pelvis, as well as the abdomen, was removed from the cadaver intact, and was frozen in the usual manner.[2] A vertical mesial section was cut, drawn and described, after which the contents of the amniotic cavity were removed and a cast of the cavity made in plaster of Paris. A cast of the fœtus was also taken. The specimen was then placed in spirit and studied in detail after a few days.

Vertical Mesial Section. (Plate I.)

Bony Measurements.

Brim.—Conjugate, Anatomical,	$4\frac{1}{4}$	in.
„ Obstetrical,	4	„
Cavity.—Conjugate, . .	$4\frac{3}{4}$	„
Outlet.—Conjugate, Sacral, .	$3\frac{7}{8}$	„
„ Coccygeal,	$4\frac{1}{4}$	„

Vertical length of symphysis is one and a half inches, of sacrum and coccyx six inches.

Pelvic floor projection is one and five-eighth inches.

The umbilicus is opposite the junction of the third and fourth lumbar vertebræ.

Uterus.—Occupies the main part of the pelvic cavity and extends also above the brim. It is in close contact with surrounding structures. Above the brim the anterior wall lies against the abdominal parietes and higher up against intestine. The fundus and upper part of the posterior wall are also in relation to intestine. The highest point of the uterus is two and three-quarter inches above the brim. Below the brim the anterior wall presses against the pubes and the upper wall of the bladder, the posterior wall touching from above downwards the upper part of the sacrum, the upper part of the rectum, and a dermoid tumour of the right ovary which lies in the pouch of Douglas.

The lower part of the cervix is in close contact with the vaginal walls.

The *os externum* is four inches below the brim, and the *os internum* three and one-eighth inches.

The vertical mesial circumference of the whole uterus is sixteen and a half inches.

The *body* is of firm consistence and of a pink-gray colour, that part with the placenta being slightly darker. On close examina-

[1] To Dr Hart's great kindness I am indebted for the specimen.
[2] *Lab. Reports*, vol. ii. p. 3.

tion the muscle shows a finely striated appearance, chiefly in a longitudinal direction. Several closed vessels are seen in the upper portion of the body, being especially numerous opposite the placenta. In the lower portion of the body very few vessels are seen.

Though there is no definite point at which the body can be divided into an *upper* and *lower uterine segment*, it is very evident that this distinction can be made out—the upper portion of the uterine wall being considerably thicker than the lower portion, the passage from one to the other being gradual. On the anterior wall the difference is best marked, the point of division being about four and three-quarter inches above the cervix, or one and a half above the symphysis; on the posterior wall the change takes place lower down—about three-quarters of an inch nearer the cervix.

The average thickness of the *upper uterine segment* is nearly half an inch; that of the *lower uterine segment* being in the anterior wall three-sixteenths, and in the posterior one-quarter. Near the cervix both walls thicken slightly as they pass into the cervix.

The *cervix* is darker in colour and coarser in texture than the body, being an inch in length. The anterior and posterior walls are in apposition at the lower end of the canal, but in the rest of its extent slightly separated, the upper end of the canal being funnel-shaped; it contains mucus. Both walls are of much the same thickness, the posterior being, if anything, slightly thicker.

The *placenta* is on the anterior wall, being mostly on the *upper* but partly on the *lower uterine segment*. It is of a dark red-purple colour. It is three-quarters of an inch in its greatest thickness—just above its centre; it thins more markedly towards the lower end.

The *membranes* are seen as a thin lining on the wall of the uterus and crossing the os internum.

The *liquor amnii*, the cord, the arms, and thorax of the fœtus cut transversely, are well shown.

The *peritoneum* in front descends to a point two and three-sixteenth inches below the brim, and behind three and one-quarter below it.

Over the *lower uterine segment* anteriorly it is loosely attached, but posteriorly it is closely attached, just as it is to the upper uterine segment.

The *bladder* is empty. It lies partly above, partly below the conjugate of the outlet. The upper surface is concave and in relation with the anterior uterine wall. It is in front closely attached to the back of the pubes, there being no well-defined retropubic triangular pad of fat between them. A thin layer of fat covers the anterior portion of the upper surface, and is continuous with a well-marked layer passing upwards to the abdominal wall. The upper wall below the utero-vesical pouch is

connected to the uterus by very loose cellular tissue. The cavity is a mere slit.

The *urethra* lies entirely below the outlet; it is sigmoid-shaped, one and three-eighth inches in length. The junction of urethra and bladder lies three inches below the brim.

The *vagina* has much less of the sigmoid curve than it normally has. The anterior and posterior walls are in apposition, save near the vulva.

The *rectum* is divided from the anus as far as the lower end of the sacrum. A small section of the upper portion of the gut is also seen near the lower end of the first sacral vertebra.

On examining the specimen, after it had been a few days in spirit, further information was gained.

The *uterus* is slightly nearer the right than the left side of the pelvis in its upper part.

The *bladder* slopes from below upwards and to the right, the highest point not being seen in vertical mesial section, being one and a half inches to the right of the symphysis and a quarter above the brim.

The *left broad ligament* cannot be well described, owing to the contraction of the upper part as a result of the removal of the left dermoid ovarian tumour.

The *right broad ligament* in its upper part is somewhat dragged downwards by the right ovarian tumour.

The *right dermoid ovarian tumour* is about the size of a turkey's egg, and lies in the pouch of Douglas, being compressed from before backwards. It contains the ordinary yellowish, fatty-looking contents, with hair, skin, and a few small bones, and from its plasticity is made to appear somewhat flattened between the uterus and the sacrum. No normal looking piece of ovary could be detected, neither was any *corpus luteum* to be found.

Cast of Amniotic Cavity. (Plate II.)

The cast was taken after the fœtus and liquor amnii had been removed, the placenta and membranes being left *in situ.*

Viewed from the front and back it has the general shape of a pear flattened from before backward, the broad end being lowermost. Viewed from the side it is also pyriform, the sides being compressed from before backwards; the anterior surface is markedly convex, the posterior slightly convex below and concave in its upper part. The small antero-posterior diameter of the upper part is due to the flattening of the upper part of the uterus from before backwards, and also to the space occupied by the placenta on the upper part of the anterior wall. The left half of the cast is thicker than the right.

The posterior surface shows a flattening in its lower part chiefly on the right side, caused by the dermoid tumour in the pouch of

Douglas; in its upper part is seen a hollow due to the pushing inwards of the uterine wall by the promontory. On the anterior surface is seen the mark of the placenta occupying somewhat less than half the area of the surface; it is oval in shape, the long axis being almost vertical and measuring four and a half inches, the transverse measuring three and a quarter, while the circumference measures twelve and a quarter.

The water displacement of the whole cast is 610 c.c. The surface-area of the whole cast is about sixty-five square inches. The placental area measures about eleven and three-quarter inches.

Cast of Fœtus.

The parts of the frozen fœtus removed from the amniotic cavity were placed together, and cast in plaster. The attitude is one of flexion, though not of extreme degree, the limbs showing a considerable degree of extension at all the joints. The water displacement of the cast is 210 c.c.

Résumé.

The *pelvic floor projection* is one and five-eighth inches. If this be compared with the projection in other cases, we find that it is greater than in the nulliparous condition, and less than in the later months of pregnancy.

Stage.	Whose Case.	Pelvic floor Projection.	Skin-distance from Coccyx to Symphysis.
Nullipara, . . .	Average, ...	1 in.	$5\frac{1}{4}$ in.
Five months' Preg.,	Webster, ...	$1\frac{5}{8}$ „	$5\frac{1}{2}$ „
Eight months' „ .	Barbour and Webster,	2 „	$6\frac{1}{2}$ „
Nine months' „ .	Braune, ...	$3\frac{3}{4}$ „	10 „
„ „ .	Braune and Zweifel, .	$2\frac{3}{4}$ „	$7\frac{1}{2}$ „

The uterus has the following characteristics worthy of note. Its longest diameter is the vertical, which measures from os externum to fundus about seven and three-quarter inches; the greatest width is five inches; and the greatest antero-posterior diameter four inches. In the frozen state there is seen to be a flattening of the uterus from before backwards. In its upper part this is evidently due to the pressure of the anterior abdominal wall, and in the lower to the presence of the dermoid tumour in the pouch of Douglas. The irregularity of outline of the wall is due to the pressure of neighbouring structures against it, chiefly the symphysis and promontory.

The cast of the cavity shows these points, and also brings out the fact that the uterus near the fundus, in both its transverse and

antero-posterior diameters, is smaller than that part situated just above the cervix. When the parts were examined after thawing took place, the pressure of the anterior abdominal wall being removed, it was found that, when viewed from the side, the antero-posterior measurements of the upper and lower poles of the uterus were more nearly equal than they appeared to be in the frozen state. The fact that the upper portion of the uterus is not of larger bulk than the lower is worthy of note.

At the beginning of pregnancy the pyriform shape of the uterus,

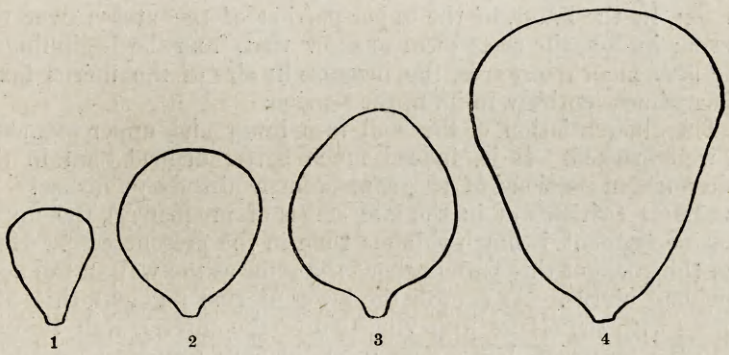

OUTLINE OF UTERUS SEEN FROM THE FRONT.

1. At the beginning of pregnancy. 2. During the third and fourth months. 3. At the beginning of the fifth month. 4. At the end of pregnancy.

with its wide upper and narrow lower portion, is well recognised. A similar shape is again found late in pregnancy, as frozen sections and casts made by Dr Barbour and myself show.[1] It is also usually taught that, after the very early months, the uterus becomes spherical in shape. In this five months' case the uterus is neither spherical, nor pyriform as in the later months. It seems, indeed, to be in an intermediate position. The longest diameter is the vertical one. The antero-posterior diameter is greatest just below the middle of the body. Of special interest, however, is the shape of the body as seen from the front. It differs from the pyriform and spheroidal shapes of the early months, as well as from the pyriform of the late months; it has indeed a pyriform appearance, with, however, *the widest part lowermost* and not uppermost, as is the case in the late months. The foregoing diagrams represent the uterus as seen from the front at various stages of pregnancy.

Whether this is the normal shape at the beginning of the fifth month can only be demonstrated by frozen sections and casts of other cases. In this case it is possible that the presence of the tumours may have somewhat modified the growth of the

[1] *Lab. Reports*, vol. ii. p. 1.

uterus, though one cannot definitely settle this point. Even, however, allowing for the pressure on the lower uterine segment by the small tumour in the pouch of Douglas, it is evident that the transverse diameter of the upper part of the uterus is at least *not greater* than that of the lower part (thus differing greatly from the condition in early and late pregnancy). There seems, indeed, to be no doubt that in this case the lower diameter is wider than the upper.

If the uterus be compared with that of an eight months' pregnancy case,[1] it is evident that there is a marked preponderance in size, in the latter, of the upper portion of the uterus over the lower; in fact, the casts seem to show that, from the beginning of the fifth month onwards, the increase in size of the uterus takes place almost entirely in its upper portion.

The differentiation of the wall into lower and upper segments is well marked. It is, indeed, much better defined than in the other frozen sections of pregnant women already published. In the latter (which are in the late stages of pregnancy), the upper uterine segment is much thinner than in the present case. Here the thickness of this part is about the same as the wall of the non-pregnant uterus. As regards the lower uterine segment, this case agrees with the others in having that of the anterior wall thinner than the posterior, but differs from them in the great extent to which it is developed. Anteriorly, the apparent junction of the upper and lower segments is more than four inches above the cervix (at this point there is a sinus in the wall—? circular sinus); below this level the peritoneum is loosely attached, while above it, it is very firmly attached. Posteriorly, the lower uterine segment is not so well marked off from the upper; the peritoneum covering it is firmly attached save in the lowermost portion.

In none of the other published cases is the lower uterine segment of such a length as in this case. In a uterus at full time, described by Bayer,[2] it measured three and one-eighth inches (8 c.c.); in another it measured three and one-sixteenth (7·5 c.c.). Hofmeier[3] has also found it to measure two and three-quarters (7 c.c.) in two full-time cases.

Is the extreme degree of development of the lower uterine segment in this case abnormal or only unusual? In Barbour's table,[4] describing all the uteri in which the segment has been described, the greatest variations are found to exist. For example, in Benckiser's four months' case, the firm attachment of the peritoneum is one and three-eighth inches (3·5 c.c.) above the cervix, whereas in Bayer's it is opposite the upper end of the cervix. There is no reason to doubt that the present condition is but one of many variations found.

[1] *Lab. Reports*, vol. ii. p. 7.
[2] *Morph. d. Gebärmutter*, 1885.
[3] *Das untere Uterinsegmentes, etc.*, 1886.
[4] *The Anat. of Labour, etc.*, 1889.

Possibly the firm attachment of the peritoneum may not mark the upper limit of the segment, though, indeed, it is exactly opposite the junction of the thick upper and thin lower uterine segments. In some cases described by Bandl, it was a little above the upper end of the lower segment.

It is possible, also, that the uterine wall to which the lowest bit of the placenta is attached is not lower but upper segment, and it may be only the commencement of the thinning of that part of the wall because of the placental attachment. In the other frozen sections the placental part of the wall is much thinner than in the present case. Allowing for this possible explanation of part of the thinning, there would still remain a lower segment of exceptional length—*the longest of any recorded case.*

It is very evident that the cervix does not enter into the formation of the lower segment; it is of much the same size as in the nulliparous condition. A careful study of all the vertical mesial frozen sections in published cases shows that in the later months the cervix is as large as in the early period, being only somewhat compressed from above downwards, so that it appears slightly shorter and thicker. This condition is chiefly due to the pressure of the softened uterus against the sacral segment of the pelvic floor; the softening becomes even more marked as pregnancy advances. Owing to the continued hyperæmia there may even be some increased growth.

Much of the discussion as to the relation of the cervix to the lower segment has arisen from the study of uteri removed from the body; in this way flattening of the cervix occurs, so that its normal shape is completely altered. Moreover, a microscopic study of the mucous membrane cannot decide the question; the passage of the cervical mucous membrane into the decidua of the lower segment is not abrupt but gradual, and no well-defined os internum can be made out. Of much greater value is the examination of the muscular tissue, that of the lower segment being arranged in a series of plates, mostly longitudinally arranged, that of the cervix being a felted network of bundles.

The *peritoneum* has a somewhat unusual arrangement. In front, the bottom of the utero-vesical pouch is not as low in relation to the cervix and bladder as is generally the case; behind, also, the bottom of the pouch of Douglas is above the level of the posterior fornix, not reaching down between the rectum and upper part of the posterior vaginal wall as it does in the great majority of cases. The dip of the utero-vesical pouch below the brim is two and three-sixteenths inches, and that of the pouch of Douglas three and a quarter. If these measurements be compared with corresponding ones in the nullipara, there is found to be very little difference.

The peculiarity in this case is not that the pouches are unusually high, but that the uterus is exceptionally low in the

pelvis. It is probable that the peritoneum has not descended with the uterus as the latter has sunk down, and has been consequently separated from its lowest attachments. The tissue below the utero-vesical pouch, between the bladder and lower uterine segment, is very delicate and loose, and would easily allow of this separation.

The reflection of the peritoneum, from the anterior abdominal wall to the bladder, is exceptional. In most nulliparous cases, the highest point of the bladder is in the middle line, either above or below the upper margin of the symphysis, the outer edge sloping downwards and outwards on each side behind the pubic bones.

In this case, however, the bladder is inclined obliquely from below upwards and to the right, the highest point being a quarter of an inch above the brim, and one and a half to the right of the symphysis.

The disposition of the pelvic peritoneum during pregnancy has not yet been definitely settled. Regarding its lateral arrangement it is clear that, during the progress of gestation, as the uterus increases in its transverse and vertical diameters, the peritoneum on each side of the pelvis is considerably elevated. This has been well demonstrated by Barbour and Polk.

Regarding the arrangement in front and behind, there is considerable uncertainty. Polk[1] declares that the peritoneum is lifted up so that (while in the non-pregnant condition a line drawn from the centre of the symphysis to the junction of the third and fourth sacral bones corresponds to its lowest portion in front of the uterus and behind, except the pouch of Douglas) at the end of pregnancy, and before the uterus has fallen, its lowest level (excepting the pouch of Douglas) is at a line from the centre of the symphysis to the promontory.

This statement is not in accord with the evidence furnished by frozen sections. Polk formed his conclusions from dissectional work—an unreliable method in determining topographical relationships, especially in investigating pregnancy, because, owing to the increased softening of the pelvic tissues in that condition, they are very readily stretched and compressed, the normal position of parts being easily altered.

Most of the frozen sections of nulliparæ show that the peritoneum reaches a lower level than that indicated by Polk.

In regard to the changes during pregnancy, though we cannot speak with absolute certainty, owing to the lack of a sufficient number of frozen sections, yet we have sufficient facts at our disposal to disprove the statements made by Polk and others. Variations are doubtless found, just as in the nulliparous condition. If we measure the dip of the peritoneal pouches below the brim of the present five months' case, in Barbour and

[1] *New York Med. Journ.* vol. xxxv. p. 560.

Webster's eight months' case, and in Braune's full-time case, we find that the pouches are as low as in the nullipara, or even lower. In a sixth months' case of Barbour's (unpublished) it is three-quarters of an inch lower (I leave out of consideration the full-time cases of Waldeyer, and Braune and Zweifel, the first having a fractured pelvis and the other an unusual arrangement of the bladder).

The changes in the anterior attachments of the peritoneum during pregnancy have always been described in relation to the uterus and the bladder. The growing uterus elevates the peritoneum, it is usually said, stripping it from the bladder; the pouch of Retzius, therefore, as well as that of Douglas, must reach a higher level as pregnancy advances. This conclusion is contradicted, we find, by frozen sections.

As regards the stripping of the bladder, we find, certainly, that this does take place in pregnancy, though, as the sections show, the amount varies in different cases. From a study of the frozen sections, it seems to me that the hitherto attributed cause, viz., the elevation of the peritoneum by the growing uterus, is not the main cause. The growth-changes in the uterus in the latter half of pregnancy, as I have already indicated, affect chiefly its upper and not its lower part. It is difficult to see how these changes can disturb the peritoneal relations of the pouches of Douglas and Retzius. The explanation is rather that the bladder is stripped away from the peritoneum by the sinking of the pelvic floor; owing to the very delicate loose connective tissue joining the bladder and peritoneum, the latter does not follow the posterior part of the former in its downward descent.

Usually the bulging of the floor is most marked near the end of the pregnancy, and Waldeyer's and Braune's sections show a great part of the bladder uncovered. In Barbour and Webster's eight months' case, where the bladder is not so pushed down, there is scarcely any stripping of the peritoneum. In this five months' case, where the bladder is very low, a considerable portion has lost its peritoneum.

The variations that are found in the different cases may have normally existed in the non-pregnant condition, but they are, no doubt, partly due to the fact that the peritoneum of the utero-vesical pouch is more or less folded in different cases. Whatever be the cause of the stripping of the bladder, the extent of the stripping must depend upon the number and size of these folds to be unfolded.

As regards the pouch of Douglas, there is no elevation in its central portion throughout the whole pregnancy.

The explanation of the low position of the uterus is not evident. The frozen sections of full-time cases show as much sinking, while in the eight months' case it is nearly as low. It is usually taught that this extreme degree is only normally met with at the end of

gestation. It may be that the sinking is progressive from about the middle of pregnancy, being, in some cases, very marked long before term. In this case, it must not be forgotten, the presence of the tumours may have something to do with the low position.

The co-existence of pregnancy and double ovarian tumour, though rare, has been noticed in several cases. Sometimes, as here, it is impossible to find ovarian tissue, while no corpus luteum may be found.

Bibliography.

Barbour.—1. *The Anatomy of Labour and its Clinical Bearings.* Edinburgh, 1889.

2. *Atlas of the Anatomy of Labour.* Edinburgh, 1889.

Barbour and Webster.—"Anatomy of Advanced Pregnancy and of Labour," *Lab. Reports, R.C.P.Ed.*, 1890.

Bayer.—*Morphologie d. Gebärmutter, etc.* Strassburg, 1885.

Bandl.—*Ueber d. Verhalten d. Uterus u. Cervix in d. Schwangerschaft u. wahrend d. Geburt.* Stuttgart, 1876.

Benckiser.— *Zur Anat. d. Cervix u. unteren Uterinsegmentes, etc.* Stuttgart, 1887.

Braune.—*Die Lage d. Uterus u. Fœtus am ende d. Schwangerschaft.* Leipsic, 1872.

Braune u. Zweifel.—*Gefrierdurchschnitte durch den Körper e. Hochswang. geführt.* Leipsic, 1890.

Hofmeier.—*Das untere Uterinsegmentes in Anat. und Physiolog. Beziehung.* Bonn, 1886.

Polk.—"Observations upon the Anat. of the Female Pelvis," *N. Y. Med. Journ.* vol. xxxvi.

Waldeyer.—*Medianschnitt einer Hochschwangeren, etc.* Bonn, 1886.

DESCRIPTION OF PLATES.

Plate I.

a. Level of umbilicus.
b. Fundus uteri.
c. Placenta.
d. Liquor amnii.
e. Venous sinus.
f. Umbilical cord.
g. Symphysis pubis.
h. Utero-vesical pouch of peritoneum.
i. Bladder.
j. Promontory.
k. Junction of upper and lower uterine segments of posterior wall of uterus.
l. Bit of rectum.
m. Arm of fœtus.
n. Dermoid tumour of right ovary.
o. Fœtal heart.
p. Pouch of Douglas.
q. Rectum.
r. Os internum.
s. Os externum.
t. Anterior fornix.

Plate II.

Cast of Amniotic Cavity.

1. Seen from the front.
a. d. Fundus uteri.
c. f. Os internum.

2. Seen from the left side.
b. Placental area.
e. Promontory mark.

PLATE I.

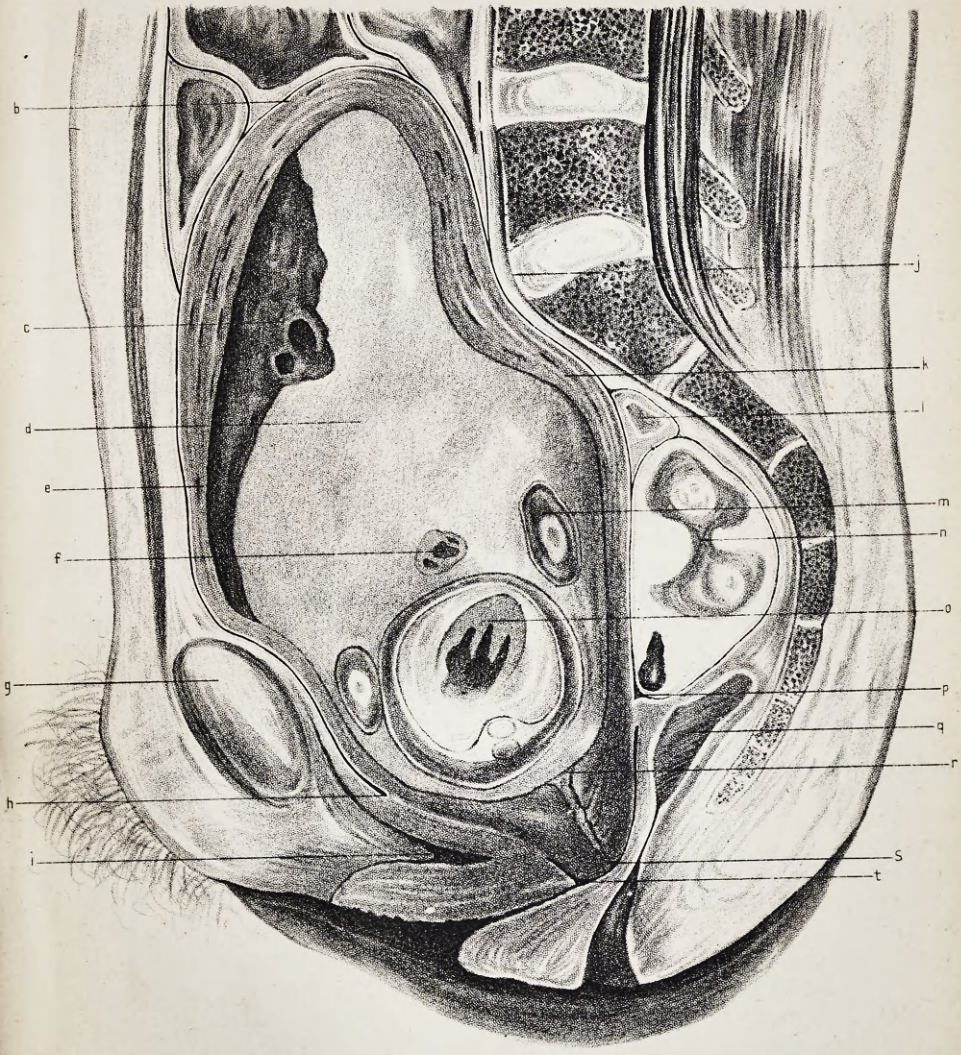

Vertical Mesial Section of the Pelvis at the beginning of the Fifth Month of Pregnancy (×).

PLATE II.

FIG. 1.

FIG. 2.

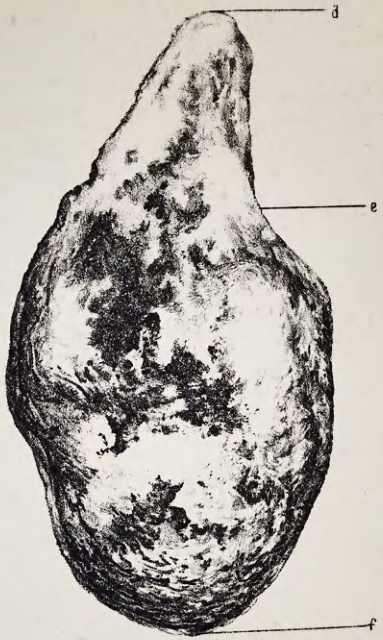

CAST OF AMNIOTIC CAVITY.

1. Seen from the front. 2. Seen from the left side.

a, *d*. Fundus uteri. *b*. Placental Area.

c, *f*. Os internum. *e*. Promontory mark.

The President remarked on the value of Dr Webster's communication, which did not lend itself much to discussion, but which would prove a very notable contribution to our knowledge of the pregnancy changes in the uterus and the other pelvic viscera. There were many of the debateable points on which this research would give important information. In regard to the lower uterine segment, for instance, this case seemed to confirm the opinion that was gradually becoming established, that the cervical canal did not open from above to receive the ovum during pregnancy, though Dr Webster had indicated that the line of demarcation between the mucous membranes of cervix and uterus was not so well defined as some had been disposed to allege. That the question was not finally answered was shown in a recent paper by Keilman, who from study of changes in the gravid uterus of the bat was able to trace how in that animal the upper part of the cervical canal expanded during pregnancy to receive a portion of the ovum. He (the President) regarded also the observation as to the mode in which the bladder became to some extent denuded of peritoneum as of special value, and thought that Dr Webster's explanation was likely to be correct, all the more if we kept in view the firmer attachment of the peritoneum to the anterior abdominal wall than to the bas fond of the bladder, and remembered how the growing mass of the uterus tended to stretch the abdominal walls outwards and upwards in all their thickness from the striated skin to the tense peritoneal lining. The paper altogether was one of exceptional interest and value.

Dr Berry Hart thought Dr Webster's paper supplied a valuable link in the series of preparations. He himself had never believed in the raising of the peritoneum during pregnancy—it was a labour phenomenon.

VII. PEDUNCULATED UTERINE GROWTHS: A Practical *Résumé* of a Series of Cases.

By F. W. N. Haultain, M.D., F.R.C.P. Ed., Lecturer on Midwifery and Diseases of Women, Edinburgh School of Medicine; Obstetrician and Gynæcologist, Royal Dispensary, Edinburgh.

Having within the last nine months had under treatment four patients suffering from intravaginal pedunculated uterine growths, each of which represented a distinct type of neoplasm, I bring before you a short account of the cases and a description of the structural character of the tumours, which I hope may be of interest both from a clinical and a pathological standpoint.

Stalked growths of the uterus, though not infrequently met with, cannot be reckoned as of common occurrence,—thus, for instance, in Ward 28, Royal Edinburgh Infirmary, during the last six years only twenty-two cases are recorded: of these seventeen