

Diethylstilbestrol-Treated Adult Rats with Altered Epididymal Sperm Numbers and Sperm Motility Parameters, but Without Alterations in Sperm Production and Sperm Morphology¹

H.O. Goyal,^{2,3} T.D. Braden,⁵ M. Mansour,³ C.S. Williams,³ A. Kamaleldin,³ and K.K. Srivastava⁴

Department of Biomedical Sciences³ and Department of Pathobiology,⁴ Tuskegee University, Tuskegee, Alabama 36088
 Department of Anatomy, Physiology and Pharmacology,⁵ Auburn University, Auburn, Alabama 36849

ABSTRACT

In this study, we characterized estrogenic effects of diethylstilbestrol (DES) on reproductive parameters in male rats to identify a minimal dose level that alters epididymal and sperm functions but has little or no effect on sperm production and/or spermatogenesis. Adult rats (five animals/group) received s.c. injections of 0.2 ml of corn oil containing DES at a rate of 1.0 mg, 200 μ g, 40 μ g, 8 μ g, 1.6 μ g, or 320 ng rat⁻¹ day⁻¹ for 12 days. The control group received corn oil only. DES effects were similar in the 8- μ g group and higher dose groups and included significant ($P \leq 0.05$) reductions in 1) absolute and relative weights of the head and body of the epididymis (EP), tail of the EP, and seminal vesicle, 2) numbers of sperm in both regions of the EP, and 3) motility characteristics in sperm collected from the tail of the EP. Conversely, no significant changes were observed in relative testis weight, daily sperm production, spermatogenesis, seminiferous epithelial height in stage VII, and sperm morphology. All of the above parameters in the 1.6- μ g group (except seminal vesicle weight) and 320-ng group were comparable to those of controls. Plasma testosterone (T) level was reduced to an almost undetectable level in the ≥ 8 - μ g groups and to a very low level in the 1.6- μ g group (0.35 vs. 2.36 ng/ml in controls or 320-ng group), but LH level was unaltered. In a parallel fertility study, males received DES at a rate of 40, 8, or 1.6 μ g rat⁻¹ day⁻¹ for 12 days prior to and 12 days during cohabitation (1:1) with untreated females. Of the 15 females cohabited with treated males (5 females/dose), none in the 40- μ g and 8- μ g groups and 1 in the 1.6- μ g group formed a copulatory plug and delivered 8 pups, in contrast to 5/5 copulatory plugs and 13–15 pups/litter in the controls. DES at a rate of 8 μ g rat⁻¹ day⁻¹ for 12 days reduced EP weights, sperm numbers in the EP, and sperm motility patterns but caused minimal to no alterations in daily sperm production, spermatogenesis, or sperm morphology. Factors other than T, or in addition to lower T, may be responsible for DES-induced reproductive disorders (despite lower T, sperm contents and sperm motility patterns in the EP were normal in the 1.6- μ g group). Deficits in EP sperm functions and/or sexual behavior (as evident from absence of copulatory plugs) probably accounted for reduced fertility in treated males.

epididymis, estradiol, male reproductive tract, sperm, sperm motility and transport, testis

¹This work was supported by NIH grants MBRS-5-S06-GM-08091 (to H.O.G.) and RCMI-5-G12RR03059 and by USDA grant CSR-EES-ALX-TU-CTIF.

²Correspondence: H.O. Goyal, Department of Biomedical Sciences, School of Veterinary Medicine, Tuskegee University, Tuskegee, AL 36088. FAX: 334 727 8177; e-mail: goyalho@acd.tusk.edu

Received: 19 September 2000.

First decision: 3 October 2000.

Accepted: 6 November 2000.

© 2001 by the Society for the Study of Reproduction, Inc.

ISSN: 0006-3363. <http://www.bioreprod.org>

INTRODUCTION

Testicular sperm in all mammalian species studied to date are immature, but they acquire the potential to move in a forward direction during their 10- to 12-day sojourn through the excurrent ducts, including the efferent ductules and the head, body, and tail regions of the epididymis (EP) [1, 2]. The maturation of sperm requires a specific luminal environment, which in turn is created and maintained by testosterone (T)-dependent absorptive and secretory activities of the epithelium lining the excurrent ducts [3, 4]. The maintenance of those activities in the head of the EP, the primary site of sperm maturation, is absolutely dependent not only on T but also on other components of testicular fluid [5, 6]. One important component is estrogen [7], but its role in sperm maturation remains unclear [8].

If estrogens have an influence on sperm maturation, male excurrent ducts must possess estrogen receptors (ER). Recently, a number of studies using immunocytochemistry, Northern blotting, and/or in situ hybridization have demonstrated a variable concentration of ER protein and/or ER mRNA throughout the length of the excurrent ducts in several species, including rats [9–14], mice [15–20], monkeys [9, 21–23], goats [24], humans [25, 26], and roosters [27]. Infertility observed in ER alpha knockout mice [8] and aromatase knockout mice [28, 29] reinforces the significance of estrogens in male reproduction. It is hypothesized that estrogens are involved in the regulation of fluid transport in the male excurrent ducts, especially at the level of the efferent ductules and the head of the EP, and that a disturbance in this regulation is the cause for infertility seen in mutant mice lacking ER alpha [30].

The long-term goal of this study is to understand the mechanism of estrogen action in male reproductive organs, especially in EP-mediated sperm maturation. To achieve this goal, it would be ideal to develop an estrogen-treated adult animal model with altered epididymal and sperm functions but with minimal to no alteration in sperm production and/or spermatogenesis. Because estrogen and/or its agonists have been shown to affect sperm numbers and sperm motility/fertility in the EP [31–33], we tested various dose regimens of diethylstilbestrol (DES) in adult male rats to identify a minimal dose level that alters epididymal and sperm functions but has minimal to no effects on sperm production in a 12-day period of treatment. This period was selected because it closely corresponds to the duration of one cycle of seminiferous epithelium and to the sperm transit time from the testis to the tail of the EP [34]. Hence, this period of treatment will minimize the possibility of any toxicity on testicular sperm confounding the effects on sperm in the tail of the EP.

MATERIALS AND METHODS

Animals and Treatments

A total of 60 male and 20 female Sprague-Dawley rats (Harlan Sprague Dawley, Indianapolis, IN), approximately 70–80 days of age, were maintained under controlled conditions at 22–23°C ambient temperature, 55%–60% relative humidity, and 12L:12D cycle, were supplied with water and food (Rodent Chow 5001; Purina Mills, St. Louis, MO) ad libitum, and were acclimatized for 5 days prior to the beginning of the treatment. All animal procedures were approved by the Institutional Animal Care and Use Committee at Tuskegee University.

Because the objective of the study was to identify a minimal dose level of an estrogenic compound that alters epididymal and sperm functions but has minimal to no effect on sperm production and/or spermatogenesis in a 12-day period of treatment, a broad range of DES dose regimens, from 1 mg to 320 ng, was used. Five male rats each in six groups received a daily s.c. injection of DES (Sigma Chemical Co., St. Louis, MO) for 12 days at a dose of 1 mg, 200 µg, 40 µg, 8 µg, 1.6 µg, or 320 ng, respectively, in 0.2 ml of corn oil. The control group received corn oil only. Animals were necropsied on the 12th day.

The second study evaluated the effects of DES on fertility using three dose regimens (40, 8, and 1.6 µg), which were selected because DES effects on various testicular and epididymal parameters were similar between the 8-µg group and the higher dose groups and between the 1.6-µg and 320-ng groups. The protocol for drug administration was the same except that male rats received DES for 12 days prior to and for 12 days during cohabitation (1:1) with untreated females. The control group received corn oil only. The presence of a copulatory plug and the number of pups born per litter were used as fertility indices. Neither male nor female rats of this study were necropsied.

Body and Organ Weights

The initial body weight on the first day and the final body weight on the terminal day (prior to necropsy) of the experiment were used to calculate individual body weight gain/loss over the 12-day period of treatment. The weights of the testis, head and body of the EP, tail of the EP, and seminal vesicle of both sides were recorded for each animal, and relative weights (weight of the organ/100 g body weight) were calculated. Testes and EPs were trimmed of fat prior to recording their weights. After weighing, testis and EP of the right side were processed for histopathology, and those from the left side were frozen at –80°C until thawed for sperm counts.

Sperm Motility Parameters

Sperm were collected from the right tail of the EP, near its junction with the ductus deferens [35], in 2 ml of M-199 medium (Life Technologies Inc., Gaithersburg, MD) with 5 mg/ml BSA. After 10 min of diffusion, sperm were loaded into a cannula (50 mm × 2 mm × 100 µl; Vitrocom, Mountain Lake, NJ), and images of sperm movements were stored on optical disks with a phase contrast microscope. Using a computer-assisted semen analysis system (Integrated Visual Optical Systems, Hamilton Thorn Research, Beverly, MA), 200 sperm from each animal were analyzed for the following motion parameters: percentage of motile sperm, percentage of progressively motile sperm, average path velocity, straight line velocity, curvilinear velocity, lat-

eral head displacement, straightness ([straight line velocity/average path velocity] × 100), and linearity ([straight line velocity/curvilinear velocity] × 100). Prior to recordings of sperm motility parameters, the instrument was optimized, and the analysis was done using the following settings: frame rate, 60 Hz; frames acquired, 30; minimum cell size, 7 pixels; minimum contrast, 15; and brightness, 2631. Sperm were considered motile if average path velocity exceeded 20 µm/sec and considered progressively motile if average path velocity exceeded 100 µm/sec. All procedures were performed at 37°C, and all equipment that came in contact with sperm were prewarmed to and maintained at 37°C.

Sperm Morphology

An aliquot of sperm suspension (50 µl) used for motility analysis was further diluted in 0.5 ml of M-199 medium containing 10 µl of concentrated (37%) formalin. A 10-µl drop of the diluted formalized sperm sample was placed on a glass slide, coverslipped, and examined with a phase contrast microscope (400× total magnification). Two hundred sperm from each animal were evaluated and classified as follows: normal, head defect, middle piece defect, principal piece defect, proximal droplet, distal droplet, and detached head. In sperm with two or more defects, only the defect affecting its more proximal region was recorded (e.g., in sperm with both head and middle piece defects, only the head defect was recorded).

Daily Sperm Production

After thawing the left testis, the capsule was detached and weighed, and the parenchyma was homogenized for 2 min in 50 ml of PBS using a Waring laboratory blender (Fisher Scientific, Pittsburgh, PA) that was set at low speed. The homogenate was filtered through a metal sieve to remove connective tissue, and the filtrate was used to count the number of homogenization-resistant spermatids/sperm in each sample in duplicate using a hemocytometer. Daily sperm production was calculated by dividing the total number of spermatids or sperm per gram of testicular parenchyma (testis weight minus weight of the capsule) by 6.1 days, the duration of step 19 spermatids in the seminiferous epithelial cycle [36].

Epididymal Sperm Number

The total number of homogenization-resistant sperm in the head and body and in the tail of the EP was determined using a hemocytometer as described above for the testis.

Hormonal Measurement

One blood sample was collected from the heart of each animal prior to necropsy, and plasma was frozen at –20°C until assayed. LH was measured using materials obtained through NHPP, NIDDK, and Dr. A.F. Parlow (antibody: NIDDK-anti-rLH-S-11; reference standard: NIDDK-rLH-RP-3; tracer: NIDDK-rLH-I-10). The sensitivity of the assay was calculated as 0.006 ng. T was measured using a COAT-A-COUNT T radioimmunoassay (Diagnostic Products Corporation, Los Angeles, CA) according to manufacturer's protocol. The sensitivity of the assay was calculated as 0.002 ng.

TABLE 1. Mean (\pm SEM) body weight (BW) change and paired absolute and relative weight (mg) of organs^a in rats treated with DES for 12 days.

DES	BW change (g)	Testis		EP head and body		EP tail		Seminal vesicle	
		Absolute	Relative	Absolute	Relative	Absolute	Relative	Absolute	Relative
Control	29 \pm 5	3379 \pm 55	1022 \pm 23	589 \pm 10	178 \pm 3	397 \pm 16	120 \pm 6	1069 \pm 45	325 \pm 18
320 ng	28 \pm 2	3343 \pm 106	1036 \pm 32	590 \pm 13	182 \pm 3	372 \pm 30	115 \pm 9	1020 \pm 63	316 \pm 18
1.6 μ g	-10 \pm 4 ^b	3161 \pm 57	1123 \pm 26	547 \pm 14	194 \pm 6	332 \pm 15 ^b	117 \pm 4	467 \pm 68 ^b	164 \pm 22 ^b
8 μ g	-22 \pm 5 ^b	2585 \pm 83 ^b	1001 \pm 39	304 \pm 35 ^b	117 \pm 12 ^b	205 \pm 17 ^b	79 \pm 6 ^b	282 \pm 19 ^b	108 \pm 5 ^b
40 μ g	-36 \pm 4 ^b	2540 \pm 98 ^b	929 \pm 24	287 \pm 14 ^b	105 \pm 4 ^b	164 \pm 11 ^b	60 \pm 3 ^b	223 \pm 6 ^b	81 \pm 5 ^b
200 μ g	-39 \pm 4 ^b	2296 \pm 83 ^b	857 \pm 27 ^b	244 \pm 7 ^b	91 \pm 3 ^b	155 \pm 5 ^b	58 \pm 2 ^b	215 \pm 12 ^b	80 \pm 4 ^b
1 mg	-37 \pm 4 ^b	2532 \pm 74 ^b	947 \pm 28	277 \pm 16 ^b	103 \pm 6 ^b	174 \pm 6 ^b	65 \pm 2 ^b	253 \pm 10 ^b	94 \pm 3 ^b

^a Because organ weights between left and right sides did not differ significantly ($P \geq 0.05$), they were combined.

^b Significantly different from control ($P \leq 0.05$).

Histopathology of the Testis

Three- to five-millimeter-thick slices of tissue from the middle of the right testis were fixed for 16–24 h in Bouin's fluid. Tissue samples were embedded in paraffin, cut at 5 μ m thickness, stained with periodic acid-Schiff, counterstained with hematoxylin, and examined with a light microscope. Twenty cross-sections of stage VII–VIII seminiferous tubules from each animal were analyzed for tubular diameter (basal lamina to basal lamina), epithelial height (basal lamina to neck of elongated spermatids), and luminal diameter using a computer-assisted image analysis system.

Statistics

Statistical analyses were performed using Sigma Stat statistical software (Jandel Scientific, Chicago, IL). One-way analyses of variance were utilized on all parameters. Treatment groups with means significantly different from controls ($P \leq 0.05$) were identified using Dunnett test. When data were not distributed normally, analyses were performed on ranked data, and differences from controls were identified by Dunn test.

RESULTS

Effects of DES on most, if not all, reproductive endpoints studied were essentially similar in the 8- μ g group and higher dose groups ($\geq 8 \mu$ g); therefore, results from these animals are described together unless indicated otherwise.

Body Weight

All animals in the $\geq 8\text{-}\mu\text{g}$ dose groups and four of five animals in the 1.6- μg group lost weight. The mean weight loss was 3% of their initial body weight in the 1.6- μg group, in contrast to 8%–12% in the $\geq 8\text{-}\mu\text{g}$ groups. Conversely, animals in the control and 320-ng groups increased weight by 10% of their initial body weight (Table 1).

Weights of Reproductive Organs

The absolute weight of all reproductive organs, including the testis, head and body of the EP, tail of the EP, and seminal vesicle, was significantly lower than that in controls in the $\geq 8\text{-}\mu\text{g}$ groups. However, this decrease was much more pronounced in the seminal vesicle (75%–80%) and both regions of the EP (46%–60%) than in the testis (25%–30%). The decrease in testis weight was not significant (except in the 200- μg group) when its weight was expressed as a relative weight (organ weight/100 g body weight). Neither absolute nor relative weight of the above reproductive organs in the 1.6- μg group (except absolute and relative weights of the

seminal vesicle and absolute weight of the tail of the EP) and the 320-ng dose group were significantly different from those of controls (Table 1).

Number of Sperm in the Testis and EP

The number of spermatids or sperm per testis and the daily sperm production per gram of testicular parenchyma

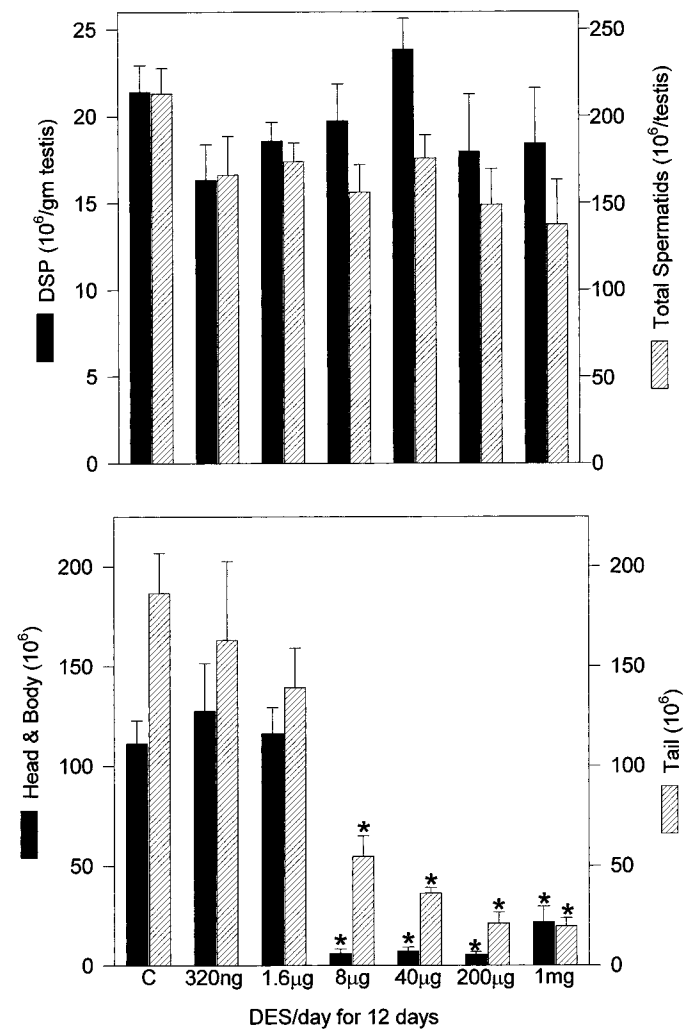


FIG. 1. Number of homogenization-resistant sperm in the testis and EP of DES-treated male rats. Although total number of spermatids or sperm per testis or the daily sperm production (DSP) per gram of testis (upper panel) in treated animals is not significantly different from controls, numbers of sperm in the head and body or the tail of the EP (lower panel) are markedly decreased in the $\geq 8\text{-}\mu\text{g}$ groups. Data are expressed as mean \pm SEM. Asterisks indicate significant differences ($P \leq 0.05$) from controls (C).

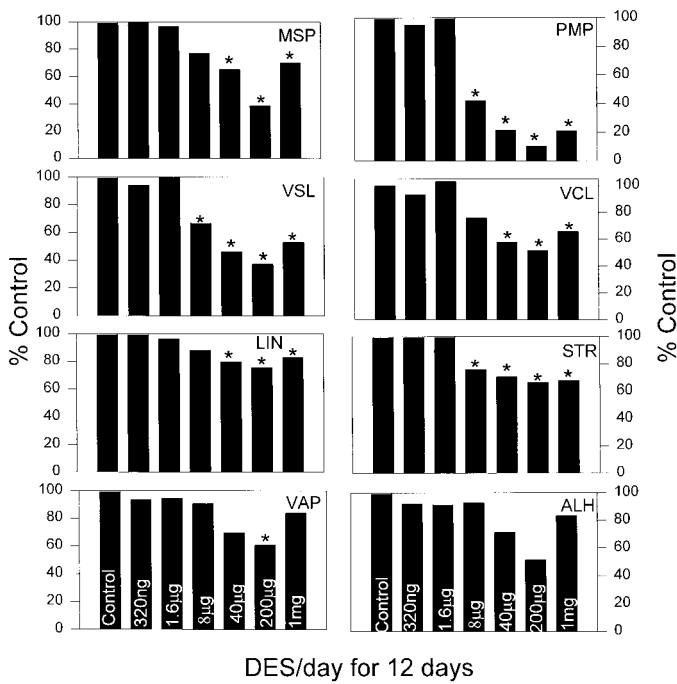


FIG. 2. Kinematic parameters of sperm from the tail of the epididymis in male rats treated with DES. MSP, Percentage of motile sperm; PMP, percentage of progressively motile sperm; VSL, straight line velocity; VCL, curvilinear velocity; LIN, linearity; STR, straightness; VAP, average path velocity; ALH, lateral head displacement. Data are expressed as percentage of controls. Asterisks indicate significant differences ($P \leq 0.05$) from controls.

in any treatment group were not significantly different ($P \leq 0.05$) from that of controls (Fig. 1). Conversely, the number of sperm in the EP was reduced to $\leq 20\%$ of controls in the head and body and to $\leq 30\%$ of controls in the tail in the $\geq 8\text{-}\mu\text{g}$ groups. No significant reduction in sperm numbers ($P \leq 0.05$) was observed in either region of the EP in the 1.6- μg and 320-ng groups (Fig. 1).

Computer-Assisted Sperm Motility Analysis

Of all motility parameters studied, the percentage of progressively motile sperm, straight line velocity ($\mu\text{m}/\text{sec}$), and straightness (%) significantly decreased in the $\geq 8\text{-}\mu\text{g}$ groups, and percentage of motile sperm, curvilinear velocity ($\mu\text{m}/\text{sec}$), and linearity (%) significantly decreased in the $\geq 40\text{-}\mu\text{g}$ groups. However, none of these parameters were altered in the 1.6- μg and 320-ng groups (Fig. 2). Both average path velocity ($\mu\text{m}/\text{sec}$) and lateral head displacement (μm) did not significantly differ from controls in any of the treated groups (except average path velocity for the 200- μg group). Among the affected parameters, the per-

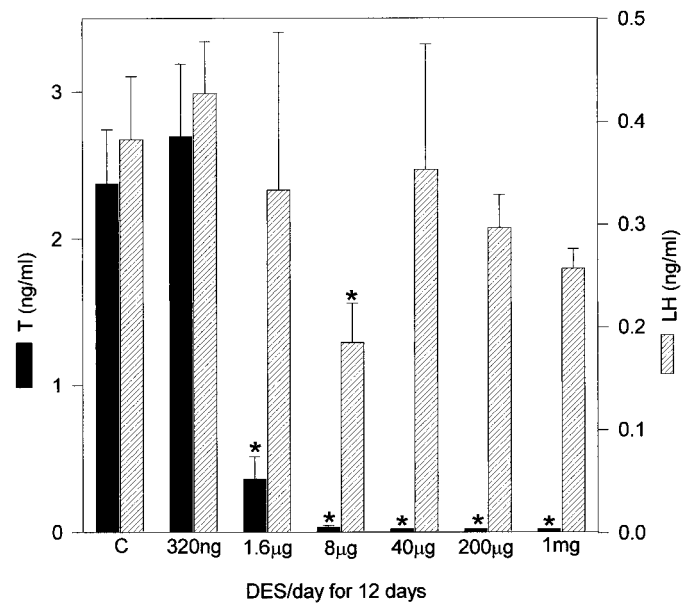


FIG. 3. Plasma concentration of T and LH in male rats treated with DES. Data are expressed as mean \pm SEM. Asterisks indicate significant differences ($P \leq 0.05$) from controls (C).

centage of sperm with progressive motility was the most sensitive parameter. This value was reduced to $\leq 20\%$ that of controls in the $\geq 40\text{-}\mu\text{g}$ groups and to 42% of controls in the 8- μg group.

Sperm Morphology

The mean percentage of normal sperm ranged from 80% to 94% in all treatment groups, and it did not differ significantly among treatments or between any treatment and the control. Furthermore, none of the sperm abnormalities, including misshapen head, middle piece, or principal piece and retention of proximal or distal protoplasmic droplet, was more frequently encountered as a result of DES treatment (Table 2).

Hormones

The mean plasma T concentration was similar in the 320-ng and control groups (2.3–2.6 ng/ml), but it was very low in the 1.6- μg group (0.36 ng/ml) and barely detectable in the $\geq 8\text{-}\mu\text{g}$ groups. However, mean LH concentration in treated groups (except in the 8- μg group) did not significantly differ ($P \leq 0.05$) from that of controls (0.18–0.42 ng/ml) (Fig. 3).

TABLE 2. Effect (mean \pm SEM%) of DES on sperm morphology in rats treated with DES for 12 days.

DES	Normal (%)	Defect (%)					
		Head	Midpiece	Principal piece	Proximal droplet	Distal droplet	Detached head
Control	84.4 \pm 3.1	10.3 \pm 2.9	0.6 \pm 0.2	0.4 \pm 0.2	0.2 \pm 0.1	4.0 \pm 0.8	0.1 \pm 0.1
320 ng	94.2 \pm 0.8	2.6 \pm 0.7	0.6 \pm 0.4	0.0 \pm 0.0	0.0 \pm 0.0	2.2 \pm 0.4	0.0 \pm 0.0
1.6 μg	86.2 \pm 2.6	8.2 \pm 2.0	1.0 \pm 0.3	0.6 \pm 0.2	0.0 \pm 0.0	3.2 \pm 1.7	1.0 \pm 0.5
8 μg	84.5 \pm 4.0	8.3 \pm 2.0	2.2 \pm 1.2	1.2 \pm 0.5	0.2 \pm 0.2	2.3 \pm 0.7	1.3 \pm 0.5*
40 μg	82.6 \pm 1.2	13.0 \pm 2.1	1.0 \pm 0.3	0.6 \pm 0.2	0.0 \pm 0.0	2.8 \pm 1.0	0.0 \pm 0.0
200 μg	80.6 \pm 2.8	15.0 \pm 2.1	2.2 \pm 0.6	0.8 \pm 0.6	0.0 \pm 0.0	1.4 \pm 0.5	0.0 \pm 0.0
1 mg	84.3 \pm 1.9	12.0 \pm 1.2	2.2 \pm 1.0	0.8 \pm 0.4	0.0 \pm 0.0	0.7 \pm 0.3	0.0 \pm 0.0

* Significantly different from control ($P \leq 0.05$).

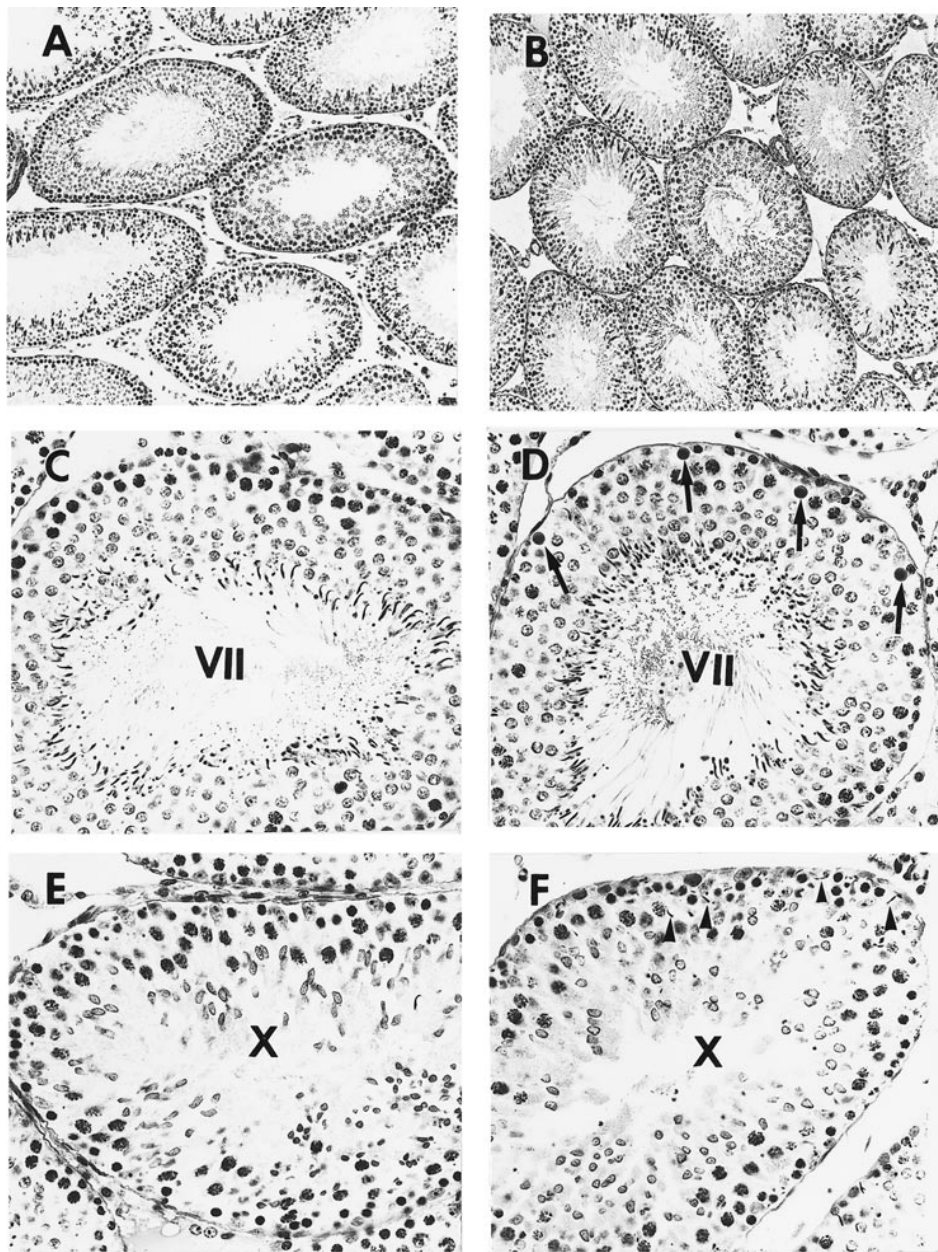


FIG. 4. Testicular morphology. **A, B** In these low power micrographs of the testis from a control rat (**A**) and a rat treated with DES at a rate of 1 mg/day/rat/12 days (**B**), the morphology of seminiferous tubules and intertubular tissue is essentially similar. $\times 90$. **C–F** High-power photomicrographs of seminiferous tubules in stages VII and X from control rats (**C, E**) and DES-treated rats at a rate of $8 \mu\text{g rat}^{-1} \text{ day}^{-1}$ for 12 days (**D, F**). Note the presence of degenerating spermatocytes in a stage VII tubule (arrows) and retention of elongate spermatids in a stage X tubule (arrowheads) in treated animals. $\times 295$.

Histopathology of the Testis

A histological examination of the testis, including seminiferous tubules and Leydig cells, did not reveal any morphological differences from controls in the 1.6- μg and 320-ng groups. However, minor histological changes were observed in some seminiferous tubules in a non-dose-dependent manner in animals treated with 8 μg and higher doses of DES. These changes included the presence of a few degenerating primary spermatocytes, characterized by round and heterochromatic nuclei, per tubular cross-section in stage VII and the retention of elongated spermatids near the basal lamina in stages X–XII (Fig. 4). Leydig cells in these animals appeared fewer in number and smaller in size, which probably resulted from a reduction in the cytoplasm.

Mean measurements for the tubular diameter, height of the seminiferous epithelium, and luminal diameter did not significantly differ among treatments or between any treatment and the control (Fig. 5).

Fertility

Fertility was evaluated in the 40-, 8-, and 1.6- μg dose groups, and the numbers of copulatory plugs and live pups were used as fertility indices. None of the females that cohabited with males in the 40- and 8- μg groups had a plug or produced a pup. Only one of five females in the 1.6- μg group had a plug, and this female gave birth to eight pups. In contrast, plugs were present in five of five control fe-

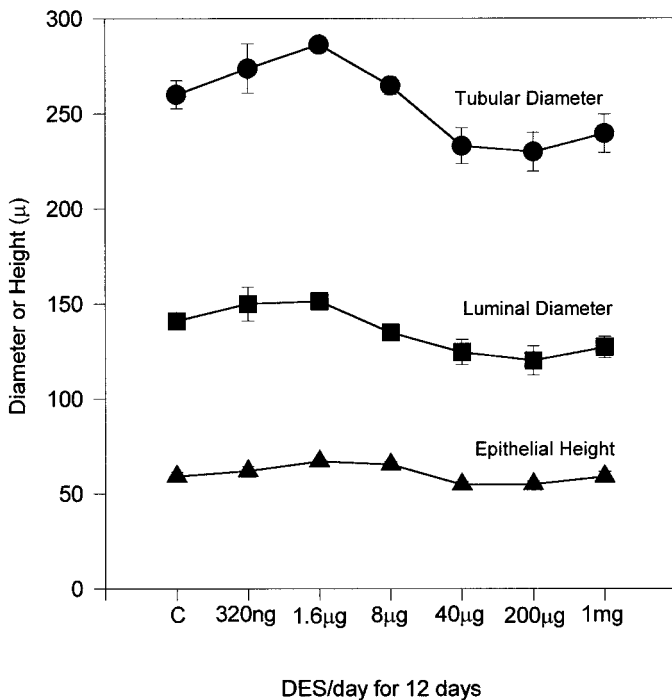


FIG. 5. Tubular diameter, luminal diameter, and epithelial height of stages VII and VIII seminiferous tubules in male rats treated with DES. Data are expressed as mean \pm SEM. None of the parameters in any treated group were significantly different ($P \leq 0.05$) from controls (C).

males, and four of these females delivered 13–15 pups each.

DISCUSSION

In the present study, we used six dose regimens of DES to characterize estrogenic effects in adult male rats on the following reproductive endpoints: 1) weights of reproductive organs, 2) numbers of spermatids or sperm in the testis and EP, 3) motility and morphology of sperm collected from the tail of the EP, 4) reproductive hormones, 5) histopathology of the testis, and 6) fertility. Results revealed that DES treatment at the rate of $\geq 8 \mu\text{g day}^{-1}$ animal $^{-1}$ for 12 days caused significant reductions in epididymal sperm numbers and sperm motion parameters but did not affect daily sperm production or sperm morphology.

Exposure to DES significantly reduced absolute weights of all reproductive organs, including the testis, head and body of the EP, tail of the EP, and seminal vesicle, in the $\geq 8\text{-}\mu\text{g}$ groups, but no significant differences from controls were seen in the 1.6- μg (except seminal vesicle and tail of the EP) and 320-ng groups. However, when organ weights were expressed as relative weights, the decrease in weight of the testis in the 8- μg , 40- μg , and 1-mg groups and of the tail of the EP in the 1.6- μg group was not significant. Similar to testis weight, daily sperm production per gram of testicular parenchyma was not affected by any treatment. Conversely, the numbers of sperm in the EP were reduced to $\leq 20\%$ of controls in the head and body and to $\leq 30\%$ of controls in the tail in the $\geq 8\text{-}\mu\text{g}$ groups but were not altered in the 1.6- μg and 320-ng groups. These results indicate a differential response between the testis and the EP to DES exposure. Whereas daily sperm production and relative testis weight were unaffected by a DES dose that was as high as 1 mg rat $^{-1}$ day $^{-1}$ for 12 days, epididymal weights

and sperm contents were significantly reduced by a dose that was as low as 8 $\mu\text{g rat}^{-1}$ day $^{-1}$ for 12 days.

Similar differential responses to estrogen exposure have been reported previously. Daily i.m. injection of 10 μg of estradiol benzoate for 39–50 days in adult mice did not affect sperm contents of the testis but reduced those of the head and body and the tail of the EP to approximately 12% and 21% of controls, respectively [31]. Although both sperm content and the weight of the tail of the EP in adult rats implanted with 3-mm and 7-mm estradiol-filled capsules (release rate, 0.24 $\mu\text{g mm}^{-1}$ day $^{-1}$) for 18 wk were significantly lower than those of controls, both parameters were unaffected in the testis [32]. In adult rats treated orally with ethinyl estradiol at a daily dose of 1 mg/kg or 10 mg/kg, sperm numbers in the tail of the EP were reduced to almost 50% that of controls after 1 wk of administration, whereas those in the testis were not affected [33]. F₁ rats sired from P₁ rats treated with ≥ 2.5 ppm 17 β -estradiol in the diet for 90 days had significantly lower epididymal weight and sperm numbers, whereas no significant decrease was noted in testis weight or testicular spermatid numbers [37]. These epididymal effects, according to the authors, may have resulted from an in utero exposure to 17 β -estradiol.

As with sperm numbers in the EP, most motility parameters of sperm collected from the tail of the EP were severely affected in the $\geq 8\text{-}\mu\text{g}$ groups but were unaltered in the 1.6- μg and 320-ng groups. A precipitous decline in progressive forward motility and a significant decline in straight line velocity, curvilinear velocity, straightness, and linearity indicated that DES treatment severely affected not only the ability of sperm to move in a forward direction but also affected their vigor. Unlike sperm motility, sperm morphology, in terms of percentage of normal sperm, did not differ from that of controls in any of the treated group. Although few studies have examined effects of estradiol on sperm motility and/or morphology, the percentage of motile sperm was significantly reduced in rats treated with ethinyl estradiol after 1 wk of treatment at 10 mg/kg body weight and after 2 wk of treatment at 1 mg/kg body weight [33]. An increased incidence of decapitated sperm was reported after estradiol administration to adult rats [38, 39]. Reasons for differences in sperm morphology between our results and those of these other authors may be related to the nature of the compound and the length, dose, and/or route of treatment.

The most interesting finding of the present study was that DES-induced alterations in epididymal sperm contents and sperm motility occurred in the absence of an alteration in sperm production and sperm morphology. The question that remains to be answered is "What mediates these selective reproductive disorders?" It is tempting to speculate that they resulted from a lower concentration of T, which was almost undetectable in the $\geq 8\text{-}\mu\text{g}$ groups. Both castration and hypophysectomy alter motility and fertility in epididymal sperm [40]. Lower T is believed to accelerate sperm transport [41] and thus can explain the reduced number of sperm in the EP.

However, results for the 1.6- μg group do not support lower T as the only or even a major factor in inducing the epididymal and sperm disorders. In this group, although the T level was only one-sixth that of controls (0.36 vs. 2.37 ng/ml), neither epididymal sperm contents nor sperm motility parameters were affected. Similarly, rats treated with 10 mg/kg ethinyl estradiol for 3 and 5 days had an undetectable level of T, but sperm concentration in the tail of

the EP was not affected [33]. A very high dose of T substitution (80 $\mu\text{g}/\text{day}$) somewhat improved estradiol-induced reduction in epididymal sperm numbers, but these numbers were still only one-third those of controls [31]. These functional disorders in the EP may have resulted from an imbalance between estrogen and T, because receptors for both hormones in androgen-deprived EP declined and then were restored to a normal level with T treatment [42].

The decrease in epididymal sperm content can also result from 1) reduced production of sperm in the testis, 2) blockage in the excurrent ducts, 3) phagocytosis of sperm in the excurrent ducts, and 4) retention of sperm/spermatids in the seminiferous epithelium. The first possibility is unlikely because the daily rate of sperm production did not decline in any treated group. A histological examination of the excurrent ducts, from the rete testis to the ductus deferens, did not reveal any evidence of spermiostasis in the lumen or extravasation of sperm in the connective tissue nor did it provide any evidence of sperm phagocytosis in the epithelium (data not shown). A retention of spermatids was observed in stages X–XII; but the numbers of retained spermatids were so few that they cannot possibly account for the level of sperm decline ($\geq 70\%$) seen in the EP. In addition to retained spermatids, a few degenerating primary spermatocytes were seen in stage VII. Both of these seminiferous epithelial responses seem to be typical for estrogen exposure [33, 37, 43] and are probably caused by reduced T [44, 45]. In this context, lower T level seen in animals of this study probably resulted from an effect of DES directly on Leydig cells, because LH level was unaltered.

The final reproductive endpoint that was tested was the male's ability to sire offspring in a fixed time period. Of the females that cohabited with males, none in the 40- μg and 8- μg groups and only one in the 1.6- μg group had a copulatory plug and delivered pups, clearly suggesting that DES treatment for 24 days (12 days before and 12 days during cohabitation) at a dose rate as low as 1.6 μg was effective in reducing male fertility by at least 80%. Similarly, all female mice paired with nine male mice that were given 10 $\mu\text{g}/\text{day}$ estradiol benzoate for 28 days before and during cohabitation failed to get pregnant [31]. Male rats treated orally with ethinyl estradiol at a daily dose of 10 mg/kg did not impregnate any female after 2 wk of treatment [33]. A decline in fertility and a decrease in the number of seminal plugs were observed, in a dose-dependent manner, in females mated with males that received a sustained release of estradiol from 1- to 7-mm-long implants (release rate, 0.24 $\mu\text{g mm}^{-1} \text{day}^{-1}$) for 18 wk [32].

Whether reduced fertility observed in DES-treated rats resulted from lower sperm numbers, altered sperm motility, or depressed sexual desire cannot be determined from the present fertility data, which involved only two indices, copulatory plug and pups per litter. However, the absence of copulatory plugs in 14 of 15 females may indicate depressed sexual behavior in DES-treated males. Hence, additional in-depth fertility studies are needed involving observations on numbers of male sexual mounts in a given time period, presence or absence of sperm in the vagina, and numbers of corpora lutea, implantation sites, and numbers of live and dead embryos. These studies will help us determine effects of DES not only on the status of male libido but also on the fertility index ([number of implantation sites divided by number of corpora lutea] $\times 100$) and the fecundity index ([number of live pups divided by number of implantation sites] $\times 100$). In addition, artificial in-

semination using a fixed number of sperm from the tail of the EP will be an ideal method for comparing fertility between the control and DES-treated animals because it will allow assessment of sperm fertility at a given time point (for example, on the 12th day of the experiment) without confounding effects on sperm of additional treatment or no treatment (recovery) during the period of cohabitation.

In conclusion, this study provides a DES-treated animal model (8 $\mu\text{g rat}^{-1} \text{day}^{-1}$ for 12 days) with altered epididymal and sperm functions that can be used to further explore endocrine and molecular mechanisms of estrogen actions in males.

ACKNOWLEDGMENTS

The authors thank Valerie Ingram, Tajelsir Mohamed, Nicholas Chambers, and Henry Rabon for technical help.

REFERENCES

- Hinton BT, Palladino MA. Epididymal epithelium: its contribution to the formation of a luminal fluid microenvironment. *Microsc Res Tech* 1995; 30:67–81.
- Cooper TC. Interactions between epididymal secretions and spermatozoa. *J Reprod Fertil Suppl* 1998; 53:119–136.
- Orgebin-Crist MC. Androgens and epididymal function. In: Bhasin D, Gabelnick HL, Spieler JM, Swerdloff RS, Wang C (eds.), *Pharmacology, Biology, and Clinical Application of Androgens*. New York: Wiley-Liss; 1996: 27–38.
- Syntin P, Dacheux JL, Dacheux F. Postnatal development and regulation of proteins secreted in the boar epididymis. *Biol Reprod* 1999; 61:1622–1635.
- Robaire B, Hermo L. Efferent ducts, epididymis, and vas deferens: structure, functions, and their regulation. In: Knobil E, Neil J (eds.), *The Physiology of Reproduction*. New York: Raven Press; 1988: 999–1080.
- Sharpe RM. Regulation of spermatogenesis. In: Knobil E, Neil J (eds.), *The Physiology of Reproduction*, 2nd ed. New York: Raven Press; 1994: 1363–1434.
- Hess RA. Oestrogen in fluid transport in efferent ducts of the male reproductive tract. *Rev Reprod* 2000; 5:84–92.
- Eddy EM, Washburn TE, Bunch DO, Goulding EH, Gladen BC, Lubahn DB, Korach KS. Targeted disruption of estrogen receptor gene in male mice causes alteration of spermatogenesis and infertility. *Endocrinology* 1996; 137:4796–4805.
- Fisher JS, Millar MR, Majdic G, Saunders PT, Fraser HM, Sharpe RM. Immunolocalization of estrogen receptor-alpha within the testis and excurrent ducts of the rat and marmoset monkey from perinatal life to adulthood. *J Endocrinol* 1997; 153:485–495.
- Hess RA, Gist DH, Bunick D, Lubahn DB, Farrell A, Bahr J, Cooke PS, Greene GL. Estrogen receptor (α and β) expression in the excurrent ducts of the adult male rat reproductive tract. *J Androl* 1997; 18:602–611.
- Kuiper GG, Carlsson B, Grandien K, Enmark E, Haggblad J, Nilsson S, Gustafsson JA. Comparison of ligand binding specificity and transcript tissue distribution of estrogen receptor alpha and beta. *Endocrinology* 1997; 138:863–870.
- Saunders PTK, Maguire SM, Gaughan J, Millar MR. Expression of estrogen receptor beta (ER-beta) in multiple rat tissues visualized by immunohistochemistry. *J Endocrinol* 1997; 154:R13–R16.
- Saunders PTK, Fisher JS, Sharpe RM, Millar MR. Expression of estrogen receptor beta (ER-beta) occurs in multiple cell types, including some germ cells, in the rat testis. *J Endocrinol* 1998; 156:R13–R17.
- van Pelt AM, de Rooij DG, van der Burgh B, van der Saag PT, Gustafsson JA, Kuiper GG. Ontogeny of estrogen receptor-beta expression in rat testis. *Endocrinology* 1999; 140:478–483.
- Cooke PS, Young P, Hess RA, Cunha GR. Estrogen receptor expression in developing epididymis, efferent ductules, and other male reproductive organs. *Endocrinology* 1991; 128:2874–2879.
- Iguchi T, Uesugi Y, Sato T, Ohta Y, Takasugi N. Developmental pattern of estrogen receptor expression in male mouse genital organs. *Mol Androl* 1991; 3:109–119.
- Couse JF, Lindzey J, Grandien K, Gustafsson JA, Korach KS. Tissue distribution and quantitative analysis of estrogen receptor- α (ER α) and

- estrogen receptor- β (ER β) messenger ribonucleic acid in the wild-type and ER α -knockout mouse. *Endocrinology* 1997; 138:4613–4621.
18. Rosenfield CS, Ganjam VK, Taylor JA, Yuan X, Stiehr JR, Hardy MP, Lubahn DB. Transcription and translation of estrogen receptor-beta in male reproductive tract of estrogen receptor-alpha knock-out and wild-type mice. *Endocrinology* 1998; 139:2982–2987.
 19. Jefferson WN, Couse JF, Banks EP, Korach KS, Newbold RR. Expression of estrogen receptor β is developmentally regulated in reproductive tissues of male and female mice. *Biol Reprod* 2000; 62:310–317.
 20. Nielsen M, Bjornsdottir S, Hoyer PE, Byskov AG. Ontogeny of estrogen receptor α in gonads and sex ducts of fetal and newborn mice. *J Reprod Fertil* 2000; 118:195–204.
 21. West NB, Brenner RM. Estrogen receptor in the ductuli efferentes, epididymis and testis of rhesus and cynomolgus macaques. *Biol Reprod* 1990; 42:533–538.
 22. Heikinheimo O, Mahony MC, Gordon K, Hsiu JG, Hodgen GD, Gibbons WE. Estrogen and progesterone receptor mRNA are expressed in distinct pattern in male primate reproductive organs. *J Assist Reprod Genet* 1995; 12:198–204.
 23. Pau CY, Pau KYF, Spies HG. Putative estrogen receptor beta and alpha mRNA expression in male and female rhesus macaques. *Mol Cell Endocrinol* 1998; 146:58–68.
 24. Goyal HO, Bartol FF, Wiley AA, Neff CW. Immunolocalization of receptors for androgen and estrogen in male caprine reproductive tissues: unique distribution of estrogen receptors in efferent ductule epithelium. *Biol Reprod* 1997; 56:90–101.
 25. Ergun S, Ungefroren H, Holstein AF, Davidoff MS. Estrogen and progesterone receptors and estrogen receptor-related antigen (ER-D5) in human epididymis. *Mol Reprod Dev* 1997; 47:448–455.
 26. Taylor AH, Al-Azzawi F. Immunolocalisation of estrogen receptor beta in human tissues. *J Mol Endocrinol* 2000; 24:145–155.
 27. Kwon S, Hess RA, Bunick D, Kirby JD, Bahr JM. Estrogen receptors are present in the epididymis of the rooster. *J Androl* 1997; 18:378–384.
 28. Fisher CR, Graves KH, Parlow AF, Simpson ER. Characterization of mice deficient in aromatase (ARKO) because of targeted disruption of the *cyp 19* gene. *Proc Natl Acad Sci U S A* 1998; 95:6965–6970.
 29. Robertson KM, O'Donnel L, Jones MEE, Meachem SJ, Boon WC, Fisher CR, Graves KH, McLachlan RI, Simpson ER. Impairment of spermatogenesis in mice lacking a functional aromatase (*cyp 19*) gene. *Proc Natl Acad Sci U S A* 1999; 96:7986–7991.
 30. Hess RA, Bunick D, Lubahn DB, Zhou Q, Bouma J. Morphological changes in efferent ductules and epididymis in estrogen receptor alpha knockout mice. *J Androl* 2000; 21:107–121.
 31. Meistrich ML, Hughes TJ, Bruce WR. Alteration of epididymal sperm transport and maturation in mice by oestrogen and testosterone. *Nature* 1975; 258:145–147.
 32. Robaire B, Duron J, Hales BF. Effect of estradiol-filled polydimethylsiloxane subdermal implants in adult male rats on the reproductive system, fertility, and progeny outcome. *Biol Reprod* 1987; 37:327–334.
 33. Kaneto M, Kanamori S, Hishikawa A, Kishi K. Epididymal sperm motion as a parameter of male reproductive toxicity: sperm motion, fertility, and histopathology in ethinylestradiol-treated rats. *Reprod Toxicol* 1999; 13:279–289.
 34. Amann RP. Detection of alterations in testicular and epididymal function in laboratory animals. *Environ Health Perspect* 1986; 70:149–158.
 35. Slott VL, Suarez JD, Perreault SD. Rat sperm motility analysis: methodological considerations. *Reprod Toxicol* 1991; 5:449–458.
 36. Robb GW, Amann RP, Killian GJ. Daily sperm production and epididymal sperm reserves of pubertal and adult rats. *J Reprod Fertil* 1978; 54:103–107.
 37. Cook JC, Johnson L, O'Connor JC, Biegel LB, Krams CH, Frame SR, Hurtt ME. Effects of 17 β -estradiol exposure on serum hormone concentrations and testicular parameters in male Crl:CD BR rats. *Toxicol Sci* 1998; 44:155–168.
 38. Rao MV, Chinoy NJ. Effect of estradiol benzoate on reproductive organs and fertility in the male rat. *Eur J Obstet Gynecol Reprod Biol* 1983; 15:189–198.
 39. Oko R, Hrudka F. Comparison of the effects of gossypol, estradiol-17 β and testosterone compensation on male rat reproductive organs. *Biol Reprod* 1984; 30:1198–1207.
 40. Dyson ALMB, Orgebin-Crist MC. Effects of hypophysectomy, castration and androgen replacement upon the fertilizing ability of rat epididymal spermatozoa. *Endocrinology* 1973; 93:391–402.
 41. Sujarit S, Pholpramool C. Enhancement of sperm transport through the rat epididymis after castration. *J Reprod Fertil* 1985; 74:497–502.
 42. Goyal HO, Bartol FF, Wiley AA, Khalil MK, Williams CS, Vig MM. Regulation of androgen and estrogen receptors in male excurrent ducts of the goat: an immunohistochemical study. *Anat Rec* 1998; 250:164–171.
 43. O'Connor JC, Frame SR, Biegel LB, Cook JC, Davis LG. Sensitivity of a tier 1 screening battery compared to an in utero exposure for detecting the estrogen receptor agonist 17 β -estradiol. *Toxicol Sci* 1998; 44:169–184.
 44. Bartlett JM, Kerr JB, Sharpe RM. The effect of selective destruction and regulation of rat Leydig cells on the intratesticular distribution of testosterone and morphology of the seminiferous epithelium. *J Androl* 1986; 7:240–253.
 45. Kerr JB, Millar M, Maddocks S, Sharpe RM. Stage dependent changes in spermatogenesis and Sertoli cells in relation to the onset of spermatogenic failure following withdrawal of testosterone. *Anat Rec* 1993; 235:547–559.