

Clinical Assessment of Absence of the Palmaris Longus and its Association With Other Anatomical Anomalies – A Chinese Population Study

Sandeep J Sebastin,¹*MCh (Plastic)*, Aymeric YT Lim,¹*FRCS (Glas)*, Hwee-Bee Wong,²*MSc*

Abstract

Introduction: Ethnic variations in the prevalence of absence of the palmaris longus (PL) are well known. Many techniques for clinically determining the presence of the PL have been described. Studies have also attempted to correlate its absence with other anatomical anomalies. However, most studies have been done in Caucasian populations. **Materials and Methods:** The presence of the PL was clinically determined in 329 normal Chinese men and women using the standard technique. In subjects with an absent PL, 4 other tests were performed to confirm absence and an Allen's test was done to assess the palmar arches. All subjects were examined for the presence of the flexor digitorum superficialis (FDS) to the little finger. **Results:** The overall prevalence of absence of the PL was 4.6%. All techniques were equally effective in determining the absence of the PL. There was no significant difference in its absence with regard to the body side or sex. Absolute deficiency of FDS to the little finger was seen in 6.4%. No correlation could be detected between the absence of the PL and FDS of the little finger. **Conclusions:** The prevalence of absence of the PL and absence of FDS to the little finger in a Chinese population is much lower compared to previous reports in the literature. There is no association between absence of the PL and absence of the FDS to the little finger. Although all techniques of examining for the absence of the PL are equally effective, the method suggested by Mishra seems the best as it was easily understood by subjects and can be used even when thumb abduction is not possible.

Ann Acad Med Singapore 2006;35:249-53

Key words: Chinese, Palmaris longus, Tendon anomalies

Introduction

The prevalence of absence of the palmaris longus (PL) has been extensively studied following the first report of its absence in 1559 by Colombos in *De Re Anatomica Libri*.¹⁻⁹ It is well known that there is a wide variation in the reported prevalence of PL absence in different ethnic groups.^{4,6} However, only one report has documented the prevalence of its absence in a Chinese population.⁶

Some authors suggest that apart from its ethnic variations, its absence is more common in women, bilateral absence is more common, and that unilateral absence occurs more frequently on the left side.^{3,5} Others have attempted to correlate the absence of the PL with other anatomical anomalies, like an anomalous superficial palmar arch, an absence of the plantaris, etc.^{2,10-14} A clinical study has even

attempted to explore the relationship between the functional absence of the flexor digitorum superficialis (FDS) to the little finger and the absence of the PL.¹⁵ Most papers attempting to correlate the relationship of the PL with other anatomic structures have been carried out in Caucasian subjects (or cadavers). Many techniques for clinically determining the presence of the PL have been described in the literature.^{3,4,16,17}

In this study, we examined 329 people of Chinese descent (658 upper limbs) to address the above issues and see if they applied to a Chinese population. We studied the prevalence of absence and correlated it with other anatomic variations. In subjects with an absent PL, we reconfirmed the absence using 4 additional clinical tests and determined the best technique to assess absence of the PL.

¹ Department of Hand and Reconstructive Microsurgery
National University Hospital, Singapore

² Clinical Trials and Epidemiology Research Unit, Singapore

Address for Reprints: Dr Aymeric Lim, Department of Hand and Reconstructive Microsurgery, Level III, Main Building, National University Hospital, 5 Lower Kent Ridge Road, Singapore 119074.

Email: aymericlim@nuh.com.sg

Materials and Methods

A sample of the normal population was taken from subjects at a health screening programme. The sample population included 418 subjects (78% Chinese, 10% Malays, 9% Indians and 3% other races). Of these 418 subjects, only the 329 Chinese men and women were included in this study. Individuals with a history of injury, disease or abnormality of the upper limb, which would preclude examination for the presence of the PL tendon and the FDS to the little finger or the implementation of an Allen's test, were excluded from the study. The examination was carried out in 3 parts.

The first part of the examination assessed the presence of the PL. The presence or absence of the PL tendon was recorded on both sides. The subject was initially asked to do the standard test for the assessment of the PL tendon. If the tendon was not visualised or palpable, 4 additional tests were done to confirm the absence.

1. Standard test (Schaeffer's test):³ The subject is asked to oppose the thumb to the little finger and then flex the wrist (Fig. 1).
2. Thompson's test:⁴ The subject is asked to make a fist, then flex the wrist and finally the thumb is opposed and flexed over the fingers (Fig. 2).
3. Mishra's test I:¹⁶ The metacarpo-phalangeal joints of all fingers are passively hyperextended by the examiner and the subject is asked to actively flex the wrist (Fig. 3).
4. Mishra's test II:¹⁶ The subject is asked to abduct the thumb against resistance with the wrist in slight palmar flexion (Fig. 4).
5. Pushpakumar's "two-finger sign" method:¹⁷ The subject is asked to fully extend the index and middle finger, the wrist and other fingers are flexed and finally the thumb is fully opposed and flexed (Fig. 5).

The second part of the examination assessed the functional ability of the superficialis tendon to flex the proximal interphalangeal joint (PIPJ) of little finger. First, full and free range of motion of the PIPJ of both little fingers was confirmed. FDS function in the little finger was assessed by standard and modified tests and divided into independent, common and absent function.^{15,18,19} Independent function was defined as the ability to flex the PIPJ of the little finger $>90^\circ$ with the PIPJ of the other fingers extended, while common function was defined as the ability to flex the PIPJ of the little finger $>90^\circ$ only when the ring finger PIPJ was also allowed to flex simultaneously. Absent function was the inability to flex the PIPJ $>90^\circ$ even when flexion of the ring finger PIPJ was allowed.

The third part of the examination assessed for the completeness of the palmar arch in the hand using an

Allen's test. This part of the examination was carried out only in patients with an absent PL tendon. In cases where the PL was absent bilaterally, Allen's test was carried out bilaterally.

All statistical analyses were carried out using SPSS (version 11.5). The prevalence of absence of the PL (unilateral or bilateral) were presented with a 95% confidence interval. The association between absence of the PL and body side, sex and FDS to the little finger was assessed using chi-square or Fisher's exact tests. Statistical significance was set at $P < 0.05$.

Results

Three hundred and twenty-nine individuals of Chinese descent (120 men and 209 women) aged between 7 and 85 years [mean age, 43.4; standard deviation (SD), 16.8] were examined (Table 1). There were 16 left-handed individuals (4.9%) and 10 manual workers (3%). The PL was absent unilaterally in 11 subjects (3.3%; 95% CI, 1.9 to 5.9), while it was absent bilaterally in 4 subjects (1.2%; 95% CI, 0.5 to 3.1). It was absent on the right side in 3 subjects (0.9%) and on the left side in 8 subjects (2.4%). The overall prevalence of the absence of PL (unilateral or bilateral) was 4.6% (15 subjects; 95% CI, 2.8 to 7.4). The difference in the prevalence

Table 1. Detailed Data

No. of subjects examined	329 Total	120 (36.5%) Men	209 (63.5%) Women
Age (y)	Range: 7-85	Mean age: 43.4	SD: 16.8
Hand dominance	16 (4.9%) Left handed	313 (95.1%) Right handed	
Occupation	10 (3.0%) Manual workers	319 (97.0%) Sedentary workers	
Absence of palmaris longus	Right	Left	Bilateral
Men	1 (0.5%)	7 (3.3%)	2 (1.0%)
Women	2 (1.7%)	1 (0.8%)	2 (1.7%)
Overall	3 (0.9%)	8 (2.4%)	4 (1.2%)
FDS to little finger (658 hands)	Absent	Common	Independent
Right	20 (6.1%)	133 (40.4%)	176 (53.5%)
Left	22 (6.7%)	139 (42.2%)	168 (51.1%)
Men	8	89	143
Women	34	183	201
Overall	42 (6.4%)	272 (41.3%)	344 (52.3%)
Concomitant PL Absence	1 (R) (0.05%)	9 (3R + 6L) (49.9%)	9 (3R + 6L) (49.9%)
Allen's test (done only in the 15 subjects with an absent PL)	No. of subjects with a competent palmar arch 14 (93.3%)	No. of subjects with an incompetent palmar arch 1 (6.7%)	

PL: palmaris longus; SD: standard deviation

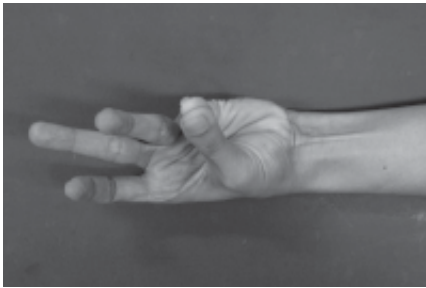


Fig. 1. Schaeffer's (1909)³ technique for assessment of the PL. It involves opposition of the thumb to the little finger and flexion of the wrist.

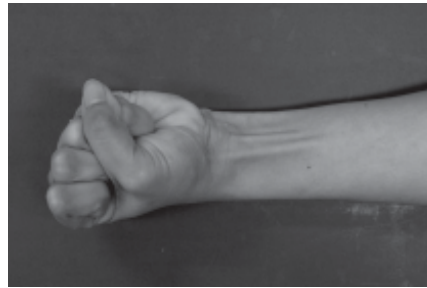


Fig. 2. Thompson's (1921)⁴ technique for assessment of the PL. It involves flexion of the fingers to form a fist followed by flexion of the wrist and finally the thumb is opposed and flexed over the fingers.

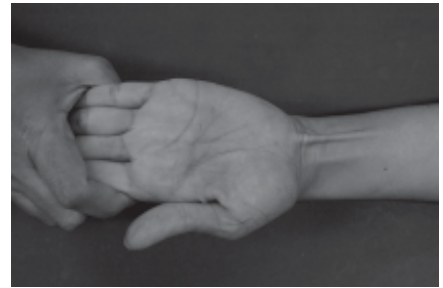


Fig. 3. Mishra's (2001)¹⁶ first test for demonstrating the PL. It involves passive hyperextension of the metacarpo-phalangeal joints followed by resisted active flexion at the wrist.

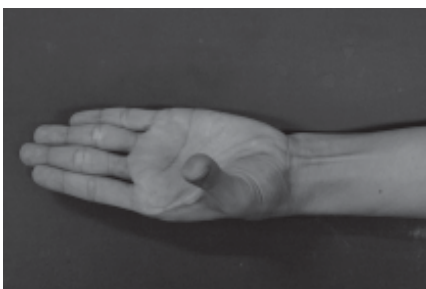


Fig. 4. Mishra's (2001)¹⁶ second test for demonstrating the PL. It involves resisted abduction of the thumb.



Fig. 5. Pushpakumar's (2004)¹⁷ two finger sign method. It involves extension of the index and middle finger with flexion of the other fingers and the wrist followed by opposition and flexion of the thumb.

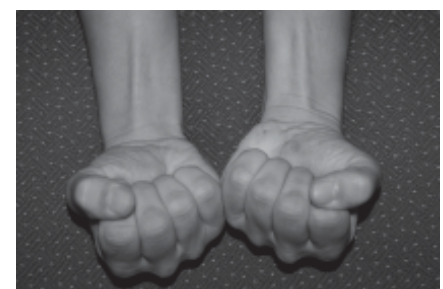

Fig. 6. Thompson's fist test in a patient with an absent palmaris longus demonstrating prominence of the flexor carpi radialis which could be mistaken for the palmaris longus.

of PL absence between right and left side was -1.5% (95% CI, -4.4 to 1.2). This implies that the prevalence was not significantly different between sides. However, subjects with absence of the PL on the right side were 52.3 times more likely to have a concomitant absence of PL on the left side [odds ratio (OR), 52.3; 95% CI, 10.0 to 273.4; $P < 0.001$].

Among the men, it was absent on the right side in 2 subjects (1.7%), on the left side in 1 subject (0.8%) and bilaterally in 2 subjects (1.7%). Among the women, it was absent on the right side in 1 subject (0.5%), on the left side in 7 subjects (3.3%) and bilaterally in 2 subjects (1.0%). The overall prevalence of an absent PL was 4.2% in men (5 men) and 4.8% in women (10 women). The difference in overall prevalence of PL absence (unilateral or bilateral) between male and female was -0.6% (95% CI, -5.1 to 5.0). Hence, there was no significant difference in overall prevalence of PL absence between sexes. In all subjects, who demonstrated an absence of the PL with the standard technique (19 forearms), all the other 4 techniques were used to confirm the absence. The results of the other 4 techniques also concurred with the standard technique.

On testing for FDS functionality of the little finger, it was found that out of the 658 little fingers studied, FDS was

absent in 42 fingers (6.4%), had a common function in 272 fingers (41.3%) and an independent function in 344 fingers (52.3%). Only 1 male patient with bilateral absence of the PL had a concomitant absence of the FDS to the right little finger. There was also no correlation between the presence or absence of the PL and the FDS to the little finger (right side: $P = 0.516$; left side: $P = 0.603$).

Of the 15 subjects with an absent PL tendon (unilateral or bilateral), Allen's test indicated a complete palmar arch in 14 subjects (right hand: 3 subjects; left hand: 7 subjects; bilateral: 4 subjects) and an incomplete arch in the left hand of only 1 female subject.

Discussion

Prevalence of PL Absence in the Chinese

Our study found the overall prevalence of absence of PL (unilateral or bilateral) in the Chinese population to be 4.6%. This value is comparable to the low prevalence of an absent PL (2.8%) reported by Wagenseil in the only other study of a Chinese population.⁶ It is interesting to note that most standard textbooks of hand surgery quote a prevalence of absence of around 15%.²⁰⁻²⁶ This value is quite high compared to the values we obtained for the Chinese and it is likely that these reflect the values seen in Caucasian

populations. There is disagreement in the literature regarding the symmetry of muscle absence and whether absence is more common in women. Most studies^{4-6,9} indicate that absence is more common on the left side and in women. A few studies also suggest that bilateral absence is more common compared to unilateral absence.⁴⁻⁶ The discussion of this point is made difficult because most authors do not support their conclusions with statistical analysis of the data. The 5 studies^{2,7,9,13,14} where statistical analysis was carried out failed to detect any association between the absence of PL and the side of the body or the sex. Our study also found no statistically significant difference between unilateral and bilateral prevalence of absence, between body sides and between men and women.

Association of the PL with Other Anatomical Structures

The prevalence of absence of the FDS to the little finger in our study was 6.4%. This is quite low when compared to other studies in Caucasian populations, which report a rate of absence of around 15% to 21%.^{15,18,19} In our study, only 1 hand out of a total of 658 hands had an absolute deficiency of the FDS to the little finger and an absent PL tendon (0.15%). Statistical analysis confirmed that there was no correlation between the two. In their study of 300 patients, Thompson et al¹⁵ found only 2 patients with concomitant absence of the PL and the FDS to the little finger. It appears safe to conclude that there is no relationship between the functional absence of the FDS to the little finger and the unilateral or bilateral absence of the PL, irrespective of ethnic origins.

After a cadaveric study of 47 embalmed hands, O' Sullivan and Mitchell¹⁰ suggested that there was an association between the absence of the PL and the presence of an abnormal superficial palmar arch. Out of the 47 cadaveric hands they examined, the PL was absent in 25 hands (53.19%) and of these 25 hands, the superficial palmar arch was anomalous in 22 hands. In our study, we did an Allen's test on all subjects with an absent PL. However, out of the 15 subjects with an absent PL tendon, only 1 subject (a female) had an Allen's test suggestive of an incomplete palmar arch. We therefore feel that there is no association between the absence of the PL tendon and an incomplete palmar arch. However, this could not be statistically verified, as we did not perform an Allen's test on all our subjects.

It has been postulated that an absence of the plantaris may be associated with agenesis of the PL.¹³ This relationship was not explored in this study. However, a review of literature showed 4 studies^{2,12-14} that have specifically addressed this question. All these studies have statistically analysed their data and failed to demonstrate any association between the presence (or absence) of the PL and the plantaris.

Clinical Assessment of the PL

Five techniques of examining for the presence of the PL in vivo have been described in literature. The most commonly used technique is the standard technique described by Schaeffer in 1909.³ The second method was described by Thompson et al⁴ in 1921. In 2001, Mishra¹⁶ described 2 methods of examining for the PL and in 2003, Pushpakumar et al¹⁷ described the "two finger" sign method. All except Mishra tested for both actions of the PL simultaneously. Mishra's 2 tests examine for different actions of the PL. The first test makes use of the better known action of the PL as a weak flexor of the wrist, while the second test makes use of the lesser known, but equally important, function of the PL as a stabiliser of the superficial structures in the palm, in preparation for the abduction of the thumb.^{27,28}

We concur with Pushpakumar et al¹⁷ that the standard test is somewhat difficult for patients to understand and is a moderately complex hand manoeuvre. However, the "two finger" sign test suggested by them is also a moderately complex manoeuvre. The authors additionally mention that the two-finger gesture is a less than respectful gesture in England and Ireland. Although the test described by Thompson et al⁴ is an easy and simple manoeuvre, it does not result in adequate abduction of the thumb unless the subject has been specifically instructed to make the thumb tip touch the dorsum of the PIPJ of the little finger after a fist has been made. Usually, the thumb is placed over the dorsum of the middle finger or index finger, as the illustration in Thompson's original article demonstrates.⁴

Thompson's test, Schaeffer's test, Mishra's second test and Pushpakumar's two-finger sign test require the patient to flex the fingers and/or the wrist. This commonly leads to a prominence of the flexor carpi radialis in most cases and FDS in some cases in addition to the PL. The prominence of these tendons could be confused with the PL (Fig. 6). Another disadvantage of the above tests is that they all depend on thumb abduction for making the PL prominent. These tests are therefore of less value if the patient cannot abduct his thumb, as is commonly seen in patients with median nerve palsy. We feel that Mishra's first test is the best to demonstrate the PL. It was also the easiest to explain to subjects.

Conclusion

The prevalence of an absent PL in the Chinese is 4.6%, which is much lower than what is commonly mentioned in the literature. There is also no relationship between the absence of the PL and the different sides of the body, gender and whether the absence is unilateral or bilateral. The prevalence of absence of FDS to the little finger in the Chinese is 6.4%, which is also much lower compared to

values reported in Caucasians. There seems to be no association between the absence of the PL and other anatomical structures like the FDS to the little finger and plantaris. Although there seemed to be no association between an absent PL and the superficial palmar arch, further study is needed to confirm this. Among the various techniques mentioned in the literature, Mishra's first test was the easiest to explain to subjects and seems the best way to clinically assess the presence of the PL.

REFERENCES

1. Tountas CP, Bergman RA. *Anatomic Variations of the Upper Extremity*. New York: Churchill Livingstone, 1993:141-3.
2. Wehbe MA. Tendon graft donor sites. *J Hand Surg (Am)* 1992; 17:1130-2.
3. Schaeffer JP. On the variations of the palmaris longus muscle. *Anat Rec* 1909;3:275-8.
4. Thompson JW, McBatts J, Danforth CH. Hereditary and racial variations in the musculus palmaris longus. *Am J Phys Anthropol* 1921;4:205-20.
5. Reimann AF, Daseler EH, Anson BJ, Beaton LE. The palmaris longus muscle and tendon; a study of 1600 extremities. *Anat Rec* 1944;89:495-505.
6. Machado AB, DiDio LJ. Frequency of the musculus palmaris longus studied in vivo in some Amazon Indians. *Am J Phys Anthropol* 1967;27:11-20.
7. Troha R, Baibak GJ, Kelleher JC. Frequency of the palmaris longus tendon in North American Caucasians. *Ann Plast Surg* 1990;25:477-8.
8. Ceyhan O, Mavt A. Distribution of agenesis of the palmaris longus muscle in 12-18 years old age groups. *Indian J Med Sci* 1997;51:156-60.
9. Thompson NW, Mockford BF, Cran GW. Absence of the palmaris longus muscle: a population study. *Ulster Med J* 2001;70:22-4.
10. O'Sullivan E, Mitchell BS. Association of the absence of the palmaris longus tendon with an anomalous superficial palmar arch in the human hand. *J Anat* 2002;201:405-8. Erratum in: *J Anat* 2003;202:253.
11. Ito MM, Aiko M, Kida MY, Ishii S, Kumaki K, Tanaka S. Length and width of the tendinous portion of the palmaris longus: a cadaver study of adult Japanese. *J Hand Surg (Am)* 2001;26:706-10.
12. George R. Co-occurrence of the palmaris longus and plantaris muscles. *Anat Rec* 1953;116:521-3.
13. Harvey JF, Chu G, Harvey PM. Surgical availability of the plantaris tendon. *J Hand Surg (Am)* 1983;8:243-7.
14. Vanderhoof E. The frequency and relationship between the palmaris longus and plantaris tendons. *Am J Orthop* 1996;25:38-41.
15. Thompson NW, Mockford BJ, Rasheed T, Herbert KJ. Functional absence of the flexor digitorum superficialis to the little finger and absence of the palmaris longus – is there a link? *J Hand Surg (Br)* 2002;7:433-4.
16. Mishra S. Alternative tests in demonstrating the presence of palmaris longus. *Indian J Plast Surg* 2001;34:12.
17. Pushpakumar SB, Hanson RP, Carroll S. The 'two finger' sign. Clinical examination of palmaris longus (PL) tendon. *Br J Plast Surg* 2004;57:184-5.
18. Baker DS, Gaul JS, Williams VK, Graves M. The little finger superficialis – clinical investigation of its anatomic and functional shortcomings. *J Hand Surg (Am)* 1981;6:374-8.
19. Austin GJ, Leslie MB, Ruby LK. Variations of the flexor digitorum superficialis of the small finger. *J Hand Surg (Am)* 1989;14A:262-7.
20. Hentz VR, Chase RA. Divided flexor tendon. In: Hentz VR, Chase RA, editors. *Hand Surgery – A Clinical Atlas*. Philadelphia: WB Saunders, 2001:364.
21. Kleinert HE, Pulvertaft RG, Smith DJ. Flexor tendon grafting in the hand. In: Jupiter JB, editor. *Flynn's Hand Surgery*. Baltimore: Williams & Wilkins, 1991:285.
22. Saldana MJ. Primary extensor tendon grafts in zones 5 to 7. In: Blair WE, editor. *Techniques in Hand Surgery*. Baltimore: Williams & Wilkins, 1996:587.
23. Smith P. Injury. In: Smith P, editor. *Lister's the Hand – Diagnosis and Indications*. London: Churchill Livingstone, 2002:11.
24. Smith RJ. Tendon transfers to restore thumb opposition. In: Smith RJ, editor. *Tendon Transfers of the Hand and Forearm*. Boston: Little Brown and Co, 1987:75.
25. Valentine P. Extrinsic muscles of the hand and wrist: An introduction. In: Tubiana R, editor. *The Hand*. Vol. I. Philadelphia: WB Saunders, 1981:237.
26. Zancolli EA, Cozzi EP. The retinaculum cutis of the hand. In: Zancolli EA, Cozzi EP, editors. *Atlas of Surgical Anatomy of the Hand*. New York: Churchill Livingstone, 1992:2.
27. Fahrer M, Tubiana R. Palmaris longus, anteductor of the thumb. *Hand* 1976;8:287-9.
28. Fahrer M. The role of palmaris longus muscle in the abduction of the thumb. *J Anat* 1973;116:476.