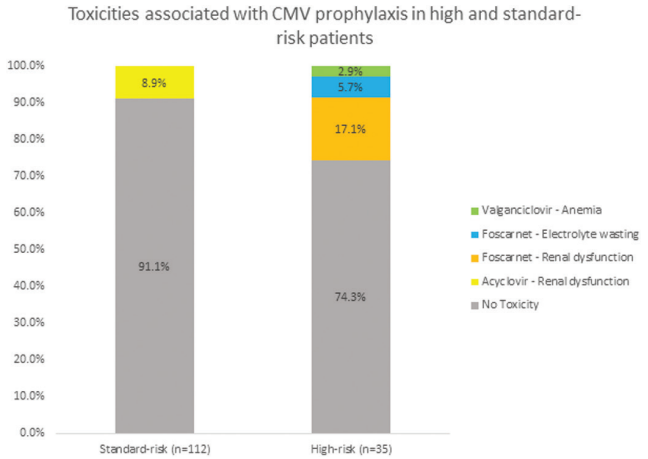

Disclosures. **M. Hayes**, Merck: Grant Investigator, Research grant. **A. Newman**, Merck: Grant Investigator, Research grant. **C. L. K. Boge**, Merck: Grant Investigator, Research grant. **B. T. Fisher**, Merck: Grant Investigator, Grant recipient and Research grant.

1897. Letermovir Salvage for Complicated Cases of Resistant CMV

Nicholas Turner, MD[1]; Andrew Strand, MD[1]; Jennifer Saullo, MD, PharmD[1]; Sana Arif, MBBS[1]; Eileen K. Maziarz, MD[1]; Dilraj Grewal, MD[2]; Arthur W. Baker, MD, MPH[3] and Cameron R. Wolfe, MBBS (Hons), MPH, FIDSA[1]; [1]Division of Infectious Diseases, Duke University Medical Center, Durham, North Carolina, [2]Ophthalmology, Duke University Medical Center, durham, North Carolina, [3]Division of Infectious Diseases, Duke University School of Medicine, Durham, North Carolina

Session: 224. Antiviral Therapies
Saturday, October 6, 2018: 12:30 PM

Background. Limited treatment options exist for ganciclovir-resistant CMV disease. Foscarnet can cause renal insufficiency, and maribavir has poor ocular penetration. Letermovir is approved for primary CMV prophylaxis in hematopoietic stem cell transplantation, but efficacy in treatment of CMV disease or secondary prophylaxis is not known.

Methods. We analyzed data from all adult patients at a single center who initiated letermovir for treatment of CMV disease or secondary prophylaxis of CMV retinitis from November 2017 through April 2018. We described patient characteristics, extent of CMV disease, prior antiviral therapies, kinetics of CMV DNAemia, and clinical outcomes.

Results. Four patients received letermovir for treatment, and one for secondary suppression, of CMV DNAemia and CMV retinitis (table). All patients had proven genotypic resistance with complications and/or clinical failure on prior antivirals. Letermovirdoses ranged from 480 mg to 720 mg daily. Three patients received concomitant CMV immune globulin and intravitreal therapy with foscarnet and/or ganciclovir. No patients developed side effects attributable to letermovir, and expected increases in tacrolimus levels occurred. All five patients demonstrated clinical and retinoscopic improvement (Figure 1), but two patients did not achieve complete resolution of DNAemia (Figure 2).

Conclusion. Use of letermovir, often in combination with intravitreal therapy, was associated with sustained clinical improvement in five patients with CMV retinitis. Treatment doses of up to 720 mg were well tolerated. Despite marked improvement of ocular disease, two patients did not achieve sustained suppression of DNAemia.

Table: Patient Characteristics

	A. 66-Year-Old Male	B. 50-Year-Old Male	C. 46-Year-Old Male	D. 66-Year-Old Male	E. 43-Year-Old Female
CMV risk factor(s)	Lung txp	Lung txp	Heart txp	Heart txp	Susac syndrome
Disease burden	CMV syndrome Retinitis	CMV syndrome Retinitis	CMV syndrome Retinitis Colitis	Retinitis	Retinitis
Previous antivirals	C, G/V, M, F	G/V, F, M	G/V, F	C, G/V, F	G, F
CMV mutations	M460V	Q578H	M460I	H520Q, C603W, T503I	A594V
Current letermovir duration (weeks)	9.5	9.5	7	5	26[a]

[a]Secondary prophylaxis only.

C, CMV Immune globulin; F, foscarnet; G, ganciclovir; M, maribavir; txp, transplant; V, valganciclovir.

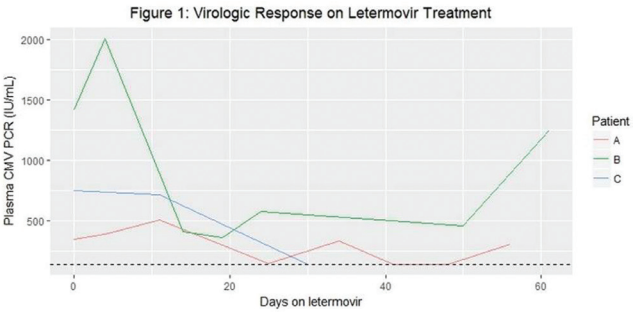

Figure 2: Patient E, CMV retinitis improvement on letermovir.

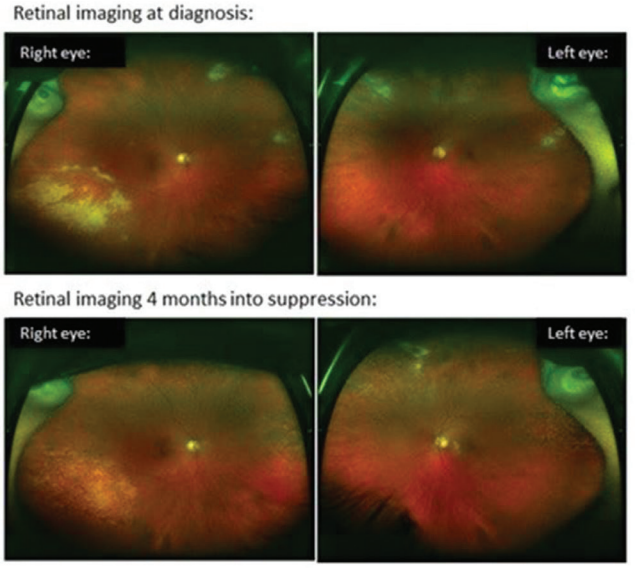

Disclosures. **C. R. Wolfe**, Merck: Scientific Advisor, Consulting fee.

1898. Clinical Characteristics of Patients With Solid-Organ Transplantation (SOT) and Norovirus (NV) Infections

Verena König, Medical Student[1]; Jörg Hofmann, PhD[2]; Markus Tölle, MD[3]; Petra Reinke, MD[4]; Susanne Brakemeier, MD[5] and Stefan Schwartz, MD[1]; [1]Department of Hematology and Oncology, Campus Benjamin Franklin, Charité Universitätsmedizin, Berlin, Germany, [2]Institute of Virology, Campus Mitte, Charité Universitätsmedizin, Berlin, Germany, [3]Department of Nephrology and Intensive Care Medicine, Campus Benjamin Franklin, Charité Universitätsmedizin, Berlin, Germany, [4]Department of Nephrology and Intensive Care Medicine, Campus Virchowklinikum, Charité Universitätsmedizin, Berlin, Germany, [5]Department of Nephrology and Intensive Care Medicine, Campus Mitte, Charité Universitätsmedizin, Berlin, Germany

Session: 224. Antiviral Therapies
Saturday, October 6, 2018: 12:30 PM

Background. NV infections in immunocompromised patients could cause chronic gastroenteritis (GE) with devastating consequences. A successful reduction of the medical immunsuppression in patients with NV GE and SOT have been reported repeatedly, but the optimal approach in these patients is less well defined.

Methods. We identified patients with PCR-confirmed NV GE and SOT from a laboratory database and patients with other underlying conditions from a clinical database. Clinical data were retrieved from pt files and by telephone interviews. The severity of GE was assessed by the Vesikari score (VS). Subgroups were dichotomised at their medians. Continuous variables were compared by Kruskal–Wallis test and time-dependant variables were compared by Kaplan–Meier analyses and log-rank test.

Results. Overall, 101 patients (age: 1–90 years, median 60) with SOT (36), hematopoietic stem cell transplantation (HSCT, 23), hematological malignancies (HM, 20), solid tumor (ST, 8), and other nonimmunocompromising conditions (14) were identified. Patients with SOT had received kidney (30), combined kidney/pancreas (4), liver/pancreas/stomach/small bowel (1), or liver/small bowel (1) transplantation.

The median duration of symptoms was significantly longer in patients with SOT compared with those with other conditions (SOT 26, HSCT 12, HM 5, ST 4, other 3 days; Figure 1, $P < 0.0001$), but the disease severity (VS, 74 patients with sufficient data; Figure 2) was not significantly different across the risk groups.

Age, time since transplantation, the use of calcineurin inhibitors vs. other drugs for immunosuppression, and comparison of kidney only vs. other organ transplantation