SCIENTIFIC PAPER JSLS

A Novel Laparoscopic Tissue Retrieval Device

Michael A. Schellpfeffer, MD, MS

ABSTRACT

Background and Objectives: A persistent problem in operative laparoscopy is the removal of laparoscopically resected tissue specimens. This study is a consecutive series demonstrating a device designed to facilitate the removal of laparoscopically resected tissue specimens.

Methods: Forty-two patients met the criteria for inclusion in this study. These patients included gynecologic operative laparoscopy patients with a laparoscopically resected tissue specimen placed in a tissue retrieval sac. The sac could not to be removed from a subumbilical trocar incision with axial traction. The device was placed and an attempt was made to remove the sac/specimen. When successful, the wound was inspected for a fascial defect and closed, and if unsuccessful the wound was enlarged to remove the tissue specimen.

Results: Thirty-four patients had successful removal of the laparoscopic tissue specimen. In 8 patients, the device was not successful. No adverse intraoperative outcomes occurred. Three patients had superficial postoperative wound infection treated successfully with outpatient oral antibiotic therapy. There were no other postoperative complications.

Conclusion: This novel medical device allows an easy and effective means to remove trapped laparoscopic tissue retrieval sacs. Prudent use of this device appears to convey no increased risk of adverse surgical outcomes.

Key Words: Laparoscopic tissue retrieval device, Laparoscopic tissue retrieval sac.

Kenosha, Wisconsin, USA

The author is the President and Chief Executive Officer of Laparoscopic Technologies, Inc. the distributor of this medical device, and he is the owner of the patent for this medical device. He has no financial relationship with Harbor Machining, Inc. the manufacturer of the forceps.

Harbor Machining, Inc. Kenosha, Wisconsin, is recognized as the manufacturer of this medical device as well as the prototypes used in the development of the device.

Address correspondence to: Michael A. Schellpfeffer, MD, MS, 1400 75th Street, Kenosha, Wisconsin 53143, USA. Telephone: (262) 658-2133, Fax: (262) 658-2699, E-mail: maschellpfeffer@gmail.com

DOI: 10.4293/108680811X13176785204319

INTRODUCTION

Operative laparoscopic surgery has expanded its boundaries exponentially over the past 2 decades. In this regard, laparoscopic surgeons continue to face one persistent problem. This problem is the ability to safely and effectively remove a variety of laparoscopically resected tissues from the abdominal cavity. Of course, one solution to this problem is to enlarge one of the laparoscopic trocar incisions to remove the tissue specimen intact. This solution is, however, counterproductive to the concept of minimally invasive surgery. Another solution is to morcellate the specimen with some type of morcellation device. Morcellation, however, is not acceptable in many surgical cases, because of the risk of dissemination of infection and/or malignant neoplasia. Also, morcellation may compromise adequate pathologic examination of the resected tissue specimen.

Several laparoscopic tissue retrieval sacs exist to facilitate removal of intact surgical tissue specimens (eg, E-Sac, ENDO CATCH™, Pleatman Sac®, Endobag®). Though these sacs are very effective in isolating a surgical specimen from the peritoneal cavity and the abdominal incision, they all have one inherent disadvantage. This disadvantage is that they distend as the tissue inside of them is brought up to the interior aspect of the abdominal wall in preparation for removal from the abdominal cavity. The specimen becomes trapped in the abdominal cavity if the diameter of the distended sac becomes larger than the diameter of the incision. A variety of maneuvers can be attempted using traditional surgical instrumentation to facilitate the removal of these laparoscopically resected tissue specimens with variable success. In many cases, a laparoscopic surgeon is frustrated by either rupturing the laparoscopic retrieval sac or enlarging an otherwise small incision. Ghezzi et al[1] recently published the only study that showed that large gynecologic masses could be safely and successfully removed by morcellation of the masses in the laparoscopic tissue retrieval sac through a standard 10-mm trocar incision.

With the above considerations in mind, a device is needed to counteract the physical constraints of small incisions and the physical characteristics of a laparoscopic tissue retrieval sac. First, such a device should minimize the

diameter of the laparoscopic tissue retrieval sac and the enclosed surgical specimen. Second, the device should help protect the integrity of the sac/surgical specimen. Third, it should facilitate removal of the sac/surgical specimen by allowing axial traction to be applied to the device and not the sac/surgical specimen. Such a device has been developed by Schellpfeffer.[2-4] It is patterned after an obstetrical forceps[5] and fulfills all of the above requirements. Recently, Brown et al[6] confirmed this concept, demonstrating that standard obstetrical forceps can be used to extract nephrectomy specimens enclosed in a laparoscopic retrieval sac. As illustrated in **Figure 1a**, the device consists of a left and right side. Each side has a handle, a shank, a portion of the locking mechanism, and a blade.

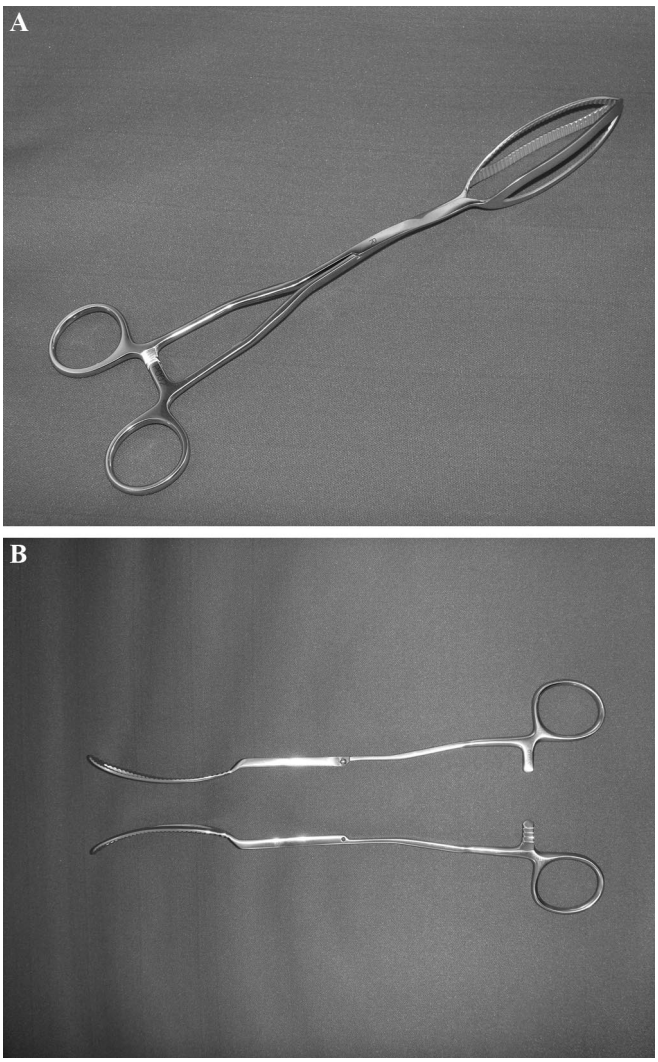

Figure 1. The laparoscopic tissue retrieval forceps is seen (a) assembled and (b) disassembled.

Each blade's width is 2cm. The device freely articulates and disarticulates to allow for placement around a sac/specimen **(Figure 1b)**. The size and curve of the blades allow for easy introduction of each portion of the device around the laparoscopic tissue retrieval sac/specimen through a standard incision made for a 10/12-mm trocar. Once applied to the sac/specimen, the device minimizes the diameter of the sac/specimen and protects its integrity. Axial traction is then applied to the device to facilitate removal of the sac/specimen.

The purpose of this study was to demonstrate the usefulness of this newly developed laparoscopic tissue retrieval device in removing trapped surgical tissue specimens resected at the time of operative gynecologic surgery.

MATERIALS AND METHODS

This study was a consecutive series of patients over a 5-year period all operated on by the author. The inclusion criteria for this study were as follows:

1) a laparoscopically resected tissue specimen placed within a laparoscopic tissue retrieval sac not able to be removed from the abdominal cavity by axial traction on the sac.

2) all of the extractions were performed through a subumbilical trocar incision that had previously accommodated a standard 10/12-mm disposable laparoscopic trocar without enlarging the incision.

3) no cases of obvious malignant or grossly infected surgical tissue specimens were included in this study.

Forty-two operative gynecologic laparoscopic procedures were performed that met the criteria of this study. All surgical procedures were performed by the author, and the study was approved by the hospital Institutional Review Board.

Extraction Procedure

The extraction procedure begins after an unsuccessful attempt at removal of the laparoscopic tissue extraction sac and the enclosed tissue specimen through the subumbilical incision site after removal of the trocar. The sac/specimen is directly visualized using a 5-mm laparoscope placed through a previously placed lower abdominal 5-mm accessory port. Direct laparoscopic visualization of the sac/specimen and the forceps placement is performed continuously throughout the extraction process. **Figures 2 through 4** demonstrate the application of the device to a laparoscopic tissue retrieval sac/specimen, and removal

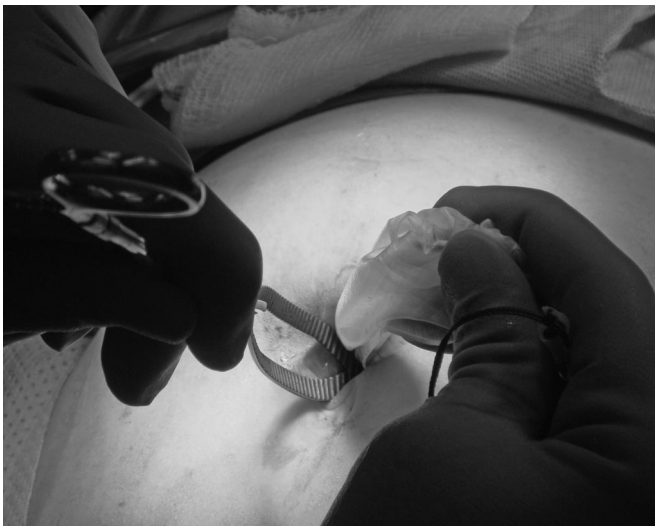

Figure 2. The right forceps blade (lower blade) is placed alongside of the tissue retrieval sac. The retrieval sac is always oriented anterior or in front of the blade placement.

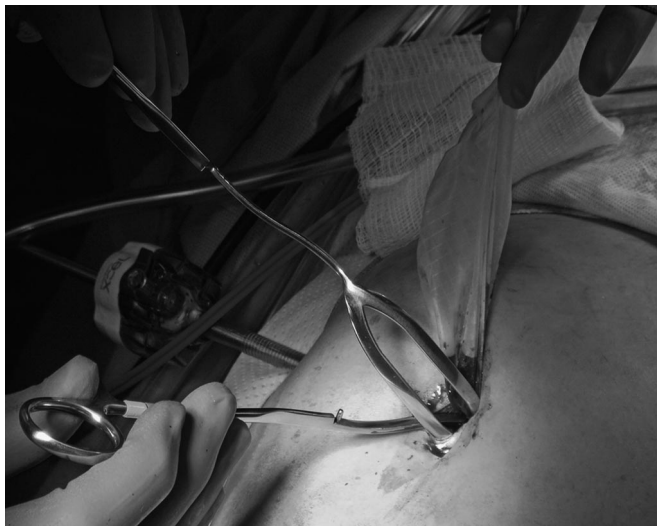

Figure 3. The left forceps blade (upper blade) is placed alongside of the tissue retrieval sac. The left forceps blade is placed in between the right blade and the retrieval sac.

of the sac/specimen from the abdominal cavity. **Figure 2 and 3** show an exterior view of the placement of the right and left blade, respectively. **Figure 4** illustrates the 2 blades locked in place around the sac/specimen with traction being applied for removal from the abdominal cavity. After removal of the sac/specimen, the trocar incision site is inspected to identify any possible extension of the trocar incision fascial defect that may have occurred as a result of placement of the device or removal of the sac/specimen. The fascial defect from the subumbilical trocar is then closed with interrupted synthetic delayed absorption sutures. Postoperatively, all of the patients are seen for a routine postoperative examination between 2 weeks to 6 weeks after the surgery. All patients are queried and examined for any adverse outcomes. Long-term outcomes are obtained if possible.

RESULTS

Of the 42 patients included in this study, 34 had successful removal of the laparoscopic tissue retrieval sac and surgical specimen. **Table 1** lists the procedures performed and the outcomes. In 8 patients (19%), the sac/specimen was unable to be removed successfully. All of the unsuccessful cases were related to the size of the tissue to be removed. In these cases, the subumbilical incision was enlarged, and the specimen was removed successfully. There were no sac ruptures. All of the specimens were removed intact for standard pathologic examination. Tissue volumes were provided from the pathology reports. Several specimens were drained inside the laparoscopic retrieval sac, and one specimen was divided due to its size prior to placement in a sac. There were no other intraoperative adverse outcomes among the study population. Postoperatively, 3 patients (7%) had superficial subumbilical trocar-site wound infections. Each of the infections responded quickly and completely to oral antibiotic therapy. One patient had postoperative urinary retention requiring continuous bladder catheterization for 24 hours. Two patients, done on an emergent basis, failed to follow up for postoperative visits and were lost to follow-up. In the short-term follow-up over a 2-week to 6-week period, there were no incisional hernias in the study population patients who returned for follow-up examinations. There were no other postoperative complications as a result of the use of the device in this study population. Fifteen of 42 patients (35.7%) were seen in long-term follow-up from 6 months to 5 years. There were no long-term adverse outcomes as a result of the use of the device.

DISCUSSION

This study showed that this novel medical device is potentially both efficacious and safe to use in facilitating the removal of trapped laparoscopically resected tissue specimens. By design, this study demonstrated the efficacy of the forceps in that the major criteria for entry into the study was the inability to remove the tissue retrieval sac/specimen from the abdominal cavity with ordinary axial traction on the retrieval sac. Over 80% of the trapped

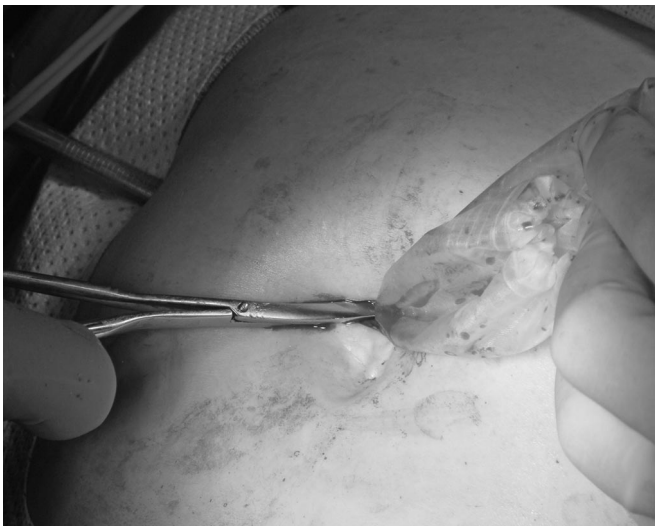

Figure 4. The forceps blades are aligned and locked together. Extraction of the tissue retrieval sac is accomplished by applying axial traction to the locked forceps.

extraction sacs/specimens were successfully removed using the forceps. The majority of the forceps failures were due to the size of the tissue specimen. The safety of the device was also demonstrated in that there were no major complications observed as a result of using the forceps. The postoperative infections were all minor and well within the range of current reports of infectious complications for operative gynecologic laparoscopy.[7-9] Long-term follow-up in greater than a third of the patients also demonstrated no adverse outcomes from use of the device.

There are, however, several points that need to be emphasized in using this device. First, it is imperative that the device placement, locking, and extraction process continually be observed through the laparoscope as it is performed to avoid any possible injury to the intraabdominal organs. Injury to intraabdominal organs is also prevented by maintaining an adequate pneumoperitoneum. This is facilitated by holding the tissue extraction sac in close apposition to the inferior aspect of the anterior abdominal wall during the forceps placement. Secondly, to allow for quick and easy placement and locking of the device, proper initial orientation of the instrument is essential. The extraction sac must always be kept anterior or in front of the blade placement. The device itself should always be assembled outside the abdomen with the locking pin of the right blade facing up and the left blade label "L" facing up. Each blade is then introduced separately. The right or bottom blade is placed first beneath or posterior to the anteriorly oriented extraction sac. Then the left or top blade is placed between the right blade handle and the anteriorly oriented extraction sac. This procedure will ensure that the blades will always be oriented correctly around the specimen for easy and effective locking and extraction. Finally, the trocar site used for the extraction must be inspected to ensure that the fascial defect is properly closed. On occasion, the fascial defect is enlarged during the extraction process. As long as the entire extent of the fascial defect is identified, it is easily closed in the routine fashion as is done with any other trocar site >10mm as recommended by Kadar et al.[10]

It appears that use of this device conveys no significant additional risk, and it does allow the laparoscopic surgeon another means to facilitate removal of laparoscopically resected tissue specimens. Prudent use of this device is, however, imperative. Following the general guidelines recommended for performance of safe operative laparoscopic surgery is still paramount. As general use of this device increases, continued monitoring and re-assessment of its capabilities and potential ultimate limitations is also important. Certainly a larger cohort of patients needs to be studied to confirm the efficacy and safety of this device. Future clinical uses for this device could include its use in a wider range of laparoscopic surgeries. Prototypes are already under development for larger versions of the device to allow bigger laparoscopic tissue retrieval sacs and specimens to be removed through mini-laparotomy type incisions. Smaller prototypes are also in development for use in pediatric operative laparoscopic cases.

CONCLUSIONS

This laparoscopic tissue retrieval device is a novel medical device that allows an easy and effective means to remove trapped laparoscopic tissue retrieval sacs with enclosed tissue specimens.

References:

1. Ghezzi F, Cromi A, Uccella S, Siesto G, Bergamini V, Bolis P. Transumbilical surgical specimen retrieval: a viable refinement of laparoscopic surgery for pelvic masses. *BJOG*. 2008;115:1316-1320.

2. Laparoscopic Tissue Retrieval Forceps Patent Number: #5,626,606. Date of Patent: 6 May 1997.

3. Schellpfeffer Forceps FDA 510k Approval: 15 November 2007 #K072761.

Table 1.
Procedures and Outcomes

Patient	Age	Weight	Clinical Indication[a]	Procedure[a]	Pathology	Tissue Volume (cc)	Outcome	Complications
1	45	159	Pelvic Pain/Mass	LSO	Hydrosalpinx	25	Successful	None[d]
2	40	147	Complex Pelvic Mass	LSO	Hydrosalpinx	15[b]	Successful	LTF
3	47	148	Pelvic Pain S/P Hyst	BSO	Hem. C-L Cysts	L-35/R-31.5	Successful	None
4	54	166	Complex Pelvic Mass	BSO	Serous Cystadenoma	L-42/R-18	Failed	None[d]
5	34	117	Pelvic Pain	LSO	Endometrioma	36.7	Successful	None[d]
6	81	173	Postmenopausal Mass	LSO	Serous Cystadenoma	30	Successful	None
7	44	187	Complex Pelvic Mass	LSO	Serous Cystadenoma	168	Successful	None[d]
8	72	144	Postmenopausal Mass	LSO	Serous Cystadenoma	9.5	Successful	None
9	34	165	Complex Pelvic Mass	L Cyst	Benign Cystic Teratoma	8.2	Successful	None[d]
10	45	150	Pelvic Pain/Mass	LSO	Serous Cystadenoma	34.9	Failed	None
11	74	107	Postmenopausal Mass	BSO	Ovarian Fibroma	R-2.8/L-22.8	Successful	None
12	30	161	Pelvic Pain/Mass	RSO	Hem. C-L Cyst	8.4	Successful	None
13	33	202	Acute Pelvic Pain	LSO	Adnexal Torsion	523	Failed	None
14	44	202	Pelvic Pain/Mass	BSO	Endometrioma	R-13.4/L-10.9	Successful	None[d]
15	46	199	Pelvic Pain S/P Hyst	BSO	Normal T/O	56	Successful	None
16	54	155	Postmenopausal Mass	BSO	Benign Cystic Teratoma	6.7[b]	Successful	None[d]
17	67	175	Postmenopausal Mass	BSO	Serous Cystadenoma	R-3.1/L-5.2	Successful	SWI[d]
18	49	188	Pelvic Pain/Mass	RSO	C-L Cyst	48	Successful	SWI
19	34	194	Pelvic Pain/Mass	LSO	TOA	96	Failed	None
20	34	184	Acute Pelvic Pain	LSO	Torsed Cystadenoma	256[c]	Successful	None[d]
21	38	158	Pelvic Pain/Mass	RSO	Serous Cystadenoma	8	Successful	None
22	42	112	Pelvic Pain/Mass	BSO	Paratubal Cyst	L-28/R-35	Successful	None
23	34	337	Complex Pelvic Mass	L Cyst	Benign Cystic Teratoma	22.4[b]	Successful	None[d]
24	60	197	Postmenopausal Mass	LSO	Hydrosalpinx	33.5	Successful	None
25	45	207	Metastatic Breast CA	BSO	Normal T/O	38.4	Successful	None
26	25	150	Chronic PID	BS	Hydrosalpinx	14.5	Successful	None[d]
27	55	227	Postmenopausal Mass	BSO	Serous Cystadenoma	L-113/R-6[b]	Successful	None
28	46	158	Leiomyoma Uteri	BSO w/VH	Normal T/O	22.4	Successful	None[d]
29	39	200	Pelvic Pain/Mass	RSO	Hem. C-L Cyst	17.5	Successful	None
30	40	140	Pelvic Pain/Mass	RSO	Hydrosalpinx	12	Successful	None
31	53	176	Pelvic Pain/Mass	BSO	Serous Cystadenoma	R-19.9/L-16.6	Successful	None[d]
32	40	N/A	Acute Pelvic Pain	LSO	Torsed Hydrosalpinx	121	Failed	LTF
33	48	194	Familial Ovarian CA	BSO	Normal T/O	22.3	Successful	None[d]
34	17	166	Pelvic Pain/Mass	L Cyst	Benign Cystic Teratoma	9.4	Successful	None
35	50	148	Pelvic Pain/Mass	BSO	Hem. C-L Cyst	33.5	Successful	PUR[d]
36	38	173	Pelvic Pain/Mass	RO	C-L Cyst	10	Successful	None
37	54	130	Post menopausal Mass	LSO	Serous Cystadenoma	68.2[b]	Successful	None
38	69	227	Postmenopausal Mass	BSO	Lipoleiomyoma	R-3.5L-64.7	Failed	None

Table 1 continued on next page.

Table 1. Continued
Procedures and Outcomes

Patient	Age	Weight	Clinical Indication[a]	Procedure[a]	Pathology	Tissue Volume (cc)	Outcome	Complications
39	54	240	Postmenopausal Mass	RO	Benign Cystic Teratoma	351[b]	Failed	None
40	45	149	L Pelvic Mass	LO	Benign Cystic Teratoma	22.4[b]	Success	None
41	42	154	Bil Pelvic Masses	Bil Cyst	Benign Cystic Teratoma	R-28.1/L-7	Failed	None
42	43	147	L Pelvic Mass	L Cyst	L Peritubal Cyst	8.2	Success	None

[a]LSO=left salpingo-oophorectomy, RSO=right salpingo-oophorectomy, BSO=bilateral salpingo-oophorectomy, L=Cyst left cystectomy, C-L corpus luteum, LTF=lost to follow-up, SWI=superficial wound infection, VH=vaginal hysterectomy, T/O=tube and ovary, TOA=tubo-ovarian abscess, N/A not available, PUR=postop urinary retention, Hem=hemorrhagic, Hyst=hysterectomy, CA=cancer.

[b]Mass aspirated.

[c]Mass morcellated.

[d]Long-term follow-up—6 months to 5 years.

4. Schellpfeffer MA. 2005 AAGL Annual Meeting Video Presentation: Schellpfeffer Forceps-A laparoscopic tissue retrieval device. *J Min Inv Surg*. 2005;12(5) Suppl:S120.

5. Gilstrap LC, Cunningham FG, VanDorsten JP. *Operative Obstetrics*. 2nd ed. Chapter 6 p. 89-122 McGraw Hill New York; 2002.

6. Brown CT, Hindley RG, Rimington PD, Barber NJ. The Eastbourne Extraction: forceps removal of large laparoscopic nephrectomy specimens without morcellation. *Surg Laparosc Endosc Percut Tech*. 2009;19(1):82-83.

7. Quasarano RT, Kashef M, Sherman SJ, Hagglund KH. Complications of gynecologic laparoscopy. *J Am Assoc Gyn Laparosc*. 1999;6(3):317-321.

8. Litta P, Sacco G, Tsiroglou D, Cosmi E, Ciavattini A. Is antibiotic prophylaxis necessary in elective laparoscopic surgery for benign gynecologic conditions? *OB/GYN Invest*. 2010;69:136-139.

9. Voitk AJ, Tsao SGS. The umbilicus in laparoscopic surgery. *Surg Endosc*. 2001;15:878-881.

10. Kadar N, Reich H, Siu CY, Manko GF, Gimpelson R. Incisional hernias after major laparoscopic gynecologic procedures. *AJOG*. 1993;168(5):1493-1495.