

Unexpected Hemodynamic Deterioration and Mitral Regurgitation Due to a Tissue Stabilizer during Left Anterior Descending Coronary Anastomosis in Off-pump Coronary Artery Bypass Graft Surgery

Sakura Kinjo, MD,¹ Joho Tokumine, MD, PhD,¹ Kazuhiro Sugahara, MD, PhD,¹ Manabu Kakinohana, MD, PhD,¹ Kiyoshi Iha, MD, PhD,³ Hideyo Matsuda, MT,⁴ Mitsuru Akasaki, MD,⁵ and Satoshi Yamashiro, MD, PhD²

We have experienced three rare cases of hemodynamic deterioration and transient mitral regurgitation (MR) induced by a suction-type tissue stabilizer during the left internal thoracic artery (LITA)-to-LAD (left anterior descending) coronary artery anastomosis.

Transesophageal echocardiogram (TEE) showed new or worsening MR during the placement of a tissue stabilizer. In all three cases, the positioning of the stabilizer was difficult to secure a good surgical field, because the LAD coronary artery migrated deep into the myocardium. This anatomical variation seemed to require a stronger fixation of the stabilizer to the heart.

We concluded that compression of the left ventricular (LV) wall may have possibly caused morphologic changes of the LV and the distortion of the annulus of the mitral valve. These changes are thought to have caused decreased LV filling and the MR, which led to an unexpected hemodynamic deterioration. (Ann Thorac Cardiovasc Surg 2005; 11: 324–8)

Key words: off-pump coronary artery bypass graft, mitral regurgitation, tissue stabilizer

Introduction

Off-pump coronary artery bypass graft (OP-CABG) has recently gained popularity and has been performed in many facilities mainly due to the development of tissue stabilizers. Anesthetic management of OP-CABG is challenging because of hemodynamic instability during the procedure, and the precise mechanisms of hemodynamic variability during OP-CABG are still not clearly understood. It has been postulated that the decrease in cardiac output by heart positioning, or myocardial ischemia during the clamping of the coronary lesion contributes to

From ¹Department of Anesthesiology and ²Second Department of Surgery, Faculty of Medicine, University of the Ryukyus, Departments of ³Cardiovascular Surgery and ⁴Medical Laboratory, Chubu Tokushukai Hospital, and ⁵Department of Cardiovascular Surgery, Nambu Tokushukai Hospital, Okinawa, Japan.

Received March 7, 2005; accepted for publication April 2, 2005. Address reprint requests to Joho Tokumine, MD, PhD: Department of Anesthesiology, Faculty of Medicine, University of the Ryukyus, 207 Uehara, Nishihara, Okinawa 903-0215, Japan. Presented in part at The 51th Annual Meeting of Japanese Society of Anesthesiologists, Nagoya, Japan, May 27, 2004.

such variability.¹⁾ Anastomosis on the anterior wall (CABG to LAD) causes relatively less hemodynamic compromise compared to the grafting of other lesions, such as the left circumflex (LCX) or the right coronary artery (RCA).^{2,3)} Volume loading, the usage of vasopressors and Trendelenburg positioning usually correct hemodynamic instability, although in severe cases, the right ventricle assist device⁴⁾ or snaring of the inferior vena cava^{5,6)} have been proposed.

Recently, we have experienced three cases of transient mitral regurgitation (MR) induced by a suction-type tissue stabilizer during the left internal thoracic artery (LITA)-to-LAD anastomosis in OP-CABG. Transient MR due to the compression of the left ventricular (LV) wall during OP-CABG has yet to be reported.

Case 1

A seventy-five-year-old woman was admitted for a three-month history of progressively worsening dyspnea on exertion. Her past medical history was only significant for diet-controlled type II diabetes. ECG showed ST depression in leads II, III and aV_f. Coronary angiography

revealed the total occlusion of segment 1 and 99% stenosis of segment 7 with depressed ventricular function (ejection fraction of 41%). There were slight MR, mild tricuspid regurgitation and moderate diffuse hypokinesis of the LV wall on echocardiography.

She was scheduled for OP-CABG. A pulmonary artery catheter and an intra aortic balloon pump (IABP) were placed prior to the procedure. She was premedicated with morphine 7.5 mg I.M., and anesthesia was induced with propofol infusion 7 mg/kg/hr, ketamine 1 mg/kg/hr and a bolus of fentanyl 5 µg/kg. Vecuronium was used as a paralytic agent. Transesophageal echocardiography (TEE) were performed intra-operatively. The hemodynamics were relatively stable until the application of the tissue stabilizer (The Donut Heart Stabilizer System (Fukuda Denshi Co., Ltd., Tokyo, Japan)) to anastomose segment 7 of the LAD. The positioning and the placement of the stabilizer to the cardiac surface was difficult and took about 10 minutes. The LAD was embedded in the myocardium, which required technical challenges to secure a good surgical field. Blood pressure (BP) fluctuated, and dropped from 110/40 mmHg to 60/30 mmHg after the final positioning of the tissue stabilizer. The cardiac index (CI) also dropped from 2.7 L/min/m² to 1.3 L/min/m². Rapid infusion of fluids and inotropic support including norepinephrine, dopamine and dobutamine, were required for hemodynamic support. Concomitant unexpected elevations in the mean pulmonary arterial pressure (mPAP) from 15 mmHg to 30 mmHg, and in the central venous pressure (CVP) from 7 mmHg to 16 mmHg were recognized without any changes on the ECG (I, II, III and modified CR5). The procedure was halted until hemodynamic stability was restored. TEE was utilized to evaluate the cardiac performance, and showed worsening of the MR from slight to moderate (Figs. 1A and 1B). The presence of MR through the posterior commissure was also observed in addition to the preexisting MR through the anterior commissure (Fig. 1C). Proceeding with the intended anastomosis, the target coronary artery was clamped by applying snares proximal to and distal to the anastomotic sites using an Elastic A needle (Matsuda Ika Kogyo Co., Ltd., Tokyo, Japan). The degree of MR did not change during this snaring and there were no remarkable changes in the vital signs, the ECG, or the TEE.

Immediately after removal of the tissue stabilizer following the LITA-to-LAD anastomosis, the degree of MR improved from moderate to slight and the hemodynamics normalized (Fig. 1D). The other anastomoses (right internal thoracic artery to the RCA and aorta-to-LCX

using saphenous vein graft (SVG)) were performed subsequently encountering the generally expected circulatory variability. The MR was unchanged during these anastomoses.

Case 2

A sixty-nine-year old man was scheduled for OP-CABG for angina pectoris. Past medical history was significant for hypertension and type II diabetes. He was premedicated with morphine 10 mg and atropine 0.5 mg I.M. Anesthesia was induced with propofol 10 mg/kg/hr, ketamine 1 mg/kg/hr and a bolus of fentanyl 300 µg. Muscle paralysis was achieved with vecuronium. Anesthesia was maintained with propofol, fentanyl and ketamine infusions. Prior to the placement of the tissue stabilizer to segment 7 of the LAD, his vital signs were stable. There was no MR observed with the TEE. However, after the stabilizer placement (The Donut Heart Stabilizer System (Fukuda Denshi Co., Ltd., Tokyo, Japan)), the hemodynamic parameters showed signs of compromise (BP: 135/70 mmHg to 110/60 mmHg; HR: 65 bpm to 80 bpm; CI: 2.7 L/min/m² to 0.7 L/min/m²; CVP: 6 mmHg to 15 mmHg; mPAP: 11 mmHg to 27 mmHg). Subsequently, the patient required a rapid fluid infusion as well as the administration of phenylephrine, and the TEE showed a new MR. As in case 1, the LAD coronary artery was embedded in the myocardium. The attachment of the heart stabilizer at the cardiac surface was re-adjusted multiple times. The detachment of the stabilizer each time made the MR disappear immediately. There was no optimal position of the stabilizer where the hemodynamic deterioration and the MR resolved. Although there were no ECG changes noted, the concerns of possible myocardial ischemia prompted the placement of a temporary coronary shunt. The degree of MR was not affected by this shunt placement. The detachment of the stabilizer following the LAD anastomosis made the MR disappear instantaneously. We proceeded with the other intended anastomosis of the aorta-to-SVG-to-LAD (on Segment 8), and the usual hemodynamic support was provided using norepinephrine. No MR was recognized during this anastomosis. The postoperative course was uneventful and the patient continued to be free of MR.

Case 3

A sixty-eight-year old woman underwent OP-CABG for unstable angina. Her past medical history included hypertension and PTCA 2 years earlier. ECG showed HR 52 bpm, QS pattern in V₁ and V₂, and negative T waves in

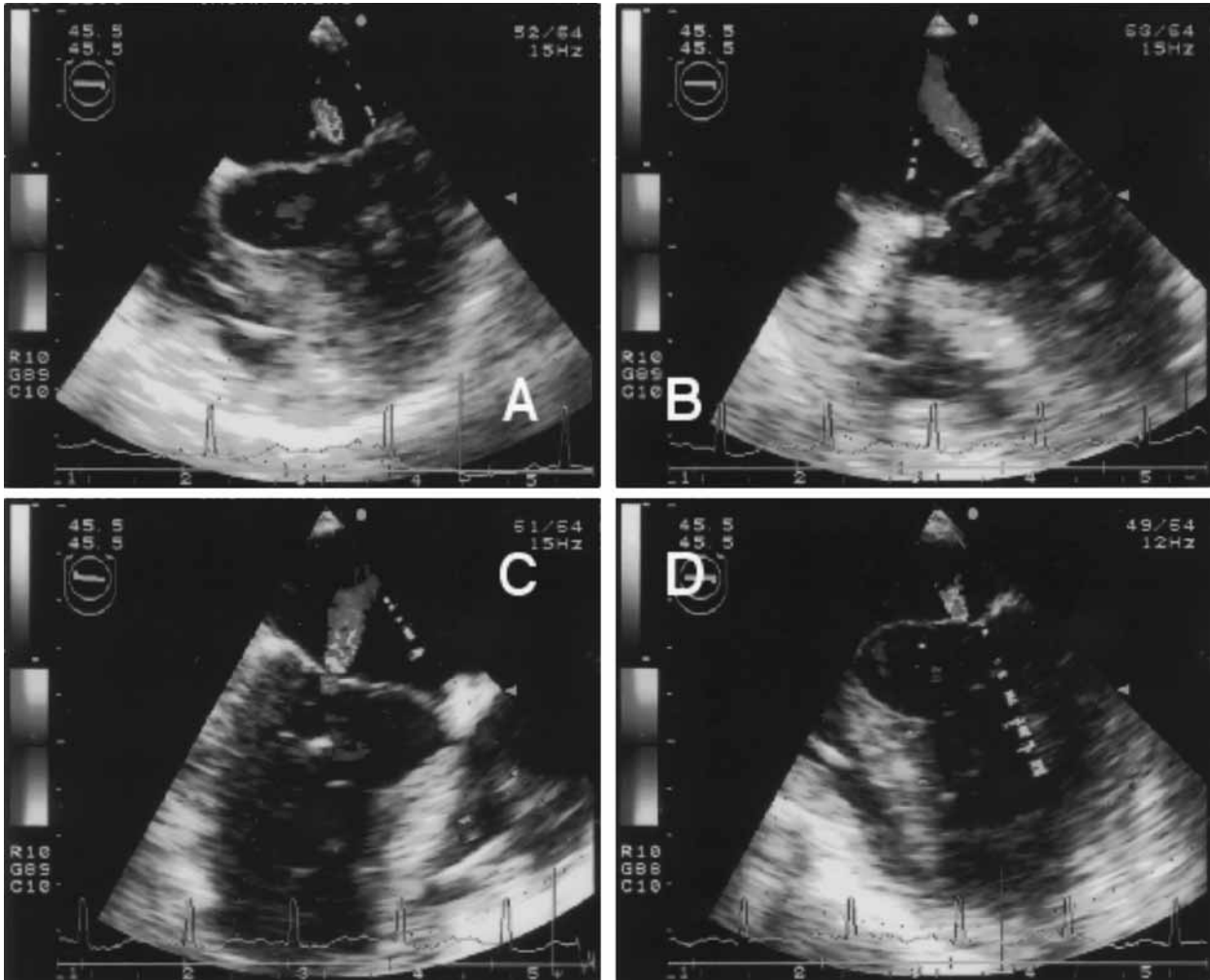


Fig. 1.

- A:** Pre-CABG 3-chamber view shows slight MR.
- B:** Exacerbation of MR (moderate) during the placement of a tissue stabilizer.
- C:** MR through posterior commissure during the placement of a tissue stabilizer.
- D:** Post-CABG 3-chamber view shows slight MR.

V₂-V₆. Echocardiography revealed mild MR, apical akinesis, and an ejection fraction of 64%. Coronary angiography showed 75% stenosis of segment 6, and 90% stenosis of segment 13. Morphine 5 mg I.M. was used for pre-medication. Inhalation induction was conducted using sevoflurane, and tracheal intubation was facilitated with vecuronium. Anesthesia was maintained with sevoflurane and continuous infusion of fentanyl. A central venous catheter was placed through the right internal jugular vein, and a left atrial pressure (LAP) line was inserted via the right upper pulmonary vein prior to the initiation of the anastomosis.

The tissue stabilizer (Octopus System II (Medtronic,

Inc., Minneapolis, MN, USA)) was placed for the LITA-to-LAD grafting. As in cases 1 and 2, the surgeon faced technical difficulties in placing the tissue stabilizer secondary to the embedded LAD. The attachment of the heart stabilizer at the cardiac surface was re-adjusted multiple times. We noticed the worsening of MR from mild to severe on the TEE. The detachment of the stabilizer each time made the MR decrease to mild immediately. We also noticed abrupt increase in LAP from 10 mmHg to 16 mmHg during the stabilizer fixation to the myocardium and returning to its base line after removal of stabilizer. This phenomenon was seen repeatedly during the adjustment of the stabilizer (Fig. 2).

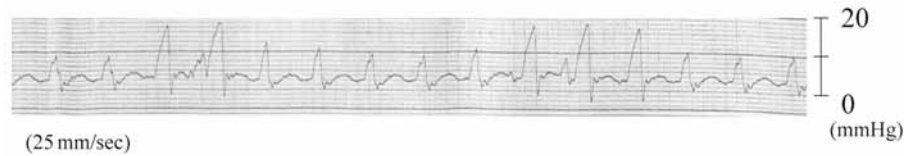


Fig. 2. Transient elevation of LAP during the placement of a tissue stabilizer. LAP returned to its baseline after the detachment of stabilizer. This phenomenon was seen repeatedly.

During this period, the BP dropped from 110/70 mmHg to 70/40 mmHg, and the CVP increased from 5 mmHg to 13 mmHg. The snare was yet to be applied for the clamping of the target coronary artery. The patient required a rapid infusion of fluids and the continuous administration of norepinephrine to maintain BP.

Following the completion of the anastomosis and the removal of the tissue stabilizer, the degree of MR decreased to pre-procedure levels, and the LAP normalized. Subsequently, the aorta and the LCX were anastomosed using a SVG. Although a small dose of epinephrine was still required for hemodynamic support, there was no worsening of the MR and there were no ECG changes.

Discussion

We have encountered three cases of hemodynamic deterioration with the new appearance or the exacerbation of existing MR during LAD anastomosis, which required intensive hemodynamic management. Hemodynamic changes in OP-CABG can be caused by different mechanisms such as myocardial ischemia, mechanical compression, or a combination of both.^{1,3} We observed significant reductions in the arterial pressure and in the CI as well as elevations in mPAP during LITA-to-LAD grafting associated with new or worsening MR. Furthermore, the MR seems to have been induced by the direct pressure of the stabilizer device on the cardiac surface and causing unintended compression of the LV wall. In case 1, we found the appearance of MR through the posterior commissure only after stabilizer placement, in addition to the preexisting MR via anterior commissure. This observation suggests the presence of a distinct pathophysiology, rather than a simple deterioration of the preexisting MR. Even though the possibility of ischemic LV dysfunction was not completely excluded due to limitations of monitoring with ECG and TEE, this morphologically distinct MR was transient, reversible, and was unrelated to the blood supply, suggesting the low possibility of myocardial ischemia. In this case, pre-operative cardiac

reserve was limited, so that even a moderate MR was probably severe enough to cause hemodynamic changes. In case 2, the placement of the coronary shunt did not help to correct the degree of the new MR. However, as with case 1, the removal of the stabilizer seemed to reverse the MR completely and permanently. In case 3, there was transient increase in LAP during the stabilizer fixation to the myocardium and it returned to base line when the stabilizer was removed. This phenomenon was seen repeatedly during adjustment of the stabilizer. None of three cases required mitral valve repair or replacement since the exacerbation of the MR was only transient. We hypothesize that the hemodynamic derangements and the MR were due to the direct compression effect by the placement of the stabilizer device. The compression may have caused distortion of papillary muscles and elongation of chordae, which lead to displacement of mitral leaflets. Furthermore, in all three cases, the positioning of the stabilizer was difficult in securing a good surgical field, because the LAD was embedded deep into the myocardium.

Two types of tissue stabilizers (suction and compression types) have been used for OP-CABG.² The Donut Heart Stabilizer System (Fukuda Denshi Co., Ltd., Tokyo, Japan), which ranks third in usage in Japan, was applied in cases 1 and 2. This instrument consists of a double-bottomed silicone rubber dome and a suction tube. Takahashi et al.^{7,8} has reported good surgical results for beating heart surgery using this instrument. The Octopus System II (Medtronic, Inc., Minneapolis, MN, USA) was used in case 3. Both the Donut and the Octopus are suction-type stabilizers. In this report, two different tissue stabilizing devices were employed, thereby negating the cause to be a specific stabilizing device.

Mathison et al.⁹ reported hemodynamic changes during OP-CABG using the Octopus System II stabilizer. They suggested the positioning of the LAD anastomosis showed the least hemodynamic change (decreased stroke volume, increased right atrial pressure and right ventricular end-diastolic pressure as well as LAP and left end-diastolic pressure), although they observed the compres-

sion of both ventricles on the TEE. MR was not seen unlike in our cases, and therefore they concluded that the increased right heart pressure was caused by the compression effect of the right ventricle. Since the compression of the right heart was not obvious on the TEE in our cases, we hypothesize that the cause of the hemodynamic changes in the cases we report here are pathologically distinct from that reported by Mathison.⁹⁾

Immobilization of the anastomotic sites was technically difficult in all three cases due to the characteristic embedded coronary arteries. This anatomical variation required a stronger fixation of the stabilizer to the myocardium. The compression of the LV wall may have caused morphologic changes to the LV, the papillary muscle compression and distorted annulus of the mitral valve. These changes could have caused the observed decrease in LV filling and the MR both of which led to an unexpected hemodynamic deterioration.

It needs to be noted that the same surgical group performed cases 1 and 2, but a different group performed case 3 at a separate facility. This suggests that it was neither user-dependent nor dependent on anesthesia modalities.

In summary, we have experienced three rare cases of hemodynamic deterioration with MR during LAD anastomosis in OP-CABG. We conclude that these cases of hemodynamic deterioration and MR were unlikely related to ischemia, but more likely related to compression of the left wall by the tissue stabilizer. In all three cases, the placement of the stabilizer was technically challenging because of anatomically variant embedded coronary artery. These observations suggest that even a suction-type tissue stabilizer can cause a compression effect, which induces transient MR, especially when the LAD coronary migrates into myocardium.

We emphasize that all cardiovascular anesthesiologists and surgeons should be aware of this stabilizer-induced reversible MR during the LAD anastomosis in OP-CABG, as this could be a potential complication leading to a significant hemodynamic deterioration if not recognized.

Acknowledgement

The authors thank Peter Y. Shane, M.D. for reviewing the manuscript.

References

1. Couture P, Denault A, Limoges P, Sheridan P, Babin D, Cartier R. Mechanisms of hemodynamic changes during off-pump coronary artery bypass surgery. *Can J Anaesth* 2002; **49**: 835–49.
2. Mishra M, Malhotra R, Mishra A, Meharwal ZS, Trehan N. Hemodynamic changes during displacement of the beating heart using epicardial stabilization for off-pump coronary artery bypass graft surgery. *J Cardiothorac Vasc Anesth* 2002; **16**: 685–90.
3. Jansen EW, Borst C, Lahpor JR, et al. Coronary artery bypass grafting without cardiopulmonary bypass using the octopus method: results in the first one hundred patients. *J Thorac Cardiovasc Surg* 1998; **116**: 60–7.
4. Mathison M, Buffolo E, Jatene AD, et al. Right heart circulatory support facilitates coronary artery bypass without cardiopulmonary bypass. *Ann Thorac Surg* 2000; **70**: 1083–5.
5. Degenais F, Cartier R. Pulmonary hypertension during beating heart coronary surgery: intermittent inferior vena cava snaring. *Ann Thorac Surg* 1999; **68**: 1094–5.
6. Couture P, Denault AY, Sheridan P, Williams S, Cartier R. Partial inferior vena cava snaring to control ischemic left ventricular dysfunction. *Can J Anaesth* 2003; **50**: 404–10.
7. Takahashi M, Yamaguchi S, Yamamoto S. A new instrument for immobilization and hemostasis during minimally invasive direct coronary artery bypass (“MIDCAB doughnut”): experimental study. *J Card Surg* 1997; **12**: 185–9.
8. Takahashi M, Yamamoto S, Tabata S. Immobilized instrument for minimally invasive direct coronary artery bypass: MIDCAB doughnut. *J Thorac Cardiovasc Surg* 1997; **114**: 680–2.
9. Mathison M, Edgerton JR, Horswell JL, Akin JJ, Mack MJ. Analysis of hemodynamic changes during beating heart surgical procedures. *Ann Thorac Surg* 2000; **70**: 1355–61.