

Contents lists available at [SciVerse ScienceDirect](#)

Sleep Medicine

journal homepage: www.elsevier.com/locate/sleep

Original Article

Delayed emergence of a parkinsonian disorder or dementia in 81% of older males initially diagnosed with idiopathic REM sleep behavior disorder (RBD): 16 year update on a previously reported series

Carlos H. Schenck^{a,*}, Bradley F. Boeve^b, Mark W. Mahowald^c

^a Minnesota Regional Sleep Disorders Center, Departments of Psychiatry, Hennepin County Medical Center and University of Minnesota Medical School, Minneapolis, United States

^b Mayo Clinic for Sleep Medicine, and Department of Neurology, Mayo Clinic, Rochester, Minnesota, United States

^c Minnesota Regional Sleep Disorders Center, Department of Neurology, University of Minnesota Medical School, Minneapolis, United States

ARTICLE INFO

Article history:

Available online xxx

Keywords:

REM sleep behavior disorder

RBD

Parkinson's disease

PD

Dementia with Lewy bodies

Multiple system atrophy

Video-polysomnography

Neuroprotection

ABSTRACT

Objective: To provide a 16 year update from the authors' 1996 report documenting a 38% conversion from idiopathic RBD (iRBD) to a parkinsonian disorder at a mean interval of nearly 13 years after the onset of iRBD in a series of 29 males ≥ 50 years old.

Methods: The methods of evaluation, diagnosis and follow-up were previously described in the 1996 report. All patients had video-polysomnography (vPSG) confirmed RBD.

Results: 80.8% (21/26) of patients who were initially diagnosed with iRBD eventually developed parkinsonism/dementia (three of the original 29 patients were lost to follow-up). The distribution of diagnoses was as follows: $n = 13$, Parkinson's disease (PD); $n = 3$, dementia with Lewy bodies (DLB); $n = 1$, dementia (unspecified; profound); $n = 2$, multiple system atrophy (MSA); $n = 2$, clinically diagnosed Alzheimer's Disease (AD) with autopsy-confirmed combined AD plus Lewy body disease pathology. Among the 21 iRBD "converters," the mean age (\pm SD) of iRBD onset was 57.7 ± 7.7 years; mean age (\pm SD) of parkinsonism/dementia onset was 71.9 ± 6.6 years; and mean interval (\pm SD) from iRBD onset to parkinsonism/dementia onset was 14.2 ± 6.2 years (range: 5–29 years).

Conclusion: The vast majority of men ≥ 50 years old initially diagnosed with iRBD in this study eventually developed a parkinsonian disorder/dementia, often after a prolonged interval from onset of iRBD, with the mean interval being 14 years while the range extended to 29 years. Also, the specificity of iRBD converting to parkinsonism/dementia is striking. These findings carry important clinical and research implications in the convergent fields of sleep medicine, neurology, and neuroscience, and identify an optimal clinical group for conducting prospective research studies utilizing putative neuroprotective agents to delay the emergence of, or halt the progression to, parkinsonism and/or cognitive impairment as manifestations of either PD, DLB or MSA.

© 2012 Elsevier B.V. All rights reserved.

1. Introduction

In 1996, we reported that 38% of a series of 29 males ≥ 50 years old developed a parkinsonian disorder (all presumably with Parkinson's disease [PD]) at a mean interval of nearly 13 years after the onset of idiopathic RBD (iRBD) [1]. In that report, 16 patients with persistent iRBD were last evaluated on average six years from the time of their RBD diagnosis. We now provide a 16 year update from our 1996 report, with the primary focus of this report being the percent of iRBD patients who eventually developed parkinsonism/dementia, the interval from onset of iRBD to onset of parkinsonism/dementia, and the post-mortem neuropathological findings in two cases.

2. Methods

The methods of evaluation and follow-up have previously been described [1]. All patients had video-polysomnography (vPSG) confirmed RBD. Three patients ($n = 1$ with PD; $n = 2$ with dementia with Lewy bodies [DLB]), were subsequently referred to the Mayo Clinic to be managed by one of the authors (BFB) after their neurological disorders had emerged. One patient was lost to follow-up, but his wife was eventually contacted, and she provided information about her husband's dementia, and clinical information from the patient's nursing home physician was reviewed. Another patient developed cerebrovascular disease, and then was lost to follow-up. Two other patients were permanently lost to follow-up, while still diagnosed with iRBD at their last appointment. Therefore, the outcome from 26 of the original 29 iRBD patients [1] will

* Corresponding author. Tel.: +1 612 873 6201; fax: +1 612 904 4207.

E-mail address: schen010@umn.edu (C.H. Schenck).

be reported now. The diagnoses of PD, MSA, and DLB satisfied recognized diagnostic criteria [2–4]. Specifically, clinically definite PD was diagnosed if \geq three of the cardinal features were present (resting tremor, rigidity, bradykinesia, impaired postural reflexes), or if \geq two of the cardinal features were present, provided that one of the first three features displayed asymmetry [2]. For MSA, whereas the definite diagnosis requires neuropathological confirmation, the clinical diagnosis of probable MSA requires the presence of autonomic failure/urinary dysfunction plus poor levodopa responsive parkinsonism or cerebellar ataxia [3]. For DLB, whereas the definite diagnosis requires neuropathological confirmation, the clinical diagnosis of probable DLB requires the presence of dementia. Dementia is defined as “progressive cognitive decline of sufficient magnitude to interfere with normal social or occupational function” and together with \geq two core features (fluctuating cognition with pronounced variations in attention and alertness; recurrent visual hallucinations that are typically well formed and detailed; spontaneous features of parkinsonism), the diagnosis of DLB was confirmed [4]. In the diagnostic classification just described for DLB [4], RBD is considered to be a suggestive diagnostic feature of DLB in the presence of \geq 1 of the core features. Mild Cognitive Impairment (MCI) was not assessed in this study. Females were not included in this study for the sake of homogeneity, since RBD in middle-aged and older adults is strongly male dominant.

3. Results

80.8% (21/26) of patients initially diagnosed with iRBD eventually developed parkinsonism/dementia. Table 1 contains the list of parkinsonism/dementia diagnoses, and the Fig. 1 provides a distribution of time intervals for conversion from iRBD to parkinsonism/dementia. The two patients with MSA had autonomic failure/urinary dysfunction with parkinsonism. One of these patients had persistent hypotension despite vigorous therapy with pressor agents, with his sitting BP commonly being 100/50, and with

Table 1
Eventual parkinsonian disorders/dementia in a series of middle-aged and older males initially diagnosed with idiopathic RBD (iRBD).

N = 13 Parkinson's disease	
N = 3 Dementia with Lewy bodies	
N = 1 Dementia (unspecified; profound)	
N = 2 Multiple system atrophy	
N = 2 Clinically diagnosed Alzheimer's disease with autopsy-confirmed combined Alzheimer's disease plus Lewy body disease pathology	
N = 21 iRBD “converters”	
Mean age (\pm SD), years, iRBD onset	57.7 \pm 7.7
Mean age (\pm SD), years, parkinsonism/dementia onset	71.9 \pm 6.6
Mean interval (\pm SD), years, iRBD onset to parkinsonism/dementia onset (range: 5–29 years)	14.2 \pm 6.2

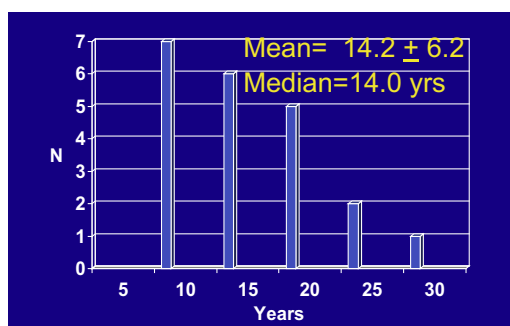


Fig. 1. Interval from onset of RBD to onset of parkinsonism/dementia ($n = 21$).

orthostatic drops down to 80/40. One patient developed fulminant-onset DLB when his wife noticed cognitive decline together with the onset of non-distressing (to the patient) visual hallucinations. He would comment to his wife with a puzzled tone, “Why was our son-in-law in the bathroom with me for 2 h while I was taking a shower? He was just standing there the whole time and did not say a word. He never called us to say he was coming over and no one heard the doorbell ring, but he was in the bathroom with me.” This is clearly not a Schizophrenic or primary psychiatric psychotic experience, but rather a typical DLB experience.

The patient with unspecified dementia had been lost to follow-up while still diagnosed with iRBD, but his wife later reported eventual dementia with rapid progression to profound dementia, in which he no longer recognized his wife and was confined to a nursing home. The wife could not recall the presence of visual hallucinations. Parkinsonism was not noted by the attending physician at the nursing home.

Two patients, who developed clinically-diagnosed Alzheimer's dementia (AD), without evidence of Parkinsonism, after the onset of iRBD, underwent neuropathological examination following their deaths. One case has previously been described [5, p. 116–23, 6,7], with histopathological findings confirming both the diagnosis of AD (neuropil threads, neurofibrillary tangles, and neuritic degenerative plaques being amply present) and LB disease (Lewy body inclusions were unequivocally present, and were most common within the limbic region; entorhinal cortex, but sparing Ammon's horn, the cortical division of the amygdaloid complex, and deeper layers of the cingulate gyrus). Histologic confirmation of brainstem LB neuronal degeneration was not possible in this case, since the brainstem had previously been used for specialized histochemical analysis, as reported [6]. However, cases with cortical LBs, but no brainstem LBs are distinctly uncommon [8]. This case was initially classified as representing the “Lewy body variant of Alzheimer's disease”, but would be characterized using updated neuropathologic criteria as a high likelihood Alzheimer's disease [9] plus limbic-predominant Lewy body disease [10].

The neuropathological findings in the second case are described below; this case would also be characterized as high likelihood Alzheimer's disease [9] plus limbic-predominant Lewy body disease [10].

- Hippocampus: moderate involvement with senile plaques and neurofibrillary tangles (NFT) in CA1 and subiculum, and mild neuronal loss. In CA2–4, occasional NFT, moderate numbers of senile plaques and moderate neuronal loss and astrocytosis.
- Entorhinal cortex, parahippocampal, fusiform and inferior temporal gyri: moderate-severe involvement by NFT, with moderate-severe involvement by senile plaques. There was mild neuronal loss—temporal cortex and occasional LBs in neurons of the parahippocampal gyrus.
- Amygdala: frequent senile plaques and NFT in the pyriform cortex, with frequent NFT and moderate numbers of senile plaques in the amygdala. LB inclusions are present in both areas.
- Pyriform cortex: amyloid angiopathy, and moderate neuronal loss in both the pyriform cortex and amygdala.
- Frontal cortex: moderate numbers of plaques and NFT with mild neuronal loss.
- Cerebral cortex: amyloid angiopathy (diffuse finding).
- Parietal/occipital lobes (only H & E staining): moderate number of senile plaques; mild neuronal loss.
- Parietal cortex: moderate number of NFT.
- Occipital cortex: no obvious tangles.
- Striatum: moderate neuronal loss in nucleus basalis, with occ. NFT. LB inclusions: not evident. Remainder of striatum: unremarkable.
- Substantia Nigra: mild neuronal loss with occ. LBs.

- Locus Ceruleus: moderately severe neuronal loss, without LBs or NFT.
- Dorsal Raphe: rare LBs and rare NFT.
- Dorsal motor nuclei of Vagus nerve: no LBs.
- Remainder of Medulla: unremarkable.
- Cerebellum: amyloid angiopathy.

Four iRBD patients died from non-neurological diseases and one iRBD patient continues to be followed. Mini-Mental State Examination (MMSE) [11] scores in all iRBD patients ranged from 27 to 30 (normal range). The four deceased iRBD patients had iRBD duration ranging from 18 to 33 years at the time of death. The one iRBD patient who is still alive and being followed has a 53 year history of iRBD. He is currently 77 years old and his clinical history has been described [5, p. 91–3], in which he was a childhood sleepwalker without associated dreaming, and then recurrent, longstanding dream-enactment emerged at 24 years old, often with prominent vestibular activation: “accelerated motion on an inclined plane,” such as a car going downhill at very fast speeds, a train speeding around a bend, a car spinning out of control, and this dream-enacting sequence would culminate in his jumping out of the car or train to save himself, when in fact he had just jumped out of bed. The patient recently described a break-through RBD episode occurring six nights after he reduced his bedtime clonazepam dose from 0.625 to 0.5 mg: “I was lying at the back of a flatbed truck that was accelerating towards a tree, and I was trying to make the truck decelerate, but when it came close to hitting the tree, I jumped out of the truck, and then woke up sitting in bed with all my bedcovers wrapped around me.” No further episodes occurred after he increased the clonazepam dose back to 0.625 mg. Therefore, his RBD remains active, necessitating nightly therapy with the proper dose of clonazepam. This patient also described a long history of sleep paralysis (SP), with eventual spontaneous cessation, but without cataplexy or excessive daytime sleepiness. He described his recurrent SP episodes as being associated with “an intense feeling while being in a dreamy state; it was hard work to stop it.”

Finally, as previously reported [1], 89% (24/27) of treated patients (both iRBD and parkinsonian patients) responded substantially or fully to bedtime therapy of their RBD with clonazepam.

4. Discussion

The main findings from this study of men ≥ 50 years, initially diagnosed with iRBD at the Minnesota Regional Sleep Disorders Center, is that the vast majority (80.8%) eventually developed a parkinsonian disorder/dementia, and often with a prolonged interval from onset of RBD to delayed emergence of parkinsonism/dementia, with the mean interval being 14 years and the range extending to 29 years. Also, the specificity of the RBD-parkinsonism/dementia association is striking, as only one patient from the original series of 29 patients (with two others lost to follow-up while still diagnosed with iRBD) was diagnosed with a different neurological disorder (cerebrovascular disorder) and he then was lost to follow-up. Even though the one remaining iRBD patient who is being followed has had iRBD for 53 years, he most likely has not outlived his risk period for conversion to parkinsonism/dementia, given the recent report on how RBD can precede other aspects of synucleinopathies by up to 50 years [12]. Also, this patient most likely has LB disease, since the only two reported cases of iRBD, without dementia or parkinsonism, undergoing post-mortem histopathological examination had identified LB disease as a purely histological finding [13,14]. The first case involved an 84 year old Japanese man with a 20 year history of PSG-confirmed RBD who demonstrated marked decrease of pigmented monoaminergic neurons in the Locus Ceruleus (LC) and Substantia Nigra

(SN) [13]. The second case involved a 72 year old Caucasian man with a 15 year history of PSG-confirmed RBD who demonstrated brainstem-predominant LB disease, including involvement of the LC and SN with LBs but without significant neuronal loss, in contrast to the previous case [14]. The authors of the latter report commented that “since symptomatology in LB disease reflects neuronal loss more so than the presence of LBs and LNs (Lewy neurites) [15], the findings in this case argue against RBD reflecting degeneration in the SN, LC and RN (Raphe nucleus)” [14].

While there is current debate on how many Lewy bodies and over which topography are required, and on how many and over which topography are Lewy neurites required, for the histopathologic diagnosis of Lewy body disease (LBD) or Lewy related pathology (LRP), in the vast majority of cases, there are sufficient numbers of LB and LN that the diagnosis is clear. Most neuropathologists characterize the topography of LBD as brainstem-predominant, limbic-predominant or transitional LBD, or neocortical-predominant, or diffuse LBD according to Kosaka et al. [16,17], or they follow the Braak staging system and classify cases along the Stage 1–6 continuum according to Braak et al. [18]. When LBD is clearly present histopathologically, but no neurologic signs or symptoms were present during the life of the patient, this is known as “incidental LBD” [19–21], “presymptomatic LBD” or “preclinical Parkinson’s disease,” or “premotor Parkinson’s disease” [22,23], among other terms. The analogy is similar to Alzheimer’s disease when no cognitive symptoms are present, but ample neuritic plaques and neurofibrillary tangles are present at post-mortem histopathologic examination [24,25]. The underlying presumption is that if any neurologically asymptomatic individual with LBD or AD pathology had lived long enough, obvious clinical features of cognitive impairment and/or parkinsonism would have developed. These diagnoses and concepts are well-established in the neurodegenerative disease field.

The patient who developed rapidly progressive and profound dementia, classified as unspecified in Table 1, given the lack of sufficient available clinical information, most likely had DLB, given published findings that dementia occurring in the context of RBD is most likely DLB and not AD [26,27].

The striking finding from this study and from studies by the Barcelona and Montreal groups [28,29] is that iRBD in middle aged and older adults commonly heralds future parkinsonism. iRBD thus compromises an optimal clinical group for conducting prospective research studies utilizing putative neuroprotective agents to delay the emergence of, or halt the progression to parkinsonism and/or cognitive impairment as manifestations of either PD, DLB or MSA. Since the intracellular inclusions in these disorders involve abnormal aggregation of the protein α -synuclein, these disorders are collectively termed “the synucleinopathies.” These disorders, for reasons that are not yet known, reflect the phenomenon of “selective vulnerability” whereby certain structures are affected by α -synuclein aggregation, while many other structures are spared. The nigrostriatal system is typically affected early in the synucleinopathies, including many cases that only manifest initially as iRBD. A critical issue for planning for disease-modifying therapies focusing on iRBD is identifying one or more biomarkers, and fortunately, some key biomarkers have emerged that are promising for use in neuroprotective trials.

DAT (dopamine transporter) scan images of the brain using SPECT (single photon emission computed tomography) after injection of Ioflupane that has high binding affinity for presynaptic DATs, particularly in the striatum, can be used as a biomarker of neuroprotection in studies with iRBD patients, based on the findings of Iranzo et al. [30]. Their data suggest that iRBD patients with reduced nigrostriatal uptake on DAT scans are at short term risk (<5 years) for developing clinical features of parkinsonism and/or cognitive impairment. Predictors of imminent parkinsonism in

newly diagnosed iRBD patients, as described in the aforementioned study, which also identified SN hyperchogenicity on transcranial sonography as a risk marker of synucleinopathy [30], and in another recent study by Postuma et al. [31] that identified olfaction and color vision dysfunction as other risk markers, offer the hope that the timeline of neuroprotective studies can be relatively short, i.e. five years. Furthermore, in iRBD patients, there is progressive longitudinal decrease of DAT uptake in the putamen [32]. These studies should help propel the identification of effective neuroprotective agent(s) that can be utilized in such studies. A main concern for any neuroprotection study involving iRBD patients is enrolling too many patients who either do not have an underlying neurodegenerative disorder, or who are too early in their disease that they will not show cognitive or motor signs for 10–20 years. Therefore, DAT scans should be used at screening so that any iRBD patients with abnormal findings can be enrolled, as they are most likely to have an underlying disease and convert to parkinsonism and/or cognitive impairment over a five year span. DAT scans should be repeated yearly, or at least after three to five years to gain insights about the rate of change. The most obvious clinical endpoint for neuroprotective trials in iRBD would be the time to conversion from iRBD to a more overt neurodegenerative disorder such as PD, DLB or MSA.

From a clinical patient management perspective, we do not recommend the routine clinical use of DAT scans or other expensive tools that should be reserved for research purposes to characterize iRBD subjects over time, and better understand the natural history while we wait for effective disease-modifying therapies to be developed. We endorse the approach utilized by many sleep medicine clinicians to have their iRBD patients followed longitudinally by a neurologist, and the neurologic examination can eventually reveal subtle changes in olfaction, motor or cognitive functioning, suggesting a transition towards clinical dementia and/or parkinsonism.

The topic of iRBD as the common herald, or initial manifestation of a synucleinopathy has received considerable recent attention [33,34–39]. The broader associations of RBD and synucleinopathies, such as PD emerging prior to or concurrent with the emergence of RBD, and the almost 100% link of MSA with RBD, and approximately 50% link of PD with RBD, have also received considerable attention [33,34–40,41,42]. As previously discussed, it appears that the site and progression of the lesion(s) responsible for synucleinopathies can account for whether RBD emerges prior to, concurrent with, or subsequent to the emergence of PD and other synucleinopathies [42].

Besides important research implications, our findings carry substantial clinical implications. Middle-aged and older patients diagnosed with iRBD should be informed along with their spouses and/or other family members about the increased risk for future parkinsonism/dementia. Considerable clinical sensitivity needs to be exercised in this area, with an appreciation for how much detail each patient is interested in and/or capable of absorbing. This situation is similar to possessing a genetic mutation with incomplete penetrance, and clinicians should counsel their patients and their relatives accordingly. Also, the nature and range of the longitudinal course of PD, DLB, MSA need to be specified, e.g. the signs and symptoms. For example, one author [CHS] has encountered patients who believed that PD was a rapidly fatal illness. The primary care physician also needs to be informed, since yearly neurologic exams, focusing on cognitive functioning and the motor system, need to be strongly recommended. Failure to alert patients and spouses about the increased risk for these neurologic conditions associated with iRBD could pose major clinical problems if the patient becomes aware of these associations through the Internet or some other source, including word of mouth. Besides the identification of an at-risk group for parkinsonism/dementia, an important

beneficial aspect of diagnosing RBD remains the robust and highly effective response to pharmacotherapy, particularly with clonazepam and melatonin [43], given the major risk for injuries, including life-threatening injuries often present in RBD [44].

Conflict of Interest

The ICMJE Uniform Disclosure Form for Potential Conflicts of Interest associated with this article can be viewed by clicking on the following link: <http://dx.doi.org/10.1016/j.sleep.2012.10.009>.

References

- [1] Schenck CH, Bundlie SR, Mahowald MW. Delayed emergence of a parkinsonian disorder in 38% of 29 older men initially diagnosed with idiopathic rapid eye movement sleep behavior disorder. *Neurology* 1996;46:388–93.
- [2] Calne DB, Snow BJ, Lee C. Criteria for diagnosing Parkinson's disease. *Ann Neurol* 1992;32(Suppl.):125–7.
- [3] Gilman S, Low PA, Quinn N, et al. Consensus statement on the diagnosis of multiple system atrophy. American Autonomic Society and American Academy of Neurology. *Clin Auton Res* 1998;8:359–62.
- [4] McKeith IG, Dickson DW, Lowe J, Emre M, O'Brien JT, Feldman H, et al. Diagnosis and management of dementia with Lewy bodies: third report of the DLB Consortium. *Neurology* 2005;65:1863–72.
- [5] Schenck CH. Paradox lost: midnight in the battleground of sleep and dreams. Minneapolis (MN): Extreme-Nights, LLC; 2005. <www.parasomnias-rbd.com>.
- [6] Schenck CH, Garcia-Rill E, Skinner RD, Anderson ML, Mahowald MW. A case of REM sleep behavior disorder with autopsy-confirmed Alzheimer's disease: postmortem brain stem histochemical analyses. *Biol Psychiatry* 1996;40:422–5.
- [7] Schenck CH, Mahowald MW, Anderson ML, Silber MH, Boeve BF, Parisi JE. Lewy body variant of Alzheimer's disease (AD) identified by postmortem ubiquitin staining in a previously reported case of AD associated with REM sleep behavior disorder. *Biol Psychiatry* 1997;42:527–8.
- [8] Ala TA, Yang K-H, Sung JH, Frey WH. Hallucinations and signs of parkinsonism help distinguish patients with dementia and cortical Lewy bodies from patients with Alzheimer's disease at presentation: a clinicopathological study. *J Neurol Neurosurg Psychiatry* 1997;6:16–21.
- [9] Hyman BT, Trojanowski JQ. Consensus recommendations for the postmortem diagnosis of Alzheimer disease from the National Institute on Aging and the Reagan Institute Working Group on diagnostic criteria for the neuropathological assessment of Alzheimer disease. *J Neuropathol Exp Neurol* 1997;56:1095–7.
- [10] Fujishiro H, Ferman TJ, Boeve BF, et al. Validation of the neuropathologic criteria of the third consortium for dementia with Lewy bodies for prospectively diagnosed cases. *J Neuropathol Exp Neurol* 2008;67:649–56.
- [11] Folstein MF, Folstein S, McHugh P. Mini-Mental State: a practical method for grading the cognitive state of patients for clinicians. *J Psychiatr Res* 1975;12:189–98.
- [12] Claassen DO, Josephs KA, Ahlskog JE, Silber MH, Tippmann-Peikert M, Boeve BF. REM sleep behavior disorder preceding other aspects of synucleinopathies by up to half a century. *Neurology* 2010;75:494–9.
- [13] Uchiyama M, Isse K, Tanaka K, Yokota N, Hamamoto M, Aida S, et al. Incidental Lewy body disease in a patient with REM sleep behavior disorder. *Neurology* 1995;45:709–12.
- [14] Boeve BF, Dickson DW, Olson EJ, Shepard JW, Silber MH, Ferman TJ, et al. Insights into REM sleep behavior disorder pathophysiology in brainstem-predominant Lewy body disease. *Sleep Med* 2007;8:60–4.
- [15] Benarroch E, Schmeichel A, Low P, Boeve BF, Sandroni P, Parisi JE. Involvement of medullary regions controlling sympathetic output in Lewy body disease. *Brain* 2005;128:338–44.
- [16] Kosaka K, Tsuchiya K, Yoshimura M. Lewy body disease with and without dementia: a clinicopathological study of 35 cases. *Clin Neuropathol* 1988;7:299–305.
- [17] Kosaka K. Diffuse neurofibrillary tangles with calcification: a new presenile dementia. *J Neurol Neurosurg Psychiatry* 1994;57:594–6.
- [18] Braak H, Del Tredici K, Rüb U, de Vos RA, Jansen Steur EN, Braak E. Staging of brain pathology related to sporadic Parkinson's disease. *Neurobiol Aging* 2003;24:197–211.
- [19] Frigerio R, Fujishiro H, Maraganore DM, et al. Comparison of risk factor profiles in incidental Lewy body disease and Parkinson disease. *Arch Neurol* 2009;66:1114–9.
- [20] Caviness JN, Adler CH, Hentz JG, et al. Incidental Lewy body disease: electrophysiological findings suggesting pre-clinical Lewy body disorders. *Clin Neurophysiol* 2011;122:2426–32.
- [21] Tamura T, Yoshida M, Hashizume Y, Sobue G. Lewy body-related alpha-synucleinopathy in the spinal cord of cases with incidental Lewy body disease. *Neuropathology* 2012;32:13–22.
- [22] Siderowf A, Lang A. Premotor Parkinson's disease: concepts and definitions. *Mov Disord* 2012;27:608–16.

- [23] Del Tredici K, Braak H. Lewy pathology and neurodegeneration in premotor Parkinson's disease. *Mov Disord* 2012;27:597–607.
- [24] Sperling RA, Aisen PS, Beckett LA, et al. Toward defining the preclinical stages of Alzheimer's disease: recommendations from the National Institute on Aging–Alzheimer's Association workgroups on diagnostic guidelines for Alzheimer's disease. *Alzheimers Dement* 2011;7:280–92.
- [25] Jack Jr CR, Knopman DS, Weigand SD, et al. An operational approach to National Institute on Aging–Alzheimer's Association criteria for preclinical Alzheimer disease. *Ann Neurol* 2012;71:765–75.
- [26] Ferman TJ, Boeve BF, Smith GE, Silber MH, Kokmen E, Petersen RC, et al. REM sleep behavior disorder and dementia: cognitive differences when compared with AD. *Neurology* 1999;52:951–7.
- [27] Boeve BF, Silber MH, Parisi JE, Dickson DW, Ferman TJ, Benarroch EE, et al. Synucleinopathy pathology and REM sleep behavior disorder plus dementia or parkinsonism. *Neurology* 2003;61:40–5.
- [28] Iranzo A, Molinuevo JL, Santamaria J, Serradell M, Marti MJ, Valldeoriola F, et al. Rapid-eye-movement sleep behaviour disorder as an early marker for a neurodegenerative disorder: a descriptive study. *Lancet Neurol* 2006;5:572–7.
- [29] Postuma RB, Gagnon JF, Vendette M, Fantini ML, Massicotte-Marquez J, Montplaisir J. Quantifying the risk of neurodegenerative disease in idiopathic REM sleep behavior disorder. *Neurology* 2009;72:1296–300.
- [30] Iranzo A, Lomena F, Stockner H, Valldeoriola F, Vilaseca I, Salameo M, et al. Decreased striatal dopamine transporter uptake and substantia nigra hyperechogenicity as risk markers of synucleinopathy in patients with idiopathic rapid-eye-movement sleep behaviour disorder: a prospective study [corrected]. *Lancet Neurol* 2010;9:1070–7.
- [31] Postuma RB, Gagnon JF, Vendette M, Desjardins C, Montplaisir J. Olfaction and color vision identify impending neurodegeneration in idiopathic REM sleep behavior disorder. *Ann Neurol* 2011;69:811–8.
- [32] Iranzo A, Valldeoriola F, Lomena F, et al. Serial dopamine transporter imaging of nigrostriatal function in patients with idiopathic rapid-eye-movement sleep behaviour disorder: a prospective study. *Lancet Neurol* 2011;10:797–805.
- [33] Iranzo A, Santamaria J, Tolosa E. The clinical and pathophysiological relevance of REM sleep behavior disorder in neurodegenerative diseases. *Sleep Med Rev* 2009;13:385–401.
- [34] Boeve BF. REM sleep behavior disorder: Updated review of the core features, the REM sleep behavior disorder–neurodegenerative disease association, evolving concepts, controversies, and future directions. *Ann N Y Acad Sci* 2010;1184:15–54.
- [35] Postuma RB, Gagnon JF, Montplaisir JY. REM sleep behavior disorder: from dreams to neurodegeneration. *Neurobiol Dis* 2011;46:553–8.
- [36] Postuma R, Gagnon JF, Montplaisir J. Clinical prediction of Parkinson's disease: planning for the age of neuroprotection. *J Neurol Neurosurg Psychiatry* 2010;81:1008–13.
- [37] Boeve BF. Predicting the future in idiopathic rapid-eye-movement sleep behaviour disorder. *Lancet Neurol* 2010;9:1040–2.
- [38] Schenck CH, Montplaisir J, Frauscher B, et al. REM sleep behavior disorder (RBD): devising controlled active treatment studies for symptomatic and neuroprotective therapy—a consensus statement by the International RBD Study Group. *Sleep Med*, this issue.
- [39] McCarter SJ, St Louis EK, Boeve BF. REM sleep behavior disorder and REM sleep without atonia as an early manifestation of degenerative neurological disease. *Curr Neurol Neurosci Rep* 2012;12:182–92.
- [40] Boeve BF, Silber MH, Saper CB, Ferman TJ, Dickson DW, Parisi JE, et al. Pathophysiology of REM sleep behaviour disorder and relevance to neurodegenerative disease. *Brain* 2007;130(Pt 11):2770–88.
- [41] TE Sixel-Döring F, Mollenhauer B, Trenkwalder C. Associated factors for REM sleep behavior disorder in Parkinson disease. *Neurology* 2011;77:1048–54.
- [42] Schenck CH, Boeve BF. The strong presence of REM sleep behavior disorder in PD: clinical and research implications [editorial]. *Neurology* 2011;77:1030–2.
- [43] Schenck CH, Mahowald MW. REM sleep parasomnias in adults: REM sleep behavior disorder, isolated sleep paralysis, and nightmare disorders. In: Barkoukis TJ, Matheson JK, Ferber RF, Doghramji K, editors. *Therapy in sleep medicine*. Philadelphia: Elsevier Press; 2011. p. 549–58.
- [44] Schenck CH, Lee SA, Cramer Bornemann MA, Mahowald MW. Potentially lethal behaviors associated with rapid eye movement sleep behavior disorder: review of the literature and forensic implications. *J Forensic Sci* 2009;54:1475–84.