

Ruptured abdominal aortic aneurysm masquerading as isolated hip pain: an unusual presentation

Sriram Vaidyanathan, MRCS;* Himanshu Wadhawan, MRCS;* Pedro Welch;†
Murad El-Salamani, FRCS‡

ABSTRACT

The rupture of an abdominal aortic aneurysm (AAA) is a catastrophic event. Misdiagnosis by first-contact emergency physicians remains a serious concern. Varied and frequently nonspecific presentations lead to erroneous diagnostic impressions and cause significant delays in definitive intervention. We report the case of a 73-year-old man with a ruptured AAA presenting with isolated acute right hip pain without any classical features such as truncal pain or hypotension. Despite major advances in imaging and definitive treatment, a heightened awareness among emergency physicians remains the only effective means of improving detection and thereby survival.

Keywords: ruptured abdominal aortic aneurysm, diagnosis, computerized tomography scan, acute hip pain

RÉSUMÉ

La rupture d'un anévrisme de l'aorte abdominale a de graves conséquences, et la pose d'un mauvais diagnostic par les médecins d'urgence au premier contact demeure très préoccupante. Les motifs de consultation à l'urgence sont variés et fréquemment vagues, ce qui occasionne des impressions diagnostiques erronées et retarde considérablement l'intervention définitive. Nous rapportons un cas de rupture d'anévrisme de l'aorte abdominale chez un homme de 73 ans s'étant présenté à l'urgence avec une douleur aiguë isolée à la hanche droite sans symptômes types tels que des douleurs thoraciques ou de l'hypotension. Malgré les avancées de la science en matière d'imagerie médicale et de traitements définitifs, une plus grande sensibilisation des médecins d'urgence demeure l'unique moyen d'améliorer la détection de cette affection et, par le fait même, la survie des patients.

Introduction

Ruptured abdominal aortic aneurysms (rAAAs) are a substantial health care burden in developed countries and are the thirteenth leading cause of death in the United States.¹ Approximately 1 in 25 adults over 65 years of age harbour AAAs.² Population-based studies have indicated that the incidence of rAAA has almost tripled in the last 30 years.^{2,3} Misdiagnosis

by first-contact practitioners has been shown to be the most significant factor in delay to surgery, with as many as 60% of cases incorrectly diagnosed.⁴⁻⁶ This is subsequently reflected in the strikingly high overall mortality rate; up to 85% has been reported in some studies.¹ Numerous investigations have suggested that expeditious diagnosis of an AAA, even if it has ruptured, offers the best hope for patient survival.⁷ In our patient, rAAA was heralded only by isolated hip pain.

*Senior House Officer, Emergency Medicine, †Basic Surgical Trainee, and ‡Consultant, Emergency Medicine, Bassetlaw District General Hospital, Nottinghamshire, UK

Received: Nov. 30, 2006; revisions received: Apr. 20, 2007; accepted: Oct. 10, 2007

This article has been peer reviewed.

CJEM 2008;10(3):251-4

Case report

A 73-year-old man who had experienced severe right hip pain for the previous 6 hours presented to a community emergency department (ED) at about 2:00 pm. He stated that he had been picking weeds in his garden when he felt a pain that he described as “being kicked in the hip.” He sought medical attention when the pain did not abate over the next few hours and he had some difficulty bearing weight. There was no history of preceding trauma or collapse. He denied any abdominal or back pain. His vital signs were pulse 77 beats/minute, blood pressure (BP) 118/76 mm Hg, respiratory rate 18 breaths/minute, temperature 36°C. Past medical history included essential hypertension controlled by a β -blocker. Examination revealed a tender right hip with full range of movement at the hip joint. There were no hernias or lymph nodes in the patient’s groin, and his distal pulses were present and symmetrical. The perplexing absence of any local findings prompted suspicion of a referred pain and led to an examination of the patient’s abdomen. Inspection showed an obese abdomen and, surprisingly, subsequent palpation revealed a large nontender pulsating mass in the umbilical region with no signs of peritoneal irritation. Because the patient’s vital signs were stable and abdominal tenderness, guarding and rigidity were all absent, an urgent CT scan of his abdomen was performed at around 6:00 pm. This immediately confirmed a 9-cm infrarenal aneurysm that was leaking extensively around the patient’s right kidney and abutting his right psoas muscle. An urgent transfer to the regional vascular service was organized; however, the patient collapsed and died before that could be accomplished.

Discussion

The classic triad of abdominal or back pain, hypotension and a pulsatile abdominal mass may be absent in more than 60% cases of rAAA.⁵ Atypical and insidious clinical presentations of this potentially fatal disease make it challenging to diagnose as it may often mimic renal colic, urinary tract infection, diverticulitis, gastrointestinal perforation and spinal disease.^{4,6,8} In a stable patient without any truncal pain or collapse, the diagnosis of aneurysmal rupture is not usually suspected. Although internal iliac aneurysms are known to present with hip pain, this is the first reported case of an rAAA presenting with isolated hip pain.⁹ The most common diagnoses considered in an elderly patient with an acute onset of hip pain and difficulty in weight bearing are femoral neck fracture, acute monoarthropathy such as septic arthritis, neurogenic pain

or acute-on-chronic ischaemia. In our patient, the absence of trauma and lack of local findings on clinical examination suggestive of hip disease prompted an abdominal examination, revealing the underlying pathology.

While an ultrasound examination can be performed at the bedside, it is typically poor at identifying the presence of retroperitoneal blood (sensitivity 4%) and may be inconclusive in an obese individual.^{10,11} CT scan is therefore the investigation of choice when worried about bleeding.^{4,12} Furthermore, in 2 randomized controlled trials comparing surgical treatments for rAAA, Hinchliffe and Spence^{13,14} showed that CT scanning did not delay diagnosis and was an essential tool for ascertaining extent, morphology and suitability for endovascular repair or assessing graft size. Lloyd and co-authors¹² found in a series of 56 patients with nonsurgical management of rAAA that up to 87% of patients who survive to the hospital are stable enough to undergo diagnostic CT scanning. Fitzgerald and colleagues¹⁵ found major additional pathology in 35% of patients with suspected AAA, which influenced surgical management. As such, our patient exhibited no circulatory instability to preclude a CT scan. Mehta and coworkers¹⁶ demonstrated a mortality rate of 18% in their cohort of surgically treated patients with rAAA after CT scanning all patients whose systolic blood pressure was above 80 mm Hg. Boyle and colleagues¹⁷ demonstrated prospectively that mortality in the surgical group was not affected by preoperative imaging. Even in hemodynamically unstable patients there has been no demonstrated increase in postoperative deaths as a result of the delay associated with CT.¹⁸

As to why a CT scan was chosen over a bedside ultrasound, the need to establish the presence of a leak was of far greater consequence than identifying the diameter of

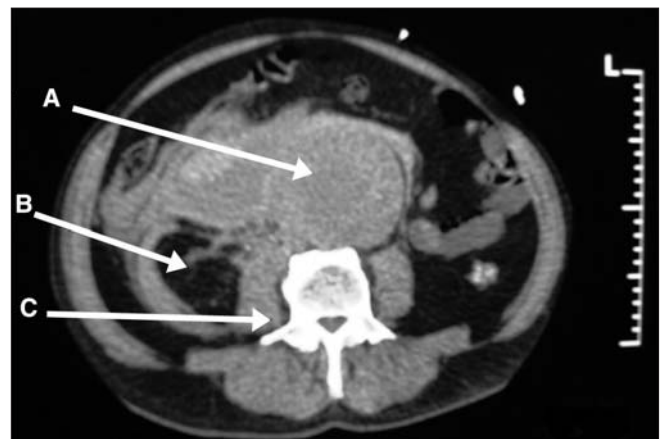


Fig. 1. A CT scan showing a large 9-cm infrarenal aortic aneurysm extensively leaking around the right kidney and psoas muscle. A = ruptured abdominal aortic aneurysm; B = right kidney; C = right psoas muscle surrounded by blood.

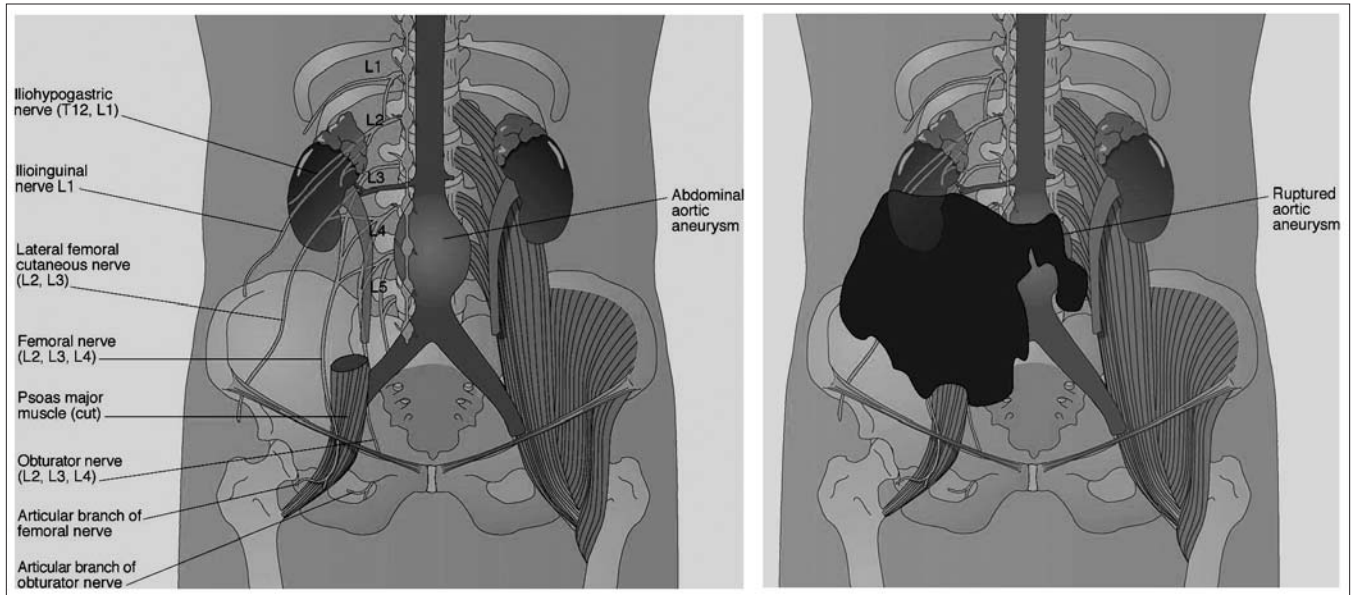


Fig. 2. A schematic representation of the lumbar plexus and its articular branches in relation to the aorta (A). A schematic representation showing a ruptured aortic aneurysm and tracking blood around the psoas muscle and lumbar plexus (B).

the aneurysm. This would determine whether the patient should be immediately rushed to the operating room or undergo medical optimization before proceeding either to an urgent open repair or to an endovascular repair. In the only published nonsystematic review comparing emergency ultrasound with CT scanning (nearly 100% sensitive and specific) as the initial investigation,¹⁹ the authors concluded that emergency ultrasound was sensitive (94%–100%) and specific (100%) in establishing the maximum diameter of the AAA by appropriately trained emergency physicians. However, on closer examination the studies were methodologically poor and suffered significant selection bias. None looked at leaking as an outcome measure. Therefore, on balance, CT scanning remains a superior investigation tool in the hemodynamically stable patient with a suspected AAA; it also provides the clinician with a valuable road map that ultrasound cannot offer.

Our patient described his pain as “being kicked.” The reason for this may be attributed to the leaking blood in the retroperitoneum irritating the articular branches of the lumbar plexus as they wrap around the psoas muscle (Fig. 1). The lumbar plexus is formed by the ventral primary rami of the first 4 lumbar spinal nerves and gives rise to several branches supplying the skin and musculature around the hip and articular branches to the hip joint itself. Plausible explanations for the hip pain in this case would include irritation of the iliohypogastric nerve (T12, L1), ilioinguinal nerve (L1), lateral femoral cutaneous nerve (L2, L3) and the articular branches of the femoral nerve (L2, L3, L4) and obturator nerve (L2, L3, L4) (Fig. 2).

Conclusion

Ruptured AAA is an important diagnostic challenge to emergency physicians and is often misdiagnosed because of its nonspecific presentations. Isolated acute hip pain that mimicks a fracture in the elderly can very rarely be the result of an rAAA. This case highlights the need for heightened awareness among emergency physicians to this time-sensitive diagnosis.

Competing interests: None declared.

References

1. Sakalihasan N, Limet R, Defawe OD. Abdominal aortic aneurysm. *Lancet* 2005;365:1577-89.
2. Hallett JW Jr. Management of abdominal aortic aneurysms. *Mayo Clin Proc* 2000;75:395-9.
3. Acosta S, Ogren M, Bengtsson H, et al. Increasing incidence of ruptured abdominal aortic aneurysm: a population-based study. *J Vasc Surg* 2006;44:237-43.
4. Haro LH, Krajicek M, Lobl K. Challenges, controversies and advances in aortic catastrophes. *Emerg Med Clin North Am* 2005;23:1159-77.
5. Akkersdijk GJ, Bockel JHV. Ruptured abdominal aortic aneurysm: initial misdiagnosis and the effect on treatment. *Eur J Surg* 1998;164:29-34.
6. Acheson AG, Graham ANJ, Weir C, et al. Prospective study on factors delaying surgery in ruptured abdominal aortic aneurysms. *J R Coll Surg Edinb* 1998;43:182-4.

7. Rose J, Civil I, Koelmeyer T, et al. Ruptured abdominal aortic aneurysms: clinical presentation in Auckland 1993-1997. *ANZ J Surg* 2001;71:341-4.
8. Contini S, McMaster P. Abdominal aortic aneurysm — the forgotten diagnosis? *Postgrad Med J* 1980;56:102-5.
9. Ijaz S, Geroulakos G. Ruptured internal iliac aneurysm mimicking a hip fracture. *Int Angiol* 2001;20:187-9.
10. Walker A, Brenchley J, Sloan JP, et al. Ultrasound by emergency physicians to detect abdominal aortic aneurysms: a UK case series. *Emerg Med J* 2004;21:257-9.
11. Goldberg BB. Aortosonography. *Int Surg* 1977;62:294-7.
12. Lloyd GM, Bown MJ, Norwood MG, et al. Feasibility of preoperative computer tomography in patients with ruptured aortic aneurysm: a time-to-death study in patients without operation. *J Vasc Surg* 1995;21:656-69.
13. Hinchliffe RJ, Bruijstens L, MacSweeney STR, et al. A randomised trial of endovascular and open surgery for ruptured abdominal aortic aneurysm- results of a pilot study and lessons learned for future studies. *Eur J Vasc Endovasc Surg* 2006;32:506-13.
14. Hinchliffe RJ, Yusuf SW, Macierewicz JA, et al. Endovascular repair of ruptured abdominal aortic aneurysm — a challenge to open repair? Results of a single centre experience in 20 patients. *Eur J Vasc Endovasc Surg* 2001;22:528-34.
15. Fitzgerald EJ, Spence LD. Pre-operative computed tomography in abdominal aortic aneurysms. *Postgrad Med J* 1996;72:484-6.
16. Mehta M, Taggart J, Darling C, et al. Establishing a protocol for endovascular treatment of ruptured abdominal aortic aneurysms: outcomes of a prospective analysis. *J Vasc Surg* 2006;44:1-8.
17. Boyle JR, Gibbs PJ, Kruger A, et al. Existing delays following the presentation of abdominal aortic aneurysm allow sufficient time to assess patients for endovascular surgery. *Eur J Vasc Endovasc Surg* 2005;29:505-9.
18. Acosta S, Lindblad B, Zdanowski Z. Predictors of outcome after open and endovascular repair of ruptured aortic aneurysms. *Eur J Vasc Endovasc Surg* 2007;33:277-84.
19. Bentz S, Jones J. Towards evidence-based emergency medicine: best BETs from the Manchester Royal Infirmary. Accuracy of emergency department ultrasound scanning in detecting abdominal aortic aneurysm. *Emerg Med J* 2006;23:803-4.

Correspondence to: Dr. Sriram Vaidyanathan, 32 Wicklow Rd., Doncaster, South Yorkshire DN2 5LA, UK; srivaidyanathan@gmail.com