

Received: 2017.03.02  
Accepted: 2017.04.02  
Published: 2017.07.11

ISSN 1941-5923  
© Am J Case Rep, 2017; 18: 777-781  
DOI: 10.12659/AJCR.904119

## Development of Graft-Site Candidiasis in 3 Solid Organ Transplant Recipients from the Same Donor

Authors' Contribution:  
Study Design A  
Data Collection B  
Statistical Analysis C  
Data Interpretation D  
Manuscript Preparation E  
Literature Search F  
Funds Collection G

ABE 1 **Nasrin El-Bandar**  
BD 2 **Daniela C. Kroy**  
BD 1 **Tom Florian Fuller**  
BC 3 **Jürgen Kramer**  
BD 4 **Lutz Liefeldt**  
BD 4 **Klemens Budde**  
BC 1 **Conrad Blobel**  
BD 1 **Kurt Miller**  
DE 1 **Frank Friedersdorff**

1 Department of Urology, Charité University Hospital Berlin, Berlin, Germany  
2 Department of Medicine III, RWTH University Hospital Aachen, Aachen, Germany  
3 Department of Urology, Vivantes Hospital Am Urban, Berlin, Germany  
4 Department of Nephrology, Charité University Hospital Berlin, Berlin, Germany

**Corresponding Author:** Frank Friedersdorff, e-mail: [frank.friedersdorff@charite.de](mailto:frank.friedersdorff@charite.de)  
**Conflict of interest:** None declared

### Case series

**Patient:** Female, 61 • Female, 33 • Female, 58  
**Final Diagnosis:** *Candida arteritis*  
**Symptoms:** Severe bleeding  
**Medication:** —  
**Clinical Procedure:** —  
**Specialty:** Infectious Diseases

**Objective:** Unusual clinical course





**Background:** Graft-site candidiasis rarely develops in solid organ transplant recipients; however, severe life-threatening complications can occur. We report the course of 3 solid organ transplant recipients developing graft-site candidiasis.  
**Case report:** All grafts, consisting of 2 kidneys and 1 liver, were procured from a single donor. Patient data were collected from our database.

*Candida albicans* was isolated from a swab taken during multiple-organ recovery. Complications associated with candidiasis occurred in all 3 recipients with preservation of the liver transplant. Both renal transplant recipients had vascular complications, eventually resulting in graft nephrectomy and subsequent return to dialysis. The patients recovered completely without residual effects of their prior fungal infection.

**Conclusions:** Fungal infections in solid organ transplant recipients are rare. Since the sequelae of these infections are serious and usually pertain to more than 1 recipient at a time, antifungal prophylaxis may be warranted in select donors.

**MeSH Keywords:** *Candida Albicans* • Lung Diseases, Fungal • Transplantation, Homologous

**Full-text PDF:** <http://www.amjcaserep.com/abstract/index/idArt/904119>

 1995  —  3  19



## Background

Invasive fungal infections, most commonly induced by *Candida* species, affect about 3% of solid organ transplant recipients in the first year after transplantation [1,2].

Graft-site candidiasis is a possible but rare manifestation of invasive fungal infections, with a reported incidence of 0.1% in renal transplant recipients [3]. The contamination of the graft during organ procurement, handling, and implantation, as well as a fungal infection of the donor, have been discussed as possible sources of candidiasis at graft the site [3–6].

*Candida arteritis* is a possible and common manifestation of graft-site candidiasis and can pose a life-threatening situation by causing anastomotic leakage or rupture and subsequent hemorrhagic shock [1,3].

In renal transplant recipients, graft nephrectomy is conducted as a surgical intervention in most patients with vascular complications to prevent severe implications [3,7]. In contrast, preservation of the renal graft is rarely achieved when candidiasis is accompanied by vascular complications [3,8].

We report the management of graft-site candidiasis in 3 solid organ transplant recipients receiving their grafts from a single donor. Patient data were recorded with privacy protection and anonymization. The study was carried out in accordance with the Declaration of Helsinki.

### Good scientific practice

Patient data were recorded with privacy protection and anonymization.

## Case Report

### Donor

Grafts were procured from a 61-year-old female donor following diagnosis of brain death. The donor had an acute flare of chronic pancreatitis with a retro-oesophageal pseudocyst. After several endoscopic interventions, a double-j stent was inserted into the pseudocyst via para-oesophageal puncture, noting a brown secretion. Nevertheless, the patient's condition deteriorated with development of peritonitis, unclear thrombocytopenia, acute renal failure, and epileptic seizures. However, no schistocytes were found on blood smears. Computed tomography (CT) showed a subdural hematoma and an intracerebral hemorrhage. Despite hemicraniectomy with removal of the hematoma, the patient's consciousness decreased, eventually resulting in brain death.

Three organs were procured from the donor: 2 kidneys and 1 liver. Multiple-organ procurement and transplantation of the kidneys was conducted at the Charité University Hospital Berlin, and liver transplantation was performed at the RWTH University Hospital Aachen. During multiple-organ procurement, the surgeons noted apparent residues of an inflammatory process. Six days after multiple-organ procurement, physicians were informed about the detection of *Candida albicans* and *Enterococcus faecium* in a swab taken during surgery. However, culture of kidney and liver perfusate was not performed. No bacteria or fungi were detected in the donor's blood culture. Unfortunately, graft-site candidiasis developed in all 3 solid organ transplant recipients.

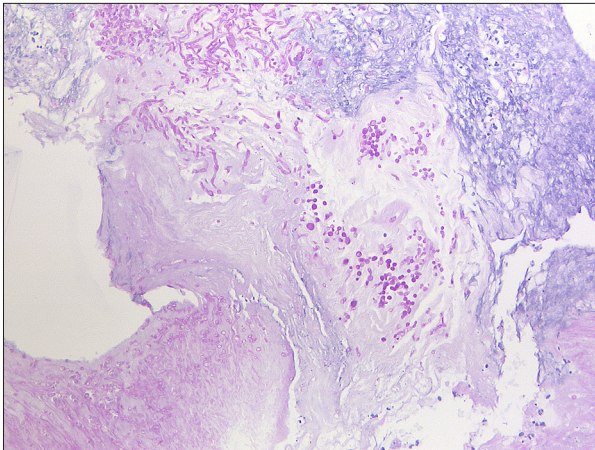
### Kidney transplant recipient 1

A 33-year-old woman with end-stage renal disease resulting from IgA nephropathy received, after 42 months of hemodialysis, the left kidney of a deceased donor.

During back-table preparation of the kidney, the surgeons noted an adherent renal gland and pararenal tissue, probably corresponding to a 12-mm hypodense mass at the site of the left renal gland on the donor's CT. The graft was placed in the right iliac fossa with end-to-side anastomosis of the renal vessels to the external iliac vessels. The kidney had good perfusion after 13 h 4 min of cold ischemia time and 50 min of anastomosis time. Ureteroneocystostomy was performed using 2-stitch technique. The patient received triple-drug therapy with tacrolimus, prednisone, and mycophenolate mofetil.

On post-transplant day 6, hemoglobin fell to 4 g/dl. Consequently, an emergency surgery was conducted, identifying insufficiency of the arterial anastomosis, which resulted in acute hemorrhage. Unfortunately, an unsuccessful reconstruction of the arterial anastomosis necessitated an ensuing graft nephrectomy. On the same day, the donor's swab tested positive for *Candida albicans*. Microbiological testing also showed *Candida albicans* colonization in the removed kidney, thus making antifungal therapy absolutely essential. However, *Candida* antigen was negative in blood culture and remained negative during 14-month follow-up. Based on an antibiogram, caspofungin and (intermediately) fluconazole were given for antifungal treatment.

The patient underwent operative revision 3 times within the following 9 days due to recurrent hemorrhage. The third surgical revision revealed an insufficiency of the vascular suture at the site of the initial arterial anastomosis of the graft. Subsequently, resection of 1.5 cm of the external iliac artery and an ensuing arterial reconstruction were conducted using a saphenous vein interposition graft. In addition to the identification of *Candida albicans* in microbiological testing,



**Figure 1.** Fungal spores and pseudohyphae in the external iliac artery (periodic acid-Schiff stain).

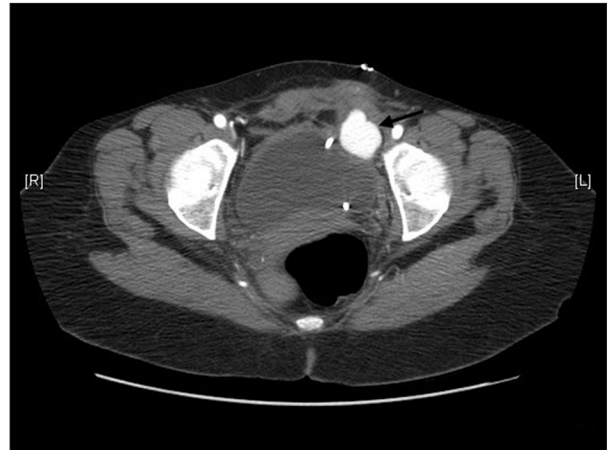histopathological examination of the resected tissue showed purulent inflammation with fungal colonization (Figure 1).

Seven weeks after transplantation, the patient's clinical condition improved and she was discharged from hospital. Eventually, following graft nephrectomy, she resumed hemodialysis for treatment of end-stage renal disease and remained under antifungal therapy for 3 months.

### **Kidney transplant recipient 2**

A 58-year-old woman with end-stage renal disease resulting from ureteral strictures caused by schistosomiasis, received a right kidney after undergoing maintenance hemodialysis for 91 months. Renal transplantation was conducted uneventfully, placing the right kidney in the left iliac fossa. Anastomosis of the vessels, ureteroneocystostomy, and immunosuppressive treatment were carried out as in the previous case. The renal graft had good perfusion after 7 h 15 min of cold ischemia time and 46 min of anastomosis time.

Six days after transplantation, the patient had syncope. A CT scan revealed a 12-cm hematoma at the graft site, necessitating an operative revision. During surgery, a hemorrhage from an arterial branch of the graft was identified and the patient developed hemorrhagic shock. Aspiration of gastric contents during the induction of anaesthesia resulted in acute respiratory distress syndrome, contributing, next to liver and graft failure, to multiorgan failure. She was admitted to the Intensive Care Unit, where her condition improved. Swabs from the graft site were positive for *Candida albicans*. However, as in the previous case, *Candida* antigen was negative. Therefore, antifungal agents were administered for 3 months, first using caspofungin. Later, antifungal medication was converted to orally administered fluconazole.



**Figure 2.** Computed tomography presenting a pseudoaneurysm (indicated by an arrow) of the arterial anastomosis caudal to the renal transplant.

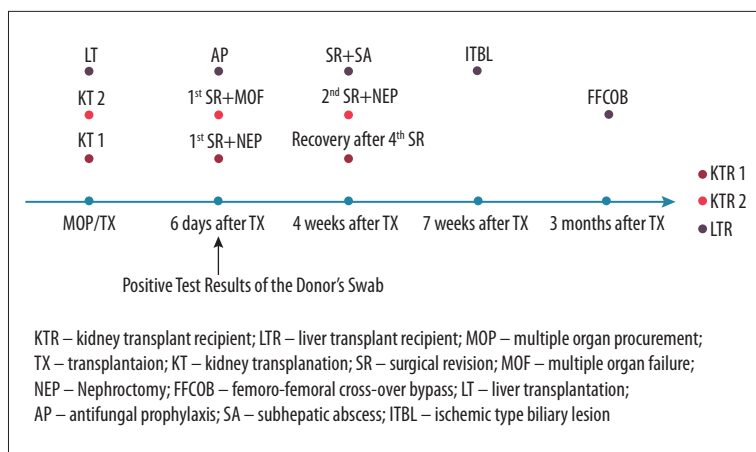
One month after transplantation, the patient reported pain at the graft site. The ensuing CT showed a pseudoaneurysm at the arterial anastomosis, measuring 4.5×2.3 cm (Figure 2). Subsequently, the patient underwent graft nephrectomy with arterial reconstruction using a saphenous vein patch. Subsequently, the patient required hemodialysis owing to end-stage renal disease.

Three months after transplantation, a CT scan once again revealed a pseudoaneurysm at the site of the former arterial anastomosis. Consequently, ligation of the external iliac artery and an ensuing femoro-femoral cross-over bypass with use of a homograft were conducted. There were no further conspicuous or intervention-requiring findings within 4-month follow-up after the last surgery.

### **Liver transplant recipient**

Six days after transplantation, the hospital in which liver transplantation was conducted was informed about the adverse events in both kidney transplant recipients. By that time, the 53-year old female liver transplant recipient had not developed any complications. Since we suspected a donor-derived infection, antifungal prophylaxis was immediately initiated using caspofungin.

The liver transplant recipient had alcoholic liver disease and underwent orthotopic liver transplantation due to acute-on-chronic liver failure, with a MELD score of 40. Transplantation was conducted with use of a venovenous bypass. Arterial anastomosis was performed between the donor's celiac trunk and the recipient's common hepatic artery at the level of bifurcation. Biliary reconstruction was performed as side-to-side choledochocholedochostomy with placement of a T-tube. The cold ischemia time and the anastomosis time were 8 h and 28



**Figure 3.** Postoperative courses of the 3 solid organ transplant recipients.

min, respectively, with subsequent good perfusion of the liver. Immunosuppressive therapy consisted of tacrolimus, prednisone, and mycophenolate mofetil.

Despite antifungal prophylaxis, complications could not be prevented. Four weeks after transplantation, the patient developed ascites. Since it could not be managed sufficiently by paracentesis, she underwent operative revision. Surgery revealed a subhepatic abscess with concomitant peritonitis caused by *Candida albicans* and *Enterococcus faecium*. Two weeks later, strictures and dilatations were seen in cholangiography, consistent with ischemic-type biliary lesions (ITBL).

During the following 5 months, the patient had recurrent cholangitis with identification of various pathogens, including *Streptococcus anginosus*, *E. coli*, *Klebsiella oxytoca*, *Clostridium perfringens*, *Candida glabrata*, *Candida albicans*, and *Enterococcus faecium*. Considering major complications in the postoperative course and the impending graft failure, the possibility and necessity of a retransplantation was discussed; however, after a total of 22 cholangiographic interventions, the patient's clinical condition improved, with slightly elevated cholestatic parameters (serum alkaline phosphatase 146 U/l and gamma-glutamyltransferase 73 U/l). Currently, after 22 months of follow-up, there are no clinical or laboratory signs of infection.

Figure 3 illustrates the postoperative course of the 3 solid organ transplant recipients presented above.

## Discussion

Although lacking of microbiological evidence, we believe the donor had invasive candidiasis. Despite the absence of fungi in the donor's blood culture, a disseminated infection could not be excluded, since the sensitivity of blood cultures in the detection of *Candida* species is rather low [1]. Thrombocytopenia in

the donor most probably occurred para-infectiously and could be related to candidiasis. Since candidiasis was verified in all 3 solid organ transplant recipients receiving a transplant from this donor, we suspect direct transmission of infection from the donor. In the context of a donor infection, a higher fungal load might be introduced into the recipient, probably expediting a more severe infection [4]. However, contamination of the graft perfusate during organ recovery is considered the predominant source of invasive candidiasis, especially in kidney transplant recipients [3, 9]. Intestinal rupture during organ recovery is a possible cause of contamination and therefore is a risk factor for candidiasis in the recipient [3].

Prevention of *Candida*-associated vascular complications is a major issue, yet difficult to achieve. Antifungal prophylaxis can prevent manifestation of disease and subsequent complications in patients at high risk of invasive fungal infections. However, identification of patients at high risk is difficult because there is no accurate test with high sensitivity and specificity. Fungal contamination of the perfusion fluid does not inevitably lead to fungal infection in the recipient, nor does a negative culture result of the organ perfusate rule this infection out. Matignon et al. [10] described 8 cases of renal transplantation in which the organ perfusate grew *Candida* species, but without clinical manifestation of a fungal infection in the recipients. In contrast, Albano et al. [3] reported development of graft-site candidiasis with vascular complications in 6 renal transplant recipients, but without fungal contamination of the perfusion fluid.

Although antifungal prophylaxis might reduce the incidence and complications of invasive fungal infections, their general use might not be advisable owing to the low incidence rate and the possible emergence of resistance [11, 12]. Moreover, fungal infections at the graft site can occur despite the prophylactic use of antifungal agents, as presented above. However, the use of antifungal agents for prophylaxis of fungal infections may be warranted when graft-site candidiasis occurs in

another transplant recipient from the same donor or when the organ perfusate is positive for fungi [3,13].

Complications due to candidiasis most frequently affect the arterial anastomosis and are often associated with a fatal outcome [3,5,9,14–16]. Vascular complications even occur after treatment with antifungals and graft nephrectomy [3,13]. In our patients, we noticed the occurrence of further complications in 1 renal transplant recipient after reconstruction of the arterial anastomosis with a patch. In contrast, the other kidney transplant recipient developed no further complications after resection of 1.5 cm of the vascular tissue at the site of the arterial anastomosis. This suggests that resection of the vascular tissue at the site of the arterial anastomosis is associated with a better outcome when the vascular tissue is affected by fungal infection. Better management of invasive fungal infections might also be achieved by a local intraoperative application of antifungal agents, as in the use of antibiotic bead chains and antibacterial sutures [17–19].

## References:

1. Shoham S, Marr KA: Invasive fungal infections in solid organ transplant recipients. *Future Microbiol*, 2012; 7(5): 639–55
2. Andes DR, Safdar N, Baddley JW et al: The epidemiology and outcomes of invasive *Candida* infections among organ transplant recipients in the United States: results of the Transplant-Associated Infection Surveillance Network (TRANSNET). *Transpl Infect Dis*, 2016; 18(6): 921–31
3. Albano L, Bretagne S, Mamzer-Bruneel MF et al: Evidence that graft-site candidiasis after kidney transplantation is acquired during organ recovery: A multicenter study in France. *Clin Infect Dis*, 2009; 48(2): 194–202
4. Gottesdiener KM: Transplanted infections: Donor-to-host transmission with the allograft. *Ann Intern Med*, 1989; 110(12): 1001–16
5. Battaglia M, Ditonno P, Fiore T et al: True mycotic arteritis by *Candida albicans* in 2 kidney transplant recipients from the same donor. *J Urol*, 2000; 163(4): 1236–37
6. Singh N, Huprikar S, Burdette SD et al: Donor-derived fungal infections in organ transplant recipients: Guidelines of the American Society of Transplantation, infectious diseases community of practice. *Am J Transplant*, 2012; 12(9): 2414–28
7. Guy A, Chinai N, Ashley S et al: *Candida arteritis* in a pair of renal transplant recipients. *Exp Clin Transplant*, 2013; 11(6): 558–61
8. Kountidou CS, Stier K, Niehues SM et al: Successful repair of post-transplant mycotic aneurysm of iliac artery with renal graft preservation: A case report. *Urology*, 2012; 80(5): 1151–53
9. Addeo P, Saouli AC, Woehl-Jaegle ML et al: *Candida albicans* arteritis transmitted by preservation fluid after liver transplantation. *Ann Transplant*, 2014; 19: 64–67
10. Matignon M, Botterel F, Audard V et al: Outcome of renal transplantation in eight patients with *Candida* sp. contamination of preservation fluid. *Am J Transplant*, 2008; 8(3): 697–700
11. Loeffler J, Stevens DA: Antifungal drug resistance. *Clin Infect Dis*, 2003; 36(Suppl. 1): S31–41
12. Prigent G, Ait-Ammar N, Levesque E et al: Echinocandin resistance in *Candida* species isolates from liver transplant recipients. *Antimicrob Agents Chemother*, 2017; 61(2): pii: e01229-16
13. Mai H, Champion L, Ouali N et al: *Candida albicans* arteritis transmitted by conservative liquid after renal transplantation: A report of four cases and review of the literature. *Transplantation*, 2006; 82(9): 1163–67
14. Levesque E, Suet G, Merle JC et al: *Candida* vascular complication in a liver transplant recipient due to yeast contamination of preservation solution. *Transpl Infect Dis*, 2014; 16(5): 827–29
15. Llado L, Sole C, Bodro M et al: *Candida arteritis* occurring in a liver transplant recipient. *Transpl Infect Dis*, 2014; 16(3): 465–68
16. Debska-Slizien A, Chrobak L, Bzoma B et al: *Candida arteritis* in kidney transplant recipients: Case report and review of the literature. *Transpl Infect Dis*, 2015; 17(3): 449–55
17. Klemm KW: Antibiotic bead chains. *Clin Orthop Relat Res*, 1993; (295): 63–76
18. Storch ML, Rothenburger SJ, Jacinto G: Experimental efficacy study of coated VICRYL plus antibacterial suture in guinea pigs challenged with *Staphylococcus aureus*. *Surg Infect (Larchmt)*, 2004; 5(3): 281–88
19. Justinger C, Moussavian MR, Schlueter C et al: Antibacterial [corrected] coating of abdominal closure sutures and wound infection. *Surgery*. 2009; 145(3): 330–34

## Conclusions

In conclusion, graft-site candidiasis remains a rare complication in solid organ transplant recipients. Nonetheless, due to the possible occurrence of life-threatening and severe complications, a prudent approach is indicated if a fungal infection is suspected. Antifungal prophylaxis should only be conducted in patients at high risk of fungal infections. When vascular complications are observed, graft nephrectomy reduces the risk of life-threatening complications in renal transplant recipients. Direct transmission of infection from the donor, although rarely reported, obviously increases risk of subsequent complications.

## Conflict of interest

The authors of this article have no conflict of interest.