

Clinical paper

Cardiac arrest in the catheterisation laboratory: A 5-year experience of using mechanical chest compressions to facilitate PCI during prolonged resuscitation efforts[☆]

Henrik Wagner^a, Christian J. Terkelsen^b, Hans Friberg^c, Jan Harnek^a, Karl Kern^d, Jens Flensted Lassen^b, Goran K. Olivecrona^{a,*}

^a Department of Cardiology, Lund University Hospital, 221 85 Lund, Sweden

^b Department of Cardiology B, Aarhus University Hospital, Aarhus, Denmark

^c Department of Emergency Medicine, Lund University Hospital, Lund, Sweden

^d Sarver Heart Center, University of Arizona, Tucson, AZ, USA

ARTICLE INFO

Article history:

Received 3 July 2009

Received in revised form 14 October 2009

Accepted 11 November 2009

Keywords:

Mechanical chest compressions

PCI

Cardiac arrest

Catheterisation laboratory

ABSTRACT

Purpose: Lengthy resuscitations in the catheterisation laboratory carry extremely high rates of mortality because it is essentially impossible to perform effective chest compressions during percutaneous coronary intervention (PCI). The purpose of this study was to evaluate the use of a mechanical chest compression device, LUCASTM, in the catheterisation laboratory, in patients who suffered circulatory arrest requiring prolonged resuscitation.

Materials and methods: The study population was comprised of patients who arrived alive to the catheterisation laboratory and then required mechanical chest compression at some time during the angiogram, PCI or pericardiocentesis between 2004 and 2008 at the Lund University Hospital. This is a retrospective registry analysis.

Results: During the study period, a total of 3058 patients were treated with PCI for ST-elevation myocardial infarction (STEMI) of whom 118 were in cardiogenic shock and 81 required defibrillations. LUCASTM was used in 43 patients (33 STEMI, 7 non-ST-elevation myocardial infarction (NSTEMI), 2 elective PCIs and 1 patient with tamponade). Five patients had tamponade due to myocardial rupture prior to PCI that was revealed at the start of the PCI, and all five died. Of the remaining 38 patients, 1 patient underwent a successful pericardiocentesis and 36 were treated with PCI. Eleven of these patients were discharged alive in good neurological condition.

Conclusion: The use of mechanical chest compressions in the catheterisation laboratory allows for continued PCI or pericardiocentesis despite ongoing cardiac or circulatory arrest with artificially sustained circulation. It is unlikely that few, if any, of the patients would have survived without the use of mechanical chest compressions in the catheterisation laboratory.

© 2009 Elsevier Ireland Ltd. All rights reserved.

Cardiac arrest in the catheterisation laboratory during percutaneous coronary interventions (PCIs), although a rare event, is often treated rapidly and successfully with cardiopulmonary resuscitation (CPR) and DC conversions.¹ In a minority of these patients, the initial resuscitation efforts are not immediately successful, and extended periods of manual chest compressions are needed to maintain coronary and cerebral circulation. In patients

who require prolonged CPR, mortality rates are very high.² Frequently, a continued uninterrupted PCI procedure of, for example, a suddenly occluded left main artery is often the best option for attaining return of spontaneous circulation (ROSC). However, continued cardiac compressions with simultaneous PCI, which requires fluoroscopy, is exceedingly difficult to perform effectively.

A novel mechanical chest compression device, LUCASTM (Jolife AB, Lund, Sweden), (Fig. 1), has been shown to sustain both coronary and cerebral circulation despite cardiac arrest.^{3,4} The device is mostly radio translucent, enabling continued PCI with maintained circulation despite ongoing cardiac arrest, which has been documented in several reports.^{5–9} Although LUCASTM has been shown to be successfully used in the catheterisation laboratory to maintain circulation,^{5–9} a recent report found abysmal survival rates in patients who were brought to the catheterisation laboratory

[☆] A Spanish translated version of the abstract of this article appears as Appendix in the final online version at doi:10.1016/j.resuscitation.2009.11.006.

* Corresponding author. Tel.: +46 46173053; fax: +46 46176011.

E-mail addresses: henrik.wagner@skane.se (H. Wagner), christian.juhl.terkelsen@hotmail.com (C.J. Terkelsen), hans.friberg@skane.se (H. Friberg), jan.harnek@skane.se (J. Harnek), kernk@u.arizona.edu (K. Kern), jens.lassen@ki.au.dk (J.F. Lassen), goran.olivecrona@med.lu.se (G.K. Olivecrona).

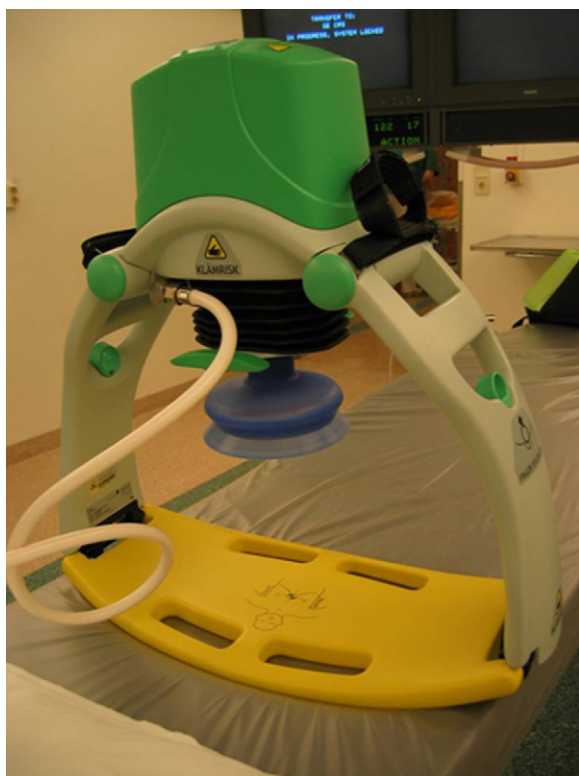

Fig. 1. Image of LUCAS™, Jolife AB, Lund, Sweden.

in cardiac arrest but with circulation maintained with mechanical chest compressions.⁸ Our experience since 2004 with the chest compression device LUCAS™ is similar. Essentially, all patients admitted to our catheterisation laboratory already in cardiac arrest, but with circulation maintained through mechanical chest compressions, do not survive. However, patients who arrive at the catheterisation laboratory with intact circulation and who then suf-

fer cardiac arrest in the catheterisation laboratory, often during the procedure of angiography or PCI, may have a benefit of LUCAS™, especially if there is concomitant PCI performed.

1. Methods

The study is a retrospective registry analysis of all patients who suffered a prolonged resuscitation episode while scheduled for any procedure in the coronary catheterisation laboratory at the Lund University Hospital during 2004–2008, to which the hospital's cardiac arrest team was alerted. The database of the cardiac arrest team was used to find the patients in the study.

Prolonged resuscitation was defined as an episode of cardiac arrest necessitating a period of several minutes of manual chest compressions, followed by the use of a mechanical chest compressions and then tracheal intubation. The other selection criterion was that the patients had to arrive alive to the catheterisation laboratory before the episode of cardiac arrest. We also evaluated similar patients (requiring >1 min of manual chest compressions and requiring tracheal intubation) in which no mechanical chest compression device was used in the same time span.

During the period 1 January 2004 to 31 December 2007, the mechanical chest compression device used was LUCAS V1 (European version).³ During the period 1 January 2008 to 31 December 2008, the mechanical chest compression device used was LUCAS V2 (US version), which has the same operating parameters as LUCAS V1 except for the decompression force which is set to a maximum of 13 N.

All charts and autopsy reports of our cohort of 43 patients were examined. The predefined endpoints were mortality status on departure from the catheterisation laboratory, successful PCI and discharge from hospital in the Cerebral Performance Categories (CPCs) 1 or 2,¹⁰ representing a good neurological outcome.

The use of LUCAS™ was stopped at the discretion of the attending physician either because the patient achieved ROSC or because further treatment with LUCAS™ was deemed futile.

Table 1
Patient characteristics and outcomes.

	n (%)	In hospital death	Discharged alive
Patient history (n = 43)			
Hypertension	24 (56%)	16	8
Diabetes	11 (25.5%)	10	4
Hyperlipidemia	15 (35%)	10	7
Smoking/X-smoke	22 (51%)	16	3
Previous MI	12 (28%)	8	4
Previous PCI	5 (11.5%)	5	0
Previous CABG	6 (14%)	5	1
Indication for cath lab procedure (n = 43)			
STEMI	33 (77%)	27	6
NSTEMI	7 (16.1%)	3	4
Elective PCI	2 (4.6%)	0	2
Tamponade	1 (2.3%)	1	0
Culprit lesion in coronary patients (n = 42)			
LM	9 (21%)	6	3
LAD	25 (60%)	20	5
LCx	2 (4.7%)	0	2
RCA	6 (14.3%)	5	1
Initial rhythm at cardiac arrest (n = 43)			
VF/VT	6 (14%)	2	4
PEA	28 (65%)	25	3
Asystole	9 (21%)	4	5

Background information of the 43 patients, the indication for the procedure in the cath lab, the culprit coronary artery and the initial rhythm at cardiac arrest. AMI: acute myocardial infarction, PCI: percutaneous coronary intervention, CABG: coronary artery bypass grafting, STEMI: ST elevation myocardial infarction, NSTEMI: non-ST elevation myocardial infarction, LM: left main artery, LAD: left anterior descending artery, Cx: left circumflex artery, RCA: right coronary artery, VT: ventricular tachycardia, VF: ventricular fibrillation, PEA: pulseless electrical activity.

Table 2
Procedural data of the 42 coronary patients.

Procedural data	n (%)	In hospital death	Discharged alive
Angiography only	6 (15%)	5	1
PCI successful	27 (76%)	16	11
PCI Unsuccessful	8 (24%)	8	0
Use of IABP	19 (43%)	9	10

The procedural data in the cath lab a technically successful PCI was defined as achieving a residual stenosis in the coronary artery of <50% with TIMI 2 or 3 blood flow. PCI: percutaneous coronary intervention, IABP: intraaortic balloon pump, TIMI blood flow: a grading scale developed by the Thrombolysis in Myocardial Infarction study group in which TIMI 2 or 3 indicates successful reperfusion.

2. Results

During the study period, a total of 6350 PCIs were performed of which 3058 patients were treated for acute ST-elevation myocardial infarctions (STEMI). A total of 118 patients were in cardiogenic shock and 81 required defibrillations due to VF or ventricular tachycardia (VT).

Mechanical chest compressions were used in 43 patients of which 31 (72%) were males. Patients were between ages 31 and 86 years (mean age: 73.3 years). The patients were admitted for STEMI, non-ST-elevation myocardial infarct (NSTEMI), elective PCI and pericardiocentesis (Table 1). The culprit artery was the left anterior descending artery (LAD) or the left main in 81% of the cases and 65% of the patients had PEA as the initial rhythm during cardiac arrest (Table 1).

A total of 36 PCIs were attempted in the 42 patients with coronary disease, of which 27 PCIs were considered 'technically successful' procedures defined as a residual stenosis <50% at the site of the target lesion and achieving TIMI 2 or TIMI 3 blood flow with ongoing mechanical chest compressions (Table 2).¹¹ Reasons for unsuccessful PCIs were primarily complex lesions, distal embolisation or no reflow in the coronary arteries and not primarily due to the use of LUCASTM. A total of 39 patients were treated with LUCASTM, and mean treatment time was 28.15 min (SEM ± 3.4, range: 1–90 min). Seventeen patients were discharged from the catheterisation laboratory, one with ongoing treatment with mechanical chest compressions and 16 with ROSC. Twenty-six patients were declared dead in the catheterisation laboratory (Fig. 2). In six of the coronary patients, no PCI was performed; in five cases, the reason was undiagnosed subacute myocardial rupture that suddenly became a fulminate rupture in the catheterisation laboratory and in one case, it was global ischaemia without any

obvious culprit lesion. All five patients with myocardial rupture and tamponade died. Three patients were referred for emergency cardiac surgery, of which two died during surgery and one postoperatively. In 31 patients, the PCI procedures were performed with ongoing mechanical chest compressions and in four patients, only an angiogram was performed during mechanical chest compressions. Of the 17 patients who were discharged from the catheterisation laboratory, 12 were eventually discharged from the hospital with 11 of them in CPC 1 (Fig. 2). The initial rhythm in the 12 patients discharged alive was VF in four patients, PEA in three patients and asystole in five patients. One of the discharged patients had incurred a serious hypoxic brain injury and later died at the referral hospital. One patient, who was successfully treated for cardiac tamponade, died at the oncology ward due to cancer, and one patient died post-procedurally in the ward due to therapy-resistant VF.

Of the 11 patients who were discharged in good condition, all underwent successful PCIs, and in eight of the cases the PCI was performed with ongoing LUCASTM, while in two cases, LUCASTM was used during the angiography. The mean treatment time of LUCASTM for the 11 survivors was 16.5 min (SEM ± 3.8, range: 1–50 min).

All 12 patients, who were discharged from hospital, suffered rib fractures and, possibly, sternal fractures. One of the survivors suffered a ruptured spleen and gastric ventricle due to user error. Six autopsies were performed on the remaining thirty-one patients who died, and rib fractures were seen in all six patients and sternal fractures in five patients. One autopsy showed a small bleeding around the aortic arch. No other potential injuries of consequence due to mechanical chest compressions were found.

During the study period, only four patients with a lengthy cardiac arrest were treated with manual chest compressions alone and all four patients died.

3. Discussion

We have retrospectively analysed the effect of using a mechanical chest compression device as an adjunctive treatment for patients who suffer extended periods of cardiac arrest following arrival in the catheterisation laboratory and found that >25% of the patients could eventually be discharged to their homes in good neurological condition (CPC 1).

Although approximately 2,000,000 patients undergo PCI yearly worldwide, during the procedure, only a very small minority of patients will suffer a protracted cardiac arrest episode that results in death.¹ However, performing effective manual chest compressions during a PCI in the catheterisation laboratory is linked with

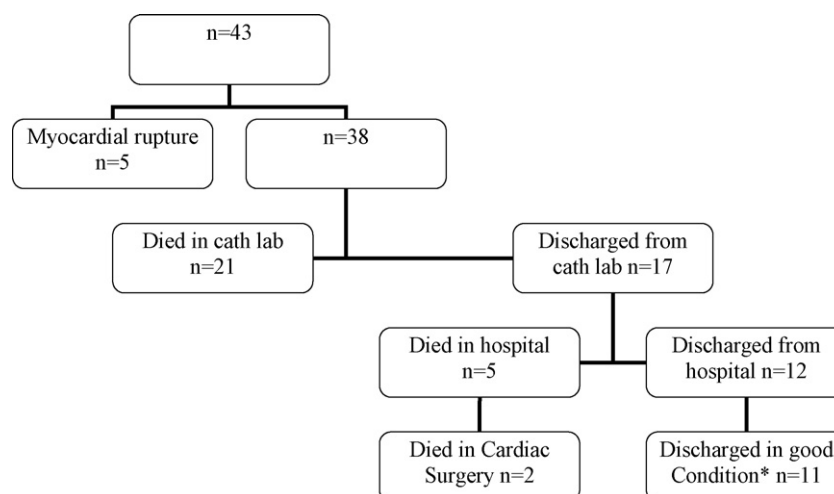


Fig. 2. Flow chart of the treatment and outcomes. Flow chart illustrating the treatment and outcomes of the patients in the study. *Cerebral Performance Categories, CPC 1.

extreme difficulties. Thus, it would be attractive to have a chest compression device that could deliver effective compressions while still allowing for continued PCI due to its radio-translucent design. LUCAS™ is one of two available mechanical chest compressions devices, the other being Autopulse™ (Zoll Medical Corporation, Chelmsford, MA, USA), which has been used in the catheterisation laboratory. With LUCAS™, due to the anterior–posterior (AP) design of the piston, essentially all views (such as cranial, caudal, RAO and LAO) except the straight AP are available during the time LUCAS™ is in place. Fortunately, the available views are almost always the preferred angiographic views during PCIs even without LUCAS™. Manoeuvring the X-ray detector around LUCAS™ is easily performed with a monoplane catheterisation laboratory and with more difficulty in a biplane laboratory. Although LUCAS™ produces an excessive movement of the chest and is somewhat bulky, it should still always be feasible, although not always easy, to perform a PCI. But if a high-precision manoeuvre is required, such as positioning a coronary stent, LUCAS™ can be temporarily paused for a few seconds, which remedies the situation of excessive chest movement during stenting.

How well does LUCAS™ work? From animal data, LUCAS™ been shown to maintain a positive coronary perfusion pressure and restore at least 60% of the cerebral blood flow in pigs.^{3,4} In one particular patient, LUCAS™ maintained circulation for 25 min, during which time the patient was in VF. Following PCI and defibrillation, the patient regained consciousness in the catheterisation laboratory and was later discharged in CPC 1.¹² In patients with cardiac arrest and ongoing treatment with LUCAS™, Larsen et al. found that a mean systolic blood pressure of 70 mmHg (range: 60–110 mmHg, $n = 11$) could be attained,⁸ which mirrors our own experience.

However, all of the patients in the study by Larsen et al. were already in cardiac arrest before arrival to the catheterisation laboratory and all these patients died. On the contrary, all the patients in our study arrived to the catheterisation laboratory with intact circulation and of these, 11 of 43 patients survived to discharge.

The main issue for patients in cardiac arrest is to restore circulation to the brain and only thereafter to attempt to remedy the cause of the cardiac arrest. Other means to solve restoration of blood flow in cardiac arrest in the catheterisation laboratory has been through percutaneous cardiopulmonary bypass (PCPB) or percutaneous left ventricular assist devices (PLVADs) such as Impella™ (Abiomed Inc., Danvers, MA, USA) or Tandem Heart™ (CardiacAssist Inc., Pittsburgh, PA, USA). Several small studies using PCPB in intractable cardiac arrest have been reported with good results.^{13–15} PCPB and PLVADs seem to be effective but are usually take longer to initiate and can require extra staff with special skills, such as a cardiovascular surgeon and a perfusionist. LUCAS™ may, on the other hand, be applied quickly (<1 min) and may also be used as a bridge to a PLVAD or PCPB.

There are several limitations to our study. First, we were unable to find any remaining recordings of continuous blood pressure measurements or coronary perfusion pressures during the periods of mechanical chest compressions, but in our experience, the circulation attained mirrors that found by Larsen et al. Second, two surviving patients had use of mechanical chest compressions for a limited time, less than 5 min. However, both patients had undergone treatment with CPR and manual compressions for several minutes prior to the application of LUCAS™. Third, this is a retrospective registry study and is limited in size. Still, our centre is the first one to ever use LUCAS™ during PCI in the catheterisation laboratory and we have collected a large cohort of patients, mainly from our STEMI population.

During the analysed period, mechanical chest compressions during prolonged CPR were not used in four patients who were either very old or suffering from severe co-morbidities.

Another issue of importance is if mechanical chest compressions cause more injuries to patients than manually performed chest compressions. Manual chest compressions are well known to cause traumatic complications^{16,17} and this is also likely to occur with mechanical chest compression devices to at least a similar degree.¹⁸ Reports of injuries caused by manual chest compressions are, however, difficult to compare due to different methodologies used,¹⁹ but a large ongoing randomised trial comparing manual chest compressions to mechanical chest compressions in out-of-hospital cardiac arrest will address this issue (the LINC study, see www.clinicaltrials.gov).

Among our patients, only one patient suffered severe injuries due to treatment with LUCAS™, but this was due to misapplication, as the LUCAS™ device was placed too low and started performing compressions in the upper abdomen, which caused traumatic rupture of both the gastric ventricle and the spleen. Both the gastric bleeding as well as the ruptured spleen was revealed and successfully treated during abdominal surgery following PCI. All survivors showed evidence of likely suffering from non-debilitating rib fractures and possibly sternal fractures. Similar injuries were seen in the limited number of autopsies performed on the deceased patients.

One patient suffered an anoxic brain injury. It is unclear why this occurred, but it is likely due to a delay in applying LUCAS™, as this was one of the early patients that LUCAS™ was used in, and this delay caused an insufficient cerebral perfusion leading to the injury.

Finally, one great advantage of mechanical chest compressions during cardiac arrest emergencies in the catheterisation laboratory is the ability to provide continuous chest compressions. Any interruption of chest compressions compromises both heart and brain blood flow. Such interruptions are a leading cause of poor outcome from cardiac arrest wherever it occurs. In circumstances where PCI or pericardiocentesis can correct the underlying cause of cardiac arrest, the provision of continued perfusion during such emergent procedures can result in not only lives being saved, but normal functioning neurological outcomes being achieved as well.²⁰

4. Conclusions

Mechanical chest compressions devices enable continued chest compressions during PCI with maintained circulation, which may reduce mortality in patients with cardiac arrest, requiring lengthy CPR, in the catheterisation laboratory, especially in patients with an initial rhythm of VF.

Conflict of interest statement

Dr. Olivecrona and Dr. Friberg have received lecture honorariums from Jolife AB, Lund, Sweden.

Acknowledgments

The authors thank Nurse Hans Olsson, Department of Anaesthesiology, Lund University Hospital, Lund, Sweden, for help in collection of data.

References

1. Webb JG, Solankhi NK, Chugh SK, et al. Incidence, correlates, and outcome of cardiac arrest associated with percutaneous coronary intervention. *The American Journal of Cardiology* 2002;90:1252–4.
2. Noc M, Benz B, Kern KB. Percutaneous coronary intervention (PCI) after successful reestablishment of spontaneous circulation and during cardiopulmonary resuscitation. In: Paradis NA, Halperin HR, Kern KB, Wenzel V, Chamberlain DA, editors. *Cardiac Arrest, the Science and Practice of Resuscitative Medicine*. 2nd ed. New York: Cambridge University Press; 2007. p. 764–71.

3. Steen S, Liao Q, Pierre L, Paskevicius A, Sjoberg T. Evaluation of LUCAS, a new device for automatic mechanical compression and active decompression resuscitation. *Resuscitation* 2002;55:285–99.
4. Rubertsson S, Karlsten R. Increased cortical cerebral blood flow with LUCAS; a new device for mechanical chest compressions compared to standard external compressions during experimental cardiopulmonary resuscitation. *Resuscitation* 2005;65:357–63.
5. Groggaard HK, Wik L, Eriksen M, Brekke M, Sunde K. Continuous mechanical chest compressions during cardiac arrest to facilitate restoration of coronary circulation with percutaneous coronary intervention. *Journal of the American College of Cardiology* 2007;50:1093–4.
6. Agostoni P, Cornelis K, Vermeersch P. Successful percutaneous treatment of an intraprocedural left main stent thrombosis with the support of an automatic mechanical chest compression device. *International Journal of Cardiology* 2008;124:e19–21.
7. Bonnemeier H, Olivecrona G, Simonis G, et al. Automated continuous chest compression for in-hospital cardiopulmonary resuscitation of patients with pulseless electrical activity: A report of five cases. *International Journal of Cardiology* 2008. August (Epub ahead of print).
8. Larsen AI, Hjernevik AS, Ellingsen CL, Nilsen DW. Cardiac arrest with continuous mechanical chest compression during percutaneous coronary intervention. A report on the use of the LUCAS device. *Resuscitation* 2007;75:454–9.
9. Nielsen N, Sandhall L, Schersten F, Friberg H, Olsson SE. Successful resuscitation with mechanical CPR, therapeutic hypothermia and coronary intervention during manual CPR after out-of-hospital cardiac arrest. *Resuscitation* 2005;65:111–3.
10. Jennett B, Bond M. Assessment of outcome after severe brain damage. *Lancet* 1975;305:480–4, 7905.
11. Nicklas JM, Diltz EA, O'Neill WW, Bourdillon PD, Walton Jr JA, Pitt B. Quantitative measurement of coronary flow during medical revascularization (thrombolysis or angioplasty) in patients with acute infarction. *Journal of the American College of Cardiology* 1987;10:284–9.
12. Olivecrona G. Mechanical Chest Compressions in a Patient with Left Main Closure During PCI. TCTMD.com, Cardiovascular Research Foundation, NY, NY [accessed 23 October, 2006 at <http://www.tctmd.com/Show.aspx?id=53760>].
13. Shawl FA, Domanski MJ, Wish MH, Davis M, Punja S, Hernandez TJ. Emergency cardiopulmonary bypass support in patients with cardiac arrest in the catheterization laboratory. *Catheterization and Cardiovascular Diagnosis* 1990;19:8–12.
14. Overlie PA. Emergency use of portable cardiopulmonary bypass. *Catheterization and Cardiovascular Diagnosis* 1990;20:27–31.
15. Mooney MR, Arom KV, Joyce LD</ET-AL>. Emergency cardiopulmonary bypass support in patients with cardiac arrest. *The Journal of Thoracic and Cardiovascular Surgery* 1991;101:450–4.
16. Hoke RS, Chamberlain D. Skeletal chest injuries secondary to cardiopulmonary resuscitation. *Resuscitation* 2004;63:327–38.
17. Baubin M, Rabl W, Pfeiffer KP, Benzer A, Gilly H. Chest injuries after active compression-decompression cardiopulmonary resuscitation (ACD-CPR) in cadavers. *Resuscitation* 1999;43:9–15.
18. Smekal D, Johansson J, Huzevka T, Rubertsson S. No difference in autopsy detected injuries in cardiac arrest patients treated with manual chest compressions compared with mechanical compressions with the LUCAS device: a pilot study. *Resuscitation* 2009;80:1104–7.
19. Wininger KL. Chest compressions: biomechanics and injury. *Radiologic Technology* 2007;78:269–74, 4.
20. Kern KB, Thai HM. Cardiac arrest and resuscitation during percutaneous coronary intervention. In: Butman SM, editor. *Complications of Percutaneous Coronary Interventions*. 1st ed. New York: Springer; 2005. p. 141–51.