Online May 23 2016
Journal of Neuroendovascular Therapy 2016; 10: 127–133
DOI: 10.5797/jnet.cr.2016-0005

Case Report

Successful Stentings for Bilateral Jugular Bulb Stenosis/Occlusion in a Case of Bilateral Transverse Sinuses Dural Arteriovenous Fistulas: Case Report

Takahiro Murata, Hisashi Nagashima, Shunsuke Ichinose, Toshiya Uchiyama, Jun-ichi Koyama, and Kazuhiro Hongo

Objective: We describe successful stentings for treatment of bilateral jugular bulb stenosis and occlusion in a case of dural arteriovenous fistulas (d-AVFs) of bilateral transverse sinuses.

Case Presentations: A 71-year-old woman presented with rapidly progressive cognitive impairment as well as consciousness disturbance, and cerebral angiography demonstrated d-AVFs of bilateral transverse sinuses, right jugular bulb occlusion, and left jugular bulb stenosis accompanied by marked intracranial venous congestion. The symptoms were temporarily alleviated after transarterial and transvenous embolization, but recurred one year later. Curative embolization was thought to be difficult, and stenting for stenosis/occlusion of the bilateral jugular bulbs, which were considered to be causing her symptoms, was performed and resulted in improvements in the condition.

Conclusion: Stent for treating sinus stenosis/occlusion accompanying d-AVF is effective to improve venous congestion and hypertension.

Keywords ▶ dural arteriovenous fistula (d-AVF), jugular bulb, percutaneous transluminal sinus stenting, sinus thrombosis, sinus stenosis

Introduction

Dural arteriovenous fistula (d-AVF) is often accompanied by stenosis or occlusion of the venous sinus due to sinus thrombosis, and sinus stenosis/occlusion is closely involved in the pathological condition and progression of d-AVF. The etiology of d-AVF and sinus stenosis/occlusion is controversial. It is known to be developed secondary to head trauma, surgical craniotomy, or sinus thrombosis. Several factors, including thrombi in the sinus, venous hypertension, and inflammation have been reported as etiologic factors of d-AVF.[1] On the other hand, the tendency that the presence of AV shunt promotes sinus thrombosis, leading to localization and resolution of the shunt with increases in the pressure in the sinus, has also been reported.[2] Sinus stenosis/occlusion is one of the important factors in the treatment for d-AVF.

Here, we experienced successful stent placements of the bilateral jugular bulbs in a patient with stenosis and occlusion of the bilateral jugular bulbs accompanying d-AVFs of the bilateral transverse sinuses (TSs), who had the onset with rapidly progressing dementia. Stenting resulted in reducing the increased venous pressure and succeeded in relieving the symptoms. We describe the details and discuss stenting for sinus stenosis/occlusion accompanying d-AVF.

Case Presentation

A 71-year-old woman developed an increased tendency to fall and cognitive impairment, 6 months before referral to us. She had a past history of pulmonary embolism and had taken oral warfarin. Her symptoms were progressive, and she became incapable of standing up or walking, and exhibited consciousness disturbance, 5 months after the onset. MR imaging demonstrated extensive edematous changes in the bilateral cerebral cortexes, and MR angiography suggested d-AVF. On admission, consciousness disturbance was marked with the Glasgow Coma Scale (GCS) score varying from 6–11;

Department of Neurosurgery, Shinshu University School of Medicine, Matsumoto, Nagano, Japan

Received: January 8, 2016; Accepted: April 20, 2016
Corresponding author: Takahiro Murata. Department of Neurosurgery, Shinshu University School of Medicine, 3-1-1, Asahi, Matsumoto, Nagano, Japan
Email: tmurata@shinshu-u.ac.jp

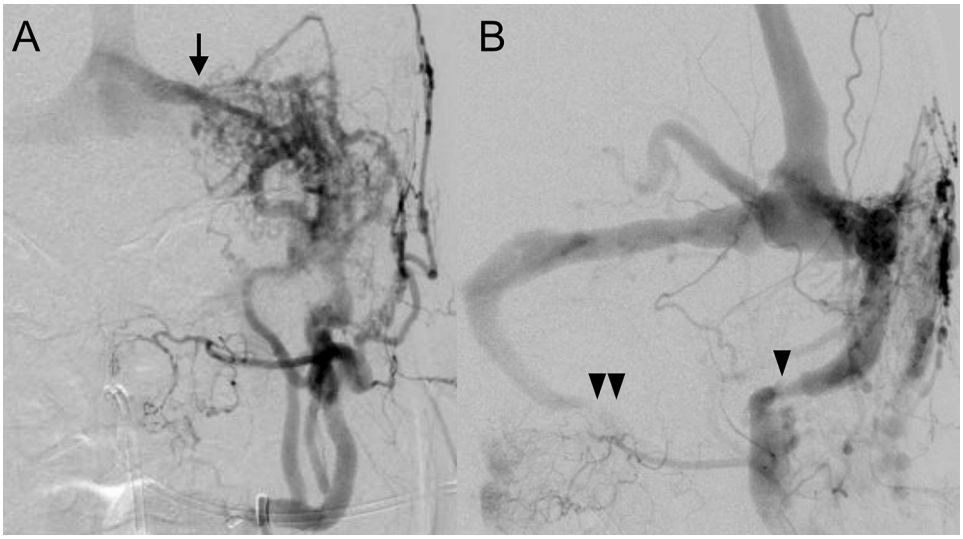

Fig. 1 (A) Frontal projection of the left external carotid artery (ECA) angiogram (early arterial phase) demonstrating left transverse sinus (TS) dural arteriovenous fistula (d-AVF) (arrow) with blood supply through the left occipital artery and middle meningeal artery. (B) Left antero-oblique (LAO) projection of the left ECA angiogram (late arterial phase) disclosing stenosis of the left jugular blub (single arrowhead) and occlusion of the right jugular bulb (double arrowheads).

aphasia and tetraparesis were noted, and completely dependent in her activity of daily living (ADL) including nasal tube feeding. Cerebral angiography revealed a high flow d-AVF involving the confluence of sinuses to the left TS (Fig. 1). The fistulas were fed by multiple branches of the bilateral external carotid arteries, including the occipital artery (OA), the middle meningeal artery (MMA), muscular branches and posterior meningeal artery (PMA) from the vertebral artery (VA). The venous flow was primarily drained into the left jugular vein antegradely, but stenosis was observed in the bulb (Fig. 1). The right jugular vein was occluded in the bulb and drained into the vertebral venous plexus through narrow channels. There was retrograde venous flow in the superior sagittal sinus (SSS) and straight sinus with marked cortical venous reflux. On bilateral internal carotid arteriography, no antegrade outflow of the cerebral venous circulation toward the SSS was noted, and intracranial venous congestion was observed.

Endovascular Therapy

1st intervention

MR imaging showed minor intracerebral hemorrhage, semi-urgent treatment was judged to be required. The treatment consisted of maximally possible transvenous embolization (TVE) of the dilated parallel venous channels near the left TS using 23 coils (165.5 cm) and transarterial embolization (TAE) of the bilateral MMAs and OAs using a liquid embolic agent. Decreasing the shunt flow gradually resolved consciousness disturbance after surgery, the second embolization was scheduled for further improvements.

2nd intervention

TVE in the dilated parallel venous channels below the confluence of sinus was achieved using 22 coils (192 cm). With sufficient anticoagulation treatment, percutaneous transluminal angioplasty (PTA) was achieved using a PTA balloon (Gateway 4.0 × 20 mm, Stryker, Kalamazoo, MI, USA) at a low pressure (4atm) in the stenotic portion of the left jugular bulb. With alleviation of stenosis, the antegrade venous drainage increased towards the left jugular vein, and intracranial venous circulation improved comparably prior to surgery despite persistence of cortical venous reflux.

Clinical course after the 1st and 2nd interventions

The decrease in the shunt flow and alleviation of stenosis of the venous outflow tract resulted in disappearance of edema of the cerebral cortex on MR imaging. Neurologically, her GCS score improved to 14, and Mini-Mental State Examination (MMSE) to 10, she was able to take food orally and was ambulatory. After hospitalization for rehabilitation, she became independent 3 months after the 2nd intervention. However, gait instability and cognitive impairment gradually recurred 1 year after the 2nd intervention, and her consciousness deteriorated. An MR imaging showed extensive edematous changes in the bilateral cerebral cortexes (Fig. 2), and cerebral angiography indicated

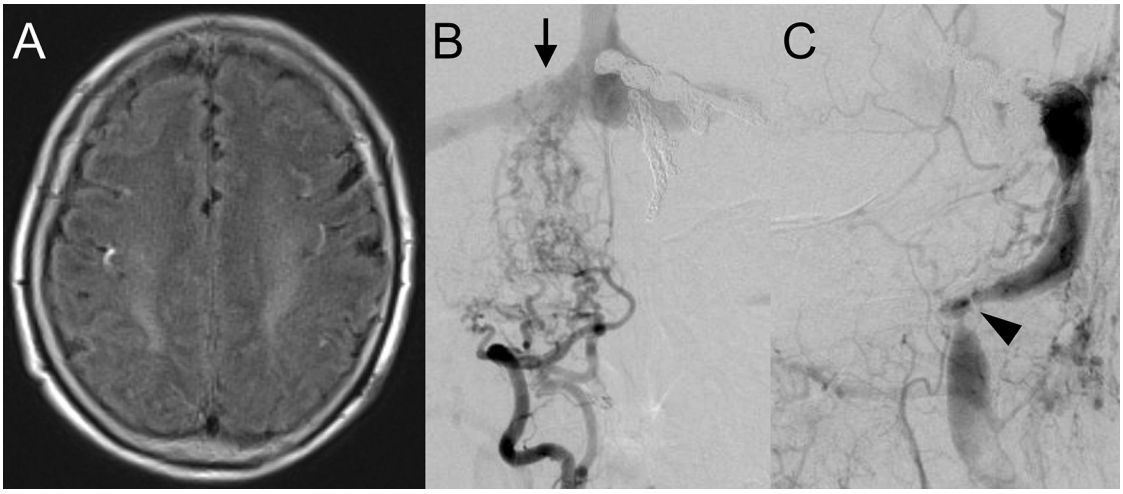

Fig. 2 (A) MR image (FLAIR) before 3rd intervention showing extensive cortical edema in the bilateral cerebral hemispheres. (B) Frontal projection of right vertebral artery (VA) angiogram (early arterial phase) showing that d-AVFs at the sinus confluence and the medial portion of right TS (arrow) are fed by the multiple feeders from muscular branches and the posterior meningeal artery of the right VA. Aggravation of these d-AVFs are also noted. (C) LAO projection of the left ECA angiogram (late arterial phase) demonstrating progressive stenosis of the left jugular bulb (arrowhead). d-AVF: dural arteriovenous fistula; ECA: external carotid artery; LAO: left antero-oblique; TS: transverse sinus

an increase in the shunt flow from the muscular branches and PMAs of the bilateral VAs, which persisted after the previous interventions, re-exacerbation of the left jugular bulb stenosis, and marked cortical venous reflux (Fig. 2).

3rd intervention

Curative occlusion of the remaining shunt would be difficult without total occlusion from the SSS to the bilateral TSs including the straight sinus and the confluence of sinuses, thus we decided to attempt PTA of the jugular bulb again for preservation of venous outflow tract. For stenosis of the left jugular bulb, dilation using a PTA balloon (Sterling 5.0 mm × 30 mm, Boston Scientific, Natick, MA, USA) was achieved. Also, as the occluded right jugular bulb could be pierced easily using a micro-guidewire, it was recanalized by dilation using a PTA balloon (Sterling 4.0 mm × 20 mm, Boston Scientific). With dilation of the bilateral jugular bulbs, cortical venous reflux was improved.

4th intervention

Three weeks after the 3rd treatment, stent placement was planned to prevent restenosis of the bilateral jugular bulbs with approval by the Shinshu University Hospital Ethics Committee. While continuing anticoagulant therapy (prothrombin-international normalized ratio: about 2.0), the administration of dual antiplatelet agents (aspirin, clopidogrel) was initiated before stenting, and the activated clotting time (ACT) was intraoperatively controlled over 200 seconds using heparin. Under local anesthesia, the left femoral vein was punctured, a 6-Fr guiding sheath (Shuttle, COOK MEDICAL, Bloomington, IN, USA) was placed in the right internal jugular vein, and the re-occluded right jugular bulb was recanalized using a microcatheter (Excelsior1018, Stryker) and a micro-guidewire (Chikai14, Asahi Intecc, Aichi, Japan). The micro-guidewire was exchanged to ChoICE PT Exchange 300 cm (Boston Scientific), and Aviator 4.0 mm × 20 mm (Cordis Endovascular, Miami Lakes, FL, USA) was used for pre-dilation, a self-expanding open-cell stent (Precise Pro RX 6.0 mm × 20 mm, Johnson & Johnson, Miami, FL, USA) was deployed to the occluded portion, and post-dilation was attempted using Shiden 5.0 mm × 20 mm (Kanaka Medix, Osaka, Japan) (Fig. 3). Next, a guiding sheath was advanced in the left jugular vein, the stenotic portion of the left jugular bulb was dilated as in the right jugular bulb using the same device, 2 stents (Precise Pro RX 8.0 mm × 30 mm) were deployed because of adjusting its curvature, and post-dilation was also attempted as the same manner (Fig. 3). Cerebral angiography after stent placements showed antegrade venous drainage of the cerebral circulation into the SSS, elimination of the cortical venous reflux from shunt, and the absence of acute occlusion or restenosis in the stents.

Results

Postoperative CT scan demonstrated that the stents were sufficiently expanded in the curved portion of the both jugular bulbs (Fig. 4). MR imaging after one month from stenting disclosed resolution of the cortical edema (Fig. 4), and MR venography clearly showed the patency of bilateral jugular veins (Fig. 4).

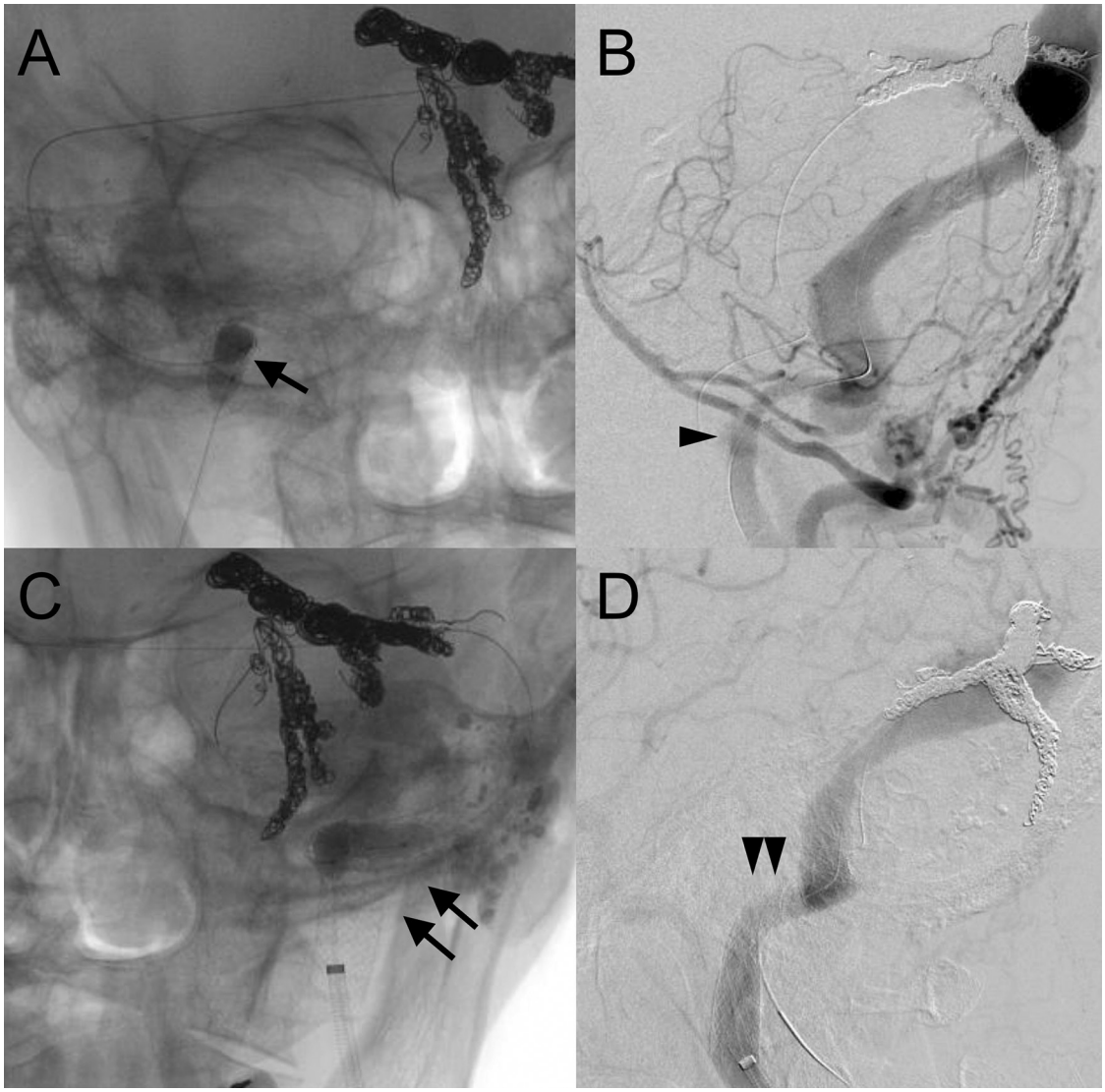

Fig. 3 (A) Frontal projection of fluoroscopic image during balloon dilatation of the right jugular bulb following stenting demonstrating sufficient dilatation of the occluded portion (single arrow). (B) Lateral projection of the right VA angiogram showing recanalization of the right jugular blub (single arrowhead). (C) Frontal projection of fluoroscopic image during balloon dilatation of the left jugular bulb after stent placement demonstrating sufficient dilatation of the stenotic portion (double arrows). (D) Lateral projection of the left CCA angiogram showing dilatation of the left jugular blub (double arrowheads). CCA: common carotid artery; VA: vertebral artery

Consequently antiplatelet medication was reduced to one drug. Neurologically, the GCS score improved to 15, and the MMSE to 22. She was ambulatory and discharged to home independently in her ADL. Although d-AVF remained, she was followed up without any neurological deterioration in an outpatient clinic, and the bilateral internal jugular veins were patent on MR venography 9 months after stent placements.

Discussion

In endovascular treatment for d-AVF, curative treatment is generally attempted by transvenous embolization in the affected venous sinus using coils. However, patients with diffuse AV shunts in the sinus and those with a shunt at the confluence of sinuses are difficult to treat, because occlusion of the affected sinus may cause serious impairment of cerebral venous drainage. The case presented here also had refractory d-AVF primarily involving the confluence of sinuses, and treatment decision was made to improve the intracranial venous drainage by relieving venous outflow tract obstruction because she showed marked neurological deterioration. In this case, d-AVF, which was preoperatively Borden Type II,[3] became Type I after stent placement, and her clinical symptoms were markedly alleviated. This

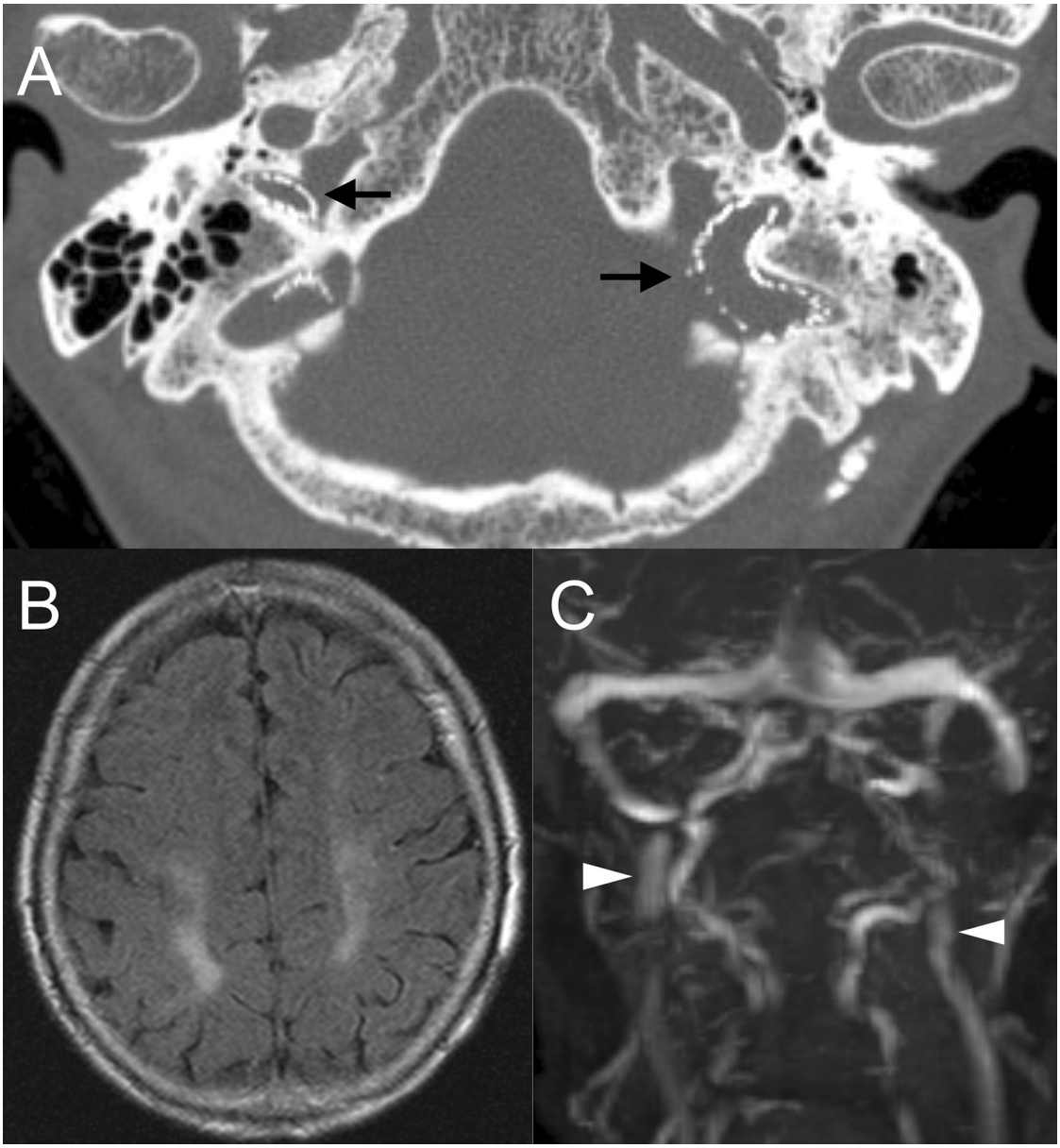

Fig. 4 (A) Post-stenting CT scan demonstrating that the stents in the both jugular bulb are sufficiently expanded (arrow). (B) MR image (FLAIR) after 1 month from stent placement showing disappearance of cortical edema. (C) Time-of-flight MR venography (frontal projection) after 1 month from stenting disclosing good patency of the both internal jugular veins (white arrowheads).

suggests that an increase in the venous pressure by two mechanisms, i.e., influx of arterial blood into the venous sinus via the shunt and outflow tract obstruction due to stenosis or occlusion of the venous sinus, is closely involved in the pathology of d-AVF. There have been a few reports of treatment in patients with stenosis/occlusion of the venous sinus associated with d-AVF for relieving venous outflow tract obstruction.[4,5] Haraguchi et al.[4] presented a case of transverse sinus-sigmoid sinus (TS-SS) d-AVF in which PTA achieved for marked stenosis of the contralateral TS-SS prior to radical treatment was useful and reported that, by measuring the pressure in the sinus before and after PTA, improvement of intracranial venous congestion and decrease in the pressure in the sinus could be confirmed after PTA. In the reported case, treatment was PTA alone without stent placement. In our case, stent was not placed at the 2nd intervention, because intracranial venous congestion was alleviated, and antegrade venous outflow was improved by dilation of the stenotic portion; however, stenting was eventually needed due to restenosis.

Stenting of the venous sinus for the treatment of d-AVF has been reported with recent advancements in the interventional techniques and devices.[5–11] In most reported cases, stenosis/occlusion was present in the affected sinus with AV shunt, and stent was placed in expectation of obliteration of the shunt site by compressing the sinus wall as well as preservation of the antegrade venous outflow tract by dilating the sinus. On the other hand, in a small number of reported cases, stents have been placed in the stenotic/occluded portion of the venous sinus distant from the affected sinus similar our case.[5] Stents have often been placed not only in the TS to SS,[6–8] but also in the SSS[9,10] or straight sinus.[5,11] The stents used were often balloon- or self-expanding closed-cell type,[5–7,9,11] but a few instances of balloon-expanding covered stent have also been reported.[8,10] There have been no reports on stenting for stenosis/occlusion of the jugular bulb and placement of an open-cell stent in the sinus in the literatures. Since the jugular bulb is surrounded by the skull base and markedly curved, we obtained favorable results by deploying open-cell stents with excellent conformation to curvature.

However, as stents were placed in the venous sinus while persisting d-AVF in our case, prevention of restenosis/reocclusion due to in-stent thrombosis is an important issue. Levrier et al.[7] reported stent placement in ten patients with the TS-SS d-AVF and observed postoperative cerebral hemorrhage in one patient for whom postoperative antithrombotic treatment was not given. This hemorrhage was suspected to be caused by occlusion of the cortical vein due to thrombosis, they administered clopidogrel from before surgery until 3 months after surgery in the subsequent patients. Spiotta et al.[10] reported a case that received placement of a covered stent for d-AVF of the SSS to the confluence of sinuses but developed occlusion of the SSS due to in-stent thrombosis on the 4th postoperative day despite sufficient postoperative antithrombotic treatment consisting of oral administration of aspirin and clopidogrel and intravenous administration of heparin. This reported patient had a factor V Leiden thrombophilia liable to venous thromboembolism, which suggested inducing in-stent thrombus formation. Since our patient also had a past history of pulmonary embolism, she might have some latent clotting abnormality. As she exhibited a slight sign of cerebral hemorrhage at the initial intervention, the shunt flow was reduced by TVE and TAE, and PTA was achieved at the 2nd and 3rd interventions with sufficient anticoagulation therapy. Currently, there is no consensus as to perioperative antithrombotic therapy or its period for stenting in the venous sinus, and they vary with the type of stent. However, there have been many reports of oral antiplatelet medication combined with intravenous or oral administration of anticoagulants in the acute period,[8,10,11] and the duration of antiplatelet medication was diverse. At the 4th intervention, we placed stent grafts with sufficient antithrombotic therapy from before surgery using dual antiplatelets and an anticoagulant and could obtain a favorable outcome without occlusion. d-AVF is closely related to venous sinus thrombosis, and since there may be hypercoagulable state or nonhereditary thrombogenic tendency such as protein C deficiency in the patient's background, indications for stenting in patients with d-AVF must be carefully evaluated. However, satisfactory results may be obtained by stepwise treatment from PTA to stenting and appropriate antithrombotic therapy as well as proper selection of patients.

Conclusion

A case of bilateral TSs d-AVF successfully treated by stenting for stenosis and occlusion of the bilateral jugular bulbs was presented. Stent placement is effective for the treatment of stenosis/occlusion of the venous sinus causing venous outflow tract obstruction or venous hypertension. d-AVF is closely related to venous sinus thrombosis, and stenting for such conditions requires antithrombotic treatment appropriate for each case.

Disclosure Statement

None of the authors has conflicts of interest in reporting the present case.

References

1) Lasjaunias P, Berenstein A: Surgical Neuroangiography. Vol 2.2. Springer-Verlag. Germany, 2004, 565–607.
2) Satomi J, Satoh K, Matsubara S, et al: Angiographic changes in venous drainage of cavernous sinus dural arteriovenous fistulae after palliative transarterial embolization or observational management: a proposed stage classification. *Neurosurgery* 2005; 56: 494–502; discussion 494–502.
3) Borden JA, Wu JK, Shucart WA: A proposed classification for spinal and cranial dural arteriovenous fistulous malformations and implications for treatment. *J Neurosurg* 1995; 82: 166–179.
4) Haraguchi K, Matsumoto Y, Kondo R, et al: Percutaneous transluminal sinus angioplasty for transverse sinus-sigmoid sinus stenosis associated with recurrent dural arteriovenous fistula: case report. *JNET* 2010; 4: 33–39. (in Japanese)
5) Troffkin NA, Graham CB, Berkmen T, et al: Combined transvenous and transarterial embolization of a tentorial-incisural

dural arteriovenous malformation followed by primary stent placement in the associated stenotic straight sinus. Case report. *J Neurosurg* 2003; 99: 579–583.

6) Murphy KJ, Gailloud P, Venbrux A, et al: Endovascular treatment of a grade IV transverse sinus dural arteriovenous fistula by sinus recanalization, angioplasty, and stent placement: technical case report. *Neurosurgery* 2000; 46: 497–500; discussion 500–501.
7) Levrier O, Métellus P, Fuentes S, et al: Use of a self-expanding stent with balloon angioplasty in the treatment of dural arteriovenous fistulas involving the transverse and/or sigmoid sinus: functional and neuroimaging-based outcome in 10 patients. *J Neurosurg* 2006; 104: 254–263.
8) Choi BJ, Lee TH, Kim CW, et al: Reconstructive treatment using a stent graft for a dural arteriovenous fistula of the transverse sinus in the case of hypoplasia of the contralateral venous sinuses: technical case report. *Neurosurgery* 2009; 65: E994–E996; discussion E996.
9) Ohara N, Toyota S, Kobayashi M, et al: Superior sagittal sinus dural arteriovenous fistulas treated by stent placement for an occluded sinus and transarterial embolization. A case report. *Interv Neuroradiol* 2012; 18: 333–340.
10) Spiotta AM, Sivapatham T, Hussain MS, et al: Combined surgical and endovascular approach to a complex dural arteriovenous fistula involving the superior sagittal sinus and torcula. *J Stroke Cerebrovasc Dis* 2012; 21: 283–288.
11) Takada S, Isaka F, Nakakuki T, et al: Torcular dural arteriovenous fistula treated via stent placement and angioplasty in the affected straight and transverse sinuses: case report. *J Neurosurg* 2015; 122: 1208–1213.