

## Prokinetic effects of mirtazapine on gastrointestinal transit

Jieyun Yin,<sup>1</sup> Jun Song,<sup>1</sup> Yong Lei,<sup>3</sup> Xiaohong Xu,<sup>3</sup> and Jiande D. Z. Chen<sup>1,2,3</sup>

<sup>1</sup>Division of Gastroenterology, University of Texas Medical Branch, Galveston, Texas; <sup>2</sup>Ningbo Pace Translational Medical Research Center, Ningbo, China; and <sup>3</sup>Veterans Research and Education Foundation, VA Medical Center, Oklahoma City, Oklahoma

Submitted 26 April 2013; accepted in final form 24 February 2014

**Yin J, Song J, Lei Y, Xu X, Chen JD.** Prokinetic effects of mirtazapine on gastrointestinal transit. *Am J Physiol Gastrointest Liver Physiol* 306: G796–G801, 2014. First published March 13, 2014; doi:10.1152/ajpgi.00130.2013.—Mirtazapine is a noradrenergic and specific serotonergic antidepressant. The aim of this study was to investigate the effects of mirtazapine on gastrointestinal motility in dogs, including solid gastric emptying, antral and small intestinal contractions, and small intestinal and colonic transit. Six dogs were implanted with two cannulas located at the duodenum and the ascending colon; another six dogs were implanted with gastric cannula 6 cm proximal to the pylorus. Mirtazapine 45 mg was administered orally 90 min before the study. We found that 1) Mirtazapine accelerated gastric emptying during the entire 3 h in normal dogs ( $P < 0.04$ ) and accelerated delayed gastric emptying induced by rectal distention ( $P < 0.04$ ). 2) Mirtazapine restored impaired gastric tone and accommodation induced by rectal distention ( $P < 0.05$ ). 3) No significant changes were noted in small intestinal contractions or transit with mirtazapine ( $P > 0.1$ ). 4) Mirtazapine accelerated colonic transit at 2 and 4 h but not 6 h. The geometric center was increased from  $1.9 \pm 0.6$  to  $3.0 \pm 0.5$  and  $3.9 \pm 0.5$  to  $4.7 \pm 0.1$  at 2 and 4 h respectively ( $P = 0.04$  vs. corresponding control). In conclusion, mirtazapine improves gastric emptying in healthy dogs and normalizes rectal distention-induced delay in gastric emptying and accelerates colon but not small intestinal transit in healthy dogs. Clinical studies are warranted to assess the effects of mirtazapine on gastrointestinal motility and sensory functions in patients with functional gastrointestinal diseases.

antidepressant; gastrointestinal motility; gastric emptying; colonic transit; rectal distention

DELAYED GASTRIC EMPTYING IS reported frequently in various gastrointestinal (GI) motility disorders, such as gastroesophageal reflux disease, functional dyspepsia, and gastroparesis (25, 28, 35). Delayed gastric emptying is associated with upper gastric symptoms such as nausea, vomiting, fullness, bloating, and early satiety (25). Prokinetics are the first-line medicine for treating delayed gastric emptying. However, there is a poor correlation between the acceleration of gastric emptying and the improvement of gastric symptoms with prokinetics (27).

Upper GI symptoms are common in patients with lower GI motility disorders. It is reported that 30–50% of patients with functional GI disorders had both functional dyspepsia (FD) and irritable bowel syndrome (IBS) (23, 37). Patients with constipation-dominant IBS reported significantly more overall GI symptoms compared with the patients with diarrhea-dominant IBS (37). One study has reported that 90% patients with overlapping symptoms exhibited rectal intolerance to disten-

tion (4). Currently, there is lack of effective medications for treating both upper and lower GI symptoms.

Antidepressants are often prescribed in patients with IBS or FD (7, 17, 24). Their efficacy on treating IBS may be attributed to a reduction in visceral sensation and a relief of depression (5). The rationale for the use of antidepressants in FD was considered to reduce the severity of psychological symptoms: central analgesic actions and local pharmacological actions on the upper gut (38). However, the effects of antidepressants on the GI motility have not been reported frequently. Mirtazapine was reported to act on both noradrenergic and serotonergic systems, suggesting a brand-new antidepressive mechanism compared with other antidepressants. It increases the release of norepinephrine (NE) and serotonin (5-hydroxytryptamine, 5-HT) by blocking presynaptic  $\alpha_2$ -adrenergic receptors (11, 16). Recently, it was reported that mirtazapine reduced visceral hypersensitivity and accelerated liquid gastric emptying in rats with neonatal colon sensitivity (42). Clinic case report showed that mirtazapine was effective in treating severe gastroparesis unresponsive to the conventional prokinetic treatment (29); in a patient with diabetic gastroparesis who is recalcitrant to first-line treatment, mirtazapine improved gastroparetic symptoms (20). We therefore hypothesized that mirtazapine might have a prokinetic effect on GI motility.

The aim of this study was to investigate the effect of mirtazapine on GI motility in a canine model under normal conditions and during rectal distention. Experiments were designed to assess the possible prokinetic effects of mirtazapine on solid gastric emptying and on small intestinal and colonic transit.

### MATERIALS AND METHODS

#### *Animal Model and Surgical Procedures*

Twelve healthy female hound dogs (22–26 kg) were used. Under general anesthesia, in six of the dogs, two cannulas were implanted in each animal: one at the duodenum, 20 cm distal to the pylorus for the assessment of solid gastric emptying and small intestinal motility, and the other at the ascending colon, 6 cm distal to the cecum for the measurement of colonic motility. In the other six dogs, a gastric cannula was implanted at the anterior wall of the stomach 6 cm proximal to the pylorus for assessing gastric tone and accommodation. The study was initiated after the dogs were completely recovered from the surgery, usually 2 wk after the operation. The study was approved by the Animal Care and Use Committee at both the University of Texas Medical Branch at Galveston, Texas, and VA Medical Center, Oklahoma City, Oklahoma.

#### *Experimental Protocols*

*Experiment 1: assessment of complete gastric emptying of solid.* This experiment was performed in six dogs with a duodenal cannula. Each dog was studied in one session. The purpose of this session was

Address for reprint requests and other correspondence: J. Yin, Division of Gastroenterology, Route 0655, Galveston, TX 77555-0655 (e-mail: jieyunyin07@gmail.com).

to measure the total gastric emptying of solids and to determine the percentage of gastric chyme we were able to collect for complete gastric emptying. The experiment was needed because some gastric chyme might bypass the duodenal cannula and flow distally to the small intestine. After an overnight fast, each dog was fed with 375 g of solid dog food (413 kcal, Pedigree, Chopped Chicken). Immediately after the ingestion of the test meal, the duodenal cannula was opened for collecting gastric chyme emptied from the stomach. The chyme was collected every 15 min for the first hour and every 30 min for subsequent hours. The collection was continued for about 8 h until the completion of gastric emptying (nothing except secretion was collected from the cannula for a period of 30 min). The amount of total collections was defined as 100% gastric emptying.

*Experiment 2: effects of mirtazapine on solid gastric emptying.* The same six dogs from *experiment 1* were used in this experiment. Each dog was studied in four sessions on separate days in a randomized order: control, mirtazapine (Remeron, Rockford, IL), rectal distention (RD), and RD + mirtazapine. In the control session, no medication was given. Since our aim was to study the effect of mirtazapine on GI transit, and antidepressants are often used to treat patients with functional GI diseases. Clinically, the tablet of mirtazapine is mixed with the vehicle; it is therefore more relevant for us to compare the difference between the use of mirtazapine tablets and no medication at all. The method of gastric emptying was the same as in *experiment 1* except that the total measurement time was 3 h; the duration was chosen on the basis of a previous study indicating that more than 80% of the solids were emptied during the first 3 h (40). Mirtazapine (45 mg) was administered orally 1.5 h prior to the meal. The dose of 45 mg was chosen on the basis of the dosage used in clinic (30 mg/day) (7); since the dosage of 30 mg/day was for chronic treatment and the present study was acute, we chose a higher dose of 45 mg. The half-life of mirtazapine was reported to be  $14 \pm 3$  h with a single oral dose of 45 mg (19). In the two sessions with RD, RD was performed 60–90 min after the meal. From preliminary studies, we observed that gastric emptying of solid was the fastest 60–90 min after the meal and therefore RD was performed during that period (40). RD was achieved by the inflation of a latex balloon inserted into the rectum with 120 ml of air (6).

*Experiment 3: effects of mirtazapine on gastric tone and accommodation.* The experiment was performed in six dogs with the gastric cannula. Each dog was studied for four sessions in a randomized order: control, mirtazapine (45 mg), RD, and RD + mirtazapine (45 mg). Gastric tone and accommodation were assessed using an established method of Barostat (Distender Series IIR, G & J Electronics, Willowdale, Ontario, Canada) (36, 41, 45). Gastric volume was recorded for 30 min in the fasting state and 30 min after a liquid meal (237 ml, 240 kcal, Boost) in the sessions without RD, and for 60 min in the fasting state and 60 min after the liquid meal in the sessions with RD, in which RD was performed during the second 30-min fasting period and first 30-min postprandial period.

*Experiment 4: effects of mirtazapine on small intestinal contractions and transit.* This experiment was performed in the same six dogs as in *experiment 1*. It consisted of two sessions on 2 separate days in a randomized order: control and mirtazapine 45 mg. After an overnight fast, each dog was fed with a 375-g solid meal to induce postprandial small intestinal contractions. Small intestinal contractions were then recorded for 60 min after the meal.

Small intestinal transit was assessed simultaneously with gastric emptying in *experiment 1* in two of the sessions: control and mirtazapine. Immediately after the meal, a 30-ml solution with phenol red (0.5 mg/ml, dissolved in saline) was injected through the duodenal cannula, then 50 ml saline was injected every 30 min until the end of the experiment; these saline injections were used to offset the diversion of gastric secretion and chyme from the duodenum cannula. Samples through the colonic cannula were collected every 15 min during the experiment and small intestinal transit was determined by the time of first appearance of phenol red from the colonic cannula.

The appearance of phenol red in the colonic collection was verified by spectrophotometer after the experiment.

*Experiment 5: effects of mirtazapine on colon transit.* Each dog was studied in two randomized sessions with an interval of 3–5 days: control and mirtazapine. After an overnight fast, mirtazapine 45 mg was administered orally 1.5 h prior to the experiment. The experiment was initiated immediately after the insertion of a capsule containing 24 radiopaque markers (Sitzmarks, Konsyl Pharmaceuticals, Easton, MD) through the colonic cannula. Before inserting the Sitzmarks, we flushed the colon gently with 20 ml saline through the colonic cannula. The capsule was dissolved in the colon within 10 min. Abdominal X-ray was performed at 2, 4, and 6 h after the insertion of the capsule. To avoid possible stress effects, the animals were acclimated to X-ray film taking several times a week before the initiation of the colon transit test.

#### Measurements and Analyses

*Measurement of solid gastric emptying.* The collected chyme samples from the duodenal cannula were centrifuged for 20 min (3,000 rpm). After centrifugation, each sample was placed in a  $-20^{\circ}\text{C}$  refrigerator for 4 h and then kept for 30–45 min at room temperature; in this way, the total sample in each tube was completely transferred. The entire precipitate of each collection was then taken out, placed in a paper plate, and dried in air for a few days until there were no changes in weight. The percentage of gastric emptying for each collection was calculated by using the following formula: % gastric emptying for each collection =  $\text{Wn}/\text{Wt} \times 100\%$ , where Wn was the dried weight of the collection and Wt was the total dried weight of all samples collected in the same dog in *experiment 1* (40). This normalized percentage of gastric emptying compensated for any possible loss of ingested food, such as bypass of gastric chyme to the distal small intestine and any absorption that might have occurred before the collection from the duodenal cannula.

*Measurement of gastric tone and accommodation.* Gastric tone was assessed from the measured gastric volume. At the constant operating pressure, an increase in gastric volume reflects a decrease in gastric tone, and vice versa. Gastric accommodation was calculated by the difference in gastric volume before and after a meal.

*Measurement and analysis of small intestinal contractions.* Small intestinal contractions were measured by the same manometric system. All pressure sensors were located in the jejunum with the most proximal one 15 cm distal to the duodenal cannula. Intestinal contractions measured from the middle sensor, which was 25 cm distal to the duodenal cannula, showed the best quality and were chosen to be analyzed (43), from 0 to 60 min.

*Measurement of colonic transit.* Colonic transit was assessed by counting the numbers of radiopaque markers from X-ray films in different segments of the colon at different time points. The colon was divided into five segments, including ascending colon (*segment 1*), transverse colon, splenic flexure, descending colon, and rectum (*segment 5*); the markers expelled out from the anus were considered to be in *segment 6*. The geometric center (GC) of the markers was used to represent colon transit and calculated as follows:

$$\text{GC} = \sum (\text{P}_n n) / 24 \text{ for } n = 1, 2, 3, 4, 5, 6$$

where  $\text{P}_n$  was the number of radiopaque markers in the  $n$ th segment and  $n$  was the number of the segment.

#### Statistical Analysis

All data are presented as means  $\pm$  SE. One-way ANOVA was used to investigate differences in gastric emptying and GC at different time points among various sessions. Paired *t*-test was used to evaluate differences in antral contractions and small intestinal motility between control and mirtazapine. A *P* value of  $< 0.05$  was considered statistically significant.

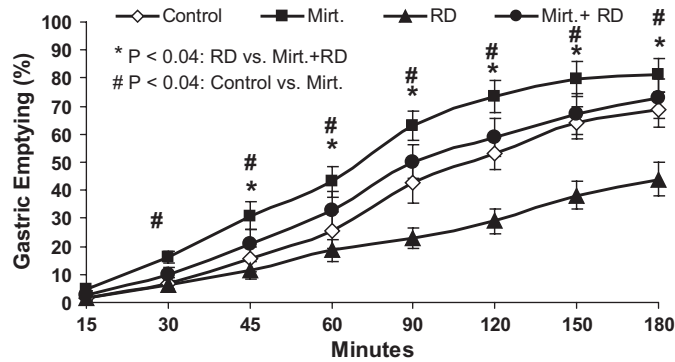


Fig. 1. Effects of mirtazapine (Mirt.) on solid gastric emptying. Mirtazapine significantly accelerated gastric emptying in the normal condition ( $P < 0.04$ ). In addition, mirtazapine normalized delayed gastric emptying in dogs with rectal distention (RD) ( $P < 0.04$ ).

## RESULTS

### Effects of Mirtazapine on Solid Gastric Emptying and Antral Contractions

Under normal condition without RD, mirtazapine accelerated gastric emptying during the entire 3-h experimental period (Fig. 1). Compared with the control session, gastric emptying was accelerated with mirtazapine by 48.1% at 90 min ( $P < 0.01$ ), 38.2% at 120 min ( $P = 0.02$ ), and 17.7% at 180 min ( $P = 0.03$ ).

RD during 60–90 min substantially delayed gastric emptying (Fig. 1). Gastric emptying was reduced with RD by 46.2% at 90 min ( $P < 0.01$ ), 45.2% at 120 min ( $P < 0.001$ ), and 36.3% at 180 min ( $P < 0.01$ ). As shown in Fig. 1, mirtazapine accelerated gastric emptying during 45–60 min without RD and normalized RD-induced delayed gastric emptying during 90–180 min: the percentages of gastric emptying during 90–180 min in the session with RD and mirtazapine were comparable to those in the control session without RD. The acceleration before the administration of RD confirmed that mirtazapine was able to increase gastric emptying even under the normal condition.

Consistent with the findings on gastric emptying data, mirtazapine enhanced antral contractions in the fed state. As shown in Fig. 2, the contractile index (sample-by-sample average of manometric data) was increased from  $8.0 \pm 0.7$  mmHg in the control session to  $12.9 \pm 3.0$  mmHg with mirtazapine ( $P = 0.03$ ).

### Effects of Mirtazapine on Gastric Tone and Accommodation

Mirtazapine had no effects on gastric tone or gastric accommodation in the normal physiological condition (without RD). RD significantly reduced both gastric tone and gastric accommodation, whereas mirtazapine partially blocked the inhibitory effects of RD on gastric tone and gastric accommodation. The RD-induced increase in gastric volume in the fasting state was  $253.6 \pm 61.1\%$  without mirtazapine and  $97.8 \pm 23.1\%$  with mirtazapine ( $P = 0.03$ ). Gastric accommodation was  $149.4 \pm 29.8$  ml with RD and  $290.9 \pm 45.7$  ml with RD plus mirtazapine ( $P = 0.012$ ) (Fig. 3).

### Effects of Mirtazapine on Small Intestinal Transit and Contractions

Mirtazapine had no effect on either small intestinal transit or contractions. The small intestinal transit, represented by the first appearance of phenol red in the colon cannula, was not different between the control and mirtazapine sessions ( $137.8 \pm 19.3$  min vs.  $150.0 \pm 17.4$  min,  $P = 0.3$ , Fig. 4). Neither was there a difference in the small intestinal contractions between the two sessions. The postprandial small intestinal contractile index was  $10.6 \pm 1.4$  mmHg in the control session and  $13.6 \pm 3.7$  mmHg with mirtazapine ( $P = 0.2$ , Fig. 4).

### Effects of Mirtazapine on Colonic Transit

Mirtazapine accelerated colonic transit at 2 and 4 h after the insertion of the markers from the colon cannula. As shown in Fig. 5, the GC was increased from  $1.9 \pm 0.6$  to  $3.0 \pm 0.5$  at 2 h and  $3.9 \pm 0.5$  to  $4.7 \pm 0.1$  at 4 h ( $P = 0.04$ , control vs. mirtazapine at both time points). At 6 h, the GC became similar between the two sessions since most of the markers were in the rectum ( $5.0 \pm 0.1$  vs.  $5.0 \pm 0.1$ ,  $P = 0.5$ ).

## DISCUSSION

In the present study, we have found that mirtazapine accelerated solid gastric emptying in dogs with or without RD. Mirtazapine also accelerated colonic transit but showed no effects on small intestinal transit or contractions.

Delayed gastric emptying is common in patients with GI motility disorders, such as FD and gastroparesis. Treatment options for FD and gastroparesis are very limited. Although prokinetics stimulate peristalsis and improve gastric pump functions by enhancing antral contractility, electrical rhythm, and/or antroduodenal coordination, sometimes they do not result in significant symptom improvement (27, 34). This is because patients with delayed gastric emptying often have impaired gastric accommodation and/or visceral hypersensitivity. The failure of certain prokinetics on improving symptoms may be attributed to their detrimental effects on gastric accommodation and/or ineffectiveness in improving visceral hypersensitivity.

Because of the lack of effective therapies on functional GI motility disorders, antidepressants are commonly prescribed in

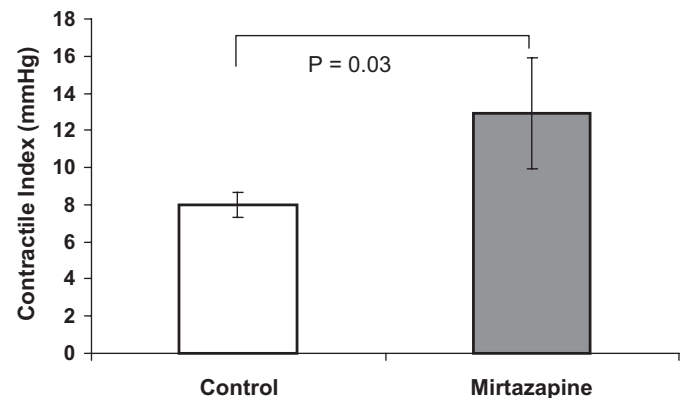


Fig. 2. Effects of mirtazapine on postprandial antral contractions in dogs under normal condition. Mirtazapine significantly enhanced antral contractions compared with the control session ( $P = 0.03$ ).

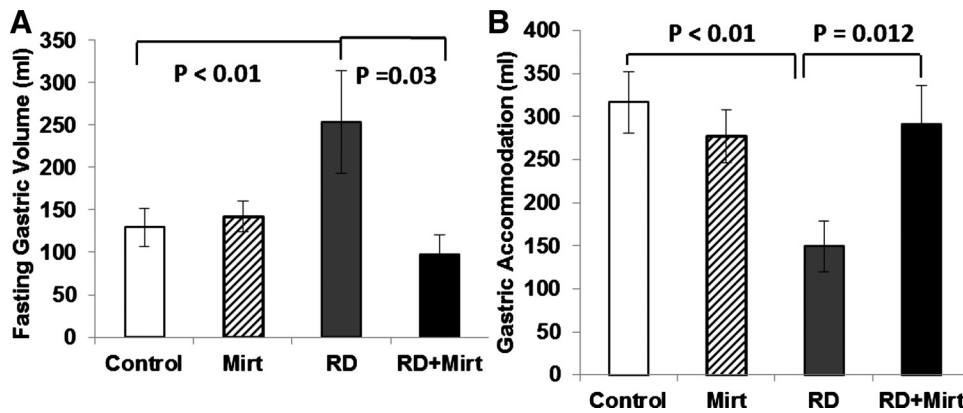


Fig. 3. Effects of mirtazapine on gastric sensitivity to rectal distention. Rectal distention significantly reduced gastric tone and accommodation. Mirtazapine restored rectal distention induced reduced gastric tone (A) and accommodation (B) ( $P < 0.05$ ).

clinic practices, such as tricyclic antidepressants and selective serotonin reuptake inhibitor. It is conceivable to treat functional GI disorders with antidepressants because these drugs are used to treat depression and reduce chronic pain. However, the evidence is conflicting and there is lack of large controlled trials. Mirtazapine is a noradrenergic and specific serotonergic antidepressant, a newer class of antidepressant that is characterized by a potent antagonism of presynaptic  $\alpha_2$  adrenergic receptors on both NE and serotonin neurons (11). While treating depression, mirtazapine was noticed to be beneficial for bowel movement in IBS patients (39). In patients with severe gastroparesis unresponsive to the conventional prokinetic treatment, refractory nausea and vomiting that persisted for over 7 mo were improved dramatically within a few days of once-daily mirtazapine dosing (29). In a previous study, we observed improvement of gastric emptying with mirtazapine in colonic sensitized “IBS-like” rats (42). In the present canine study, we found that mirtazapine improved gastric emptying, gastric accommodation, and colon transit; this was different from what was reported in a clinical study in which mirtazapine showed no effects on gastric emptying in healthy volunteers (7). The difference might be attributed to the differences in species (dogs vs. humans), dosage (45 mg vs. 30 mg), and/or duration of the study (acute vs. chronic).

There were at least two limitations in the present study: lack of dose-response study and absence of chronic repetitive study. A dose-responsive study was, however, performed in our previous study investigating the ameliorating effect of mirtazapine on neonatal rectal distention-induced gastric hypersensitivity. The absence of any data on repetitive chronic study was attributed to the fact that the present canine model with

rectal distention was not suitable for such a study; rectal distention was performed to induce delayed gastric emptying; however, it was only convenient for assessing acute effects but not adequate for a chronic study.

Overlapping syndrome is common in clinic practice; upper GI dyspepsia symptoms are often present in patients with lower GI tract disorders, such as constipation. The mechanisms have not been elucidated and there is lack of satisfactory treatment options for overlapping syndromes. Fecal or gas distention might be one of the major contributing factors in producing upper GI symptoms in patients with lower GI dysmotility. Rectal balloon distention was reported to induce upper GI symptoms, inhibit gastric tone and accommodation, and delay gastric emptying (2, 31, 44), and it is considered one of the constipation models commonly used in the study of upper GI motor activities. In the present study, in addition to testing the effect of mirtazapine on solid gastric emptying in normal dogs, RD was used to mimic fecal or gas stasis in the colorectal region. We found that RD at 60–90 min substantially delayed gastric emptying from 90 min to 180 min, whereas mirtazapine normalized RD-induced delayed in gastric emptying. Moreover, mirtazapine restored RD-induced reduced gastric tone and accommodation. The changes of gastric sensitivity and gastric emptying may explain the improvements of symptoms in patients with gastroparesis reported in the clinic practice. The normalization of RD-induced delay in gastric emptying and the acceleration of colon transit suggest that mirtazapine may have a therapeutic potential for treating patients with symptoms attributed to both upper and lower GI motility disorders.

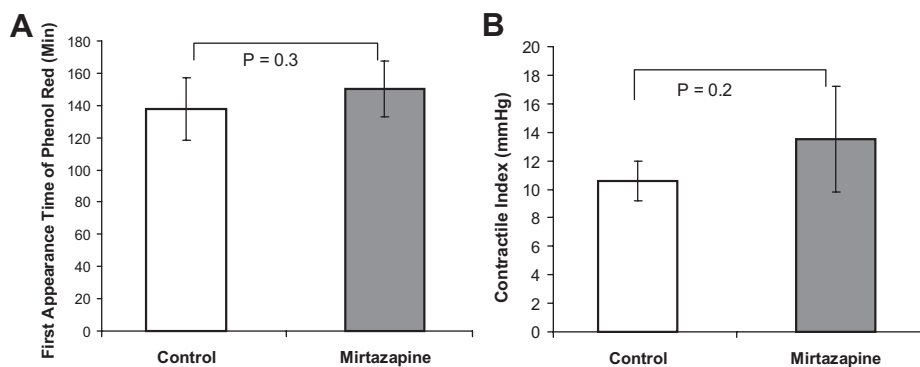


Fig. 4. Effects of mirtazapine on small intestinal motility. The small intestinal transit was not different between the control and mirtazapine sessions ( $P = 0.3$ ) (A); neither was there a difference in small intestinal contractions between the control and mirtazapine sessions ( $P = 0.2$ ) (B).

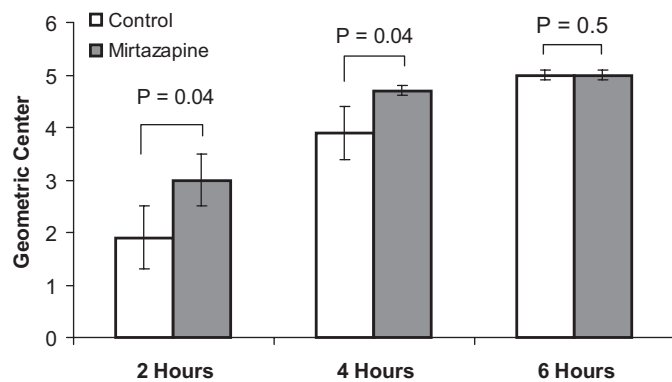


Fig. 5. Effects of mirtazapine on colonic transit. Mirtazapine accelerated colonic transit 2 and 4 h after the insertion of the radiopaque markers ( $P = 0.04$ ).

The effect of mirtazapine on colonic transit had not been studied before. It is known that many IBS patients display visceral hypersensitivity during colorectal distention (26, 30, 33). In an earlier study we reported improvement on visceral hypersensitivity with the administration of mirtazapine in colonic sensitized rats (42); however, its effect on the colonic transit was not investigated. In the present study, we found that mirtazapine accelerated colonic transit in normal dogs. The combined effects of mirtazapine on visceral hypersensitivity and colon transit may play a role in treating symptoms of IBS, especially in constipation-dominant IBS. It has to be mentioned that in the present study acceleration of colonic transit by mirtazapine was observed in normal dogs rather than a canine model of constipation.

Mirtazapine is an adrenoceptor antagonist with preferential affinity for presynaptic  $\alpha_2$  adrenoceptors and low affinity for  $\alpha_1$  adrenoceptors (10). Blockade of  $\alpha_2$  receptors by mirtazapine enhances both noradrenergic and serotonergic transmission (11). Although the increase in NE potentially inhibits GI motility, mirtazapine may enhance GI motility for the following reasons: 1) Blockade of  $\alpha_2$  receptors is expected to increase GI motility. In one previous study, it was shown that pretreatment of mirtazapine antagonized the effect of clonidine (21), whereas clonidine is known to delay gastric emptying and induce constipation. 2) Enhancement of serotonin transmission due to blockade of  $\alpha_2$  receptors by mirtazapine increases 5-HT release. Mirtazapine has a high affinity for serotonergic 5-HT<sub>2</sub> receptor subtypes, especially 5-HT<sub>2A</sub> and 5-HT<sub>2C</sub> (9). 5-HT<sub>2C</sub> was known to regulate GI motor activity and it was reported to stimulate phasic contractions and phase III activity in canine jejunum (19, 22). Antidepressants with a strong affinity for 5-HT<sub>2C</sub> receptor are reported to be associated with weight gain (13). Studies have shown that more than 10% of patients experience substantial weight gain during mirtazapine treatment and more than 10% patients have been noticed to have an increased of appetite (1). 3) Facilitation of NE transmission due to blockade of  $\alpha_2$  receptors by mirtazapine may further enhance serotonin transmission due to enhancement of 5-HT<sub>1A</sub> function (3, 32) mediated via  $\alpha_2$  heteroreceptors (12); blockade of  $\alpha_2$ -adrenergic heteroreceptors located on the 5-HT terminals removes the tonic inhibition caused by endogenous NE. Furthermore, mirtazapine has been reported to block 5-HT<sub>3</sub> receptors with a potency similar to its effects on  $\alpha_2$  receptors (8, 18).

Recently, a 5-HT<sub>1A</sub> receptor agonist has been shown to increase esophageal motility and colonic migrating motor complexes (14, 15). Accordingly, we speculate that the prokinetic effects of mirtazapine observed in this study are attributed to increased release of 5-HT (mainly via the actions of 5-HT<sub>2C</sub> and 5-HT<sub>1A</sub>) and the blockage of  $\alpha_2$  adrenergic receptors.

The ameliorating effects of mirtazapine on rectal distention-induced impairment in gastric motility (tone, accommodation, contractions, and emptying) are believed to be attributed to both its prokinetic effects and its inhibitory effects on rectal distention-induced hypersensitivity. In the present study, mirtazapine blocked the rectal distention-induced inhibitory effects on gastric motility. In a previous study, mirtazapine was found to reduce rectal distention-induced gastric hypersensitivity (42).

Interestingly, although mirtazapine was found to have the prokinetic effect on both gastric emptying and colonic transit, it showed no effects on small intestinal contractions or transit in the normal dogs. In this study, intestinal transit was performed simultaneously with gastric emptying, and gastric chyme emptied from the stomach was diverted out through the duodenal cannula. One might argue that this was not physiological because the intestine was not exposed to nutrients. Our rationale for such a special design was based on following considerations. Under normal physiological condition, intestinal transit is influenced by gastric emptying, i.e., how fast nutrients are delivered from the stomach to the small intestine. While designing the study, we anticipated that mirtazapine would alter gastric emptying and, therefore, the effect of mirtazapine on gastric emptying would be a confounding factor in studying the effect of mirtazapine on intestinal transit. To eliminate this confounding factor, we decided to divert all gastric chyme and perform the test simultaneously with gastric emptying by ingesting saline mixed with phenol red to the small intestine via the duodenal cannula. Although gastric chyme was diverted, the small intestinal motility pattern observed during the test was similar to the postprandial pattern. The mechanisms underlying why mirtazapine had no effect on small bowel transit or contractions was not clear. It could be due to the differences in the coupling of  $\alpha_2$  receptors to adrenergic and serotonergic neurons in the small bowel. Further mechanistic studies are needed to investigate why there were differences in the effects of mirtazapine among different organs of the gut.

In conclusion, mirtazapine improves gastric emptying in healthy dogs, normalizes rectal distention-induced delay in gastric emptying and accelerates colon transit in healthy dogs. Clinical studies are warranted to assess the effects of mirtazapine on GI motility and sensory functions in patients with functional GI diseases.

#### DISCLOSURES

No conflicts of interest, financial or otherwise, are declared by the author(s).

#### AUTHOR CONTRIBUTIONS

J.Y. and J.D.C. conception and design of research; J.Y., J.S., Y.L., and X.X. performed experiments; J.Y., J.S., Y.L., and X.X. analyzed data; J.Y. and J.D.C. interpreted results of experiments; J.Y. prepared figures; J.Y. drafted manuscript; J.Y. and J.D.C. edited and revised manuscript; J.Y. and J.D.C. approved final version of manuscript.

## REFERENCES

1. Anttila SA, Leinonen EV. A review of the pharmacological and clinical profile of mirtazapine. *CNS Drug Rev* 7: 249–264, 2001.
2. Azpiroz F, Malagelada JR. Perception and reflex relaxation of the stomach in response to gut distention. *Gastroenterology* 98: 1193–1198, 1990.
3. Berendsen HH, Broekkamp CL, Van Delft AML. Downregulation of 5-HT<sub>1A</sub> receptors after chronic treatment with Remeron [letter]. *Eur Neuropsychopharmacol* 5: 306, 1995.
4. Bouin M, Lupien F, Riberdy M, Boivin M, Plourde V, Poitras P. Intolerance to visceral distension in functional dyspepsia or irritable bowel syndrome: an organ specific defect or a pan intestinal dysregulation? *Neurogastroenterol Motil* 16: 311–314, 2004.
5. Camilleri M, Chang L. Challenges to the therapeutic pipeline for irritable bowel syndrome: end points and regulatory hurdles. *Gastroenterology* 135: 1877–1891, 2008.
6. Chen J, Song GQ, Yin J, Koothan T, Chen JD. Electroacupuncture improves impaired gastric motility and slow waves induced by rectal distension in dogs. *Am J Physiol Gastrointest Liver Physiol* 295: G614–G620, 2008.
7. Choung RS, Cremonini F, Thapa P, Zinsmeister AR, Talley NJ. The effect of short-term, low-dose tricyclic and tetracyclic antidepressant treatment on satiation, postnutrient load gastrointestinal symptoms and gastric emptying: a double-blind, randomized, placebo-controlled trial. *Neurogastroenterol Motil* 20: 220–227, 2008.
8. Costall B. The breadth of action of the 5-HT<sub>3</sub> receptor antagonists. *Int Clin Psychopharmacol* 8, Suppl 2: 3–9, 1993.
9. de Boer T. The pharmacologic profile of mirtazapine. *J Clin Psychiatry* 57, Suppl 4: 19–25, 1996.
10. de Boer TH, Maura G, Raiteri M, de Vos CJ, Wieringa J, Pinder RM. Neurochemical and autonomic pharmacological profiles of the 6-aza-analogue of mianserin, Org 3770 and its enantiomers. *Neuropharmacology* 27: 399–408, 1988.
11. de Boer TH, Nefkens F, van Helvoirt A, van Delft AM. Differences in modulation of noradrenergic and serotonergic transmission by the alpha-2 adrenoceptor antagonists, mirtazapine, mianserin and idazoxan. *J Pharmacol Exp Ther* 277: 852–860, 1996.
12. De Boer TH, Nefkens F, Van Helvoirt A. The  $\alpha_2$ -adrenoceptor antagonist Org 3770 enhances serotonin transmission in vivo. *Eur J Pharmacol* 253: R5–R6, 1994.
13. De Luca V, Mueller DJ, de Bartolomeis A, Kennedy JL. Association of the HTR2C gene and antipsychotic induced weight gain: a meta-analysis. *Int J Neuropsychopharmacol* 10: 697–704, 2007.
14. Di Stefano M, Papanthanasopoulos A, Blondeau K, Vos R, Boeckstaens V, Farre R, Rommel N, Tack J. Effect of buspirone, a 5-HT<sub>1A</sub> receptor agonist, on esophageal motility in healthy volunteers. *Dis Esophagus* 25: 470–476.
15. Dickson EJ, Heredia DJ, Smith TK. Critical role of 5-HT<sub>1A</sub>, 5-HT<sub>3</sub>, and 5-HT<sub>7</sub> receptor subtypes in the initiation, generation, and propagation of the murine colonic migrating motor complex. *Am J Physiol Gastrointest Liver Physiol* 299: G144–G157, 2010.
16. Fawcett J, Barkin RL. Review of the results from clinical studies on the efficacy, safety and tolerability of mirtazapine for the treatment of patients with major depression. *J Affect Disord* 51: 267–285, 1998.
17. Ford AC, Talley NJ, Schoenfeld PS, Quigley EM, Moayyedi P. Efficacy of antidepressants and psychological therapies in irritable bowel syndrome: systematic review and meta-analysis. *Gut* 58: 367–378, 2009.
18. Frazer A. Antidepressant drugs. *Depression* 2: 1–19, 1994.
19. Fujitsuka N, Asakawa A, Hayashi M, Sameshima M, Amitani H, Kojima S, Fujimiya M, Inui A. Selective serotonin reuptake inhibitors modify physiological gastrointestinal motor activities via 5-HT<sub>2c</sub> receptor and acyl ghrelin. *Biol Psychiatry* 65: 748–759, 2009.
20. Gooden JY, Takahashi PY. Mirtazapine treatment of diabetic gastroparesis as a novel method to reduce tube-feed residual: a case report. *J Med Case Rep* 7: 38, 2013.
21. Gower AJ, Broekkamp CL, Rijk HW, Van Delft AM. Pharmacological evaluation of in vivo tests for alpha 2-adrenoceptor blockade in the central nervous system and the effects of the enantiomers of mianserin and its aza-analog ORG 3770. *Arch Int Pharmacodyn Ther* 291: 185–201, 1988.
22. Graf S, Sarna SK. 5-HT-induced jejunal motor activity: enteric locus of action and receptor subtypes. *Am J Physiol Gastrointest Liver Physiol* 270: G992–G1000, 1996.
23. Halder SL, Locke GR 3rd, Talley NJ, Fett SL, Zinsmeister AR, Melton LJ 3rd. Impact of functional gastrointestinal disorders on health-related quality of life: a population-based case-control study. *Aliment Pharmacol Ther* 19: 233–242, 2004.
24. Halpert A, Dalton CB, Diamant NE, Toner BB, Hu Y, Morris CB, Bangdiwala SI, Whitehead WE, Drossman DA. Clinical response to tricyclic antidepressants in functional bowel disorders is not related to dosage. *Am J Gastroenterol* 100: 664–671, 2005.
25. Hasler WL. Gastroparesis: symptoms, evaluation, and treatment. *Gastroenterol Clin North Am* 36: 619–647, ix, 2007.
26. Kanazawa M, Hongo M, Fukudo S. Visceral hypersensitivity in irritable bowel syndrome. *J Gastroenterol Hepatol* 26, Suppl 3: 119–121, 2011.
27. Karamanolis G, Caenepeel P, Arts J, Tack J. Determinants of symptom pattern in idiopathic severely delayed gastric emptying: gastric emptying rate or proximal stomach dysfunction? *Gut* 56: 29–36, 2007.
28. Keshavarzian A, Bushnell DL, Sontag S, Yegelow EJ, Smid K. Gastric emptying in patients with severe reflux esophagitis. *Am J Gastroenterol* 86: 738–742, 1991.
29. Kim SW, Shin IS, Kim JM, Kang HC, Mun JU, Yang SJ, Yoon JS. Mirtazapine for severe gastroparesis unresponsive to conventional prokinetic treatment. *Psychosomatics* 47: 440–442, 2006.
30. Klooker TK, Liefeld KE, Van Den Wijngaard RM, Boeckstaens GE. The cannabinoid receptor agonist delta-9-tetrahydrocannabinol does not affect visceral sensitivity to rectal distension in healthy volunteers and IBS patients. *Neurogastroenterol Motil* 23: 30–35.e2
31. Lei Y, Xing J, Chen JD. Effects and mechanisms of implantable gastric stimulation on gastric distention in conscious dogs. *Obes Surg* 15: 528–533, 2005.
32. Norman TR, McGrath CJ, Burrows GD. The neurochemical and behavioural effects of the isomers of mirtazapine in normal rats [letter]. *Eur Neuropsychopharmacol* 5: 316, 1995.
33. Nozu T, Okumura T. Visceral sensation and irritable bowel syndrome: with special reference to comparison with functional abdominal pain syndrome. *J Gastroenterol Hepatol* 26, Suppl 3: 122–127, 2011.
34. Patrick A, Epstein O. Review article: gastroparesis. *Aliment Pharmacol Ther* 27: 724–740, 2008.
35. Shay SS, Egli D, McDonald C, Johnson LF. Gastric emptying of solid food in patients with gastroesophageal reflux. *Gastroenterology* 92: 459–465, 1987.
36. Tack J, Piessevaux H, Coulie B, Caenepeel P, Janssens J. Role of impaired gastric accommodation to a meal in functional dyspepsia. *Gastroenterology* 115: 1346–1352, 1998.
37. Talley NJ, Dennis EH, Schettler-Duncan VA, Lacy BE, Olden KW, Crowell MD. Overlapping upper and lower gastrointestinal symptoms in irritable bowel syndrome patients with constipation or diarrhea. *Am J Gastroenterol* 98: 2454–2459, 2003.
38. Talley NJ, Herrick L, Locke GR. Antidepressants in functional dyspepsia. *Expert Rev Gastroenterol Hepatol* 4: 5–8, 2010.
39. Thomas SG. Irritable bowel syndrome and mirtazapine. *Am J Psychiatry* 157: 1341–1342, 2000.
40. Yin J, Chen JD. Electroacupuncture improves rectal distension-induced delay in solid gastric emptying in dogs. *Am J Physiol Regul Integr Comp Physiol* 301: R465–R472, 2011.
41. Yin J, Ouyang H, Chen JD. Potential of intestinal electrical stimulation for obesity: a preliminary canine study. *Obesity (Silver Spring)* 15: 1133–1138, 2007.
42. Yin J, Wang W, Winston JH, Zhang R, Chen JD. Ameliorating effects of mirtazapine on visceral hypersensitivity in rats with neonatal colon sensitivity. *Neurogastroenterol Motil* 22: 1022–1028.e267, 2010.
43. Yin J, Zhang J, Chen JD. Inhibitory effects of intestinal electrical stimulation on food intake, weight loss and gastric emptying in rats. *Am J Physiol Regul Integr Comp Physiol* 293: R78–R82, 2007.
44. Youle MS, Read NW. Effect of painless rectal distension on gastrointestinal transit of solid meal. *Dig Dis Sci* 29: 902–906, 1984.
45. Zhao X, Yin J, Chen J, Song G, Wang L, Zhu H, Brining D, Chen JD. Inhibitory effects and mechanisms of intestinal electrical stimulation on gastric tone, antral contractions, pyloric tone, and gastric emptying in dogs. *Am J Physiol Regul Integr Comp Physiol* 296: R36–R42, 2009.