Ann Vasc Dis Vol. 8, No. 3; 2015; pp 246–248
Online June 17, 2015
doi:10.3400/avd.cr.15-00009


*Case Report*

# Extra-Anatomic Bypass Operation for an Infected Aortic Arch Aneurysm with Broad Mediastinal Abscess: A Case Report

**Hironori Inoue, MD,[1] Yoshifumi Iguro, MD,[2] Masahiro Ueno, MD,[1] and Keisuke Yamamoto, MD[1]**

We encountered an informative case of infected aortic arch aneurysm. The proximal descending aorta, left common carotid artery, and left subclavian artery were severely involved in an abscess; thus, typical in situ reconstruction of the arch was considered impossible. Therefore, to secure more distal branches appropriate for anastomosis, a modified extra-anatomic arch repair was performed through additional incisions. The patient developed renal and respiratory failure and died of septicemia five and a half months after the operation. However, postoperative computed tomograms demonstrated that the abscess had disappeared.

***Keywords:*** extra-anatomic bypass, infected aortic arch aneurysm

## Introduction

The management of infected aortic arch aneurysms is problematic. In situ reconstruction or hybrid thoracic endovascular aortic repair[1)] is certainly desirable for addressing anatomical issues, but is arguable in terms of the control of infection and active debridement.[2)] Here, we report a surgical case of an infected aortic arch aneurysm. Excessive invasion is a serious problem; however, we applied a modified extra-anatomic bypass, which enabled us to secure intact branches for anastomosis and to perform active debridement.

[1]*Department of Cardiovascular Surgery, Tenyoukai Central Hospital, Kagoshima, Kagoshima, Japan*
[2]*Kimotsuki Town's Hospital, Kimotsuki-gun, Kagoshima, Japan*

Received: January 26, 2015; Accepted: May 2, 2015
Corresponding author: Hironori Inoue, MD. Department of Cardiovascular Surgery, Tenyoukai Central Hospital, 6-7 Izumicho, Kagoshima, Kagoshima 892-0822, Japan
Tel: +81 99 226 8181, Fax: +81 99 224 2752
E-mail: h.inoue@tenyoukai.org

## Case Report

A 77-year-old man was referred to Kagoshima University hospital with the diagnosis of impending rupture of aortic arch aneurysm. He had fever of 38°C, high white blood cell (WBC) count (12000/ul) and an elevated serum level of C-reactive protein (20 mg/dl). Blood culture studies were positive for methicillin-sensitive *Staphylococcus aureus*. Computed tomography (CT) showed a mushroom-shaped arch aneurysm, indicating infection (**Fig. 1A**). In addition, a broad abscess containing small bubbles was identified in the mediastinum (**Fig. 1B**, arrows), and a compressed proximal left common carotid artery (CCA) and left subclavian artery (SCA) were observed (**Fig. 1C**). Therefore, we were concerned about in situ reconstruction of the arch not being accomplished because of tight adhesion and fragile vessels. Therefore, we preoperatively considered the possibility of an extra-anatomic bypass.

The aneurysm strongly convoluted mediastinal circumferential tissue containing the innominate vein, proximal left CCA and left SCA (**Fig. 2A**). The innominate vein was injured during the initial adhesiotomy; therefore, in situ reconstruction was abandoned at that time. Instead we decided to conduct an extra-anatomic bypass, as described below, to search for intact branches.

In addition to a median sternotomy, we made a left oblique cervical incision, 5th left anterior thoracotomy and bilateral subclavian incision. The left second rib was separated from the sternum and that was transected at a level, which facilitated the superolateral traction of the left clavicle (**Fig. 2B**). All grafts were soaked for 10 min in vancomycin (5 mg/1 ml saline). First, two 10-mm Dacron grafts (HEMASHIELD PLATINUM, MAQUET GmbH & Co. KG, Rastatt, Germany) were anastomosed to bilateral subclavian arteries in end-to-side fashion, and brought to the front through the pleural spaces. Next, the 8-mm graft was anastomosed to the distal side of the cervical left CCA, delivering blood from the 10-mm graft connected to the right SCA, via T-shaped carotid

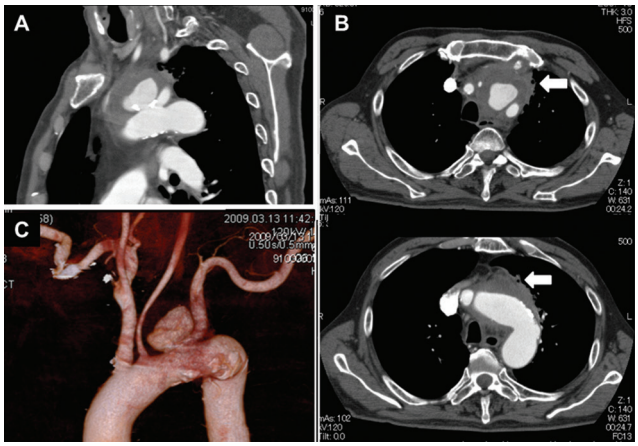


**Fig. 1** Preoperative CT showing the infected aortic arch aneurysm, rising between the compressed left common carotid artery and left subclavian artery (**A** and **C**). The aneurysm is surrounded by a broad, low density area with bubbles (**B**, arrows). CT: computed tomography

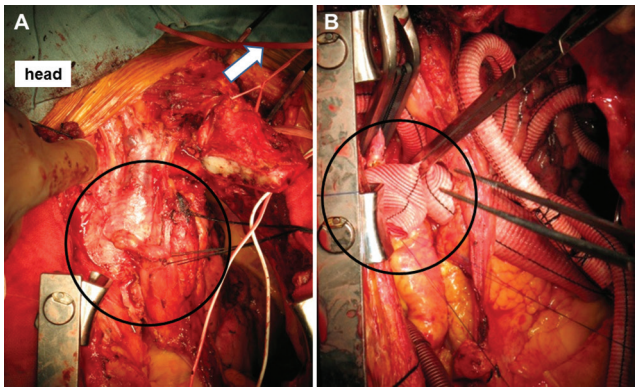


**Fig. 2** (**A**) The intraoperative photograph showing that the innominate vein, left CCA and left SCA are significantly involved in the aneurysm (circle). The left clavicle is pulled upward (arrow). (**B**) The proximal stump of the 4-branched graft is anastomosed to the ascending aorta at right angles (circle). CCA: common carotid artery; SCA: subclavian artery

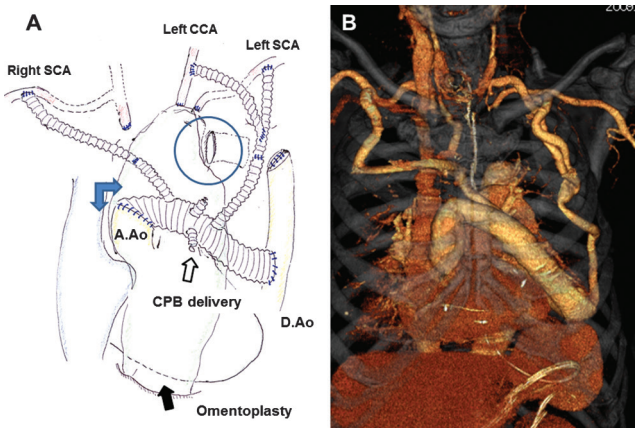


**Fig. 3** (**A**) The schema for our extra-anatomic bypass operation. The distal stump of the aorta just below left SCA (Z3 level [3]) was too fragile to close from the front (circle). (**B**) Postoperative 3-dimensional CT showing all the reconstructed vessels. SCA: subclavian artery; CCA: common carotid artery; A.Ao: ascending aorta; D.Ao: descending aorta; CPB: cardiopulmonary bypass; CT: computed tomography

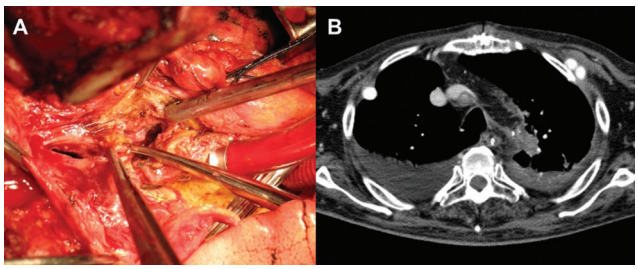


**Fig. 4** (**A**) Intraoperative photograph showing the incised infected aneurysm with debris. (**B**) CT showing that the original aortic arch and the abscess had disappeared. CT: computed tomography

shunt-device (C. R. Bard, USA). We then established the cardiopulmonary bypass (CPB), with delivery through the right femoral artery and drainage from the right atrium. After CPB was established, a 4-branched 24-mm Dacron graft (HEMASHIELD PLATINUM) was anastomosed to the thoracic descending aorta (T-8 level[3]) between cross-clamps in the end-to-side fashion. This graft was introduced to the ascending aorta over the pulmonary trunk, avoiding the abscess as much as possible. Each graft (10 mm and 8 mm) was anastomosed to a branch of the 24-mm graft. The arterial delivery of CPB via a branch of the 24mm-graft was added, and perfusion of the upper body through the 24-mm graft was secured. The ascending aorta was cross-clamped and proximal anastomosis of the aorta was performed at right angles, without hypothermia or circulatory arrest (aortic clamp time, 9 min). The patient was easily weaned from CPB. Then, each fragile proximal stump (brachiocephalic artery, left CCA, left SCA and descending aorta) was trimmed and closed after administration of protamine, without much bleeding (**Fig. 3**). Finally, active debridement was successfully achieved (**Fig. 4A**) and the greater omental flap was brought up to the mediastinum.

Sulbactam/ampicillin, doripenem and gentamicin sulfate were at first administrated intravenously for two weeks. There was no postoperative neurological damage, thromboembolism or sternal infection. Postoperative CT two months after the operation demonstrated that the abscess had disappeared (**Fig. 4B**). The patient was in temporary rest, but renal failure requiring hemodialysis persisted. He then developed MRSA septicemia followed by erythroderma and died five and a half months after operation.

## Discussion

An infected aortic aneurysm remains a devastating disease with serious complications such as sepsis, coagulopathy and rupture. Successful endovascular stent-grafting for infected descending aortic aneurysms has been reported with remarkable results.[3,4] However, infected aortic arch aneurysms demand particularly difficult surgical decisions, because the application of an extra-anatomic bypass or stent-grafting is limited by anatomy. Therefore, out of necessity, in situ prosthetic graft or allograft replacements have been performed for infected aortic arch aneurysms with good results.[4–6] However, as in our case, in situ reconstruction may occasionally be difficult in patients with severely adherent and damaged branches due to infection.

During in situ reconstruction of the arch, difficulties with anastomosis could result in disasters such as fatal cerebral and cardiac ischemia. Thus, to expose more distal branches appropriate for reliable anastomosis, additional incisions were made before the initiation of CPB. Our approach, similar to "hybrid" repair,[7] shortened the cardiac ischemic time[8] and avoided deep hypothermia and circulatory arrest. In addition, having a sufficient distance between graft and the abscess facilitated intensive debridement. Accordingly, distinct mediastinal abscess disappeared in our patient. However, our patient ultimately died of septicemia. We should have used grafts bonded with effective antibacterial agents, such as rifampicin;[9] furthermore, this course of action should be given serious consideration in the future.

Given the recent flourishing of less-invasive surgeries, many aspects of our procedures could be improved. During the procedure, we first used right femoral cannulation for CPB. In retrospect, we should have side-clamped the descending aorta and anastomosed the 24-mm graft prior to CPB, to shorten CPB time and preserve antegrade visceral flow, which may have led to renal protection.

It is undeniable that the criteria and timing for determining an extra-anatomic bypass are ambiguous. Our procedures would certainly be considered devious, excessive, and controversial by many cardiovascular surgeons. Nevertheless, we believe that this case demonstrates the potential of sure and steady extra-anatomic bypass for infected aortic arch aneurysms with severely adherent and damaged branches.

## Conclusion

We reported a case of extra-anatomic bypass for infected arch aneurysm, to secure intact branches for anastomosis and to perform active debridement.

## Acknowledgement

We thank Yasuo Morishita, MD for his educational advices.

## Disclosure Statement

The authors have no conflicts of interest to declare.

## References

1. Kamohara K, Tanaka A, Itoh M, et al. Hybrid one-stage repair using a sutureless telescoped stent graft fixation for ruptured multiple thoracic aortic aneurysms. Ann Thorac Cardiovasc Surg. 2014; **20**: 918-21.
2) Sekar N. Primary aortic infections and infected aneurysms. Ann Vasc Dis 2010; **3**: 24-7.
3. Mitchell RS, Ishimaru S, Ehrlich MP, et al. First International Summit on Thoracic Aortic Endografting: roundtable on thoracic aortic dissection as an indication for endografting. J Endovasc Ther 2002; **9** Suppl 2: II98-105. Review.
4) Chan FY, Crawford ES, Coselli JS, et al. In situ prosthetic graft replacement for mycotic aneurysm of the aorta. Ann Thorac Surg 1989; **47**: 193-203.
5) Sörelius K, Mani K, Björck M, et al. Endovascular repair of mycotic aortic aneurysms. J Vasc Surg 2009; **50**: 269-74.
6) Patel HJ, Williams DM, Upchurch GR, et al. Late outcomes of endovascular aortic repair for the infected thoracic aorta. Ann Thorac Surg 2009; **87**: 1366-71; discussion 1371-2.
7) Hsu RB, Lin FY. Surgery for infected aneurysm of the aortic arch. J Thorac Cardiovasc Surg 2007; **134**: 1157-62.
8) Xydas S, Wei B, Takayama H, et al. Use of carotid-subclavian arterial bypass and thoracic endovascular aortic repair to minimize cerebral ischemia in total aortic arch reconstruction. J Thorac Cardiovasc Surg 2010; **139**: 717-22; discussion 722.
9) Iida Y, Ito T, Kitahara H, et al. A case of in-situ reconstruction with a rifampicin-bonded gelatin-sealed woven dacron graft for prosthetic graft infection with pseudoaneurysms after ascending aortic replacement for type a dissection. Ann Vasc Dis 2014; **7**: 68-71.