

Chronic Exertional Compartment Syndrome

Diagnosis and Management

Matthew R. Bong, M.D., Daniel B. Polatsch, M.D., Laith M. Jazrawi, M.D., and Andrew S. Rokito, M.D.

Abstract

During exercise, muscular expansion and swelling occur. Chronic exertional compartment syndrome represents abnormally increased compartment pressures and pain in the involved extremity secondary to a noncompliant musculo-fascial compartment. Most commonly, it occurs in the lower leg, but has been reported in the thigh, foot, upper extremity, and erector spinae musculature. The diagnosis is obtained through a careful history and physical exam, reproduction of symptoms with exertion, and pre- and post-exercise muscle tissue compartment pressure recordings. It has been postulated that increased compartment pressures lead to transient ischemia and pain in the involved extremity. However, this is not universally accepted. Other than complete cessation of causative activities, nonoperative management of CECS is usually unsuccessful. Surgical release of the involved compartments is recommended for patients who wish to continue to exercise.

The first published report of chronic exertional compartment syndrome (CECS) was by Mavor in 1956.¹ He reported bilateral anterior leg pain in a professional soccer player during exercise, which was successfully treated with surgery. It is thought that an even earlier account came from Dr. Edward Wilson's description of his

own symptoms in 1912.² Since Mavor's description, there have been numerous studies in the literature comparing diagnostic modalities and treatment outcomes.

Chronic exertional compartment syndrome most commonly occurs in the lower leg, but has been reported in the thigh, erector spinae musculature, hand, and forearm.³⁻⁵ The incidence of CECS in the general population is unclear, however, in one study of patients with undiagnosed lower leg pain, the incidence was 14%.⁶ In a study of patients with chronic exercise-induced anterior lower leg pain the incidence was 27%.⁷ Although early studies reported a large male predominance, this was most likely a result of patient selection and a reflection of the overall demographics of athletic participants and military recruits at that time. As more women have become involved in competitive athletics, it appears that the incidence of CECS in men and women is similar.^{6,8-10}

Anatomy

Traditionally the lower leg has been divided into four distinct myofascial compartments: anterior, lateral, superficial posterior, and deep posterior (Fig. 1). Additionally, it has been shown that the tibialis posterior muscle is contained within its own fascial compartment and may be considered the "fifth" compartment of the lower leg.¹¹ The anterior compartment contains the tibialis anterior, extensor hallucis longus, extensor digitorum longus, and peroneus tertius. The neurovascular structures course anterior to the interosseous membrane and include the anterior tibial artery and vein and the deep branch of the common peroneal nerve. The lateral compartment contains the peroneus longus and peroneus brevis muscles and the superficial branch of the common peroneal nerve.

The superficial posterior compartment contains the soleus, plantaris, and gastrocnemius muscles and the sural nerve. In the deep posterior compartment lie the flexor

Matthew R. Bong, M.D., and Daniel B. Polatsch, M.D., are Residents in the NYU-Hospital for Joint Diseases Department of Orthopaedic Surgery, New York, New York. Laith M. Jazrawi, M.D., is an Assistant Professor in the NYU-Hospital for Joint Diseases Department of Orthopaedic Surgery, New York, New York. Andrew S. Rokito, M.D., is the Associate Director of the Sports Medicine Service in the NYU-Hospital for Joint Diseases Department of Orthopaedic Surgery, New York, New York.

Correspondence: Laith M. Jazrawi, M.D., NYU-Hospital for Joint Diseases Department of Orthopaedic Surgery, 301 East 17th Street, New York, New York 10003.

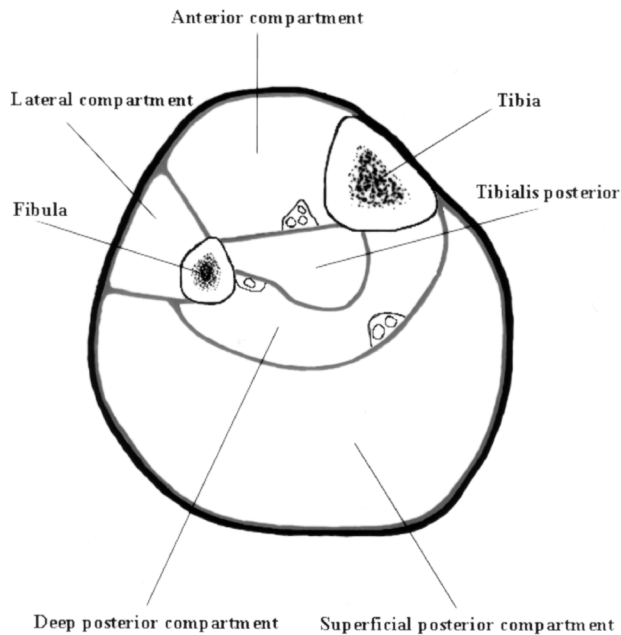


Figure 1 Cross-section of the lower leg showing the four main compartments and the separate tibialis posterior compartment.

digitorum longus, flexor hallucis longus, and proximally, the popliteus. The neurovascular structures include the posterior tibial artery and vein and the tibial nerve. There are no neurovascular structures within the compartment of the tibialis posterior.

Pathophysiology

Much of the early research into the pathophysiology of CECS was based on the knowledge of acute compartment syndromes. In acute compartment syndromes, tissue pressures within fascial compartments rise to extreme levels leading to ischemic necrosis of tissues and neural changes. Acute exertional compartment syndrome presents like other acute compartment syndromes that occur after trauma, arterial injury, drug overdose, or burns. In CECS, tissue pressures are elevated, but not to the same degree as in acute compartment syndrome and do not lead to irreversible ischemic changes. While it is clear that elevated tissue pressures are responsible for the symptoms of CECS, the ultimate cause of pain has recently been questioned.

During strenuous exercise, there can be up to a 20% increase in muscle volume and weight due to increased blood flow and edema. In addition, the normal muscular hypertrophy that occurs over time with chronic exercise reduces the reserve volume available within the fascial compartment. Chronic fascial thickening may also contribute to compartment noncompliance.¹⁰ A normal fascial compartment can accommodate increased muscular volume during strenuous exercise, however, in CECS, a relatively noncompliant compartment leads to abnormally elevated tissue pressures.

Research on CECS has shown that elevated tissue

pressures lead to relative ischemia within the fascial compartment.^{6,12} It is postulated that increased compartment pressure obstructs venous outflow and leads to a reduced arteriovenous gradient and a decrease in local blood flow. This results in ischemia of both muscle tissues and nerves leading to pain and paresthesias.

While there is evidence that tissue ischemia is the ultimate cause of pain symptoms in CECS, this is not universally accepted. Amendola and colleagues¹³ could not demonstrate consistent ischemic changes with nuclear medicine blood flow studies in patients with CECS. Likewise, Balduini and associates,¹⁴ using ³¹P-NMR Spectroscopy, found that ischemia only occurred when tissue pressure were exceptionally high (≥ 160 mmHg). They postulated that stimulation of fascia or periosteal sensory nerves, through increased compartment pressures, was the cause of pain in CECS. The local release of kinins that can occur during contraction of muscles with minimally reduced blood flow may be another alternate etiology of pain.¹⁴ Most recently, Trease and coworkers¹⁵ found no compartment perfusion deficit using thallium-201 single-photon emission tomography in patients with raised intracompartmental pressures associated with CECS.

Differential Diagnosis

For patients with exercise-induced lower leg pain, the differential diagnosis includes: CECS, medial tibial stress syndrome (MTSS), fibular and tibial stress fractures, fascial defects, nerve entrapment syndromes, vascular claudication, and lumbar disc herniation (Table 1). In a study of 150 patients with exercise induced lower leg pain, 33% were diagnosed with CECS, 25% with stress fractures, 14% with muscle strains, 13% with MTSS, and 10% with neuropathies.¹⁶ When isolated anterior exercised induced lower leg pain was studied in 98 patients, 42% were diagnosed with periostitis, 27% with CECS, 13% with superficial peroneal nerve compression, 5% with fascial defects without CECS, and 13% with miscellaneous conditions.

Evaluation

Evaluation of the athlete with chronic exercised-induced lower leg pain begins with a thorough history and physical examination. Patients with CECS will often complain of pain that starts as a dull ache, usually within the first 30 minutes after the initiation of exercise. Burning, cramping, or aching pain and tightness develop as exercise is continued. Most patients are runners or are involved in sports that require a great deal of running such as basketball, soccer, and football. Almost all patients complain that the pain adversely affects their athletic performance. The pain is usually located over the involved compartments and may radiate to the ankle or foot. Usually, the pain ceases when the provocative activity is stopped. Anterior and lateral compartment pain is located over the anterolateral aspect of the lower leg and may radiate to the dorsum of the foot. Deep posterior and tibialis

Table 1 Differential Diagnosis for Patients with Chronic Exertional Compartment Syndrome

Diagnosis	Symptoms	Physical Examination	Diagnostic Studies
Chronic Exertional Compartment Syndrome	Pain starts within first 30 minutes of exercise and can radiate to ankle/foot. Pain ceases when activity is stopped. Bilateral in 80%-95%. Daily activities usually not provocative.	Typically benign. Fascial herniations in 40-60%. Reproduction of symptoms with exercise.	Elevated intracompartment tissue pressures. MRI may show increase T2-weighted signal intensity.
Medial Tibial Stress Syndrome	Pain along posteromedial aspect of mid and distal tibia. Usually exacerbated by activity and only partially relieved by rest. Daily activities may exacerbate pain.	Point tenderness at rest over posteromedial tibial periosteum and soleus fascia.	Bone scintigraphy may reveal linear uptake along posteromedial tibia. Compartment pressures to rule out deep posterior compartment syndrome.
Stress Fracture	Localized area of pain over tibia or fibula initially relieved by rest. Usually occurs after change in training routine. Daily activities may exacerbate pain.	Point tenderness over tibia or fibula. Often exacerbated with percussion.	Plain films usually negative initially. "Dreaded black line," cortical thickening or callous can be seen after 2-4 weeks. Bone scintigraphy can show localized uptake within one week. MRI may aid in diagnosis.
Fascial Defects	Often asymptomatic. Can be painful if associated with superficial peroneal nerve compression or muscle ischemia at defect. Often associated with CECS.	Defect can be visible in thin patients. Herniated muscle belly may be tender to palpation.	Intracompartmental tissue pressures should be tested if associated with symptoms of CECS. MRI may be helpful to rule out other potential etiologies.
Nerve Entrapment Syndromes	Paresthesias and burning pain along involved nerve distribution. Can be associated with weakness.	Weakness and atrophy of muscles innervated by involved nerve. Positive Tinel's sign at sight of entrapment.	EMG and nerve conduction studies can localize area of entrapment.
Radiculopathy	Radiating pain at rest that follows a specific dermatome. Can be associated with weakness, paresthesias.	Localized weakness and diminished reflexes in musculature innervated by involved root. Decreased sensation. Positive long tract signs.	MRI of lumbar spine.
Vascular Claudication	Rare cause of leg pain in healthy adults. Pain with activities and leg elevation. Pain relieved with leg in dependent position.	Diminished pulses and capillary refill. Loss of hair and pallor in advanced changes.	Ankle/brachial index. Arterial Doppler studies. Angiogram is the gold standard.

posterior pain is typically located along the posteromedial border of the tibia and may radiate to the medial aspect of the foot. Superficial posterior compartment pain may be vague and poorly localized. A minority of patients will complain of numbness or weakness in the leg or foot. Symptoms occur bilaterally in up to 80% to 95% of patients.^{10,17} The anterior compartment is involved in 40% to 60% of patients, the deep posterior compartment in 32% to 60%, the lateral

compartment in 12% to 35%, and the superficial posterior compartment in 2% to 20%.^{8,10,18}

Physical examination of the resting asymptomatic patient is typically benign and may only be helpful to rule out other etiologies. Fascial herniations may be evident in up to 40% to 60% of patients, however, they can occur in the absence of CECS.^{6,17} If the patient is allowed to exercise prior to the physical exam, involved compartments may ap-

pear tense and deep palpation and passive stretch of involved musculature may elicit pain. After exercise, neurological examination may reveal weakness and paresthesias corresponding to the distal innervations of the deep and superficial peroneal nerves.

Patients with MTSS can present with posteromedial lower leg tenderness at rest along the tibia or fascial origin of the soleus. Stress fractures usually present with more discrete bony tenderness over the involved fibula or tibia. Fascial defects most commonly occur over the anterolateral aspect of the lower leg. These defects are often located in the distal third of the leg where the superficial peroneal nerve exits the lateral compartment. Muscle herniation through this fascial defect can compress the nerve leading to radiating pain over the dorsum of the foot. Local tenderness of fascial defects may be a sign of ischemia of herniated muscle tissue. A thorough vascular and neurological examination can help to exclude radiculopathies and arterial disease from the diagnosis.

Diagnostic Studies

Plain radiographs are negative in CECS and are usually sufficient to rule out a diagnosis of stress fracture in patients with chronic symptoms. Mild posteromedial cortical thickening may be seen in patients with MTSS. Patients with symptoms of less than a month, or a suspected diagnosis of MTSS, may benefit from a technetium pyrophosphate bone scan. While results should be negative in patients with CECS, linear uptake along the posteromedial aspect of the tibia can be consistent with MTSS.¹⁹ More focal uptake in the tibia or fibula is associated with a stress fracture. Magnetic resonance imaging (MRI) of the lumbar spine is warranted if a lumbar disc herniation is suspected. Vascular abnormalities can be detected with Doppler ultrasound and ankle blood pressure measurements. While nerve conduction studies are not necessary to diagnose CECS, they may be helpful to localize pathology in nerve entrapment syndromes.

The most valuable study used to diagnose CECS is the recording of intracompartmental tissue pressures. A variety of techniques have been described including using a needle and manometer, wick catheter, slit catheter, and constant infusion catheter.²⁰⁻²³ There is no universal agreement as to the best technique; nor is there consensus as to what pressure levels are required for a diagnosis of CECS. What is clear is that pressure measurements should be made before and after exercise, and the stress exercise should closely approximate the physical activity that normally creates symptoms in the patient.

Pedowitz and colleagues⁸ have laid out tissue pressure criteria for the diagnosis of CECS that is convenient and easy to conduct in the outpatient office setting. A diagnosis of CECS is based on fulfillment of at least one of the three following criteria:

1. A pre-exercise pressure of ≥ 15 mmHg,

2. A 1 minute post-exercise pressure of ≥ 30 mmHg, or
3. A 5 minute post-exercise pressure of ≥ 20 mmHg.

In their study, they used a slit catheter for pressure recording. However, since the recording of pressure measurements is not required during active exercise, one of the commercially available hand-held fluid pressure monitors can be used. It is important to note that compartment pressures vary with ankle and knee position²⁴ and should be conducted with the foot in 20° plantar flexion and the knee in 10° to 30° of flexion. The measurement of tissue pressures in the anterior, lateral, and superficial posterior compartments are relatively straightforward. The anterior compartment can be tested by placing the needle midway between the anterior tibial crest and the anterior intermuscular septum. If the septum cannot be palpated, a point 2 cm lateral to the anterior tibial crest can be used. The lateral compartment can be tested midway between the anterior and posterior intermuscular septums, directly over the fibula. The superficial posterior compartment can be tested at the posteromedial or posterolateral aspect of the leg. Both heads of the gastrocnemius can be tested independently. The deep posterior compartment can be tested through a medial approach by placing the needle directly posterior to the tibia. Placement of the needle directly posterior to the tibial cortex will help to avoid the posterior tibial artery and tibial nerve located in the most posterior region of the deep compartment. Davey and colleagues¹¹ and Rorabeck²⁵ describe testing of the tibialis posterior compartment by inserting the needle through the anterior compartment directly lateral to the tibial cortex. A palpable “pop” is felt upon entering the tibialis posterior compartment through the interosseous membrane.

Two recent MRI studies have shown a statistically significant increase in T2-weighted signal intensity in the anterior compartment of patients with chronic anterior compartment syndrome.^{26,27} This effect was found to disappear after fasciotomy in one of the studies.²⁷ While more studies are needed to define threshold values for the diagnosis of CECS, MRI may emerge as a noninvasive alternative to detecting elevated compartment tissue pressures.

Treatment

The only nonoperative treatment that is certain to alleviate the pain of CECS is the cessation of causative activities. Unfortunately, this is an unappealing option for the competitive and recreational athlete. Cycling may be substituted for running in patients who wish to maintain their cardiorespiratory fitness, as it is associated with a lower risk of compartment pressure elevation.²⁸ Overall, however, nonoperative treatment has been generally unsuccessful.

Massage Therapy

Massage therapy may provide some benefit to patients with mild symptoms or to those who decline surgical interven-

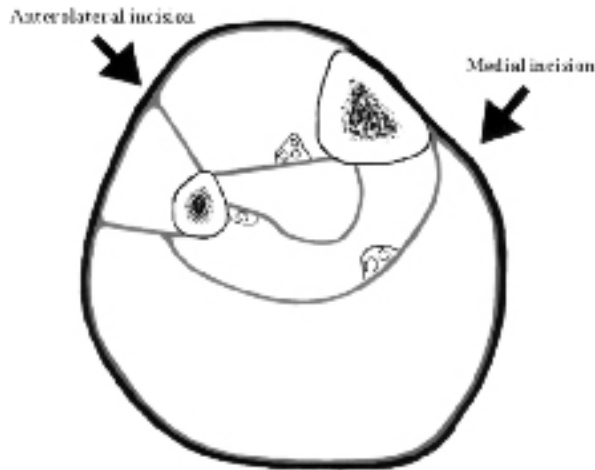


Figure 2 Cross-section of the lower leg. Arrows indicate placement of incisions for compartment release.

tion. Blackman and coworkers²⁹ studied seven patients with CECS who underwent a five-week course of leg massage and stretching exercises. He found that the patients were able to increase the amount of work performed during exercise before pain symptoms developed. However, intracompartmental pressures were not affected and all but one patient continued to experience exercise-induced pain.

Surgical Treatment

For patients who wish to continue their same exercise regimen, fasciotomy of the involved compartments is the treatment of choice, and multiple techniques have been described.^{11,30-32} Mubarak and Owen³¹ described performing fasciotomies for the anterior and lateral compartment through a single anterolateral incision (Fig. 2). A longitudinal 10-centimeter incision is made two centimeters anterior to the fibula halfway down the leg (Fig. 3). After the intermuscular septum is identified, the anterior compartment fascia is incised halfway between the septum

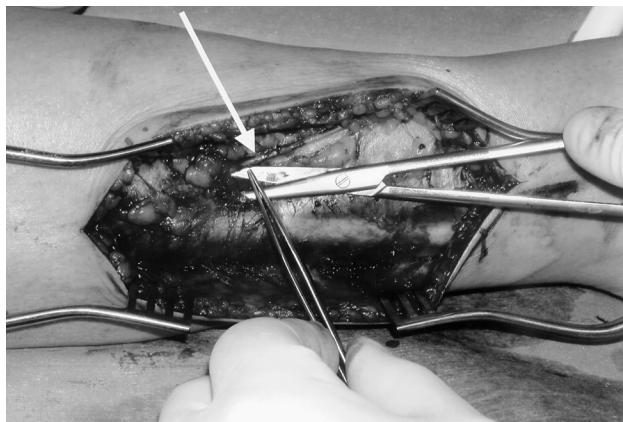


Figure 4 Intraoperative image demonstrating the superficial peroneal nerve (arrow) as it exits the lateral compartment in the distal third of the leg.

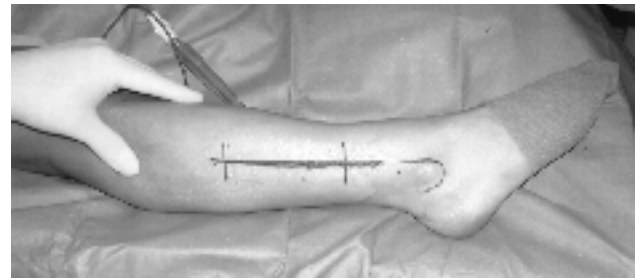


Figure 3 Placement of incisions for release of anterior and lateral compartments.

and the tibial crest. Long blunt scissors are used to extend the fascial opening proximally and distally. A longitudinal incision is then created in the lateral compartment fascia. It is likewise extended proximally and distally. Care must be taken to avoid the superficial peroneal nerve as it exits the lateral compartment at the junction of the distal and middle thirds of the leg (Fig. 4). Rorabeck and associates³⁰ describes performing fasciotomies of the anterior and lateral compartments through a proximal and distal four-centimeter incision over the anterior muscular septum separated by a 15-centimeter skin bridge. The superficial peroneal nerve is identified where it pierces the deep fascia and is protected. Skin incisions can be closed primarily.

Again, release of the posterior compartments can be performed through a single incision according to Mubarak and Owen's³¹ technique or through the double incision technique described by Rorabeck and associates³⁰ (Fig. 5). A single 10-centimeter incision is placed 2 cm posterior to the posteromedial edge of the tibia in the distal part of the leg (Fig 2). The subcutaneous tissue is undermined anteriorly to avoid the saphenous nerve and vein. The fascia over the deep and superficial compartments are incised and extended proximally and medially. If the two-incision technique is used, the incisions should be placed 1 cm posterior to the posteromedial border of the tibia. Care must be taken to avoid the saphenous vein and nerve as it courses across the proximal incision. Care must be taken to identify and release the separate compartment of the tibialis posterior muscle when decompressing the deep posterior compartment.¹¹ In patients with symptoms in the superficial posterior compartment, it may be necessary to release the lateral head of the

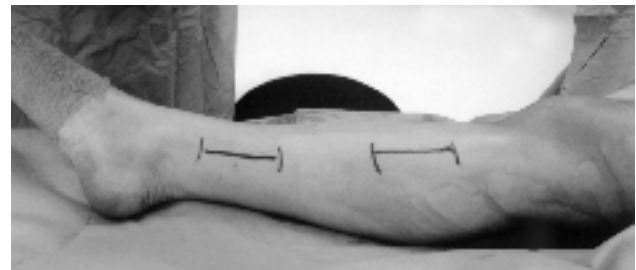

Figure 5 Placement of skin incisions in the two-incision technique for release of the superficial and deep posterior compartments.

gastrocnemius through a separate incision.¹⁰

A single incision technique for decompressing all five compartments of the leg has been described by Davey and coworkers.¹¹ A long lateral incision is created extending from the fibular neck to 3 to 4 cm proximal to the lateral malleolus. To reach the tibialis posterior compartment and at the same time protect the peroneal vessels, the flexor hallucis longus must be reflected subperiosteally of the posterior fibula.

Postoperatively, a compressive dressing should be applied for the first two to three days. Patients should be encouraged to begin early range of motion exercises and weightbearing to help prevent scarring and adhesions. This is especially true in patients who undergo decompression of the deep posterior compartment. Physical therapy may aid in mobilization in the first and second postoperative week. Once wound healing occurs, light exercise can begin, and after three to four weeks, patients may begin full activities as tolerated.

Surgical treatment of CECS has been generally successful, regardless of technique used.^{10,18,30,32-35} Detmer and colleagues¹⁰ found that 90% of patients were significantly improved after fasciotomy (39% were anterior compartment fasciotomies, 12% lateral, 48% posterior). Styf and Körner³⁵ had 95% good results after anterior compartment fasciotomy. Schepesis and associates³⁴ found similar success with fasciotomies for exertional anterior compartment syndrome, with excellent results in 96% of patients. However, 35% of patients had unsatisfactory results after fasciotomy for deep posterior exertional compartment syndrome.³⁴ Slimmon and coworkers³⁶ showed 60% excellent or good results at a mean of 51 months after fasciotomy with partial fasciectomy, with 58% of patients exercising at a lower level than before surgery. In general, studies of outcomes after surgical treatment of CECS have shown that patients fare better after anterior and lateral compartment fasciotomies than patients who undergo deep posterior compartment release.^{30,32-34} It is postulated that the surgical failures in patients with deep posterior compartment syndrome may be due to inadequate release of the tibialis posterior muscle or suboptimal postoperative mobilization that leads to hematoma and scar formation in the deep posterior compartment.^{11,33,34}

In the past, patients with exertional anterior compartment syndrome generally underwent fasciotomies of both the anterior and lateral compartment. There is recent evidence to suggest that in patients with isolated anterior compartment syndrome, simultaneous release of the lateral compartment may be unnecessary. A recent prospective study found that athletes with isolated anterior compartment release returned to full athletic activity three weeks sooner than those in whom both the anterior and lateral compartments were released.³⁷

Complications as high as 11% have been reported after surgical treatment.¹⁰ These include wound infections, hematomas, arterial and nerve injury, lymphocele, and deep vein thrombosis.

In addition to formal open procedures, endoscopic techniques for fasciotomies have recently been described.^{38,39} While these techniques allow for less soft tissue damage and possibly a quicker return to full activities, there are no long-term results to determine their efficacy.

Treatment of Recurrences

Recurrence rates after fasciotomy vary anywhere from 3% to 12%.^{33,35,40} Recurrence of elevated compartment pressures and pain upon exertion is most likely due to inadequate release of the involved compartment, or post-surgical fibrosis formation leading to a reduction in the space available for muscular expansion during exercise. In patients with an inadequate compartment release, extension of the fascial split from the previous operation can be curative.⁴¹ For patients with fibrosis formation, partial fasciectomy has been found to be successful in restoring normal compartment pressures and relieving pain during exertion.⁴²

Acute Exertional Compartment Syndrome

Acute exertional compartment syndrome is rare, but if unrecognized, can be devastating. It can present in the nonathlete who engages in strenuous, lengthy and unaccustomed physical activity; or it can present in athletes with a prior history of CECS as an acute-on-chronic type.^{17,18} Regardless of the patient's previous history or state of athletic conditioning, such cases must be considered absolute emergencies. Muscle necrosis and permanent neurological deficit will develop if patients are not promptly treated. The pathophysiology of acute exertional compartment syndrome is identical to compartment syndromes caused by trauma, burns, electrocution, and drug overdose. If suspected, compartment pressures should be rapidly obtained and involved compartments should undergo emergency fasciotomies.

Upper Extremity Exertional Compartment Syndrome

Chronic exertional compartment syndrome in the upper extremity is considered rare, with only case reports available in the literature. Cases have been reported in both the volar and dorsal compartments of the forearm and in the thenar, hypothenar, and interosseous musculature of the hand.^{4,43,44} As in lower extremity CECS, patients will complain of pain and swelling over the involved compartments after a period of intensive muscle use and may experience distal paresthesias. It is important to methodically examine the patient to rule out other causes of these symptoms. The differential diagnosis includes vascular claudication, herniated cervical disc, compressive neuropathies, chronic tenosynovitis, and angina with referred pain.

Tissue pressures of suspected compartments should be recorded before and after exercise stress. The same diagnostic criteria proposed by Pedowitz and colleagues⁸ for diagnosis of lower extremity CECS can be applied to the upper extremity. Cessation of causal activities can be

curative, however, no studies have looked at other forms of nonoperative management. Surgical release of the involved compartments is the mainstay of treatment for upper extremity CECS just as it is in the lower extremity. To release the superficial and deep volar compartments, the approach of Henry can be used. Proximally, the incision starts just lateral to the distal biceps tendon and travels distally along the course of the flexor carpi radialis. Both the superficial and deep volar compartments can be released through this incision. This incision can be extended distally across the wrist, making sure not to cross the volar wrist crease at a right angle, to allow for decompression of the carpal tunnel. Dorsally, the Thompson approach can be used. The skin incision lies along the line running from the lateral epicondyle to the ulnar aspect of Lister's tubercle. Both the dorsal compartment and the mobile wad can be released through this incision.

Summary

Chronic exertional compartment syndrome most commonly presents in the lower leg of athletic individuals. It results in exercise-induced pain, swelling, and paresthesias that can significantly affect athletic performance. Tissue pressure recordings remain the most specific test for diagnosis, but there is some evidence that noninvasive testing such as MRI may be helpful. The only curative nonoperative management is avoidance of causal activities. Surgical fasciotomies of involved compartments are generally quite successful. Acute exertional compartment syndrome is rare and is a surgical emergency. Exertional compartment syndrome of the upper extremity is quite rare and patients should be comprehensively examined to rule out more common etiologies.

References

- Mavor GE: The Anterior Tibial Syndrome. *J Bone Joint Surg Br* 1956;38:513-7.
- Freedman BJ: Dr. Edward Wilson of the Antarctic; a biographical sketch, followed by an inquiry into the nature of his last illness. *Proc R Soc Med* 1953;47:23-30.
- Styf J, Lysell E: Chronic compartment syndrome in the erector spinae muscle. *Spine* 1987;12:680-2.
- Soderberg TA: Bilateral chronic compartment syndrome in the forearm and the hand. *J Bone Joint Surg Br* 1996;78:780-2.
- Raether PM, Lutter LD: Recurrent compartment syndrome in the posterior thigh: report of a case. *Am J Sports Med* 1982;10:40-3.
- Qvarfordt P, Christenson JT, Eklof B, et al: Intramuscular pressure, muscle blood flow, and skeletal muscle metabolism in chronic anterior tibial compartment syndrome. *Clin Orthop* 1983;(179):284-90.
- Styf J: Diagnosis of exercise-induced pain in the anterior aspect of the lower leg. *Am J Sports Med* 1988;16:165-9.
- Pedowitz RA, Hargens AR, Mubarak SJ, Gershuni DH: Modified criteria for the objective diagnosis of chronic compartment syndrome of the leg. *Am J Sports Med* 1990;18:35-40.
- Garcia-Mata S, Hidalgo-Ovejero A, Martinez-Grande M: Chronic exertional compartment syndrome of the legs in adolescents. *J Pediatr Orthop* 2001;21:328-34.
- Detmer DE, Sharpe K, Sufit RL, Girdley FM: Chronic compartment syndrome: diagnosis, management, and outcomes. *Am J Sports Med* 1985;13:162-70.
- Davey JR, Rorabeck CH, Fowler PJ: The tibialis posterior muscle compartment: an unrecognized cause of exertional compartment syndrome. *Am J Sports Med* 1984;12:391-7.
- Mohler LR, Styf JR, Pedowitz RA, et al: Intramuscular deoxygenation during exercise in patients who have chronic anterior compartment syndrome of the leg. *J Bone Joint Surg Am* 1997;79:844-9.
- Amendola A, Rorabeck CH, Vellett D, et al: The use of magnetic resonance imaging in exertional compartment syndromes. *Am J Sports Med* 1990;18:29-34.
- Balduini FC, Shenton DW, O'Connor KH, Heppenstall RB: Chronic exertional compartment syndrome: correlation of compartment pressure and muscle ischemia utilizing 31P-NMR spectroscopy. *Clin Sports Med* 1993;12:151-65.
- Trease L, van Every B, Bennell K, et al: A prospective blinded evaluation of exercise thallium-201 SPET in patients with suspected chronic exertional compartment syndrome of the leg. *Eur J Nucl Med* 2001;28:688-95.
- Clanton TO, Solcher BW: Chronic leg pain in the athlete. *Clin Sports Med* 1994;13:743-59.
- Reneman RS: The anterior and the lateral compartmental syndrome of the leg due to intensive use of muscles. *Clin Orthop* 1975;(113):69-80.
- Martens MA, Backaert M, Vermaut G, Mulier JC: Chronic leg pain in athletes due to a recurrent compartment syndrome. *Am J Sports Med* 1984;12:148-51.
- Michael RH, Holder LE: The soleus syndrome: a cause of medial tibial stress (shin splints). *Am J Sports Med* 1985;13:87-94.
- Mubarak SJ, Hargens AR, Owen CA, et al: The wick catheter technique for measurement of intramuscular pressure: a new research and clinical tool. *J Bone Joint Surg Am* 1976;58:1016-20.
- Brace RA, Guyton AC, Taylor AE: Reevaluation of the needle method for measuring interstitial fluid pressure. *Am J Physiol* 1975;229:603-7.
- Matsen FA 3rd, Mayo KA, Sheridan GW, Krugmire RB Jr: Monitoring of intramuscular pressure. *Surgery* 1976;79:702-9.
- Rorabeck CH, Castle GS, Hardie R, Logan J: Compartmental pressure measurements: an experimental investigation using the slit catheter. *J Trauma* 1981;21:446-9.
- Gershuni DH, Yaru NC, Hargens AR, et al: Ankle and knee position as a factor modifying intracompartamental pressure in the human leg. *J Bone Joint Surg Am* 1984;66:1415-20.
- Rorabeck CH: Exertional tibialis posterior compartment syndrome. *Clin Orthop* 1986;(208):61-4.
- Eskelin MK, Lotjonen JM, Mantysaari MJ: Chronic exertional compartment syndrome: MR imaging at 0.1 T compared with tissue pressure measurement. *Radiology* 1998;206:333-7.
- Verleisdonk EJ, van Gils A, van der Werken C: The diagnostic value of MRI scans for the diagnosis of chronic exertional compartment syndrome of the lower leg. *Skeletal Radiol* 2001;30:321-5.
- Beckham SG, Grana WA, Buckley P: A comparison of anterior compartment pressures in competitive runners and cyclists.

- Am J Sports Med 1993;21:36-40.
29. Blackman PG, Simmons LR, Crossley KM: Treatment of chronic exertional anterior compartment syndrome with massage: a pilot study. *Clin J Sport Med* 1998;8:14-7.
 30. Rorabeck CH, Bourne RB, Fowler PJ: The surgical treatment of exertional compartment syndrome in athletes. *J Bone Joint Surg Am* 1983;65:1245-51.
 31. Mubarak SJ: Double-incision fasciotomy of the leg for decompression in compartment syndromes. *J Bone Joint Surg Am* 1977;59:184-7.
 32. Fronek J, Mubarak SJ, Hargens AR, et al: Management of chronic exertional anterior compartment syndrome of the lower extremity. *Clin Orthop* 1987;(220):217-27.
 33. Rorabeck CH, Fowler PJ, Nott L: The results of fasciotomy in the management of chronic exertional compartment syndrome. *Am J Sports Med* 1988;16:224-7.
 34. Schepsis AA, Martini D, Corbett M: Surgical management of exertional compartment syndrome of the lower leg: long-term followup. *Am J Sports Med* 1993;21(6):811-7; discussion 817.
 35. Styf JR, Korner LM: Chronic anterior-compartment syndrome of the leg: results of treatment by fasciotomy. *J Bone Joint Surg Am* 1986;68:1338-47.
 36. Slimmon D, Bennell K, Brukner P, et al: Long-term outcome of fasciotomy with partial fasciectomy for chronic exertional compartment syndrome of the lower leg. *Am J Sports Med* 2002;30:581-8.
 37. Schepsis AA, Gill SS, Foster TA: Fasciotomy for exertional anterior compartment syndrome: is lateral compartment release necessary? *Am J Sports Med* 1999;27:430-5.
 38. Leversedge FJ, Casey PJ, Seiler JG 3rd, Xerogeanes JW: Endoscopically assisted fasciotomy: description of technique and in vitro assessment of lower-leg compartment decompression. *Am J Sports Med* 2002;30:272-8.
 39. Kitajima I, Tachibana S, Hirota Y, et al: One-portal technique of endoscopic fasciotomy: chronic compartment syndrome of the lower leg. *Arthroscopy* 2001;17:33.
 40. Howard JL, Mohtadi NG, Wiley JP: Evaluation of outcomes in patients following surgical treatment of chronic exertional compartment syndrome in the leg. *Clin J Sport Med* 2000;10:176-84.
 41. Puranen J, Alavaikko A: Intracompartmental pressure increase on exertion in patients with chronic compartment syndrome in the leg. *J Bone Joint Surg Am* 1981;63(8):1304-9.
 42. Bell S: Repeat compartment decompression with partial fasciectomy. *J Bone Joint Surg Br* 1986;68:815-7.
 43. Pedowitz RA, Toutoungi FM: Chronic exertional compartment syndrome of the forearm flexor muscles. *J Hand Surg [Am]* 1988;13(5):694-6.
 44. Imbriglia JE, Boland DM: An exercise-induced compartment syndrome of the dorsal forearm: a case report. *J Hand Surg [Am]* 1984;9A(1):142-3.