CASE REPORT

Robot-Assisted Laparoscopic Ileal Ureter

Joseph R. Wagner, MD, Megan O. Schimpf, MD, Jeffrey L. Cohen, MD

ABSTRACT

Background and Objectives: A patient with a solitary kidney, cysteine stones, and recurrent ureteral strictures underwent robot-assisted laparoscopic ureterectomy with ileal ureter formation.

Methods: Using a transperitoneal, 4-port robotic approach, we removed the strictured ureter and created an ileal ureter. The ileal-pyelo and ileal-vesical anastomoses were performed using the robotic system. An extracorporeal bowel anastomosis was performed using stapling devices. Operative time was 9 hours with negligible blood loss, and the patient was discharged after 5 days.

Results: A cystogram at 10 days demonstrated patent anastomoses without extravasation. The patient continues to do well 48 months later.

Conclusion: Robot-assisted laparoscopic ileal ureter replacement is feasible with excellent long-term outcome.

Key Words: Robotics, Ureter, Ileal ureteral substitution, Laparoscopy.

Department of Urology, Hartford Hospital/University of Connecticut, Hartford, Connecticut, USA (Dr Wagner).

Department of Obstetrics and Gynecology, Division of Urogynecology, Hartford Hospital/University of Connecticut, Hartford, Connecticut, USA (Dr Schimpf).

Department of Surgery/Connecticut Surgical Group, Hartford Hospital/University of Connecticut, Hartford, Connecticut, USA (Dr Cohen)

Address reprint requests to: Megan O. Schimpf, MD, 85 Seymour St, Ste 525, Hartford, CT 06106, USA. Telephone: 860 545 4338, Fax: 860 545 1973, E-mail: mschimp@harthosp.org

INTRODUCTION

In patients who require complex ureteral reconstruction, one surgical option is the creation of an ileal ureter substitution, in which a segment of diseased ureter is removed and substituted with an isoperistaltic segment of ileum.[1] In the appropriate patient, outcomes from this procedure are good.[1]

Based on the long-term robotic and advanced laparoscopic experience at our institution in both urologic and colorectal surgery, we felt that use of the da Vinci Robotic System (Intuitive Surgical, Inc, Sunnyvale, CA) in this procedure may show benefit over the conventional laparoscopic or open technique. A search of the English language medical literature since 1950 did not find any reports of a robotic-assisted laparoscopic ileal ureter creation. Here, we describe our technique and 48-month follow-up.

CASE REPORT

A 39-year-old man with a solitary left kidney and cysteine stones had undergone 27 procedures including stents, ureteroscopies, and percutaneous nephrolithotomies over 18 months. He was on maximal medical therapy to prevent stone formation and was otherwise healthy with a serum creatinine of 1.3mg/dL. Ureteroscopy was becoming increasingly difficult due to ureteral strictures. The patient opted for a "stone chute" with ileal ureter replacement and chose the robotic-assisted approach after an extensive preoperative discussion of the surgical options, risks, and benefits.

The patient was secured to the table in a 45-degree, left-flank-up position. The abdomen, flank, and genitals were included in the surgical field. A Hasson trocar was placed periumbilically and used for the robotic camera port, specimen removal, and the bowel anastomosis. Three 8-mm da Vinci robotic trocars were placed; ports 1 and 2 were used for the superior dissection and anastomosis while ports 1 and 3 were used for the inferior dissection and anastomosis **(Figure 1)**. We began with the inferior dissection.

The white line of Toldt was incised and the colon was mobilized medially. Though significant peri-ureteral in-

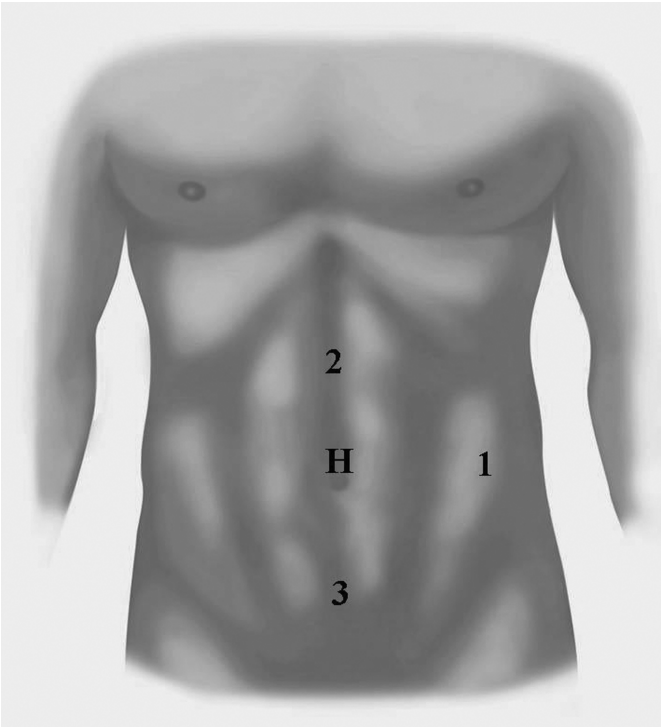

Figure 1. Port placement for robotic ileal ureter creation: A 12-mm trocar was placed at the umbilicus with a Hasson technique (H). Three 8-mm robotic trocars were placed (1,2,3) as depicted.

flammation was present, the ureter was identified crossing the iliac vessels. The ureter was clipped as it entered the bladder and transected. After dissecting the ureter as far superiorly as possible, the robot was repositioned to perform the remaining superior dissection. The renal pelvis was incised circumferentially. Several renal pelvic stones were removed, and the collecting system was flushed.

The robot was undocked and wheeled away from the surgical field. A 5-mm, 0-degree lens was placed through port 2, and the specimen was removed with a retrieval bag inserted through the Hasson trocar. Using standard laparoscopic instruments and a Harmonic scalpel, an appropriate length of ileum was selected and transected using a laparoscopic stapling device. The mesentery was incised with a Harmonic scalpel to allow adequate mobilization, and the ileum was swung laterally. We did not retroperitonealize the segment by passing it through the colonic mesentery. Two long 0 silk sutures were placed on each end of the bowel and clipped together to allow for easier identification for the bowel anastomosis.

The robot was brought back into the surgical field. The staples from each end of the ileal segment were excised. A dyed and undyed 2–0 Monocryl on an SH needle (Ethicon, Cincinnati, OH) were tied together, and a running ileal-pyelo anastomosis was performed as described for urethral-vesical anastomosis after radical prostatectomy.[2] After completing the posterior portion of the anastomosis, a 0.038 guidewire was passed through the ileal segment, over which an 8Fr, 26-cm double JJ stent was passed. The proximal anastomosis was then completed. A cystotomy was performed in the superior-lateral bladder, and the mucosa was everted with interrupted 3–0 Vicryl on an RB needle (Ethicon, Cincinnati, OH). The distal anastomosis was performed over the stent using the same technique. The bladder was backfilled without evidence of extravasation.

A Jackson-Pratt drain was placed near each anastomosis and brought out through ports 1 and 3 **(Figure 2)**. The 5-mm, 0-degree lens was again passed into port 2 and the previously placed ileal sutures were grasped through the Hasson trocar. The bowel was brought out through this site, and bowel continuity was restored using stapling devices. The Hasson incision was closed with interrupted 0 Vicryl sutures.

Total operating time was 9 hours with negligible blood loss. Pathology revealed dense ureteral strictures with chronic inflammation. The patient had an uncomplicated recovery and was discharged home on postoperative day 5. A cystogram at 10 days demonstrated patent anastomoses without extravasation **(Figure 3)**. The patient returned to his usual activities in 14 days. Serum creatinine, electrolytes, and renal ultrasound are stable. He has not had

Figure 2. Two 10-mm Jackson-Pratt drains are placed through the 8-mm robotic ports 1 and 3.

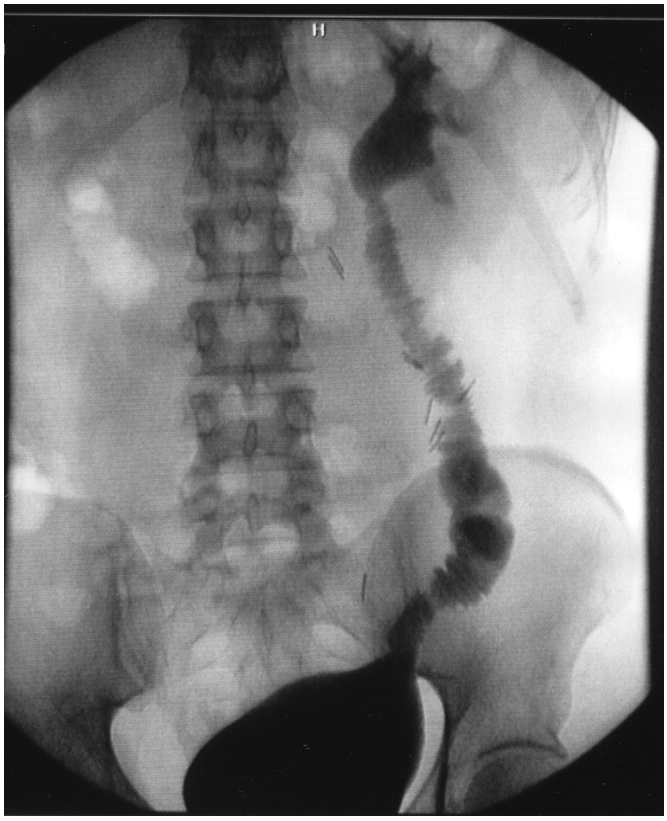

Figure 3. Postoperative cystogram confirming patent anastomoses with no extravasation.

any episodes of obstruction or renal colic and continues to do well 48 months after surgery.

DISCUSSION

The primary indication for ileal ureter replacement is lengthy ureteral injury precluding simple reimplantation or a Boari flap.[1,3] More common causes include multiple stones, surgical trauma, radiation, and malignancy.[1,3] The only alternatives for most patients requiring ileal ureter are a permanent nephrostomy tube, autotransplantation, and nephrectomy.[1] Given his solitary kidney and history of cysteine stones, our patient was an ideal candidate for ileal ureter replacement.

Laparoscopic techniques are being increasingly utilized for reconstructive procedures, such as radical prostatectomy and cystectomy. With experience, this technology is being applied to an expanding number of procedures. To our knowledge, only 2 prior reports exist of ileal ureter replacement with traditional laparoscopic techniques.[3,4]

Robotic-assisted laparoscopic surgery offers several advantages over conventional laparoscopic surgery and is ideally suited for longer, complex reconstructive procedures. The robotic system offers a 3-dimensional visualization with magnification for the surgeon, who can control camera position. Ergonomically, the surgeon is seated comfortably at a console. The surgical instruments have increased degrees of freedom that facilitate the surgeon's ability to perform complex maneuvers in a tight space without tremor or fatigue. These factors also decrease estimated blood loss, incision length, hospital length of stay, postoperative pain, and complication rate compared with open or laparoscopic surgery.[5–7]

Although the large surgical field required for this procedure may seem to preclude the robotic approach, our technique demonstrates that the same ports can be used with changes in the robotic position to safely complete the surgery. This surgery was done prior to the introduction of the newer da Vinci-S system, but either system could be used today.

Despite the advantages of robotics, the procedure was lengthy for several reasons. Identification of the ureter was difficult due to severe retroperitoneal inflammation, which was not unexpected given the patient's stone history and would have also complicated open surgery. Repositioning the robot 4 times was time-consuming. Passing the wire down the ileal segment proved to be somewhat difficult. Lastly, surgeons and nurses were performing a new procedure, and the learning curve for laparoscopic procedures has been demonstrated to be significant.[6,7] Times for this case were similar to times for reported laparoscopic cases.[3] With advancing robotic experience, some of these drawbacks can be expected to improve.[5,6]

CONCLUSION

The robot-assisted approach achieved the goals of traditional ileal ureter replacement, with maintenance of renal function and decreased stone formation, along with the usual benefits of a minimally invasive approach.[5] Because ileal ureter replacement is not a commonly performed procedure, it is unlikely a prospective comparison of the open and laparoscopic approach will be forthcoming. However, robot-assisted laparoscopic ileal ureter replacement appears to be a reasonable alternative to the open approach in the appropriate patient.

References:

1. Hsu THS, Streem SB, Nakada SY. Management of upper urinary tract obstruction. In Wein AJ, ed. *Campbell-Walsh Urology*. 9th ed. Philadelphia, PA: WB Saunders; 2007.

2. Van Velthoven RF, Ahlering TE, Peltier A, Skarecky DW, Clayman RV. Technique for laparoscopic running urethrovesical anastomosis: the single-knot method. *Urology*. 2003;61(4):699–702.

3. Gill IS, Savage SJ, Senagore AJ, Sung GT. Laparoscopic ileal ureter. *J Urol*. 2000;163:1199–1202.

4. Kamat N, Khandelwal P. Laparoscopy-assisted ileal ureter creation for multiple tuberculous strictures: report of two cases. *J Endourol*. 2006;20(6):388–393.

5. Menon M, Shrivastava A, Tewari A. Laparoscopic radical prostatectomy: conventional and laparoscopic. *Urology*. 66(Suppl 5A):101–104, 2005.

6. Chang L, Satava RM, Pellegrini CA, Sinanan MN. Robotic surgery: identifying the learning curve through objective measurement of skill. *Surg Endosc*. 2003;17:1744–1748.

7. Yohannes P, Rotariu P, Pinto P, Smith AD, Lee BR. Comparison of robotic versus laparoscopic skills: is there a difference in the learning curve? *Urology*. 2002;60:39–45.